UNIV. OF
OREGON
LIBRARY

BINDING LIST JUN 15 1924

ARCHIVES OF SURGERY

EDITORIAL BOARD

DEAN LEWIS, Chicago
EVARTS A. GRAHAM, St. Louis
THOMAS CULLEN, Baltimore
HUGH CABOT, Ann Arbor, Mich.
WILLIAM DARRACH, New York City
EDWARD STARR JUDD, Rochester, Minn.

VOLUME 7
1923

190137
27.6.24

PUBLISHERS
AMERICAN MEDICAL ASSOCIATION
CHICAGO, ILL.

RD
1
A72
v.7

CONTENTS OF VOLUME 7

JULY, 1923. NUMBER 1

Pyogenic Infection of the Parotid Glands and Ducts. Vilray Papin Blair, M.D., and Earl Calvin Padgett, M.D., St. Louis.... 1

The End-Results of Surgery of the Thyroid. John DeJ. Pemberton, M.D., Rochester, Minn..... 3

Histopathology and Etiology of Varicose Veins. Berlin D. Nicholson, M.D., Charlottesville, Va..... 47

The Physiology of an Arteriovenous Fistula. Emile Holman, M.D., Baltimore 64

The Skin Signs of Viscerosensory Phenomenon in Acute Appendicitis. Edward M. Livingston, M.D., New York..... 83

Studies in Experimental Traumatic Shock. VIII. The Influence of Morphin on the Blood Pressure and Alkali Reserve in Traumatic Shock. McKeen Cattell, Ph.D., Boston..... 96

Prolonged Intravenous Infusion and the Clinical Determination of Venous Pressure. Wilder G. Penfield, M.D., and David Teplitsky, M.D., New York..... 111

Blood Transfusion: A Study of Two Hundred and Forty-Five Cases. Clover H. Copher, M.D., St. Louis..... 125

Studies in Exhaustion: V. Hemorrhage. G. W. Crile, M.D., Cleveland 154

The Chemical Pathology of Pyloric Occlusion in Relation to Tetany: A Study of the Chlorid, Carbon Dioxid and Urea Concentrations of the Blood. Henry A. Murray, Jr., M.D., New York..... 166

Traumatic Lesions of the Intestine Caused by Nonpenetrating Blunt Force. B. M. Vance, M.D., New York..... 197

A Study of the Viability of Bone After Removal from the Body. S. L. Haas, M.D., San Francisco..... 213

Desmoid Tumors: A Report of Thirty-One Cases. Ralph W. Nichols, M.D., Rochester, Minn..... 327

SEPTEMBER, 1923. NUMBER 2

Extensive Hemorrhagic Extravasation from the Venous System of Galen, with Clinical Syndrome. A Report of Three Fatal Cases with Two Necropsies. Charles Bagley, Jr., M.D., Baltimore 237

Resection of the Proximal Colon for Malignancy. Fred W. Rankin, M.D., Louisville, Ky., and Albert J. Scholl, M.D., Rochester, Minn. 258

An Unusual Alteration in the Natural History of a Giant Cell Tumor of Bone. W. S. Stone, M.D., and James Ewing, M.D., New York 280

SEPTEMBER, 1923.—Continued

Brain Abscess. Harry Hyland Kerr, M.D., Washington, D.C..... 297

The Transfusion of Unmodified Blood. Osborne A. Brines, Detroit 306

Empyema Necessitatis and Some Allied Conditions. Frederick J. Tees, M.D., Montreal..... 321

Intra-Abdominal Hernias.. Nat H. Copenhaver, M.D., Rochester, Minnesota 332

Deetherization by Means of Carbon Dioxid Inhalations, with some Observations on Pulmonary Ventilation and Ether Tension During Anesthesia. James C. White, M.D., Boston..... 347

Endothelioma of the Spleen. A Study of Two Cases, with Review of the Literature of Primary Malignancy of the Spleen. Curtis E. Smith, M.D., and G. Y. Rusk, M.D., San Francisco.... 371

Twenty-First Report of Progress in Orthopedic Surgery. Robert B. Osgood, M.D.; Robert Soutter, M.D.; Harry C. Low, M.D.; Murray S. Danforth, M.D.; C. Herman Bucholz, M.D.; Lloyd T. Brown, M.D.; Philip D. Wilson, M.D., and M. N. Smith-Petersen, M.D., Boston..... 415

Correspondence 466

NOVEMBER, 1923. NUMBER 3

A Clinical and Pathologic Study of Ten Bone Tumors. John J. Morton, M.D., and William C. Duffy, M.D., New Haven, Conn.. 469

Notes on Five Cases of Paget's Deforming Osteomyelitis, with Description of the Specimen of a Femur from a Sixth. Leonard W. Ely, M.D., San Francisco..... 532

A Fundamental Factor in the Recurrence of Inguinal Hernia. M. G. Seelig, M.D., and Kehar Singh Chouke, M.D., San Francisco.... 553

Experimental Cord Crushes, with Especial Reference to the Mechanical Factors Involved and Subsequent Changes in the Areas of the Cord Affected. Joseph F. McVeigh, M.D., Galveston, Texas..... 573

The Prognosis and Treatment of Fractures of Leg and Ankle. End-Results in One Hundred Patients. Astley P. C. Ashhurst, M.D., and Edward T. Crossan, M.D., Philadelphia..... 601

Treatment of Fractures by Orthopedic Methods. Samuel W. Boorstein, M.D., and Isadore J. Landsman, M.D., New York..... 633

Suppurative Tenosynovitis of the Flexor Muscles of the Hand. Mather Cleveland, M.D., New York..... 661

Correspondence 687

Index 689

ARCHIVES OF SURGERY

VOL. 7 JULY, 1923 No. 1

PYOGENIC INFECTION OF THE PAROTID GLANDS AND DUCTS *

VILRAY PAPIN BLAIR, M.D.
AND
EARL CALVIN PADGETT, M.D.
ST. LOUIS

The sum of our experience in dealing with pyogenic parotitis has lead to three practical conclusions:

1. Acute suppurative parotitis is, in the great majority of cases, an ascending infection from the duct related to decreased salivary flow, fever and depressed general condition.

2. Early adequate liberation and drainage of the parotid gland is a safe and useful procedure in all cases of severe septic parotitis not plainly terminal, and in some cases it may be life saving.

3. Meatotomy of the duct is useful in certain cases of parotitis associated with obstruction not due to stones.

Both clinical observation and a review of this series of cases suggest certain tentative deductions as to etiology, clinical course and treatment. The series is of itself too small to form a basis for broad deductions that would controvert generally accepted ideas. These observations are presented as a further contribution to the subject. The tentative deductions are here used as a basis for classifying observations rather than as an asservation of principals. Certain cases will be reported en toto, with extracts from other cases which illustrate the various types and points. A few of the cases are unique in this series but none of them contradict our tentative conclusions.

A close analogy is suggested between infections of the salivary glands and of other larger glands which also empty into mucous lined

---

* From the Department of Surgery of Washington University Medical School.

* Of the fifty-six cases here presented, thirty-one were those of private patients referred to or seen in consultation by Dr. Blair in various hospitals. The other cases are from the various ward services of the Barnes Hospital and the St. Louis Children's Hospital. Only the cases at the Barnes and the St. Louis Children's Hospital, during the past four years, were seen by Dr. Padgett. Case 42 (submaxillary duct obstruction) brings the number of cases to fifty-seven. Two cases of subtemporal abscess are also recorded, but not listed as parotid cases. The presentation of the literature endeavors to give credit for certain original conception of the disease and also of its treatment.

cavities, the pathologic conditions of which have been subjected to a much closer scrutiny.

Taken as a whole, the cases in the series fall for the greatest part into two broad groups, one in which an acute inflammation of the gland is the first noticed and the predominant symptom, the other presenting primarily recurrent symptoms of duct obstruction. Added to the obstruction there may be any grade of inflammation of the gland or duct. The obstructive agent might be simply the swelling and thickening of the mucosa, or a plug of mucus lodged at the meatus; or some inflammatory constriction, or a stone formed anywhere within the duct. If one were to accept the sublingual gland as the origin of ranulae, we would have its most common failing.

Cases in the first group of parotid infections were commonly characterized by a sudden onset and a rapid course, with pain and swelling in the gland region and the general symptoms of a severe infection; or, less often, a slight swelling and mild rise in temperature were the only symptoms observed. They were practically always secondary to, or appeared as a complication of, an injury, a postoperative state or some acute or chronic illness. It was characteristic of this condition that, once relieved, it showed little tendency to recur.

Cases of the second group seemed to be related to no preceding illness or injury and showed a very distinct tendency to recurrence of symptoms. They were usually characterized by recurrent exacerbations of moderate pain and swelling in the gland region, often more pronounced when food is taken, and with or without the general symptoms of a mild infection. Rarely, the exacerbation develops with all the acute signs found in those of the first group.

Naturally, the two groups may merge, and there are a few that are not easily placed in either group.

It is now rather generally accepted that at least the great majority of pyogenic inflammations of the parotid gland are due to an ascending infection; i. e., that the infection travels along the lining mucosa of the excretory duct. The cases in which an inflammation of the duct could be demonstrated are here classified as ascending infections. Evidence of duct infection varied from a minute bright red protrusion of the duct mucosa at the papilla to a string of cloudy mucus or pus exuding from the duct, or both. There are certain acute cases recorded in this group in which the glandular inflammation so overshadowed a possible inflammation of the duct that the latter was overlooked or not recorded.

The most common infecting organism was a staphylococcus. Those cases showing a streptococcus were of the greatest virulence clinically.

Case 1 was selected as being more or less illustrative of the acute ascending type of pyogenic infection.

REPORT OF CASES

CASE 1.—A woman, aged 51, entered Barnes Hospital, Nov. 21, 1920 with a history of exposure to a cold wind, six days before entrance, while perspiring freely. She developed a slight sore throat in the afternoon of the same day, with slight swelling of the glands in the neck the following morning. Three days later, the left parotid region began to swell and was painful and tender to touch. The swelling, tenderness and pain increased during the next three days. The head ached, and the patient felt ill, had no appetite and felt hot.

On admission, the temperature was 102.5 F., the pulse, 130. The left side of the face showed a tender, pink glazed dome-shaped swelling which extended to the temporal region and down the neck to within 4 cm. of the clavicle. The maximum swelling and tenderness was situated over the left parotid region. There was no fluctuation. The left eye was nearly closed from edema. There was marked limitation of motion of the mandible. Thick pus could be expressed from the parotid duct within the mouth and the papilla of the duct was fiery red.

Operation was advised on entrance, the fourth day of the infection. The usual incision (described later) was made, and a swollen edematous gland with minute abscesses was found. Culture showed *Staphylococcus aureus.* The fever and elevated pulse rate subsided gradually. The patient left the hospital in twelve days.

This is the type of case in which operation gives marked relief and in which the mortality would probably be rather high if no operative relief was obtained. Marked evidence of duct inflammation was shown. However, the course of the inflammation of the gland is not quite so rapid as is often seen.

CASE 2.—A woman, aged 53, entered Barnes Hospital with pernicious anemia, for which splenectomy was performed. A few days after operation a fecal fistula developed. Seven days after operation, the patient complained of a pain in the region of the right ear. The ear was negative on examination. The following day, March 7, 1922, the right parotid region began to swell. Pus was expressed from the duct, and the papilla was slightly red. No fluctuation was present. The right parotid gland region was moderately swollen, edematous and tender. The temperature was 101 F., the pulse, 110. The next day, as there was greater swelling and the gland was more tender, the gland was explored and drained. It was found to be edematous, with necrotic areas and here and there a small drop of pus. Culture showed staphylococci. Convalescence was immediate. However, after being up and out of bed, the patient developed pneumonia and died, five weeks later.

This case corresponds more or less to the preceding case, save that the infection developed postoperatively in a person with a debilitating blood disease. This patient had special nurses and her mouth was washed several times a day. However, just preceding the development of the parotitis, she was very ill, was vomiting and had a diarrhea. The mouth was dry and the lips were covered with sordes.

CASE 3.—A woman, aged 35, while at St. Anthony's Hospital, Jan. 15, 1915, during an attack of pneumonia, developed a mass "the size of an egg," on the right side of the face in front and below the ear. The lump became hard

and the swelling spread rapidly. In twenty-four hours, the edema had extended down to the breast on the right side and to the middle of the forehead toward the left. The right eye was closed from edema. The swelling extended backward to the occipital region. The temperature was 102 F., the pulse, 124.

Operation was performed forty-eight hours after onset. The usual incision was made, except that the incision line was extended downward to the middle of the neck through the deep cervical fascia. Many small abscesses were found. Culture showed staphylococci. The patient recovered. No note was made here of the condition of the parotid papilla and duct.

Case 4.—A woman, aged 28, entered Barnes Hospital, January 28, 1923, following a spontaneous abortion, nineteen days previously. Uterine infection followed, and a pure culture of *Streptococcus viridans* was obtained. The patient was very ill. The temperature was 103 F., the pulse 130. She had a marked secondary anemia, with a hemoglobin of 35 per cent. A blood transfusion was given two days after entrance. On that day (January 30), she complained of discomfort anterior to the right ear. Later that night, the right parotid region was very slightly swollen. The following morning, the right parotid region was markedly swollen, with some extension of swelling to the upper neck region. No fluctuation was noted. At one time, a slight amount of turbid fluid was expressed from Stenson's duct. At other times, the fluid was clear. The papilla was not noticeably red, but the condition of profound anemia might have prevented redness. The patient was delirious. The temperature was 104 F., the pulse 120 and of very poor quality. The leukocytes numbered 10,000; erythrocytes, 1,720,000 before transfusion and 2,260,000 after transfusion. A blood culture, January 29, showed a nonhemolytic streptococcus and *Staphylococcus albus* (probably a contamination). Four more blood cultures were taken, January 30 and February 1, 5 and 15. All were negative.

The right parotid region was incised and drained the morning after the evening of onset (January 31), under gas anesthesia. February 1, a right facial weakness was present. Culture showed *Staphylococcus aureus.* January 31, Dr. Barker diagnosed a vegetative endocarditis which, from clinical signs, involved the aortic and mitral valves.

On the morning of February 1, it was noted that during the night the patient had developed a parotid swelling on the left side. The patient's condition was a little worse than at the time of the incision of the opposite parotid region and she was semicomatose. The left parotid was incised and drained. Culture showed *Staphylococcus aureus.* On the following day, there was a noticeable improvement. The pulse was 110, the temperature, 101.5 F. For about one week, the condition improved gradually. The white blood count rose to about 23,000, and after remaining at that figure for about ten days, gradually fell with the temperature. The day following the first operation, a partial paralysis of the left seventh cranial nerve was noted. Within four days, paralysis was complete. The paresis of the upper facial muscles seems to be less at the present writing (March 13, 1923). It was thought that the facial nerve was not torn with the forceps, since paralysis was not complete immediately after operation. Time alone will tell whether the paresis is due to severing the nerve or to the presence of inflammatory tissue surrounding or involving the nerve.

A superficial abscess developed on each side below the lobe of the ear over the posterior extension of the gland during the third week of convalescence. These were incised and drained under local anesthesia and caused no further trouble. At present (March 15, 1923), the patient is still in the hospital, but has a normal temperature and pulse rate.

Case 5.—A woman, aged 26, who entered Mullanphy Hospital, Feb. 5, 1923, was seen, February 13, in consultation with Dr. John Morfit, who, February 8, had removed a nonsuppurating appendix. The following day slight pain called attention to the right parotid region. The temperature was 102 F., the pulse, 90. The parotid region was noticeably swollen the following day, and the pain was more marked. Swelling and pain continued. February 11, Dr. Morfit made a short incision through the skin below the lobe of the ear and inserted a curved artery clamp, stuck upward and also forward, leaving a heavy strip of rubber dam in place. Culture from the gland showed *Staphylococcus aureus.* A free discharge of pus was noted from the duct. Three days later, profuse drainage occurred from the incision, also through the external auditory canal. The extreme induration persisted until the pus flow became free. The temperature during this time was about 102.5 F., the pulse, from 90 to 100. The temperature did not begin to recede until ten days after operation, subsiding gradually. The patient left the hospital, February 23.

Case 6.—Woman, aged 38, who was admitted to Barnes Hospital, May 14, 1922, with a diagnosis of duodenal ulcer, and May 15, 1922, underwent gastroenterostomy and curettage, was in good condition after operation. Two days later, a swelling appeared over the left parotid region. During the next twelve hours, the swelling increased to the size of half a baseball. Induration and tenderness became marked over the parotid region, and the edema extended outward radially about 1 inch (2.5 cm.). The papilla of Stenson's duct was swollen. Yellow pus could be expressed. The patient was first seen, late in the evening, by Dr. Blair, who advised deferring operation until morning, and continuing application of an icebag to the face. A culture of pus from Stenson's duct showed staphylococcus and a green streptococcus. The white blood count was 16,900. The temperature was 102.5 F., the pulse, 128. At 2 a. m., the intern was called by the nurse, who said that the patient was choking but that breathing had been normal until a few minutes before. The patient was now pulseless and pale, giving an occasional gasp, with marked stridor. A tracheotomy was performed immediately. Respiratory reaction could not be obtained with artificial respiration. In this case, a question as to edema of the glottis arose. This seemed possible because of the rapid spread of the edema in the preceding twelve hours. No necropsy was obtained.

Case 7.—A woman, aged 49, Feb. 22, 1922, following a gynecologic operation, developed swelling and a tender area over the right parotid region. The temperature was 101 F., and white blood count, 23,000. A red parotid duct opening with cloudy fluid exuding was noted, and the parotid region was drained the following day. A culture of the pus showed a staphylococcus. Convalescence was rapid.

Case 8.—A young man, aged 18, admitted to St. Anthony's Hospital, had, five days after an operation for an appendix abscess, developed pain, with swelling and redness in the left parotid region. Seven days later, the right parotid was similarly involved. Pus could be expressed from Stenson's duct on both sides. September 20, the swelling on the left began to subside, six days after onset. The right eye was closed from edema. September 26, there was fluctuation in both parotids. September 28, both parotids were incised and drained. A culture showed *Staphylococcus aureus.* The temperature ranged around 101 F., the pulse, around 100. After operation, there was rapid convalescence.

This case presented a bilateral parotid infection of a typical acute type, save that the virulency of the infection was not so marked as in certain cases.

Case 9.—A child, aged 2 years, who, in April, 1919, developed a left sided parotitis following bronchopneumonia, underwent incision and drainage of the parotid area, under gas anesthesia. Convalescence was rapid.

Case 10.—A girl, aged 12½ years, admitted to the Children's Hospital, after an appendectomy which had been followed by infection of the wound, seven days later, developed swelling in the right parotid region, with marked tenderness. The white blood count was 30,600. The following day, as the swelling continued to increase, the parotid area was incised lengthwise of the facial nerve, by the house officer. No pus was found. Three days later, the left parotid

Fig. 1 (Case 8).—Bilateral parotid abscess following operation for suppurative appendicitis. (From Blair's Surgery and Diseases of the Mouth and Jaws, 1912.)

region began to swell. Four days after the operation, both sides were equally swollen. The temperature was never over 101 F. Finally, seven days later, both parotid regions were opened, and the entire glands were found to be studded with abscesses. Convalescence was rapid.

Case 11.—A boy, aged 8, admitted to Children's Hospital, Jan. 31, 1921, with the history of onset of pain in the back of the neck, Jan. 17, three days after onset of pain, developed swelling below and in front of the right ear. The pain and swelling increased, and occasionally the patient had paroxysms of extreme pain. The temperature on admission was 39.2 C. (102.6 F.), the pulse, 120. There was a marked swelling extending over the entire parotid area downward and backward, involving the postcervical region. There was marked tenderness everywhere, and definite fluctuation just below and in front of the

ear. A profuse purulent discharge was flowing from the right external auditory canal. The ear drum was normal. Pus issued from a fistula into the external auditory canal. The white blood count was 19,400. The parotid abscess was incised and drained by an incision parallel with the nerve fibers. The temperature and pulse rate returned to normal within a week. A culture showed *Staphylococcus aureus.*

Case 12.—A boy, aged 9, entered Barnes Hospital, Jan. 1, 1915, with a history of pain and swelling in the right parotid region, Dec. 15, 1914, which increased over a period of four days. December 20, an incision was made and pus was evacuated. December 29, another abscess was opened. During the past two days, since the second abscess was opened, the pain and swelling had increased. When seen, he was unable to open his mouth more than 1 cm. The temperature was 100 F. The entire right side of the face was swollen from 2 cm. below the angle of the jaw to above the right eye. The eyelids were swollen. At a point between the zygoma and the angle of the jaw, there was a small incision in which a drain had been placed and from which pus was expressed. There was redness over the entire area. An area of induration extended from the level of the zygoma to about 2 cm. below the level of the jaw, but no definite fluctuation was noted. Jan. 1, 1915, the usual parotid incision was made, and multiple abscesses were found. A culture showed *Pneumococcus lanceolatus.* During his stay in the hospital, the temperature was never over 100 F., and pulse never over 90.

This is one of the few cases in the series that showed a pneumococcus. Drainage had not been properly made until the final operation, after which recovery was prompt. The infection was not particularly virulent, clinically.

Case 13.—A girl, aged 2 years, February 1912, in the height of a lobar pneumonia, developed an acute parotitis of the left side. It did not cause much discomfort and was allowed to go on to localized abscess formation. An incision was made below the ear, and pus was drained. Saliva discharged for a few weeks, and then the fistula closed.

In the ten cases following, the parotitis was secondary to other conditions, which were lethal. One cannot always be sure a given condition is terminal, and when there was doubt the parotid region was drained. The first three patients, therefore, were operated on. In the last seven of the ten cases, it was thought that the absolute hopelessness of the condition was recognized and operation was not advised.

Case 14.—A colored child, aged 30 months, entered Barnes Hospital in May, 1921, with bronchopneumonia and pyelonephritis. The nonprotein nitrogen was 120 mm. per hundred cubic centimeters. The patient had several convulsions, and was extremely drowsy in the meantime. Brawny swelling was present in the left parotid region, extending around over the mastoid to the back of the head. Hot wet packs were suggested at first because of the patient's poor condition, but the following day the gland was incised and drained. No pus was found. Culture showed a staphylococcus. The patient died the day after operation.

Histologic examination of a section of the gland revealed an extensive infiltration with lymphocytes and large mononuclears, with practically no poly-

morphonuclear cells, and small areas of early necrosis. The lumen of the acini contained débris and cells of the type seen elsewhere.

The question arises in this case as to which came first, the parotitis or the pneumonia, and which caused death.

Case 15.—A woman, aged 41, seen at the Missouri Baptist Hospital, March 11, 1921, following an operation for a pelvic and a gallbladder condition rapidly developed sepsis and uremia. Seven days after operation, the left parotid became swollen, painful and tender. The patient was delirious. The parotid area was incised and drained the following day. Several abscesses were found. A culture showed *Staphylococcus aureus*. The patient died from general sepsis.

Case 16.—A woman, aged 45, admitted to St. John's Hospital with a history of pelvic suppuration following a gynecologic operation, March 20, 1916, three days later developed pain and marked swelling of the right parotid region and the upper neck. The patient was seen three days after the onset. She com-

Fig. 2 (Case 16).—Extent of wound after removal of first packing. (From Blair's Surgery and Diseases of the Mouth and Jaws.)

plained of weakness of the right facial nerve. When the swelling was incised and drained, pus and necrotic tissue were found. The patient died, eight days later. Locally, the parotid infection was much improved. The original pelvic infection was thought to be the chief cause of death. Here, a weakness of the seventh nerve was noted previous to operation, which is a rare finding.

Following are the seven cases previously mentioned, in which operation was not advised.

Case 17.—A woman, aged 88, who entered Barnes Hopital, October 3, and who was unable to answer questions in connection with her condition, had a gangrene of the left foot of six months' duration, due to endarteritis obliterans. She had chronic nephritis and general arteriosclerosis. September 23, a swelling was said to have appeared over the left side of the face. On entrance to the hospital, the left parotid region was markedly swollen; the skin was tender;

the left eye was closed from edema, and the mouth was so dirty that inspection was difficult. No fluctuation was found, and operation was not advised. The pulse ranged from 110 to 130; the temperature from 101 to 102 F. The patient died on the day of admission to the hospital. At postmortem, the parotid contained *Staphylococcus aureus.*

Pathologic examination of the parotid gland revealed numerous small abscesses. There was marked edema.

Case 18.—A woman, aged 21, entered Barnes Hospital after a concentrated solution of potassium hydroxid had entered the bladder accidently. The bladder wall sloughed, and the patient became extremely toxic. Three weeks after entrance, a swelling of the left side of the face appeared. The maximum of swelling was just below the left ear lobe.

When seen twelve hours after onset, the left parotid area was slightly swollen in the upper half. In the lower half and extending back behind and posterior to the lobe of the left ear, the swelling was marked. The area here was bright red. The swelling extended below the angle of the jaw onto the neck about 3 cm. The parotid papilla was a little swollen, and only slightly pink. Cloudy fluid could be squeezed from the duct. The patient was drowsy and looked very ill. The teeth were dry. The pulse was 100, and temperature, 36.8 C. (98.2 F.). The brow was covered with perspiration. A culture of fluid from the parotid showed *Staphylococcus aureus.* November 18, 1922, a blood culture was negative. The nonprotein nitrogen was 63 mm. per hundred cubic centimeters. The patient died about twenty hours later. The pulse rate ran from 100 to 120 just before death. No marked rise in temperature was noted.

Case 19.—A man, aged 40, entered Barnes Hospital, March 1, 1918, with serofibrinous pleurisy of the left side and chronic nephritis. The following day, there was swelling over the left parotid region, which was tender and painful. The temperature was 102 F. in the morning. In the evening, the temperature was 105 F., and the pulse, 140. There was no improvement the following day, and the day thereafter he died. Operation was not advised, because the patient seemed nearly moribund.

Case 20.—A man, aged 45, entered Barnes Hospital, March 6, 1915, with hypertension (blood pressure, systolic 255, diastolic, 225) uremia, chronic nephritis and albuminuric retinitis. April 3, swelling developed over the left parotid, with redness and tenderness. Pus exuded from the left parotid duct; the right was normal. The temperature was 100 F. The following day, the swelling increased, extending back over the mastoid process. The jaws opened with difficulty. Before death, the patient became delirious and had several general convulsions. Operation was not advised because the patient seemed beyond help. The temperature was 103 F., the pulse, from 130 to 140. The patient died on the second day following the development of the parotid infection.

Case 21.—A woman, aged 40, seen at Washington University Hospital, had, following a gynecologic operation, developed a typical acute parotitis, which resulted in death within forty-eight hours. The patient was nearly moribund when seen. No operation was advised.

Case 22.—A woman, aged 77, who entered Barnes Hospital, March 8, 1922, had undergone a pelvic operation, March 10. She reacted poorly after the operation, and her condition became serious. April 2, it was noted that both parotid regions were "full." The pulse was 120, the temperature, 99.5 F. She had been delirious for several days previous to the onset of the parotid infection. Death ensued forty-eight hours after onset. Symptoms of pneumonia developed toward the end.

Case 23.—A woman, aged 30, entered Barnes Hospital, Dec. 26, 1920, because of a severe toxemia of pregnancy, with intense vomiting. A therapeutic abortion was performed, Jan. 6, 1921. A uterine infection followed. The throat became red and sore, January 19. Two days later, the patient complained of pain in the region of the right parotid. A slight swelling was noted in the parotid region, but this did not increase noticeably during the remaining eight days of life. She was delirious and very ill throughout this period. A positive *Streptococcus hemolyticus* blood culture was obtained, January 23 and 24. January 23, the white blood count was 7,950, the pulse ran about 130 during the infection, and temperature, from 103 to 104. No necropsy was performed.

Although there is no definite evidence, clinically, one would not suspect this parotitis of being caused by the same organism as that found in the blood. The local reaction was not severe at any time. The preceding sore throat may possibly have contributed to the parotitis.

The following cases represent an acute type of duct ascending infection which is less common. The onset is less acute and the course mild in comparison with the typical severe form. In these cases, the parotid symptoms disappeared. Hot packs or ice bags gave relief.

Case 24.—A man, aged 30, seen at Hotel Statler, with double pneumonia, which began March 6, 1922, March 8, developed a moderate swelling over the parotid regions. Pain and tenderness were slight. The temperature varied from 100 to 102 F., the pulse from 80 to 90. The parotid papillae were pink, and cloudy mucus could be expressed from both ducts within the mouth. The swelling on the right side began to subside the day following onset, and the left gland, the next day. For two days the mucopurulent discharge into the mouth continued. Convalescence from the parotitis was clinically complete at the end of five days.

Case 25.—A colored man, aged 44, entered Barnes Hospital, Feb. 8, 1920, with bronchopneumonia. While convalescing, six days after entrance, he developed a swelling of the left parotid region, with moderate pain and tenderness, localized in that region. On examination of the duct, cloudy mucus was expressed, and there was a red dot with a halo surrounding it within the mouth, representing the papilla. The swelling was stationary for three days, and then began to subside. A week after onset, it had disappeared. During the acute stage of the infection, the temperature was never over 100.5 F., and the pulse was never above 84.

Case 26.—A child, aged 18 months, entered Children's Hospital, April 7, 1920, with a history of convulsions. The temperature was 104 F. The right parotid was swollen to the size of an egg, and the left parotid was slightly enlarged. The skin above was slightly red and shiny. The white blood count was 20,300. No fluctuation was noted. No note was made in regard to the papilla. The pediatrician said the condition was not mumps. After two days, the swelling and fever began to subside. The patient left the hospital in one week, with the parotid swelling nearly gone.

Case 27.—A woman, aged 28, who entered the Deaconess Hospital, Feb. 24, 1923, had been operated on by Dr. M. M. Hamlin six days previously for an old salpingitis. There was no postoperative reaction for three days immediately following. Three days previous to consultation, swelling appeared under the lobe of the left ear, with pain localized in the parotid region. The temperature

was 102 F. The swelling increased until it covered the whole side of the face. However, the swelling was said to be more marked the day previous than the day of consultation; the temperature was a little less, 100.8 F., and the pulse was 100. The patient was nervous and pale. The gland was tender, but there was no fluctuation. Inside of the mouth was an enlarged papilla, with a drop of pus exuding. That morning, Dr. Hamlin made a small incision in front of the lobe of the ear, but obtained no pus, and none drained from the incision later. Without drainage, the swelling subsided within ten days. The pain was controlled with one-eighth grain of morphin, given twice in twenty-four hours.

Case 28.—A woman, aged 24, admitted to Barnes Hospital, July 15, 1912, with a history of having had pain in the lip and cheek one week before, which disappeared in one day, was well until twenty-four hours before admission, when a swelling appeared in the right cheek below and in front of the ear. Eight hours previously, she thought she had fever. There was moderate swelling of the parotid. The swelling and discomfort subsided in seven days. The temperature was 103 F. on admission; the pulse, 120. Temperature, pulse, tenderness and pain gradually subsided.

Case 29.—A child, aged 4 years, entered the Children's Hospital, with pneumonia and a temperature of 103 F., Jan. 8, 1920. One week later, swelling of the right side of the face developed anterior to the ear, extending down and back below the ear. The mass was firm, tense and not very painful. The throat was red and sore. The following day signs of empyema were noted. The chest was aspirated and pus found. The parotid swelling remained stationary for two days. The duct was red at the papilla. In four days, the swelling had disappeared. Six days after onset of the parotid infection, a rib resection was performed. At this time, a blood culture showed *Streptococcus hemolyticus*. Seven days after the rib resection, the child died.

It will be noted here that the parotitis had subsided before the rib resection, and it seems most probable that the parotid infection had little to do with the child's death.

Included in the group of acute and subacute inflammations in which there was recovery without surgery, there is a type of case whose course is characterized by exacerbations of slight pain and moderate swelling, with, or sometimes without, the general symptoms of a mild infection. The question arises as to whether these do not belong to the second group, the obstructive parotitis. There were typical obstructive symptoms, but no previous attacks. Clinically, the differentiation is sometimes difficult. The two cases which follow are of this type.

Case 30.—A woman, aged 72, admitted to St. Luke's Hospital, with a complaint of lymphangitis of the leg, developing from an ulcer on the right ankle, also had a general carcinomatosis with ascites. March 6, there was pain with moderate swelling and tenderness in the right parotid region. The temperature was 99.8 F., the pulse, 80. After twelve hours, the swelling and tenderness of the parotid region began to subside and in three days it had disappeared. In another two days, the pain, tenderness and swelling reappeared, and again it subsided. Finally, a third exacerbation occurred. After thirty days, the swelling completely subsided, and there was no further trouble.

Case 31.—A woman, aged 60, following a cholecystectomy, developed swelling and tenderness of the left parotid, which began to subside after twenty-four hours. The temperature was 102 F. March 9, swelling and tenderness appeared in the right parotid. The temperature was 102.5 F. This also began to subside in twenty-four hours. Swelling and discomfort reappeared several times during a period of thirty days. Both finally subsided completely.

There is evidence to warrant the belief that a blood-borne infection is an occasional cause of acute suppurative parotitis, but we have no absolute proof of such an etiology in any of our cases. This is probably due to the fact that blood cultures were not taken in certain cases, or were not taken often enough, or that the gland was not opened and cultured coincidently with the blood culture, so that the more convincing laboratory proof was not obtained. Evidence of duct infection, such

Fig. 3 (Case 32).—Appearance of wound with packing in place. (From Blair's Surgery and Diseases of the Mouth and Jaws.)

as reddening of the papilla and exudation of purulent saliva, was sought and not found in the three cases listed etiologically as possibly of this type. Clinically, a streptococcus septicemia was present in one, and in another a streptococcus was found in the blood.

Case 32.—A woman, aged 52 entered St. Anthony's Hospital, Feb. 13, 1915, with a clinical diagnosis of carcinoma of the stomach with peritonitis, from the history and physical findings. February 16, she developed marked swelling in both parotid regions, with severe pain and exquisite tenderness. No fluctuation was present. The openings of Stenson's ducts were not red, and no pus was expressed from the ducts. The process progressed, and two days later, a bilateral typical incision and drainage of the parotid glands was made. The gland showed marked edema and some necrotic areas. No frank pus was noted. At the time of operation, the temperature was 99.5 F., the pulse, 110. Later,

the temperature went to 102.5 F., the pulse to 140. She developed a purpura of the trunk and the extremities, with edema of the extremities, and murmurs in the heart considered characteristic of an acute endocarditis. She died, February 24. Clinically, one would say this patient had a septicemia. A blood culture was not made. The fact that the gross evidence of the blood infection developed after the parotid inflammation raised the question as to whether there was a septicemia previous to the parotid infection or merely afterward.

Case 33.—A woman, aged 54, entered Barnes Hospital, Dec. 29, 1920, with carcinoma of the breast, for which operation was performed, Jan. 4, 1921. January 11, the temperature was high, the pulse rose to from 140 to 160, and the condition became critical, bronchopneumonia developing. At necropsy, a lung abscess and an osteomyelitis of one rib were also found. A hemolytic streptococcus septicemia was shown by blood culture. During the last thirty-six hours of life, there was moderate swelling of the left parotid gland, with moderate tenderness and no evidence of fluctuation. No pus was noted from the duct within the mouth. During the few hours before death, the condition progressed slowly. As the general condition was practically hopeless, operation was not advised.

Case 34.—A man, aged 39, seen at the Missouri Baptist Sanitarium, while convalescing from a fractured rib sustained in an automobile accident, developed pneumonia. A blood culture, April 1, was negative. April 4, the left parotid region began to swell and to be painful. The swelling extended rapidly, with a high abrupt edge, over the side of the face, head, neck and chest. There was also a marked edema of the pharynx. The swelling increased during the next twenty hours. Respiration became embarrassed. The temperature rose to 103, the pulse to 120. The white blood count was 18,000. No pus could be expressed from the duct within the mouth, and the papilla was not reddened. Forty-eight hours after onset of the infection, the left parotid was drained in the usual manner.

A swollen edematous gland was found, with necrotic areas and many abscesses here and there. At the time of operation, the patient was in a critical condition. He died in twenty-four hours. Necropsy revealed bronchopneumonia and a hypernephroma, which was undiagnosed before death. Culture of the parotid at the time of operation showed a long chain streptococcus. This case, clinically, conforms to a typical picture of a blood-borne infection. However, the blood culture taken three days before onset of the acute parotid inflammation was negative. No evidence of a duct infection was found.

Analogy would suggest the possibility of infection being borne by the lymphatic channels. The following case is the only instance we have to present of the likelihood of this mode of transmission. However, in spite of negative blood cultures, a hematogenous origin cannot be excluded.

Case 35.—A woman, aged 70, entered Barnes Hospital, Jan. 8, 1922, with a centrally placed lacerated wound of the forehead, caused by falling on a broken dish. The wound was excised and sutured, but it became infected and broke down. A culture of the wound showed a streptococcus. February 12, the patient developed a temperature of 105 F. and had a chill. Examination revealed a bilateral swelling in both parotid regions. The duct papilla of the gland showed no reddening, nor exudation of pus. The pulse was 110; the white blood count, 23,000. The condition progressed locally and generally.

There was no fluctuation. The patient was delirious. Two days after onset, a bilateral incision was made and drainage in the usual manner was carried out. Tense gland capsules were found which, when torn with a hemostat, showed glandular necrosis here and there. No frank pus was noted. A culture showed streptococcus.

Two days after the first parotid incision, the constitutional symptoms returned with all their original severity, including a high grade delirium. Some induration was found about the lower pole of the right parotid. Under gas anesthesia, forceps were forced into the indurated area, and a little pus was liberated. The constitutional symptoms and the delirium promptly subsided. Two days later erysipelas of the face and head developed, from which there was recovery in ten days. Blood cultures taken twice were negative. Most of the parotid swelling subsided within three days of the first operation. The wound granulated and closed quickly.

Here, as will be noted, the location of the original wound is in the lymphatic radius of the parotid lymphatic system.

ACUTE PYOGENIC PAROTITIS

Occurrence.—As previously mentioned, acute parotitis usually follows as a complication of a postoperative state, of an infected wound or of an acute infectious disease, or as a part of a terminal condition. In certain instances, it seemed to follow an acute form of pharyngitis. Occurrence is most frequent in adults, especially after the third decade of life, but may occur in adolescence, childhood or infancy. Of our cases, twenty-six of the thirty-five occurred in adults, and seventeen of the twenty-six adult cases occurred after the third decade. Cases in females were slightly in the majority (twenty-four of the thirty-five cases). In this climate, there is quite a predominence of cases during and between the months of November and April, when respiratory infections are most common. Thirty of the thirty-five cases occurred during this period. Two of the cases which developed during the other six months of the year accompanied terminal states. One followed infected wounds, and one occurred postoperatively. The fifth case had no definite predisposing factor in the history.

Seasonal Incidence.—This is shown in the accompanying table.

Seasonal Incidence of Parotitis

Month	No. of Cases	Month	No. of Cases
January	7	July	1
February	8	August	0
March	9	September	1
April	3	October	2
May	1	November	2
June	0	December	1

Complication.—Pneumonia was present in nearly one third of the cases, eleven out of the thirty-five; and in four others, there was a definite history of a preceding "cold" or sore throat. About one fifth of the cases were bilateral (seven of thirty-five).

Bacteriology.—The most common infecting organism, in our cases at least, was a staphylococcus. Of eighteen cases which came to operation, five have no report of a culture and nine showed a staphylococcus in pure culture. In four of the nine cases, the organism was *Staphylococcus aureus.* The five others have no designation of the type of staphylococcus. One case showed *Pneumococcus lanceolatus,* and two cases showed a streptococcus in pure culture, type not designated. One case in which operation was not performed but in which a postmortem culture of the parotid pus was made, a staphylococcus was found. In two cases in which operation was not performed, the pus from the parotid duct showed a staphylococcus in pure culture in one case, and a staphylococcus and green streptococcus in the other.

The two cases showing a streptococcus were of an extremely virulent type. One patient died, and one recovered following incision and drainage.

Clinical Course.—The symptoms may be mild, with little fever, with mere discomfort or moderate pain and slight swelling limited to the parotid region; or they may be extremely severe from the first, with all the clinical symptoms and laboratory findings of a severe infection, including great pain in the gland, chills, high fever, and marked swelling, first in the gland, and later a rapidly spreading cellulitis of the neck, head and face.

As the infection spreads, edema sometimes closes the eye (Cases 1, 3, 8, 12, 17), and may involve the neck down to the clavicle (Cases 1, 16) or even the breast (Case 3), or may extend backward over the mastoid process (Cases 3, 11, 14, 20). In one case (Case 34), the swelling extended into the pharynx, and for a time threatened the air way; while in another case (Case 6), the occurrence of death during a period of acute swelling suggested the possibility of edema of the glottis. The duct in the mouth, in the majority of cases, where record was made, showed signs of an inflammatory reaction, as manifested by a pink or red swollen papilla with, when most pronounced, a partially everted duct mucosa. Usually, saliva flowing from the duct will vary from the faintest cloudiness to frank pus. In certain cases, which were of the severer type and were suspected clinically of being blood borne, but in which laboratory evidence was not complete enough to be convincing, no evidence of duct infection or infected saliva was found.

Twenty-four hours preceding the onset of the evident parotid infection, one patient (Case 2) complained of pain in the ear, and another (Case 11) complained of pain in the back of the neck, forty-eight hours before the evident parotitis. After the onset, only one patient (Case 11) complained of pain, during paroxysms. Several patients became delirious (Cases 4, 15, 20, 22, 23, 35). Four patients had convulsions, but three of these had uremia, so that some doubt might arise as to the origin of the convulsions. In the fourth case (Case 26), there

was no such conflicting data, as the child recovered promptly on the subsidence of the parotid inflammation. One patient (Case 17) was admitted in coma, but she had gangrene of the foot and leg and chronic nephritis. Several patients (Cases 1, 12, 20) could not open the mouth because of spasm of the muscles of mastication. Only one patient (Case 16) showed a seventh nerve weakness. In one case (Case 11) otitis media was at first suspected, in conjunction with a parotid infection, until it was found that the ear drum was normal and that there was a sinus from a parotid abscess discharging pus into the external auditory canal. When a parotitis develops as a part of a terminal process, death very often occurs in the stage of simple swelling (Cases 18, 19, 21, 22, 23, 33).

Diagnosis.—The diagnostic features are the preceding injury, operation, disease or nasopharyngeal infection; the discomfort or pain in the cheek; the swelling and tenderness corresponding to the location of the gland and, in the majority of cases, the constitutional and laboratory signs of a pyogenic infection. The discomfort may be slight, but is seldom entirely absent. In severe forms, the pain becomes more or less unbearable. The swelling may be very slight, possibly not involving the whole gland, and being confined under the tense parotid sheath and somewhat difficult to make out. It is sometimes manifested as a sense of increased resistance to the palpating finger rather than an evident swelling. In some of the more severe cases, the swelling of the gland itself may be masked by a severe and rapidly spreading edema of the temple, cheek and neck.

In the latter cases, if the patient is conscious, the location of the tenderness is a particularly valuable diagnostic feature and may help to differentiate a parotid infection from an inflammation situated under the temporal fascia, but not from a subparotid focus. We have had two cases in which the true location of a subparotid infection was determined by a transparotid operation. In seeking the parotid swelling and tenderness, it is to be borne in mind that the gland runs forward below the lower border of the zygoma and extends backward behind the ramus of the jaw below the lobe of the ear. On looking into the mouth, if it can be opened, and examining the exit for the parotid excretory duct opposite the second molar tooth, usually one saw a minute red spot representing the meatus, and, on stripping the duct, in the majority of cases faintly cloudy or more frankly purulent saliva was expressed. There may be almost any grade of constitutional symptoms, depending on the severity of the infection and the reactionary powers. The temperature may be as high as from 103 to 105 F., with a corresponding pulse rate of from 110 to 130. Among the types of low virulence, some had no elevation of pulse rate and a temperature of not over 99 or 99.5 F. In certain cases, in which patients already

debilitated by a terminal illness developed parotitis in the last twenty-four to forty-eight hours of life, there was little local or general reaction. The leukocyte count varied from 9,000 to 10,000, to as high as 23,000 to 25,000.

We have had two cases of subtemporal abscess of dental origin that presented some diagnostic difficulty. In both, the typical parotid approach was made, and the abscess was drained through the parotid gland. These two are not listed as cases of infection of the parotid.

A man, aged 25, who entered Barnes Hospital, May 18, had had a tooth pulled May 9. Infection about the tooth was noted, May 16. The next day, the right cheek began to swell. The swelling continued. The pulse was 100. On examination, the right cheek from the angle of the jaw to above the right ear was markedly swollen, red and tender. Induration seemed more marked over the right parotid than elsewhere. No fluctuation was noted. The white blood count was 18,000; pulse, 110, and temperature, 102 F. A transparotid incision was made, as pus was suspected near the parotid. Pus was found beneath the temporal muscle.

A woman, aged 30, following extraction of the left molar tooth in an acute stage of a spreading infection, presented symptoms that seemed to localize in the parotid gland of the left side, but there was no evidence of involvement of the duct. On exploring the parotid gland in the usual manner, it was found that there was an extension downward of a temporal abscess to the parotid gland, but the gland itself was not involved.

Prognosis.—If we include Cases 30 and 31, we have here reported thirty-five cases of acute parotitis. The death rate for the whole series was 42.8 per cent. (fifteen cases).

Of these thirty-five cases, eight (Cases 24 to 31) were so mild as to require no treatment. Eight cases (Cases 17-23, 33) were terminal involvements for which no special parotid treatment was given. One patient (Case 6) who died of undetermined cause possibly might have been saved by timely operation. Of the sixteen patients operated on, five died before the parotid wound healed. Three patients (Cases 14, 15, 34) were fatally ill at the time the parotitis developed, and this condition was not considered the cause of death. Eleven of the fifteen patients operated on survived. Of these, three (Cases 3, 4, 35), it is believed, were probably saved by operation, while in the other eight, judging by Cases 10 and 12, the operation at least materially sped the convalescence. Naturally, cases in which the parotid infection was but one evidence of a terminal condition in an essentially fatal malady were not favorably influenced by any form of treatment.

Treatment.—The evidently mild cases (Cases 24, 25, 26, 28) were given no special treatment other than possibly the application of heat or cold; while in the more severe (Cases 1, 2, 3, 4, 35, etc.), when not unmistakably a part of a terminal condition, the patients were operated on as soon as it appeared probable that the gland infection would not subside spontaneously. We have followed the rule of opening the

gland in all doubtful cases not later than within the second twenty-four hours, and believe that it is a more serious error to delay too long than to incise the gland unnecessarily. With regard to these doubtful cases, our own experience has caused us to swing gradually toward the rules governing appendicitis: operate and observe afterward. The local changes in the gland that operation seeks to prevent are gangrene and suppuration. The latter is often of a diffused miliary type. The operation therefore consists of exposing the gland by splitting the capsule and also puncturing the parenchyma for drainage.

Noticeable scarring is prevented by placing the greater part of the skin incision in the angle at the junction of the cheek with the ear. Free access is obtained by exposing the whole gland, and the motor facial nerve is safeguarded by puncturing the gland with blunt forceps. The incision starts 2 cm. in front of the ear at the lower border of the zygoma, running back to the ear and then downward to behind and below the angle of the jaw. This incision, which is made with one sweep of the knife, goes to, or just through, the capsule of the gland. Along this line, the facial nerve lies quite deep. A flap of skin and superficial fascia is stripped forward with sharp rake retractors; the capsule is stripped off the whole gland, and its parenchyma is punctured and torn in numerous places. It is important that the whole gland be exposed and explored. Usually, the parts behind the lobe of the ear and along the origin of Stenson's duct are the ones missed. We have had to reoperate in certain cases on this account. The wound is packed wide open with gauze and bandaged with some pressure. Spontaneous closure of the wound with a very slight scar follows, with the recovery of the patient.

Usually relief of all symptoms is almost immediate, but repuncture of the gland had been necessary in some cases (Cases 4, 35) when the original exposure was not complete.

In sixteen of our thirty-five cases, radical incision and drainage was necessary. Nine of the cases were considered hopeless when seen, and operation was not advised. In seven cases the swelling subsided without operation.

Direct incision of the gland may be followed by a salivary fistula. We had three cases in which this had occurred at a previous operation. In one of these, the fistula was bilateral.

Two cases follow. The third case is Case 50.

Case 36.—A boy, aged 12 months, congenitally syphilitic, seen at the Children's Hospital, when 4 months of age, had had a parotid abscess opened and drained by direct incision. Since then, saliva has discharged from a sinus beneath and back of the lobe of the right ear. When food was taken, saliva flowed more freely. Methylene blue was injected into the sinus tract, which, with the tributary part of the gland, was excised, exposing the trunk of the seventh nerve. Uneventful recovery followed.

Case 37.—A boy, aged 18 years, seen at Barnes Hospital, at 1 year of age had had a double parotid abscess, one on each side, incised and drained. A salivary fistula of each gland had persisted ever since. The location of the fistulas, the treatment and the results were the same as in Case 36.

PAROTITIS ASSOCIATED WITH OBSTRUCTION

In each of the following cases, there was something which suggested that the glandular trouble was associated with, or dependent on, a partial obstruction of the duct, and that when suppuration occurred

Fig. 4 (Case 38).—Arrow points to shadows, three in number, which proved to be dense hard particles, all included in one calculus the size of a navy bean.

it was secondary to this obstruction. Stones were demonstrated in a few of these cases. Complete obstruction will usually be followed by complete atrophy of the gland. We have had many illustrations of this following cancer operations. (Tait [1] discusses this pathologic change.)

Case 38.—A man, aged 39, who entered Mullanphy Hospital, July 24, 1922, about 5 years before first noted a swelling in the left parotid region, which

1. Tait: Fibrous Atrophy of Parotid Gland, Surg., Gynec. & Obst. **14**:419, 1919.

was reduced by a sulpho-ichthyolate preparation and hot applications. Two or three times a year since then, there has been a swelling in this region, which usually came on during meals, but sometimes between meals. The swelling could be diminished by massage. The swelling of the gland had appeared more frequently during the last six months. The present swelling began five days previously. He noted pus in his mouth. The swelling and pain increased for three days. The pain practically subsided for one night, and then returned with renewed vigor for the following forty-eight hours.

Examination revealed a large swelling over the left parotid region. The skin was brownish from sulpho-ichthyolate applications. There was a suggestion of fluctuation in the center. The whole gland region was very tender and warm. Thick pus exuded from the parotid duct opening. The patient was comfortable at the time of examination. The temperature was 102 F., the pulse, 100.

Roentgenograms showed three small shadows in the parotid region, which were taken to be stones. During the following day, the pain increased. When the gland was explored by the usual method (previously described), an abscess cavity about 2 cm. in diameter was found, containing thick pus. No stone was found. The wound was packed wide open.

About five days later, when the packing was removed and a curet passed into the cavity, a stone the size of navy bean, which had three small dense areas in it, was removed. The one stone was thought to account for the three shadows seen in the roentgenogram. Each was about 3 mm. in size, and they were close together. Convalescence was rapid.

This represents a typical case in which a stone contributed to the obstruction. The history is rather typical; that is, the trouble began five years previously with exacerbations of swelling and pain occurring at varying intervals, and most often the swelling occurred during meals. The lesion gradually became more marked, and finally terminated in abscess.

Case 39.—A woman, aged 31, seen Jan. 27, 1916, eight years previously had had a swelling below the lobe of the left ear. This recurred several times. Five years previously, the swelling appeared in front of the ear. The swelling was increased immediately when acids were taken into the mouth, and the discomfort increased to pain for a period of two hours. (After the removal of a crowned second bicuspid, the swelling in front of the ear disappeared for three months.) The swelling and tenderness had been present in the parotid and also in the submaxillary region for a few months before admission to hospital. Roentgenograms showed a shadow in the parotid gland region.

The patient was operated on, February 1. An incision 1½ inches long was made in the crease just in front of the ear. The tissues were dissected from the parotid gland forward to the supposed location of the stone. The gland was incised in the direction of the duct, and a stone 3 mm. in diameter was removed. A probe was passed into the duct which entered well into the cheek. The pain was not relieved, and February 10, the old wound was reopened and three small stones were found at the depth of 2 cm. from the point where the first stone was removed.

This case is similar to the one preceding, except that the patient was operated on at a time when the inflammatory condition was more or less quiescent. The diagnosis was confirmed by roentgenograms before operation.

Case 40.—A man, aged 36, seen May 18, 1919, had noticed a feeling of stiffness in the right jaw, five weeks previously, after his noon meal. The jaw gradually became swollen, and he painted it with iodin. The patient remembered that, five years previously while eating a teal duck, he had pain in the right cheek and a lump appeared the size of an egg in front of the ear. On examination, swelling was found over the parotid region and extending forward on the cheek 2 inches (5 cm.) in diameter. Fluctuation was present. A mucocheesy discharge oozed from the parotid duct within the mouth. A roentgenogram showed, on three different plates, a shadow of a small object that might be in the duct. Thick mucopurulent material was aspirated from the cheek. Operation was advised, but the patient did not return.

Case 41.—A woman, aged 46, seen Dec. 6, 1919, gave a history of stiffness or soreness in the right face and jaw region when she was eating. In the evening when she was tired, it was more noticeable, but she had no real pain. There was occasionally a swelling in front of and below the right ear. On examination, the temperature and pulse rate were normal. A very slight thickening of the right parotid region was noted. It was not tender. A probe was passed into the parotid duct, and a roentgenogram taken, which showed a small stone at the end of the probe. December 11, operation was performed. The opening of the parotid duct was caught with towel clips. A "U" shaped incision was made conversely forward in front of the duct. Through this incision, a cleavage plane was made just superficial to the duct, through which it could be followed backward to the masseter muscle. The facial artery was retracted outward from the duct. The stone was not felt. An incision was made transversely over the duct on the cheek, 1¾ inches (4.3 cm.) long, corresponding with the anterior border of the masseter muscle. The duct was then identified by intermittent traction on the towel clip. The stone was found over the edge of the border of the masseter muscle and removed by an incision parallel with the axis of the duct. Three months later, the patient still complained of stiffness and swelling in the right side of the face. The duct was probed. No obstruction was found, and it drained freely. The trouble continued for a year, when the patient still had a swollen lower half of the parotid gland. She was advised to have the lower part of the gland removed.

The following case of submaxillary duct blockage is quoted to illustrate a condition which we believe possible in the parotid as well as in the submaxillary gland, although we have no case history of such a condition. The case which follows (Case 43) seems closely identified with it in type. We feel that the relationship, anatomically and functionally, of the submaxillary gland to the parotid gland is near enough possibly to allow the same condition to be present.

Case 42.—A man, aged 55, of careful habits, without previous history of any kind of trouble in the salivary glands or ducts, one morning, on first taking food, had an obstruction of both Wharton's ducts, which persisted more or less all day. When a probe was passed into each duct, there followed a free flow of saliva that showed no visible pus or mucus. The symptoms did not recur. The possible etiologic factor was a dinner the previous evening in which both food and drinks were unusually rich and plentiful. Here the swelling of the mucosa or a plug of mucus was thought the most likely cause of the obstruction.

Case 43.—A man, aged 40, seen Oct. 3, 1922, one and a half years previously, had a swelling of the left parotid region that developed during the night. No pain was present, only a slight discomfort. The duct was probed the following morning. The swelling had appeared about every three months. No relationship to meals was noted. Three times previously, the duct had been probed with relief of swelling. The right submaxillary region became swollen for the first time without pain the night before he was seen. Only a slight discomfort was noted. On examination, the right submaxillary gland was slightly distended. A slight amount of clear saliva ran from the papilla. A probe was passed into the duct, and on removal, a gush of saliva followed. No thickening of the duct was felt. A probe was passed into the left parotid duct. The papilla seemed small. Clear saliva flowed before passage of the probe, and after passage, there was evidently no increase of flow.

The nine cases which follow represent more chronic types in which the presenting symptom is lack of free drainage of saliva and in which, from the history, it appears to have recurred several times. In the first three cases, the duct was split at operation, which was performed with the idea of widening the meatal constriction to aid drainage.

Case 44.—A woman, aged 54, first seen Jan. 18, 1922, gave a history of swelling of both parotid glands, over a period of three or four years, and occurring at varying intervals. The patient thought a cold might have brought it on. On the third day following a tonsillectomy, in December, 1921, a large swelling appeared on the left side, which did not subside for ten or twelve days. According to the patient, massage sometimes expressed saliva and sometimes "phlegm." There was no connection between swelling or pain and the taking of food. On examination, no induration of the gland was felt. A probe was passed on both sides, after which a small amount of mucus was expressed from the left duct, which was affected more.

The opening of the left duct was incised and the mucosa sutured open, as described later; and the right duct was dilated with a probe. Two days later, the patient had a slight swelling of the right gland. At the present date, one year later, she has had no recurrence of symptoms.

Case 45.—A boy, aged 6, seen March 15, 1922, for two years had had a lump in the lower part of the left parotid gland region that fluctuated in size. It disappeared for a week or two, and then returned. It was never red. When the parotid region was swollen, eating caused pain. When the cheek was massaged while the lump was present, pus was expressed into the mouth, and the patient became more comfortable. When the lump was largest, he became pale, and had headaches and slight fever. Examination revealed a mass in the left parotid region elevated 1 cm. above the normal contour of the parotid gland area. Massage caused the lump to become smaller and softer. Cloudy saliva flowed from the duct. Roentgenograms were negative. The duct opening was split, in a manner described later, and gentle massage was recommended. When seen last, about one month later, he still had slight swelling of the gland, but it was considerably less. A probe was passed, and the fulness was found to have disappeared. No further trouble has been reported up to the present time, ten months later.

Case 46.—A woman, aged 42, seen Aug. 15, 1921, in January, 1918, had had an upper right tooth extracted, after which pain and swelling appeared in the

right cheek anterior to the ear. In August, 1918, a piece of root was removed. She again had pain and swelling in the right side of the face, after which there was a discharge of clear fluid into the mouth, and the swelling disappeared. When the face was swollen, eating increased the pain. On examination, excessive secretion was found, flowing from the parotid duct on the right, and distending the duct slightly. The duct was split for one-quarter inch, and the lining mucous membrane was sutured to the mucus membrane of the cheek to give free drainage. The patient was seen one year later, and had had no further trouble.

Case 47.—A woman, aged 30, seen Nov. 7, 1916, one and a half years previously had received throat treatment. The throat was sprayed, and the same day she noted a swelling in front of the ear. This swelling appeared and then slowly disappeared several times. Previous to November, the swelling had not appeared since June. Eating did not seem to affect the swelling. At times, there was a discharge of stringy mucus in the mouth. The patient thought that a cold seemed to bring on the swelling. Usually there was a slight amount of swelling for about two weeks after the acute swelling had subsided. There was a discharge of thick mucus and pus. A probe was passed and the duct dilated. The patient was seen again, March 24, 1917; she had had no further trouble. She promised to return again if there was any trouble.

This case represents the only one with a recurrent swelling in which dilation with a probe seemed to give relief.

Case 48.—A woman, aged 73 years, who entered Barnes Hospital, Jan. 7, 1921, since June, 1920, about once a month on an average, had had a swelling of both parotid regions. She noticed pus on her false teeth, and thought she had some fever during the attacks. On eating, the discomfort was exaggerated. Cloudy mucus was expressed from both ducts. The patient was advised to have a probe passed at regular intervals when it was found that the roentgenograms were negative. She was not seen again.

Case 49.—A man, aged 23, seen April 16, 1919, had a chronic infection of the nasopharynx and pansinusitis. He gave a history of cloudy discharge from the salivary ducts for two years, without pain in the region of the salivary glands. The parotid ducts showed no secretion. A stone 1 mm. in diameter was removed from the orifice of the left submaxillary duct. July 16, a slight brownish mucoid discharge was obtained from both parotid ducts. August 6, an attempt was made to probe both parotid ducts. On the left, the probe entered to a depth of 1.5 centimeters. The right duct was obstructed. There was less discharge than usual. February 22, 1921, the patient still had a purulent discharge from the parotid ducts. From the right parotid duct, yellow pus in drops was obtained, and from the left, a stringy mucus. The submaxillary ducts secreted clear saliva.

The three cases following present a type of chronic obstruction which ended in abscess formation. The fourth may, or may not, have belonged to this class. Whether or not such an abscess could be prevented by proper duct treatment if seen earlier, is still an open question.

Case 50.—A woman, aged 28, entered Barnes Hospital, April 10, 1922, with a small abscess in the lower posterior part of the right parotid region, which was drained by a small incision. The history was as follows: Right parotid:

Ten years ago, when the patient was pregnant, the right side of the face became swollen without apparent reason. The swelling disappeared in three days. For the next six months, a slight swelling of the gland persisted. Then an abscess developed, which was lanced. The patient noted no further trouble until she was admitted to the hospital. In the left parotid, the first swelling was noted twelve years previously and was lanced by a physician. A parotid fistula of the left side resulted which had secreted saliva up to the time she was seen.

The patient had never noticed that either side became painful or more swollen on eating. Roentgenograms were negative for stones. Ten or twelve days after the lancing of a right superficial abscess of the right side, for which she entered the hospital, both parotid ducts were probed, and the openings of the ducts split. A flareup of the infection of the right parotid resulted, and again a superficial abscess formed and was opened. The salivary fistula on the left closed and remained so for two weeks after the duct-splitting operation. The ducts were dilated with a probe several times. No further trouble occurred until July 7, 1922, when another abscess developed on the right side in the same place as the previous abscess. This abscess was again drained.

During the six months from February to July, 1922, cloudy saliva was usually present, flowing from each duct. Each gland region was slightly indurated, the right side slightly more than the left. Finally, it seemed that subsidence of the chronic glandular and duct infection was rather improbable, and added to this was the fact that the fistula still remained patent on the left side, though the salivary flow was considerably less. The advisability of resecting a part of each parotid gland was discussed in the patient's hearing. The idea frightened her, and she was not seen until seven months later (January, 1923), when she entered with complete relief from all symptoms. The salivary fistula, after twelve years of discharge, had closed spontaneously two months previously. Clear saliva flowed from both ducts. The glands were still slightly indurated, but much smaller and not tender. She stated that, after leaving the hospital, she had applied an ointment to each parotid region and had then gently massaged each gland until the fistula closed, after which she pronounced herself cured, and ceased all treatment and experimentation with physicians.

Probably the patient's own treatment at this time was as good as any that could have been given. The relief of a certain amount of the obstruction by operative methods, followed by gentle massage, maintained drainage and probably brought about the present favorable outcome. An exacerbation of the infection or a reinfection might occur again. This case, of course, will have to be watched a few years longer to determine the final outcome.

Case 51.—A girl, aged 10, entered the Children's Hospital, May 5, 1913, with a history of swelling in the left parotid region for three or four years previously, which varied in size at times. When she took cold, the size increased. No history of redness or pain was obtained. On examination, a rather marked swelling was found in the left parotid region. No redness or heat was noted. The mass was dome-shaped, about 1 cm. in elevation above the surface and about 3 cm. in diameter. The cervical glands were not enlarged. At exploration, a small abscess cavity was found. An incision was

made parallel with the facial nerve branches. Lower branches of the facial nerve were cut unintentionally. No note was made in regard to duct inflammation, as its significance was not appreciated at this time.

CASE 52.—A man, aged 32, who entered Barnes Hospital in November, 1911, five weeks previously had had pain in the right tonsillar region. Soon afterward, the right side of the face began to swell. He went to a physician, who gave him electrical massage, which considerably reduced the swelling within a few hours. The swelling recurred, and again electrical treatment gave some relief. On entrance, the whole right parotid region was slightly swollen. An inch above and over the ramus of the jaw, there was definite swelling, with slight tenderness and a sense of deep fluctuation. An incision was made parallel to the seventh nerve fibers. Two small abscesses were drained.

This was the type of case which gave a history suggestive of duct obstruction of some kind. However, the obstruction to the outflow was not overcome completely. The electrical massage evidently caused enough purulent saliva to flow out to relieve the patient temporarily, but not enough to allow a subsidence of symptoms. Finally, the blockage terminated in abscess, which after drainage allowed the process to subside.

OCCURRENCE

These cases of chronic obstructive parotitis occurred at any age, usually without a preceding or accompanying severe or debilitating illness. In several (Cases 44, 47, 51), there was a history of a "cold" preceding the exacerbation of swelling. In one (Case 46), the swelling followed first the extraction of a tooth and, six months later, the extraction of its roots. In one case, the symptoms of a tonsillitis preceded the swelling. In another (Case 44), an exacerbation of the infection followed tonsillectomy. It seems likely that the acute infection in the pharynx, mouth or nose had more than a coincidental relation to the exacerbation of swelling. In most cases, such a history was elicited without any particular questioning in that direction.

DIAGNOSIS AND CLINICAL COURSE

Diagnosis depended on a history of obstruction to the outflow of saliva, as manifested by recurrent swelling, usually associated with some slight discomfort or even pain, most pronounced in the majority of cases when food was taken. Added to this, there was usually some inflammatory disturbance in the duct. A roentgenogram revealed a stone in every case in which one was subsequently found; but in one only, a single stone showed on the plate, and a number of smaller ones (sand) that did not show were found at operation. One could imagine, therefore, a case in which the roentgenogram would not aid in the diagnosis. In one case, the stone was located with a probe, and in another it could be felt with the finger under the skin of the cheek.

All cases in which the question of the presence of a stone or stones in the duct or ducts arise should have the advantage of a roentgenogram of the afflicted gland and duct region.

The most typical obstructive symptoms of increased pain and swelling in the gland on eating or drinking were not present in all of these cases. In some, the occurrence of the swelling and subsequent drainage bore no relation to eating or drinking. In others, the obstructive symptoms were very plain; the swelling and discomfort coming on or increasing while the patient was taking or thinking of food, especially such acid substances as pickles or lemons, and gradually subsiding as the saliva flowed past the point of obstruction. Such patients had none of the constitutional evidence of an infection, the discomfort being caused mostly by the back pressure of the saliva. Chronic incomplete obstruction was followed by induration of the gland in several cases, but is seen most commonly with stone in the submaxillary duct.

In the majority of cases that had recurrent swelling, the saliva was not normal at the time of exacerbation of swelling. In some, it contained globs of mucus, and in others, with a franker infection, the saliva was cloudy or semipurulent (Cases 38 [stone], 39 [stone], 45, 47, 48).

The cases with exacerbations of swelling and changes in the saliva gave general symptoms or laboratory findings of a mild infection.

Only five of these developed an interglandular abscess (Cases 38, 40, 50, 51, 52). When an abscess did form, the constitutional symptoms were nearly as severe as in the typical acute pyogenic parotitis (Case 38). In those cases in which there was suppuration, the abscess was single in four, and in one, two foci developed synchronously; but in none was there found either the diffuse gangrene or the miliary abscess observed in certain of the acute cases.

In one case, excessive salivation subsided completely when a free outlet was provided for the saliva. In none of these cases was there the direct menace to life that so frequently came with the acute diffuse infection.

PROGNOSIS

It appears that all of these patients should recover on relief of the duct obstruction and removal of stone or opening of the abscess when present.

TREATMENT

Treatment varied with the type of case. Control of infections of mouth, pharynx and nose might tend to prevent exacerbations of swelling of the duct. Surgical treatment had for its primary object the relief of the obstruction, to free the flow of saliva. When due to stones, their removal was followed by complete recovery, but several months or a year intervened before the complete subsidence of all obstructive

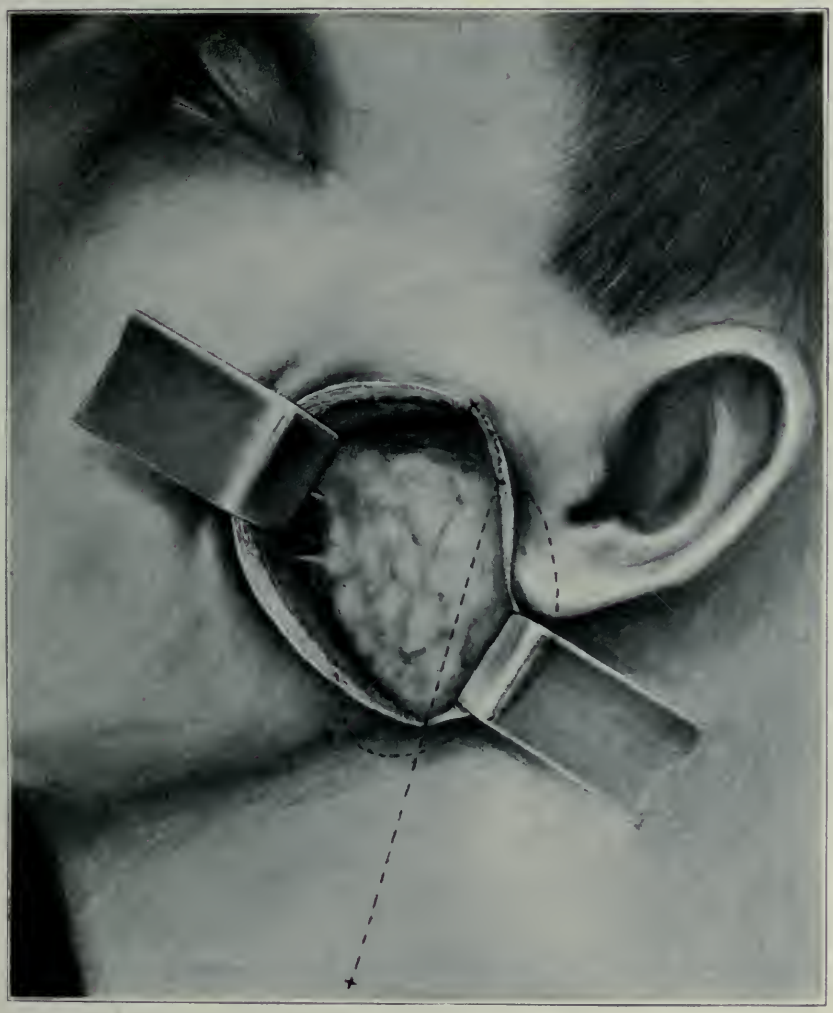

Fig. 5.—Exposure of the parotid gland. The oblique dotted line with its upper forward curve shows the line of incision which may be extended down the neck any distance. The oval dotted line shows the posterior and inferior boundary of the gland.

The two branches of the seventh nerve can be seen leaving the parotid gland at its anterior border; these should not be injured. (From Blair's Surgery and Diseases of the Mouth and Jaws, 1912.)

symptoms and of the induration in the gland. Obstruction due wholly to acute swelling of the mucous lining of the duct or to globs of mucus engaging the meatus might be relieved temporarily at least by the passage of a dilating probe into the duct. We have seen quite severe reactions or extensions of infection follow the use of probes in some cases.

Some strikingly good results have followed slitting of the constricted meatus of the duct in chronic obstructive inflammation of the ducts without stones. This constriction of the outlet of the duct is thought to be a protective mechanism, but when the duct does become infected, it is then liable to obstruct drainage. We are just now

A B

Fig. 6.—*A,* symmetrical action of the facial muscles; *B,* inconspicuous scar one year after exposure of the parotid gland for sepsis. (From Blair's Surgery and Diseases of the Mouth and Jaws, 1912.)

inclined to slit the meatus and suture its epithelial lining to the mucosa of the mouth in every case of chronic infection of the duct or gland in in which a stone cannot be demonstrated, and in which dilation with a probe fails to give permanent relief. The operation is a nice piece of work, and should not take over fifteen or twenty minutes, even for the inexperienced. A probe or probed scissors are passed into the opening and the duct is slit for one fourth inch. Three stitches of fine silk are usually sufficient, one at the apex of the slit and one on each side. In one case, little or no immediate relief was obtained other than a marked lessening of the outflow from the salivary fistula; but

at the present time the patient has been free from symptoms for six months, and the salivary fistula, present for ten or twelve years, has closed completely, and has remained closed for two months. In the three other cases in which this operation was performed on the parotid duct, complete relief of symptoms was more immediate.

In one case, the natural opening of Stenson's duct was situated close to the gingiva of the second upper molar tooth, and this malposition was thought to be the cause of the chronic infection of the duct. Transplantation and splitting of the meatus relieved the symptoms. The case follows:

Case 53.—A man with a history of discharge of pus into the mouth at intervals of two or three months, lasting three or four weeks, during the preceding three years, suffered no discomfort or swelling in the gland region. On examination, the left parotid region was found slightly thickened. In the mouth, the parotid duct was found to open at the neck of the crowned upper second molar on the left. Massage of the gland brought pus and mucus from the duct. The patient was sent to Barnes Hospital, May 25, 1917. The outlet of the duct was slit and transplanted to the normal site, and the duct was dilated with a probe. Five years later, he had had no return of any of the former symptoms.

The four cases which follow could not be classified in any particular group. Each represented a case in which the etiology is more or less obscure to us. No particular treatment was recommended. Their uniqueness seems to warrant their tabulation.

Case 54.—A boy, aged 7, entered the Children's Hospital, Feb. 11, 1920, with a swollen fluctuating mass in front of the left ear. The lymph nodes in the left posterior triangle were enlarged. No pus was noted flowing from the parotid duct. He had a history of a lump anterior to the ear for seven weeks, which had gradually grown larger. The mass was incised and drained, but very little pus was found. The Wassermann reaction was negative. Pirquet's reaction was positive. Culture of pus from the abscess was negative. A tuberculous process was suspected, but was never proved by sections. Three weeks later, a clear discharge resembling saliva from the incision was noted.

The etiologic diagnosis in this case was rather indefinite. The parotid duct was not involved. Evidently, the infective process was in the parotid gland, as after drainage there was a discharge of saliva. Grossly, tuberculosis was suspected, but the only evidence was a positive Pirquet reaction, which was more or less contradicted by the negative complement fixation test for tuberculosis.

Case 55.—A woman, aged 33, seen May 19, 1922, eight months after marriage, began to complain of dryness of the mouth. There was still a little saliva coming from beneath the tongue. The dryness came on gradually during the two previous years. Two years before she was seen, a slight thickening was noted anterior to each ear. No pain or discomfort was noted. Three years previously, the Wassermann reaction was positive. After dryness of the mouth developed, she received antisyphilitic treatment.

On examination, both parotid papillae were found to be absent. From the left submaxillary duct, a fine string of thick mucus was noted. No opening

was observed on the opposite side. Lemon juice caused no flow. Both parotid glands were slightly enlarged. The entire mouth was very dry. The left submaxillary duct was split in the hope of preserving what little function she had on that side. Unless the history of syphilis could be taken as the etiologic factor in producing the inflammatory reaction which caused the parotid gland and one submaxillary gland to cease functioning, the etiology is not evident.

Case 56.—A woman, aged 41, seen April 4, 1922, two months previously had had pain in both cheeks, lasting five weeks, with slight fulness in front of both ears. Four days before she was seen, she noted a pain in the left ear region and a swelling in front of the ear. She could not open her mouth freely. The sight of food or eating did not increase the pain. For two months, the mouth had been very dry. On examination, no saliva was found in the mouth at first. Salt was placed in the mouth and brought saliva from all glands, without pain or swelling of the glands. A diagnosis of insufficient secretion was made. The history suggests an inflammatory basis.

Case 57.—A woman, aged 46, seen May 19, 1922, in May, 1921, had noted more saliva in the mouth than usual. The same condition was noted in February, 1922. For two weeks previously, she had a burning and drawing sensation of the tongue, which was more pronounced between 2 and 3 p. m. No other positive physical findings were noted. On eating candy, there was no excessive flow. The opinion was given that the condition was most likely a functional nervous derangement.

Case 58.—A colored man, aged 53, who entered Barnes Hospital with aortic insufficiency, had marked fulness over both parotid regions. No history of a swelling or anything wrong with the parotid gland was noted. The examination of the duct was negative. Two enlarged parotid glands were felt on palpation, with no induration. The patient said that his father had had very prominent cheeks and that his had also been large as long as he could remember. He had congenitally enlarged parotid glands.

Review of the literature of these two subjects was undertaken after the record of our own observations was completed. The following résumé confirms the common observation that the ancients were great plagiarists of modern thought.

A BRIEF HISTORY OF ACUTE SUPPURATIVE PERITONITIS

The *Lancet* [2] of 1828-1829 contains a description of a case of acute parotitis at Hotel Dieu which resulted in gangrene. The "tumor extended from the posterior margin of the sternocleidomastoid muscle to the middle of the cheek and from the zygomatic arch down to the angle of the lower jaw. It was very hard and painful, the skin tense, livid and hot, the jaw could not be moved, both on account of the tension and the pain. . . . He had thirty leeches and an emollient poultice applied over the tumor. . . . Dr. M. Sanson, under whose care he was placed, made a deep incision. No liquid but blood. . . ." Four days later, pus mixed with gangrenous cellular

2. Lancet **2**:540, 1828-1829.

tissue was obtained when a trocar was plunged into an area of fluctuation. Nine days later, "the whole parotid" had sloughed out. The patient recovered.

Sir Benjamin Brodie,[3] in 1834, described accurately the clinical course and gross pathologic picture usually found. Concerning the pathologic picture, he said, "On opening the body after death, matter is found deposited in small portions throughout the interstitial substance of the gland itself and specks of matter appear here and there poured out on pressure from various parts." Concerning treatment and prognosis, he says: "If suppuration ensues . . . when sufficiently forward, the abscess should be opened. If the inflammation occurs at the termination of some other disease, I have seldom found leeches of any use. It is a very bad symptom and generally indicates approaching dissolution."

The *Lancet* [4] of 1844 contains the anonymous statement: "Inflammation of the parotid glands is apt to occur in every form of adynamic febrile disease in old age." Monson,[5] in 1848, reports a case of enlargement of the parotid gland cured by the application of tincture of iodin.

It seems that, because of the known tendency of an orchitis to follow epidemic parotitis, an association was suspected very early between the parotid gland and the female pelvic organs, especially the ovaries. Ovariotomy was the first laparotomy to be somewhat commonly performed, and most of the intra-abdominal operations were followed by more or less evidence of infection. The combination of fever, which is said to decrease the parotid secretion, and a certain amount of peritonitis, with its associated intolerance to fluid intake, made the association seem a probable one, until the era of aseptic surgery appeared, when it was noted that the acute suppurative parotitis followed many other conditions. Before the days of the blood culture, infection by the blood route was thought to explain the etiology of most cases.

In 1878, Munde [6] noted the first case of parotitis after ovariotomy, and in 1880 Moeriche [7] reported five cases of parotitis following a series of 200 ovariotomies, which was the first publication in regard to parotitis subsequent to operations on the female genitalia. The following year, Goodell [8] reported five more cases following operations on the female pelvic organs.

---

3. Brodie, Benjamin: Lancet **1**:450, 1834.
4. Lancet **1**:538, 1844.
5. Monson: Lancet **1**:43, 1848.
6. Munde, quoted by Wagner: Ueber postoperative parotitis, Wien. klin. Wchnschr. **17**:1407, 1904.
7. Moeriche, quoted by Wagner (Footnote 6).
8. Goodell: Med. Times & Gaz. **2**:290, 1881.

S. Paget,[9] in 1886, discussed the subject of acute suppurative parotitis and collected 101 cases, including his own cases. He concluded that "the parotid is related to the peritoneum; (2) it is related to the generative organs; (3) abdominal or pelvic lesions may be followed by parotitis without pyemia, and (4) such a parotitis, if it occurs late in a patient not exhausted by the primary trouble and with healthy kidneys, is usually followed by recovery." This article started a discussion into which entered Cribb,[10] O'Connor [11] and Taylor.[12] Taylor attacked the idea of a connection with injury to the peritoneum and of connection with the ovaries, and said that all cases in which it occurred were septic. As a result of this discussion, Harkins [13] reported a case of enlargement of the parotid gland that recurred on each of six successive pregnancies and grew larger slowly during pregnancy. After delivery, the swelling subsided. He interpreted this case as evidence of the relation of parotitis to the female generative organs.

Hanau [14] (1889) and Pilliet [15] (1890) suggested that parotitis could occur as a secondary infection of Stenson's duct by mouth organisms. Morley, in 1902, suggested, as routes of entrance of infection, the lymph glands, Stenson's duct and the blood stream, and thought that an anesthetic plus the drying effect of atropin might be a contributing factor in the disease.

LeDentu [16] (1903) recommended early incision in suppurative forms of parotitis consecutive to operations, and stated that positive evidence of suppuration should not be awaited because gangrene develops rapidly.

G. Wagner,[17] in 1904, says that, concerning treatment, one should follow the Latin rule "Parotidites omnes ante maturitatem aperiendae" ("One should not wait for the presence of suppuration for incision"). He advised incision parallel to the seventh nerve fibers.

---

9. Paget, S.: Secondary Inflammation of the Parotid, Lancet **1**:732, 1886; The Relation of the Parotid Gland to the Generative Organs, Lancet **1**:86, 1886.

10. Cribb, A. J.: The Connection Between the Parotid Glands and the Generative Organs, Lancet **1**:227, 1886.

11. O'Connor, T. B.: The Connection Between the Parotid Gland and the Generative Organs, Lancet **1**:375, 1886.

12. Taylor, F. T.: Lancet **1**:130, 1886.

13. Harkins, A.: The Connection Between the Parotid Gland and the Generative Organs, Lancet **1**:375, 1886.

14. Hanau: Beitr. z. path. Anat. u. z. allg. Path. **2**, No. 5, 1889.

15. Pilliet: Bull. Soc. anat. de Paris, 1890, p. 182.

16. LeDentu: Des parotides consecutives aux operation sur l'appariel genital de la femme, Arch. gén. de méd. **1**:721-723, 1903.

17. Wagner, G.: Ueber postoperative parotitis, Wien. klin. Wchnschr. **17**: 1407, 1904.

Buscarlet,[18] who presented a case in 1907, thought that very severe postoperative parotitis is only a local manifestation of a general infection. During the same year, Morestin [19] reported a case of acute suppurative parotitis in which the pus was expressed from the duct repeatedly, and the patient recovered; and Pique [20] reported a series of 7,200 operations with only two cases of parotitis following. In 1910, Lenoir [21] advised incision without delay in fulminating cases.

One of us (V. P. B.[22]), in 1912, recommended an incision anterior to the ear and posterior to the facial nerve extending downward around the angle of the jaw (the operation described in detail herein). In 1913, Morestin [23] suggested an incision and approach somewhat similar. The incision curved a little farther posteriorly behind the ear, and then forward, so that exposure of the gland was more from below upward than from behind forward, as in the operation described herein. The incision of Morestin has the advantage of exposing the posterior inferior pole of the gland, which occasionally has caused trouble and has necessitated reopening of a small abscess in this region. Later, in 1917 Lilienthal [24] advocated an incision and approach somewhat similar.

Maitland [25] says that pyrexia inhibits the salivary flow and tends toward increased activity of the micro-organisms in the mouth.

Barrow,[26] in 1917, spoke of acute suppurative parotitis due to the pneumococcus, and said such cases are rare, only thirty appearing in the literature.

Manton,[27] who reported acute suppurative parotitis in 1918, in a case of pernicious vomiting of pregnancy, said such cases are extremely rare, and reviewed the literature. Collins [28] (1918) reported a series

---

18. Buscarlet: Bull. et mém. Soc. de chir. de Paris **33**:1263, 1907.

19. Morestin, H.: Parotidite postoperatoire, Bull. et mém. Soc. de chir. de Paris **23**:1031, 1907.

20. Pique: Bull. et mém. Soc. de chir. de Paris **25**:1262, 1907.

21. Lenoir: Paris chir. **2**:118-123, 1910.

22. Blair, V. P.: Septic Parotitis, Med. & Surg. **1**:34 (March) 1917.

23. Morestin, H.: Ganglion tuberculeux de la region parotidienne, extirpaté par une incision esthétique, dissimulée dans le sillon retro-auriculaire, Bull. et mém. Soc. de chir. de Paris, N. S. **35**:1066, 1913; Evacuation of Diffuse and Marked Suppurations of the Parotid Gland, Gaz. d. hôp. **86**:86, 1913.

24. Lilienthal, H.: A Method of Incision of the Parotid Abscess Without Injury to the Facial Nerve, Am. J. Surg. **31**:101 (April) 1917.

25. Maitland, H. S., in Binnie, J. F.: Treatise on Regional Surgery, Philadelphia, P. Blakiston's Son & Co., 1917.

26. Barrow, J. V.: Bilateral Pneumococcal Parotitis, J. A. M. A. **68**:1680 (June 9) 1917.

27. Manton, W. P.: Parotitis Following Induced Abortion in a Case of Pernicious Vomiting of Pregnancy, J. A. M. A. **71**:104 (Sept. 28) 1918.

28. Collins, C. U.: Parotitis as a Postoperative Complication, Tr. West. S. A., Minneapolis **28**:51-61, 1918; Surg., Gynec. & Obst. **28**:404 (April) 1919.

of cases of acute parotitis developing in patients placed on Ochsner treatment; i. e., nothing by mouth. Collins, as a prophylaxis, used chewing gum and later a stick of candy to stimulate secretion in such cases. In 1919, Cope [29] reported seven cases, and said that the immediate exciting cause is the staphylococcus or streptococcus, but that debilitating disease is most important. Bonnet and de Nabias [30] (1919), who reported thirty cases following typhus fever, said that the orifice of Stenson's duct looked like a ureteral orifice by cystoscopic examination in pyelonephritis. Fisher [31] (1919) stated that the season of the year makes little difference, and that anatomic facts definitely eliminate transmission of infection to the parotid gland through the lymphatics of the mouth. One of his conclusions was that "septic parotitis is of hematogenous origin." We are unable to agree with this conclusion. By a study of cases and a review of the literature, it seems to us that the great majority of cases are not blood borne. Fenwick [32] (1919) advised the use of a rubber nipple to stimulate salivary secretion following operation. Fenwick also tried horse radish, a piece of raw meat and a pebble in the mouth. He reported thirty cases of rectal feeding, with no parotitis.

Rolleston and Oliver [33] (1919), in the medical treatment of 1,000 cases of gastric ulcer, concluded that secondary parotitis may complicate ulcer. With oral starvation, it occurred ten and one-half times more frequently than in cases allowed fluid by mouth. In 470 cases treated by oral starvation, there were twenty-one cases of parotitis. In 530 cases in which some food was allowed by mouth, there was 0.4 per cent. of parotitis. Hanau and Pilliet,[34] by making microscopic observations in these cases, found the infection spreading from the central duct to the periphery. Girode found cultures identical with cultures from the mouth. It is said that Tait [35] proved that the outer one third of Stenson's duct normally contains the same organisms as are found in the mouth.

---

29. Cope, V. Z.: Acute Necrotic Parotitis, Brit. J. Surg. **7**:130 (July) 1919

30. Bonnet, B., and de Nabias: Parotitis After Typhus and Relapsing Fever, Lyon chir. **16**:172-303 (March-April) 1919.

31. Fisher, W. H.: Postoperative Suppurative Parotitis, Ann. Surg. **70**: 713 (Dec.) 1919.

32. Fenwick: Brit. M. J., May 29, 1919.

33. Rolleston and Oliver: Brit. M. J., May 29, 1919.

34. Hanau and Pilliet, quoted by Brophy: Oral Surgery: The Diseases, Injuries and Malformations of the Mouth and Associated Parts, Philadelphia, P. Blakiston's Son & Co., 1915, p. 966.

35. Tait, quoted by Brophy: Oral Surgery: The Diseases, Injuries and Malformations of the Mouth and Associated Parts, Philadelphia, P. Blakiston's Son & Co., 1915, p. 966.

A BRIEF HISTORY OF PAROTITIS WITH OBSTRUCTIVE SYMPTOMS

The *Lancet* [36] for 1827-1828 describes a case at the Hospital of Surgery, Panton Square, St. James, which was probably an obstructive parotitis.

> A female, forty-five years of age applied on account of a tumor about the bulk of a hazelnut situated on the cheek, a little anterior to and below the ear, which tumor had formed suddenly on the morning of the same day and which she stated would in the course of a few hours as quickly subside. For some years past similar swellings have formed and disappeared in a like manner and when they have subsided she has always perceived the sudden escape of watery fluid into the mouth.

It is said that, in 1856, Dermarquay described a case in which Steno's duct was blocked with pus and distended with gas and secretion, and that a report embodied in an anonymous communication to the *Medical Times and Gazette* of Nov. 1, 1868, gave the first complete history and symptomatology of the lesion.

Kussmaul,[37] in 1879, recorded a case of recurring salivary tumor at intervals of almost six months, resulting from fibropurulent inflammation of Stenson's duct. The fibrinous nature was verified microscopically by Friedlander and Recklinghausen. The patient was taught to use a platinum probe. In 1881, Stiller [38] of Budapest reported a similar case. Jonathan Hutchinson,[39] in 1893, was first to describe xerostomia (dry mouth), according to Rhodes.

Johnson,[40] in 1896, appears to be the first to emphasize an obstructive parotitis of other origin than calculus:

> I may express my belief that the above cases are examples of swelling of the parotid gland resulting from interference with the escape of its secretion due to inflammation of the lining of Stenson's duct. This conclusion was suggested by the fact that . . . pressure on the swollen gland caused the escape of a plug.

In 1912, Blair [41] suggested that, in cases with obstruction of the duct near its outlet, the duct should be split. In 1913, Hewlett [42] reported a case of "bacterial intermittent swelling" of the parotid

---

36. Lancet **13**:830, 1827-1828.

37. Kussmaul: Berl. klin. Wchnschr., No. 15, 1879.

38. Stiller: Wien. med. Wchnschr., 1881.

39. Hutchinson, Jonathan: Arch. Surg., London **3**:343, 1892.

40. Johnson, P.: Some Unusual Cases of Swelling of the Parotid Gland, Lancet **1**:1056-1058, 1896.

41. Blair, V. P.: Surgery and Diseases of the Mouth and Jaws, St. Louis. C. V. Mosby Company, 1912.

42. Hewlett, A. W.: Bacterial Intermittent Swellings of the Parotid Glands Due to Infection of Steno's Duct (Sialoductilitis), J. Michigan M. A. **12**:664, 1913.

gland due to infection of Steno's duct (sialoductilitis), and discussed the condition. Rhodes,[43] in 1915, reported a case of parotitis, with obstructive symptoms, in which he split the duct in 1912, with relief of symptoms for over a year, after which time he lost trace of the patient. He reviewed the literature of this type of parotitis and found thirty-nine more cases, exclusive of cases with stone. Ransohoff, in the discussion following Rhodes' paper, expressed the opinion that the disease was due to excessive secretion reflexly produced and not to stenosis of the duct. He cited the case of pain in the parotid region, said to affect those learning to play the horn.

---

43. Rhodes, G. B.: Intermittent Swelling of the Salivary Glands, Lancet Clinic, Cincinnati **113**:248, 1915.

THE END-RESULTS OF SURGERY OF THE THYROID GLAND*

JOHN DEJ. PEMBERTON, M.D.
Head of Section in Division of Surgery, Mayo Clinic
ROCHESTER, MINN.

In recent years, there has been great improvement in the immediate and end-results of surgery of the thyroid gland. During the year 1922, in the Mayo Clinic, 1,983 operations were performed on 1,497 patients with goiter. Nineteen patients died, a mortality by operation of 0.95 per cent., and by case of 1.2 per cent. In the earlier days of thyroid surgery, the relatively high mortality rate was an influential factor in the decision of many patients with goiter to seek means of cure other than surgery. Many of these finally came to surgery late in the course of the disease, when the operative risk was increased, and when the prospect of complete cure was greatly diminished. In this manner, a small vicious circle was created. But the knowledge of the benefits derived from surgery has gradually become more widely disseminated, and today a much larger proportion of patients with goiter are operated on early in the course of the disease, when the risk is less and the prospect of complete cure is greatest. Thus, with the better recognition of the dangers associated with the surgical management, together with increased knowledge of the thyroid gland in health and disease, largely as the result of the discovery of thyroxin and the practical application of basal metabolism, the immediate and end-results following operation are now comparable with those of any major surgical procedure.

CLASSIFICATION OF OPERABLE THYROID CONDITIONS

The diseases of the thyroid gland amenable to surgical interference may be grouped, according to Plummer's classification, as: (1) diffuse colloid goiter, (2) adenoma without hyperthyroidism, (3) adenoma with hyperthyroidism, (4) exophthalmic goiter, (5) thyroiditis and (6) malignancy. It is apparent that the results of surgery vary according to the type of goiter.

Diffuse Colloid Goiter.—This type of goiter is the common physiologic enlargement of the thyroid gland in adolescence. It is a symmetrical swelling due to the distention of the follicles by excessive colloid deposit, and does not cause symptoms other than those incident

* Read before the American Life Convention, Chattanooga, Tenn., March 8, 1923.

to the pressure of the growth. Marine[1] has definitely proved that iodin insufficiency is the important etiologic factor in such cases, and that the condition can be avoided by feeding, in adolescence, a small amount of iodin. When young girls with unstable nervous systems develop this type of goiter, the symptoms are often mistaken for the hyperthyroidism of exophthalmic goiter. In most instances, the condition can be readily diagnosed, but in others, especially if the neurotic tendencies are well marked, it is extremely difficult by clinical means alone definitely to differentiate the two diseases, and only by repeated basal metabolic tests can the diagnosis be accurately made. The patient with colloid goiter has a normal basal metabolism, whereas the patient with exophthalmic goiter has a rate above normal. Usually, diffuse colloid goiter disappears spontaneously between the twentieth and thirtieth years, but its complete disappearance can also be induced by the administration of iodin or thyroxin. Unless the enlargement of the thyroid is associated with nodular masses (adenomas), or unless it attains great dimensions and thus interferes with breathing, by pressure on the trachea, operation is not indicated. In cases in which operation is advisable, the operative risk is less than 1 per cent., and the end-results are good. As a preventive measure against the recurrence of the enlargement, occasional small doses of iodin are sometimes indicated.

Adenoma Without Hyperthyroidism.—Adenomas occur in the thyroid gland either as single or multiple nodular masses, commonly late in the second, or early in the third, decade of life. They are encapsulated nodules composed of new follicles of either fetal or adult origin, in varying degrees of degeneration, and in their early life are not associated with hyperthyroidism. Symptoms, if present, are the result of the pressure of the growth on the surrounding structures, and vary in degree with the size and location of the tumor. The tumors may attain enormous proportions and may be entirely cervical, or cervical with substernal projection (13.5 per cent.), or, in a small proportion of cases, they may be entirely concealed within the thoracic cavity.[2]

Treatment other than operative is ineffective in causing the disappearance of the tumors. As a certain proportion of the patients with adenoma develop hyperthyroidism later (averaging fourteen years after the appearance of the goiter), surgery is often indicated as a preventive measure, particularly when the patient cannot be under strict medical observation. Besides, it is apparent that surgery is indicated for

---

1. Marine, David, and Kimball, O. P.: Prevention of Simple Goiter in Man, Arch. Int. Med. **25**:661 (June) 1920; Goiter Survey Work in Ohio, Ohio State M. J. **16**:757 (Oct.) 1920.

2. Pemberton, J. deJ.: The Surgery of Substernal and Intrathoracic Goiter, Arch. Surg. **2**:1-20 (Jan.) 1921.

cosmetic purposes and for the relief of symptoms incident to the pressure of the growth. The operative risk is less than 0.5 per cent. During the year 1922, in the Mayo Clinic, there were 663 thyroidectomies performed on 663 patients with adenomatous goiter without hyperthyroidism, with one death, a mortality of 0.15 per cent. In nearly 100 per cent. of cases, successful operation results in complete cure. The very infrequent recurrences may be attributed in nearly every instance to failure to remove all of the adenomatous tissue at the time of the operation.

Adenoma with Hyperthyroidism.—Plummer has shown that the toxic symptoms associated with adenoma form a definite clinical entity and must not be confused with those of exophthalmic goiter. He has pointed out that a patient who, in her twenty-second year, has an adenoma of the thyroid gland has a definite chance of developing symptoms of hyperthyroidism in her thirty-sixth year. The symptoms usually occur spontaneously, with insidious onset, and develop gradually but progressively. The symptoms may be induced abruptly by the administration of iodin to the patient with an adenoma without hyperthyroidism. On account of the insidious onset and mildly progressive course, many such patients do not appreciate any great change in their condition until symptoms of marked cardiac irregularity, or of decompensation, develop. Consequently, owing to the delay in coming to operation, visceral degenerative changes often develop, adding considerably to the operative risk and diminishing the prospect of complete cure. The operative mortality is between 2 and 4 per cent. In from ten days to two weeks after the successful removal of the adenomatous tissue, the hyperthyroidism has completely disappeared. Judd [3] found that, after the lapse of two years, about 83 per cent. of these patients considered themselves cured and 5 per cent. more were markedly improved.

Exophthalmic Goiter.—As defined by Boothby,[4] exophthalmic goiter is "a constitutional disease apparently due to an excessive, probably an abnormal, secretion of an enlarged thyroid gland showing pathologically diffuse, parenchymatous hypertrophy and hyperplasia. It is characterized by an increased basal metabolic rate with the resulting secondary manifestations, by a peculiar nervous syndrome and, usually, by exophthalmos, with a tendency to gastric intestinal crises of vomiting and diarrhea." The onset of the disease may be gradual, or apparently abrupt, and its course from the beginning may be one of overwhelming intensity, terminating fatally in a few months. More often, however,

---

3. Judd, E. S.: Results of Operations for Adenoma with Hyperthyroidism and for Exophthalmic Goiter, Ann. Surg. **72**:145-151 (Aug.) 1920.

4. Boothy, W. M.: Diagnosis and Treatment of the Diseases of the Thyroid Gland, Oxford Medicine, London, Oxford University Press, 1921, Vol. 3. p. 883-963.

this period of marked severity will be followed by one of partial or complete remission of the symptoms of hyperthyroidism, which may last for months, only to be superseded again and again by waves of varying intensity. In other cases, the onset may be gradual, and the disease may run a prolonged mild course with little variation in its intensity. On account of the natural fluctuating course of the disease, with the occurrences of spontaneous remissions of symptoms, it is impossible to evaluate any form of treatment until sufficient time has elapsed to preclude the probability of recurrences.

While the cause of exophthalmic goiter is unknown, there is always a characteristic pathologic picture of diffuse, parenchymatous hypertrophy and hyperplasia in the thyroid gland. All evidence points to the fact that the thyroid gland is producing an excessive amount of secretion, probably altered or perverted in character, and most of the present-day methods of treatment aim to diminish the activity of the gland by reducing its blood and nerve supply, or by partial ablation of the gland either by operation or radiation. The ultimate object of the surgical treatment of patients with exophthalmic goiter is the removal by resection of the greater part of the gland, the portion preserved being sufficient to carry on its normal functions. In certain stages of the disease, the removal of the gland is attended by greater dangers than in others. Particular danger is encountered immediately preceding, during or following a crisis; and in such instances it is advisable to employ preliminary surgical procedures such as ligations or injections of boiling water into the gland. The improvement in the patient's condition after such preparatory measures and a period of rest is often very great, and formerly, if not urged to return, many patients considered themselves cured and had no further operations. Our records show that some of these patients remained apparently well, but many more have had relapses; sometimes, however, not until after several years. Subsequently, in the period of development of thyroid surgery, all patients with exophthalmic goiter were urged to have a partial thyroidectomy, consisting at first of the resection of one lobe, and later of resection of a small portion of the second lobe. A decided improvement in the end-results followed this change in the surgical management, but the incidence of recurrences of symptoms, while greatly reduced, was still too high. Today the routine operation for the removal of the goiter is even more radical, consisting in a double resection of the thyroid gland with preservation of the posterior part of each lobe equivalent to from one sixth to one third of a normal lobe.

In the past, the relatively high mortality associated with surgery in cases of exophthalmic goiter was, to a large extent, dependent on factors inherent to the disease. Today, with a better knowledge of the natural course of the disease, through the cooperative efforts of the internist,

the laboratory worker and the surgeon, it is possible to avoid many of the operative dangers to which the patient was formerly subjected. During 1922, there were 1,093 operations performed on 633 patients with exophthalmic goiter. Eleven patients died, a mortality by operation of 1.005 per cent., and by case of 1.74 per cent.

DATA ON CASES OF EXOPHTHALMIC GOITER IN WHICH OPERATION WAS PERFORMED

In January, 1922, a questionnaire was mailed to each of 482 patients who had been successfully operated on during the year 1916, an average lapse of five and one-half years. Definite information was received from 349 patients (72.4 per cent.). Three hundred and fifteen (90 per cent.) of the 349 patients were living, and thirty-four (10 per cent.) had died from various causes. The questionnaire was direct and comprehensive and, when answered intelligently, gave a good idea of the condition of the patient. In many instances, the answers were written

TABLE 1.—*Comparison of Duration of Goiter and Hyperthyroidism Before Operation (1909, 1916 and the First Six Months of 1922)*

Series	Average Duration of Goiter, Months	Average Duration of Hyperthyroidism, Months
1909	59.07	31.24
1916	40.8	23.93
First six months of 1922	41.45	19.47

by, or with the assistance of, a physician. In 311 of the 315 replies concerning patients who were living, the data were sufficient to permit classification. Data concerning the 311 persons still living and the thirty-four who had died may be summarized as follows:

Age and Sex.—The oldest patient was 64 years, the youngest 14 years; the average age was 34.09 years. Sixty-one (18 per cent.) of the patients were males, and 284 (82 per cent.) females, a ratio of about 1 to 4.5.

Etiologic Factors.—The onset of the disease was attributed to infection (influenza in nine cases, and tonsillitis in 131) in 40 per cent. of the cases. In a series of cases of exophthalmic goiter in 1920 and 1921 (after the influenza epidemics), influenza was a causative factor in 22 per cent., and a history of tonsillitis, or of septic tonsils, was noted in 55 per cent.

Duration of Goiter and Hyperthyroidism.—By a comparison of the averages for 1909, 1916 and the first six months of 1922, it is obvious that there is a constant tendency for persons with exophthalmic goiter to resort to surgery earlier in the course of the disease (Table 1). In

the year 1916, 27 per cent. of the patients had had medical treatment for goiter before coming to the clinic, and 2 per cent. had had surgical treatment.

In interpreting and classifying the replies according to the degree of improvement, account has been taken of the point of view of the patient and physician; of the presence or absence of symptoms of continued or recurrent hyperthyroidism, and of symptoms suggesting visceral degenerative changes. These replies, representing the condition of the patients on an average of five and one-half years after operation, are divided into four groups:

Group A.—*Cured.* One hundred and eighty-eight patients (54 per cent.) comprise the group who consider themselves cured, and whose replies would indicate that there is no evidence of hyperthyroidism, or of the residual effects of the disease, other than the presence of exophthalmos. This is usually the last symptom to disappear, and although the eyes often partially recede and lose their staring appearance, they may always remain prominent. In this group, seventy-six patients (40 per cent.) report that their eyes are still prominent. Since the operation, eighteen (9.5 per cent.) have had what they consider evidence of recurrence, but are emphatic in their statement that they are now well. Thirty-six patients (19 per cent.) have some swelling of the neck, which has persisted since operation. As will be noted in Table 6, the routine operation in the year 1916 consisted in the resection of one lobe in 138 cases, and in the resection of two lobes in 186 cases (54 per cent.). When the second lobe was resected, it consisted in removing the "inner part," "a small portion," "one-fourth" or "one-third," and in many instances the thyroid gland preserved was equivalent to two or three times a normal-sized lobe. Many of the women in this group have borne children, and three of the men served overseas during the Great War.

Group B.—*Greatly improved and able to carry on normal duties.* There are eighty-eight patients (25.5 per cent.) in this group. In many instances, the patients report that they are cured, but later mention that they "tire more easily" or "lack strength"; or have "choking spells," "stomach trouble," "kidney trouble," "rheumatism," and the like, but no symptoms of hyperthyroidism, as evidenced by loss of weight or rapid pulse, are reported. Forty-eight of the patients (54.5 per cent.) have exophthalmos. Thirty (34 per cent.) have had further trouble from the goiter, and twenty-four (27 per cent.) have some enlargement of the neck.

Group C.—*Improved, but with evidence of persistent or recurrent hyperthyroidism or its residual effects.* Twenty-eight patients (8 per cent.) belong in this group. While most of these patients report normal weight and normal pulse rate, they complain of palpitation or dyspnea

on exertion, and are easily exhausted. Fourteen (50 per cent.) have exophthalmos. Thirteen (46 per cent.) have enlargement of the neck. Twelve (43 per cent.) had had a recurrence of symptoms.

Group D.—*Unimproved.* The condition of nine (3 per cent.) of the patients was not improved. Four (44 per cent.) had exophthalmos. Five (55 per cent.) had enlargement of the neck. Eight (88 per cent.) had a recurrence of symptoms.

Table 2.—*Classification of Results Following Operation for Exophthalmic Goiter According to Sex and Age*

	Group A	Per Cent.	Group B	Per Cent.	Group C	Per Cent.	Group D	Per Cent.	Mortality	Per Cent.	Total	Per Cent.
Males.....	32	52.4	18	26.2	1	1.6	1	1.6	9	14.7	61	18.0
Females.....	154	54.1	70	24.6	27	9.5	8	3.5	25	8.8	284	82.0
Total.....	186	53.9	88	25.5	28	8.1	9	2.6	34	9.8	345	
Age by decades:												
11 to 20.....	20	71.4	3	10.7	1	3.5	1	3.5	3	10.7	28	8.1
21 to 30.....	60	58.8	24	23.5	8	7.8	5	4.8	5	4.8	102	29.5
31 to 40.....	56	50.4	34	30.6	8	7.2	2	1.8	11	9.9	111	32.1
41 to 50.....	35	47.2	21	28.3	7	9.3	1	1.3	10	13.5	74	21.4
51 to 60.....	14	50.0	6	21.0	4	14.5	0	....	4	14.5	28	8.1
61 to 70.....	1	50.0	0	....	0	....	0	....	1	50.0	2	0.5
Average age in years.....	33.76		35.85		37.32		30.11		37.85		34.89	

Thirty-four (9.8 per cent.) of the 345 patients have died. Data concerning the cause of death are not sufficient to permit analysis.

The important data are classified according to the results of treatment (Tables 1-6), and illustrate very definitely that, in the surgical

Table 3.—*Classification of Symptoms According to Results*

	Group A		Group B		Group C		Group D		Mortality		Total	
Symptoms	Patients	Per Cent.	Patients	Per Cent.	Patients	Per Cent.	Patients	Per Cent.	Patients	Per Cent.	Patients	Per Cent.
Vomiting.....	26	46.4	16	28.5	9	16.0	1	1.7	4	7.0	56	13.3
Diarrhea.....	33	47.8	19	26.0	4	5.6	3	4.3	10	14.4	69	20.0
Vomiting and diarrhea.....	38	54.2	18	25.7	4	5.7	2	2.8	8	11.4	70	20.2
Total.....	97	49.7	53	27.1	17	8.7	6	3.0	22	11.2	195	53.0
Edema.....	16	48.4	8	24.2	4	12.1	1	3.0	4	12.1	33	9.5
Albuminuria...	77	53.4	38	26.4	7	4.8	5	3.4	17	11.8	144	41.7
Edema and albuminuria...	37	48.0	23	29.8	7	9.0	1	1.2	9	11.7	77	22.3
Total.....	130	51.1	69	27.1	18	7.0	7	2.7	30	11.4	254	73.6

treatment of exophthalmic goiter: (1) a large percentage of patients (79 per cent.) treated surgically are cured or markedly improved; (2) failure to obtain maximal benefit may be attributed, in part (*a*) to incompleteness of the operation, and (*b*) to the delay of the patient in seeking surgery. While data are not available to substantiate the assertion, I am convinced that the presence of a focus of infection is an

important factor in the incidence of recurrences, and no operative management of exophthalmic goiter should be considered complete until all foci have been eliminated.

OTHER OPERABLE CONDITIONS

Thyroiditis is uncommon. Infection of tuberculous or nontuberculous origin may occur in the normal thyroid gland, in adenomatous goiter or in exophthalmic goiter. The onset is usually slow and may be without symptoms, except the tumor, which is usually characteristically hard from the beginning. At the onset, especially of the tuberculous form, the parenchyma of the gland is stimulated; there are symptoms of hyperthyroidism, and the condition may be mistaken for exophthalmic goiter. In practically all cases, the infective process is diffuse, ultimately destroying all the parenchyma, and myxedema supersedes. Surgery is indicated only in cases of tuberculous origin and in cases in which suppuration is suspected. The results are similar to those following nonoperative measures.

TABLE 4.—*Classification of Results According to Symptoms*

	Group A	Group B	Group C	Group D	Mortality
Total number	186	88	28	9	34
Patients who had vomiting or diarrhea, or both	97	53	17	6	22
Percentage	52.1	40.0	60.7	66.6	64.7
Patients who had edema or albuminuria, or both	130	69	18	7	30
Percentage	69.8	78.4	64.2	77.7	88.2

TABLE 5.—*Classification of Results According to the Duration of Goiter and Hyperthyroidism*

	Group A	Group B	Group C	Group D	Mortality	Total
Average duration of goiter (months)	38.72	39.94	67.56	31.00	34.67	40.8
Average duration of hyperthyroidism (mos.)	20.49	20.22	45.81	25.66	33.93	23.93

Malignancy of the thyroid gland is not uncommon. Wilson [5] found the incidence of malignancy in the thyroid cases in the Mayo Clinic to be one in fifty-seven, one male to two females. Pathologically, the tumors occur as sarcoma, carcinoma, malignant adenoma and malignant papilloma. When the malignancy has invaded the capsule, the diagnosis can be made clinically; otherwise, the diagnosis is usually made by the pathologist. However, in all instances of goiter, if there has been recent rapid growth, malignancy should be suspected. Wide surgical removal of the malignant tissue, in conjunction with intensive

5. Wilson, L. B.: Malignant Tumors of the Thyroid, Ann. Surg. **74**:129-184 (Aug.) 1921.

radiation by radium and roentgen ray offers the best chance for cure. Herbst,[6] in a study of 207 cases of malignancy of the thyroid in which operation was performed in the Mayo Clinic to January, 1921, found no cures in nineteen cases of sarcoma; 5 per cent. five-year cures in the sixty-two cases of carcinoma; 20 per cent. five-year cures in 102 cases of malignant adenoma, and 33 per cent. five-year cures in twenty-four cases of malignant papilloma.

SUMMARY

The mortality of surgery of the thyroid gland compares favorably with that of any major surgery. At the Mayo Clinic during the year 1922, there were 1,983 operations on 1,497 patients with goiter, with a mortality by operation of 0.95 per cent. and by case of 1.2 per cent.

TABLE 6.—*Classification of Results According to Operation*

	Group A		Group B		Group C		Group D		Mortality		Total	
Operation	Patients	Per Cent.	Patients	Per Cent.	Patients	Per Cent.	Patients	Per Cent.	Patients	Per Cent.	Patients	Per Cent.
One ligation...	2	40.0	1	20.0	..	....	..	....	2	40.0	5	1.44
Two ligations..	4	25.0	1	6.2	1	6.2	2	12.5	8	50.0	16	4.63
Resection of one lobe after one or two ligations.....	57	54.8	22	21.1	10	9.6	4	3.8	11	10.5	104	40.0
Resection of one lobe without previous ligation.....	19	55.8	8	23.5	4	11.7	1	2.9	2	5.8	34	
Resection of two lobes after one or two ligations.....	75	54.7	43	31.3	8	5.8	2	1.3	9	6.5	137	53.6
Resection of two lobes without previous ligation.....	29	59.1	13	26.5	5	10.2	..	....	2	4.0	49	
Total.....	186	53.9	88	25.5	28	8.1	9	2.6	34	9.8	345	
Secondary thyroidectomy....	13	38.2	11	32.3	5	14.7	2	5.8	3	8.8	34	9.8

The diseases of the thyroid gland amenable to surgery may be grouped under six headings: (1) diffuse colloid thyroid, (2) adenoma without hyperthyroidism, (3) adenoma with hyperthyroidism, (4) exophthalmic goiter, (5) thyroiditis and (6) malignancy.

Diffuse colloid goiter is a physiologic enlargement of the thyroid gland occurring in adolescence, caused by iodin insufficiency and cured by the administration of iodin or thyroxin. Unless colloid goiter is associated with adenoma, or by its size causes pressure symptoms, surgery is not indicated.

Adenoma without hyperthyroidism should be treated surgically, partly for cosmetic purposes and for the relief of pressure symptoms,

6. Herbst, W. P.: Unpublished thesis.

and partly because a certain proportion of patients subsequently develop hyperthyroidism. The operative risk is less than 0.5 per cent., and the operation results in cure in practically 100 per cent. of cases.

If a patient with adenoma of the thyroid gland develops hyperthyroidism, the onset is usually so insidious that surgery is not sought until marked visceral degeneration has taken place, which increases the operative risk and diminishes the chance for complete cure. The operative mortality in this group is between 2 and 4 per cent. Surgery results in cure in about 83 per cent. and in marked improvement in another 5 per cent.

Exophthalmic goiter is a constitutional disease apparently due to an excessive (probably abnormal) secretion of the thyroid gland, and while its cause is unknown, treatment aims to diminish the activity of the thyroid gland. As a result of increased knowledge of the disease and of the dangers incident to surgery, and owing to the fact that patients with exophthalmic goiter are coming to operation earlier, before the development of visceral changes, the surgical mortality has been reduced to 1.005 per cent. in terms of operation and 1.74 per cent. in terms of cases.

The natural fluctuating course of the disease makes it difficult to evaluate any form of treatment, unless sufficient time has elapsed to preclude the probability of recurrence. For this reason, patients operated on in 1916, after the lapse of five and one-half years, were selected for the study. A questionnaire was sent to each of the 482 patients with exophthalmic goiter. Replies were received from 349 patients (72 per cent.). Ninety per cent. were living, 79 per cent. considered themselves cured or greatly improved by the operation, 8 per cent. were improved, but showed evidence of hyperthyroidism, or its effect, and 3 per cent. were not benefited. In analyzing the data concerning these patients, lack of improvement could be traced definitely to three causes: (1) incompleteness of operation, (2) the long duration of hyperthyroidism before operation, and (3) failure to eliminate after operation foci of infection.

Thyroiditis is rare, and surgery is indicated only in the tuberculous and suppurative types.

Malignancy occurs as sarcoma, carcinoma, malignant adenoma and malignant papilloma, in the ratio of one malignant case in fifty-seven, and the prospect of cure by operation and intensive radium and roentgen-ray treatment varies with the type of malignancy.

HISTOPATHOLOGY AND ETIOLOGY OF VARICOSE VEINS *

BERLIN B. NICHOLSON, M.D.
CHARLOTTESVILLE, VA.

Varicose veins, phlebectasia and venous varices are more or less synonymous terms. The term varicose vein generally refers to the diseased vein as a whole; while phlebectasia more properly refers only to the dilated veins and not to the pouched and sacculated areas. The large irregular pouches are generally designated venous varices. Because of the relative frequency of the condition in the long saphenous vein and its branches, the term varicose veins has come to be associated almost exclusively with the condition as it is found in the lower extremities. While varicosis is often seen in these parts, it is by no means the only part of the body in which it occurs. The condition is seen quite as frequently, if not more so, in the spermatic cord, where it is referred to as varicocele and is due to dilatation of the veins of the spermatic cord. Likewise, the hemorrhoidal veins about the rectum often become dilated to the extent that piles, or hemorrhoids, are formed. Less frequently, varicose veins occur in other areas. Occasionally, a true varicose condition occurs in the veins of the upper extremities. Local congenital varices have been observed in practically every portion of the body.

This investigation is concerned primarily with varicose veins of the lower extremities, and more particularly with the etiology of the condition. The diagnosis is relatively easy in the simple case, and not especially difficult in the cases due to femoral thrombosis and other mechanical obstructions. The question of treatment lies outside the scope of our present purpose.

The etiology is especially interesting in view of the fact that various theories have been advanced in an effort to explain the dilatation of the vessels. Reference is here made only to those cases that seem to come on insidiously and without apparent cause. There are certain cases following thrombosis which are explained on a purely mechanical basis. Likewise, those cases coming on during pregnancy and those seen in connection with various intra-abdominal growths, which cause increased pressure on the iliac veins, can, in part, be explained on a mechanical basis. On the other hand, there are a certain number of cases which

---

* From the Department of Histology and Embryology, University of Virginia.

are brought on through the action of forces or conditions which are not obstructive. The desire to throw some light on the etiology of these cases led me to study the microscopic structure of the diseased vein, and the gross anatomy of the saphenous and femoral veins with reference to valves.

My study has been confined chiefly to eight different specimens of tissue obtained from four patients, and to eighteen gross specimens obtained from cadavers in the anatomic laboratory. The gross specimens were studied with the idea of obtaining a more accurate knowledge concerning the number and frequency of valves in the external iliac, the upper femoral and the saphenous vein; and the frequency of the branches of the saphenous, and of the anastomoses between the saphenous and the deeper vessels.

I am thus able to make certain definite statements as to the microscopic structure of the wall of varicose veins. While the picture varies, depending on the level in the vein from which the section is cut, it is quite constant for each level. Also, the occurrence and arrangement of the valves in the external iliac, the upper femoral and the upper end of the saphenous vein are found to be quite constant. This latter fact is important in view of the prevailing ideas concerning the etiology. Sufficient evidence is produced to disprove the theory that varicose veins are caused primarily by valve insufficiency and static pressure in the vein.

For the description of the normal structure, I have depended on the literature. The most complete article on the subject is by Zancani,[1] who examined the saphenous veins of a 32-year old man and of a 22-year old woman, both of whom had clinically normal veins.

According to Zancani, the intima is composed of an endothelial lining, outside of which there is a delicate layer of connective tissue rich in elastic fibers. Peripheral to this connective tissue layer, he describes a more or less dense layer of longitudinally disposed elastic fibers, which take on the appearance of a membrane. This membrane may be called the internal elastic membrane, although it is not subendothelial as is the case with the artery. The middle layer, or media, is much thicker than the intima and is composed largely of circularly disposed smooth muscle. Between the intima and this extensive layer of circular muscle, there is a very thin layer of longitudinally disposed muscle, which Zancani places in the media. For reasons stated later, I prefer placing these muscle cells in the peripheral part of the intima, thus leaving the media composed only of circular muscle embedded in connective tissue. Through the latter pass many irregularly disposed

1. Zancani, A.: Ueber die Varicen der unteren Extremitäten, experimentelle und klinische Untersuchungen, Arch. f. Klin. chir. **96**:91-142, 1911.

delicate elastic fibers, as well as some larger ones which, along with the collagenous fibers, take a more or less longitudinal course. In the outer part of this layer, he finds a few vasa vasorum. The adventitia is composed of fibrous connective tissue, through which coarse elastic fibers run, both circularly and longitudinally. At intervals, bundles of longitudinally disposed smooth muscle cells may be seen. The majority of the vasa vasorum are also found in this layer.

Quain [2] also divides the vessel wall into intima, media and adventitia. He makes no statement, however, regarding the longitudinally disposed muscle in the media. He describes a delicate layer of longitudinal smooth muscle cells in the outer part of the intima. This, no doubt, is the same layer that Zancani described as an inner longitudinal layer of the media. He makes no mention of finding longitudinal muscle in the adventitia, which layer he describes as being slightly thicker than the media. Neither does he mention vasa vasorum.

Chiarugi [3] records practically the same observations as Quain and Zancani.

Statements regarding the nature of the change in the varicosed vessel wall are conflicting. This is partly because some have assumed that varicose veins are uniform structures. They have paid little attention to the extent of the process and to the level in the vein from which the specimen was taken. To arrive at some definite idea concerning the change, we must take into consideration the normal for each level, and also the extent of the process. The latter factor is especially important in view of the fact that, in the same section, there may be varying degrees of degeneration, ranging from the earlier to the latest. Similarly, in the same vein, at different levels, there is a great variation in the picture.

The literature discloses only one point of agreement among investigators—that the endothelium of the varicose vein is unaltered in appearance. Concerning other points, there is considerable variation of opinion. Some claim they find hypertrophy without atrophy. (Alglave and Retterer [4]). Others find both processes taking place at the same time (Epstein [5]); or hypertrophy followed by atrophy (Epstein,[5] Remedi,[6]

2. Quain, J.: Trattato di anatomia umana **1,** Part 2.

3. Chiarugi, Giulio: Istituzioni di anatomia dell'uomo **2,** Part 2, 1910.

4. Alglave and Retterer: Des modifications structurales des veines variqueuses, Compt. rend. Soc. de biol., 1907.

5. Epstein: Ueber die Structur normaler und ektatischer Venen, Virchows Arch. f. path. Anat. **108.**

6. Remedi: Contributo alla cura delle varici degli arti inferiori, Clin. chir., 1901.

Tomaselli,[7] Kashimura,[8] Marullaz[9]). It is almost universally agreed that there is an increase in the amount of connective tissue and that this increase is progressive. Some seem to think there is an increase in the amount of elastic tissue (Tomaselli[7]); while others are inclined to the contrary belief. We also find statements to the effect that the elastic fibers are broken and atrophied (Fischer[10]). In many cases there may be a relative increase in the amount of elastic tissue, while in reality there is a decrease in the amount. In other words, the functioning varicose

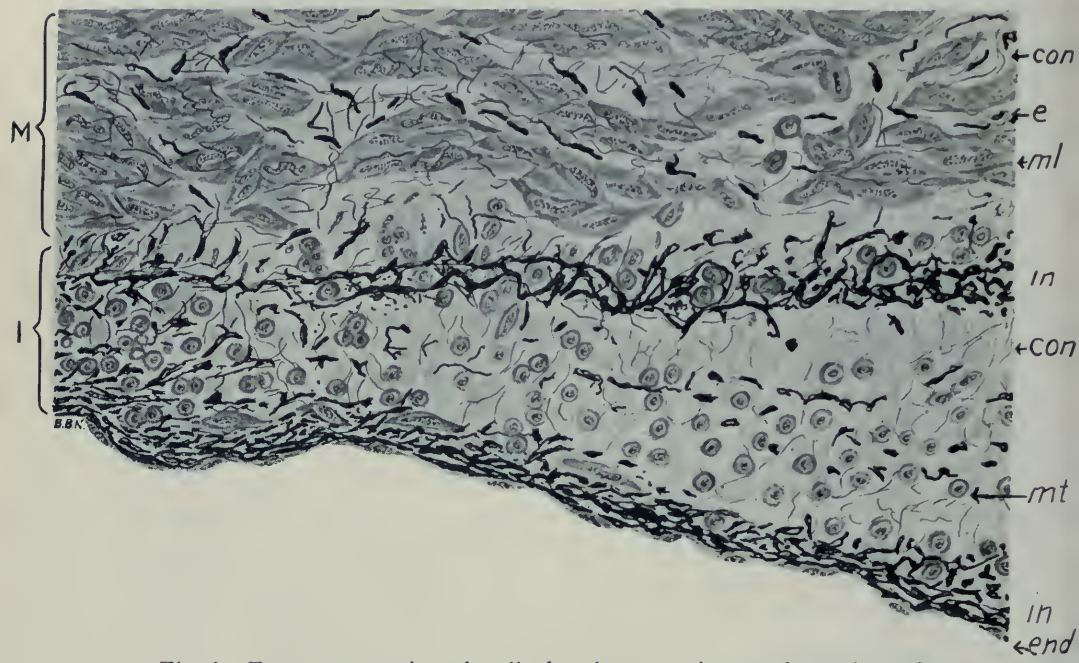

Fig. 1.—Transverse section of wall of saphenous vein near femoral opening; *M,* inner portion of media; *I,* intima, showing thickened area, which is more marked toward the right. The internal elastic membrane has been separated into two strata through an increase in muscle and connective tissue. *con,* connective tissue; *e,* elastic fiber; *end,* endothelial lining; *in,* internal elastic membrane (in two strata); *ml,* muscle in longitudinal section; *mt,* muscle in transverse section; (× 266).

7. Tomaselli: Sulle alterazioni delle tuniche venose nell processo varicoso, Gazz. d. osp., 1903.

8. Kashimura: Die Entstehung der Varicen der Vena saphena in ihrer abhängigkeit von Gefässnervensystem, Virchows Arch. f. path. Anat. **179.**

9. Marullaz: Contribution à l'étude anatomo-pathologique des veines variqueuses, Arch. de méd. expér. et d'anat. path., 1907.

10. Fischer, B.: Ueber Entzündung, Sklerose und Erweiterung der Venen mit besonderer. Berücksichtigung des elastischen Gewebes der Gefässwand., Beitr. z. path. Anat. u. z. allg. Path. **27.**

vein may have a wall thinner than the normal vein, but, when fixed, it is so contracted as to take on the gross appearance of an artery.

Regarding the finer structure, some writers report breaks in the internal elastic membrane, the gaps having been filled in with a delicate reticulum of elastic fibers (Epstein,[6] Tomaselli,[7] Marullaz,[9] Janni,[11] Kallenberger [12]). Many agree that there is a thickening of the intima through an increase in connective tissue (Epstein,[5] Remedi,[6] Marullaz,[9] Janni,[11] Kallenberger,[12] Kaufmann,[13] Seagliosi,[14] D'Antona [15]). Even hyaline changes have been reported (Kaufmann [13]).

The majority of investigators find the greatest change in the media and adventitia. Some state that there is an hypertrophy of the muscle in the media (Soboroff,[16] Pilliet,[17] Hodara [18]). They, however, give no proof in support of this view. If there is a true hypertrophy, I believe it occurs only in the early and less severe case. Unfortunately, there is no adequate data available in the literature. Many agree that there is atrophy of the muscle and an increase in the amount of connective tissue (Marullaz,[9] Fischer,[10] Janni,[11] Kaufmann,[13] Seagliosi,[14] Soboroff [16]). This is certainly true in the more severe and advanced cases. In the varix proper, I am confident that even the connective tissue itself undergoes atrophic changes. Those areas that have been thinned to a mere membrane have, as a rule, been subjected to a morbid process of long duration (Fischer,[10] Kallenberger [12]). The wall no longer contains true muscle. The three layers are fused into one dense connective tissue membrane somewhat resembling tendon (Fig. 2).

Some investigators find the amount of elastic tissue in the adventitia increased (D'Antona,[15] Hodara [18]). Others find the fibers stretched and reduced in number (Tomaselli,[7] Kashimura [8]). It is quite generally stated that the adventitia is thicker than in the normal, and the connective tissue increased in amount. Only a few references are made regarding muscle in this layer. An occasional mention is made concerning the vasa vasorum, but the majority of authors pass them by without notice. One writer states that they are subject to considerable

---

11. Janni: Arch. f. klin. chir. **61.**

12. Kallenberger: Beitrag. zur Pathogenese der Varicen, Virchows Arch. f. path. Anat. **180.**

13. Kaufmann: Trattato di anatomia pathologica speciale, Part 1, 1901.

14. Seagliosi: Ueber Phlebektasie, Virchows Arch. f. path. Anat. **180.**

15. D'Antona: Rendiconto scientifico-clinico di un quinquenio (1905-1909) della prima Clinica chirurgica di Napole.

16. Soboroff, S.: Untersuchungen über den Bau normaler und ektatischer Venen, Virchows Arch. f. path. Anat. **54.**

17. Pilliet: Note sur la structure de la parvi des veines variqueses, Compt. rend. Soc. de biol.. 1897.

18. Hodara: Cited by von Fischer.

variation, appearing well developed and dilated in some cases and rather inconspicuous in others (Kaufmann [13]).

Zancani's study, which comprises nineteen cases, is the most complete and careful piece of work I have seen. Since his findings, more than any other, are closely in accord with my own, I shall summarize his conclusions:

The changes in the saphenous vein near its opening into the femoral are less advanced than at a lower level. If the condition approaches that of the vessel below, it seems safe to say that the process is advanced and consequently an old one. In the varices, no progressive process was observed that would warrant one in speaking of an hypertrophied wall. The increase of connective tissue and disappearance of muscle are the most conspicious findings. It seems that the vessel wall can no more be considered as hypertrophied than could any other organ, when only the supporting connective tissue has increased while the more essential tissue elements, muscle cells and elastic fibers, have undergone marked regressive changes. In only one case, in which there was the history of a phlebitis previous to the ectasia, could any signs of an inflammatory process be found.



Fig. 2.—Transverse section of membranous portion of varix above knee. *ml,* wavy, unhealthy and attenuated smooth muscle cells containing dense elongated nuclei of irregular outline; *c,* connective tissue cell; *e,* elastic fiber; *end,* endothelium; (× 400).

Briefly the findings are: varying degrees of atrophy of the muscle; degeneration and fragmentation of the elastic fibers; an increase in the amount of connective tissue, and areas showing a rather delicate reticulum of elastic fibers, which probably marked the site of recent connective tissue formation. In places, this degeneration had advanced to such a degree that the muscle had disappeared entirely or had taken on the appearance of a homogeneous, dense connective tissue.

RESULTS OF INVESTIGATION

My study embraces eight sections taken from near the saphenous opening, above the knee, near the middle of the calf of the leg and just above the internal malleolus. The tissue was fixed in Helly's fluid or 10 per cent. formaldehyd. The two fixatives seemed equally satisfactory. Celloidin was used as the embedding agent. The sections were cut at from 15 to 20 microns and were stained with hematoxylin

and eosin, iron-hematoxylin, and Weigert's elastic tissue stains. The material was obtained from the operating room, most of it being fixed immediately on removal. So far as could be determined all were cases of true varicose veins with an insidious onset, excepting one, which could definitely be traced back to a femoral thrombosis.

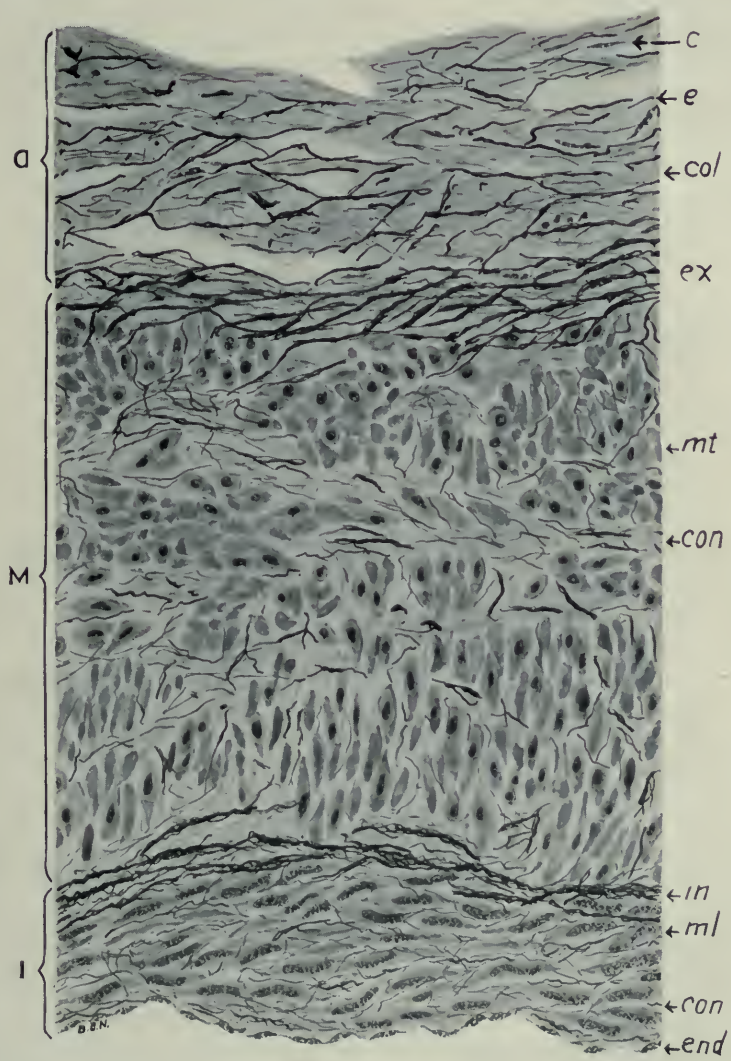

Fig. 3.—Segment of transverse section of ectatic saphenous above internal malleolus. *A*, adventitia; *M*, media; *I*, intima. Thickening internal to internal elastic membrane is evident; *con*, connective tissue; *col*, collagenous fiber bundle; *c*, connective tissue cell; *e*, elastic fiber; *ex*, external elastic network; *end*, endothelium; *in*, internal elastic membrane; *ml*, muscle in longitudinal section; *mt*, muscle in transverse section; (×266).

The marked variation, even in a single vein, is striking. At a given level, great variations in the picture may be found. This is largely because of the irregularity with which the vessel dilates. In the same section, portions of the vessel wall may be very thick, owing to an increase in the amount of connective tissue in all of the layers. Part of the thickening may be due to hyperplasia of the muscle. I am quite certain that, in a great many cases, there is such a process in the thickened areas of the intima (Figs. 1 and 3). Regarding the muscle in the media, there still remains some doubt. Judging from the general appearance, we are justified in thinking that there too hyperplasia has taken place. Whenever there is hyperplasia of the muscle, it is always in the earlier and less severe case. While the section may show a portion of the vessel wall thickened, there may be parts that

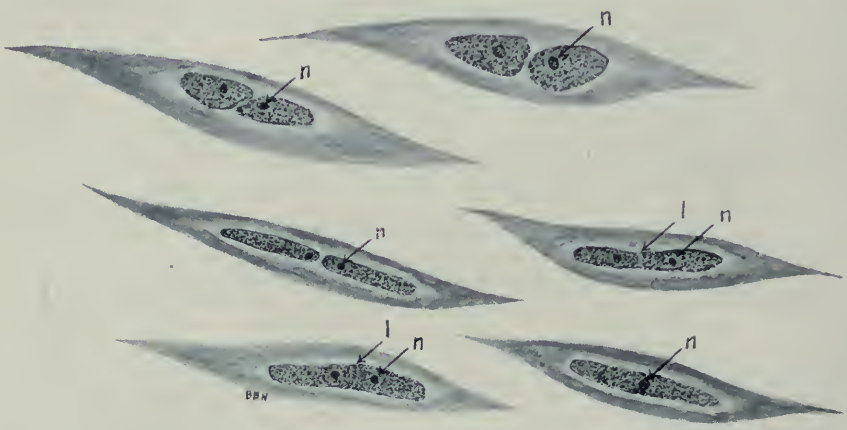

Fig. 4.—Muscle cells from thickened portion of intima showing various stages of nuclear division; *n*, nucleolus within nucleus; *l*, plane of division of nucleus; (× 1,000).

are thinned to a mere membrane. These two extremes are shown in Figures 2 and 3. Between these, there are all grades of variation. In the more severe case, in which the veins are enormously enlarged the whole wall has been reduced to a membrane.

My findings for the upper end of the saphenous near its opening into the femoral are closely in accord with those of Zancani [1] and others. The intima is thickened at intervals and contains a considerable amount of smooth muscle longitudinally disposed. In this muscle, I am able to show clearly amitotic division of the muscle nuclei (Fig. 4). This is always found in the thickened portions, where the muscle cells are very much more numerous than they are in the normal areas (Fig 1 *mt*). Thus far, I have been unable to find a reference to this in the literature.

The media at this level is by far the thickest coat and is composed of circular muscle embedded in connective tissue. There is a distinct internal elastic membrane and a less marked external elastic network. Both of these are composed of coarse elastic fibers, arranged more or less longitudinally. The adventitia is somewhat thinner than the media. It is composed largely of connective tissue and elastic fibers. At intervals, longitudinal smooth muscle may be seen. The striking feature at this level is the relatively healthy wall and the lack of thin areas.

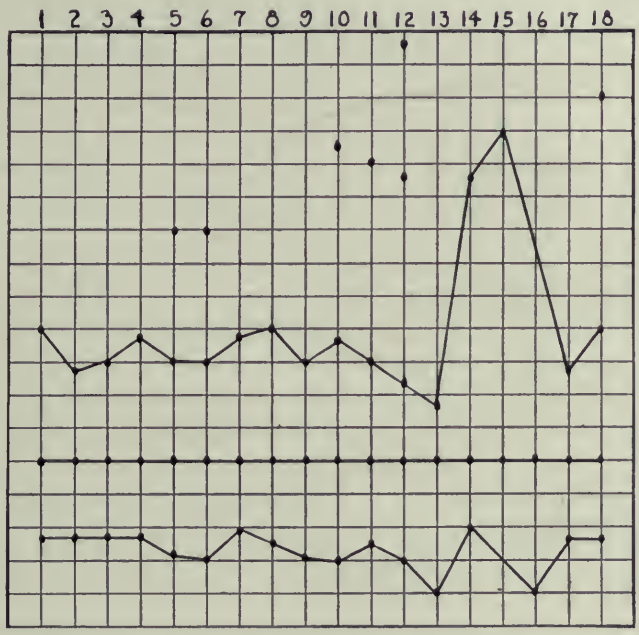

Fig. 5.—Location of valves in eighteen gross specimens of saphenous-femoral-iliac veins. The valves are represented by dots. The upper curve shows the first pair of valves in the femoral vein above the saphenous opening. This opening is represented by the middle curve (straight line). The lower curve plots the level of the first pair of valves found in the saphenous below its opening into the femoral. Vein 15 revealed no valve at level that corresponds to the lower curve. The absence of valves in vein 16 above the saphenous opening is no doubt due to an old recanalized thrombus. The ruled spaces on the ordinates represent centimeters.

More distal to the saphenous opening, there is a less healthy appearance of the muscle, a greater amount of connective tissue, a less marked and a less complete internal elastic membrane, and perhaps a more general thickening of the intima. This thickening may be internal or external to the internal elastic membrane. Near the middle of the calf of the leg, the longitudinal muscle in the adventitia may or may not be found

Just above the internal malleolus the picture is markedly different. The same layers as above occur; however, the arrangement of the muscle and connective tissue is altered. Instead of the muscle in the media being circularly arranged, it is disposed longitudinally. The elastic fibers in the elastic layers and the collagenous fibers in the adventitia are for the most part circularly arranged. Neither do we find muscle in the intima or in the adventitia.

The gross specimens, including eighteen veins, give the following data (Fig. 5): In every case except one, there occurred a pair of valves in the external iliac about 3 cm. above the saphenous opening. Six veins had a second pair of valves, from 7 cm. to 10 cm. above the saphenous opening. One vein even revealed a third pair of valves just below the bifurcation of the common iliac. In every case, there was a pair of valves guarding the saphenous opening. About 2.5 cm. below the opening, a second pair was constantly found. Below these, there was no regularity of arrangement. The most significant fact regarding the valves in the saphenous, below its opening into the femoral vein, was the regularity with which they guarded the orifices of the branches opening into the saphenous. Almost without exception, there was a pair of valves just within the mouth of the entering branch. In the few instances in which this was not true, a pair of valves was found in the saphenous just below the orifice of the branch; which amounts to having them in the mouth of the vein itself.

As might be expected, the frequency, the size and the location of branches and anastomoses showed no regularity, and therefore are of little significance.

REPORT OF CASES

Case 1.—C. R. W., man, white, aged 24, had extensive varices on both legs, those on the left being the more advanced and extensive.

Microscopic Findings.—Internal saphenous vein near femoral opening. Outstanding features of vessel wall: Thickness was 1.3 mm. The intima was slightly thickened in certain limited areas. There were a relatively great number of coarse elastic fibers. Near the media, the adventitia was composed of alternating layers of coarse elastic fibers and large bundles of collagenous fibers, the latter for the most part being circularly arranged.

Intima: This was 0.2 mm. or less in thickness. In places, it showed slight thickening, apparently between the layers of the internal elastic membrane. Thus, it appeared double. The fibers in this membrane were largely of the coarse variety, longitudinally disposed. The thickened portion showed a marked increase in connective tissue and longitudinally disposed smooth muscle cells, many of which showed amitotic division of the nucleus.

Media: This layer was 0.7 mm. in thickness, and composed of small bundles of circularly disposed smooth muscle cells, alternating with longitudinal strata of collagenous connective tissue. The coarser elastic fibers were longitudinally disposed; the more numerous delicate fibers, some of which have the form of spirals, appeared irregularly arranged. The muscle nuclei showed a characteristic spiral form, but otherwise appeared normal.

Adventitia: This was 0.6 mm. in thickness. An occasional small group of longitudinally disposed smooth muscle cells was observed. Only that portion of the layer adjacent to the media remained. This was composed of large circularly and obliquely arranged elastic fibers alternating with bundles of circularly disposed collagenous fibers.

Internal saphenous vein from calf of leg. Outstanding features of vessel wall: The thickness was 1.2 mm. corresponding to that of an artery having a lumen of equal size. The internal elastic membrane was distinct. The external elastic network was in the inner portion of the adventitia. The intima was thickened in certain areas. The muscle of the media was circularly disposed.

Intima: This was 0.3 mm. or less in thickness. Areas showed thickening external to the internal elastic membrane, and thickened areas showed many radially and longitudinally disposed smooth muscle cells. There were many coarse elastic fibers longitudinally disposed; also many delicate ones irregularly disposed.

Media: This layer was 1.1 mm. in thickness, with irregular bundles of smooth muscle cells alternating with strata of connective tissue. The latter contained many coarse, wavy elastic fibers, the majority of which were disposed longitudinally. The numerous delicate elastic fibers were irregularly arranged. The outlines of the muscle cells were poorly defined. Those of the outer portion of the layer were more distinct, and the cells healthier in appearance.

Adventitia: The thickness was 1.1 mm. The external elastic network in the inner part of this layer was composed of alternating strata of coarse elastic fibers and bundles of collagenous fibers, the majority of which were circularly disposed. The outer portion of the layer was composed of connective tissue, through which passed many irregularly arranged coarse and fine elastic fibers. No muscle could be seen.

Internal saphenous vein above the internal malleolus. Outstanding features of vessel wall: The thickness was 0.5 mm. The muscle of the media was longitudinally disposed. When compared with the vessel near the femoral opening, the wall was seen to be much thinner in proportion to the size of the lumen. This could probably be attributed to the longitudinal disposition of the muscle in the media at this level. The adventitia was slightly less than one half the entire thickness of the vessel wall.

Intima: This was only slightly thickened in certain areas. There was an incomplete internal elastic membrane, the fibers of which were for the most part circularly disposed. The thickened areas were internal to the internal elastic membrane. These areas showed no muscle cells, and the connective tissue resembled the embryonal type.

Media: Thickness was 0.3 mm. The muscle cells were quite uniformly arranged in groups of from two to four cells longitudinally disposed. The connective tissue was somewhat increased as compared with higher levels in the vessel wall. In certain areas, the muscle cells were greatly elongated and appeared to be undergoing transformation into a tendinous tissue. In other areas, the muscle looked quite healthy. Many elastic fibers were irregularly disposed. The coarser elastic ones and the collagenous fibers, however, took a circular course.

Adventitia: This layer was 0.2 mm. in thickness. At the boundary between the media and the adventitia, there was a dense network of coarse elastic fibers circularly arranged. In the outer parts of the adventitia, the elastic fibers were curled and irregularly disposed. The collagenous fibers appeared in large and irregularly disposed groups.

Case 2.—C. C., a man, white, aged 55, had large varices in the right leg extending up to a short distance below the inguinal ligament. There were a few small varices in the left leg.

Microscopic Findings.—Internal saphenous vein near femoral opening. Outstanding features of vessel wall: The thickness of the wall was 0.9 mm. The internal elastic membrane was incomplete. The media was composed of alternating bundles of muscle cells and connective tissue, circularly disposed. There was a relatively small amount of elastic tissue. The adventitia was relatively thin, the outer coat probably having been torn away at operation.

Intima: This layer was 0.4 mm. in thickness, uniformly thickened, and composed of isolated longitudinal smooth muscle cells embedded in connective tissue, which was poor in elastic fibers. The nuclei of the muscle cells showed many stages of amitotic division. The thickening was internal to the internal elastic membrane, which was incomplete. The elastic fibers were generally circularly disposed, while the collagenous fibers took an irregular longitudinal course.

Media: The thickness of this layer was 0.5 mm. and it was composed of relatively large bundles of circuarly disposed smooth muscle, between which there was a relatively small amount of connective tissue. There were a few irregularly disposed elastic fibers. The collagenous fibers for the most part were arranged longitudinally and radially. The nuclei of the muscle cells appeared somewhat shortened in consequence of their spiral form.

Adventitia: There was little or no external elastic network present, and no muscle. The layer was very thin, probably having been lost during operation or previous to embedding.

Internal saphenous vein above knee. Outstanding features of vessel wall: The thickness of the wall was from 0.1 to 0.8 mm. The vessel was thinned out on one side to the proportions of a relatively thin membrane (0.1 mm.). The remainder of the wall had about the same appearance as that of the vessel at a higher level. The muscle was circularly disposed. The strata of connective tissue were relatively more prominent. The intima was thickened over the thick portions of the vessel wall. The internal elastic membrane was incomplete and almost lacking, while the external elastic network was quite complete.

Intima: This was 0.1 mm. or less in thickness. The thickened portions of this layer were composed largely of isolated smooth muscle cells embedded in an irregular connective tissue network, which was poorly supplied with elastic fibers. The nuclei of other muscle cells had the characteristic vacuolar area surrounding them. Stages of amitotic division could be seen in many of the nuclei.

Media: Thickness was 0.4 mm. The thicker parts of the vessel wall contained a media composed of bundles of circularly disposed smooth muscle cells, separated by incomplete strata of connective tissue, the fibers of which, for the most part, ran longitudinally. The connective tissue was slightly increased in amount over that found at higher levels. The coarse elastic fibers were sparse and were arranged longitudinally; the more delicate fibers, also sparse in numbers, were irregularly disposed. The nuclei of the muscle cells were characteristically spiral in form and had clear areas about them. The thin portion of the wall somewhat resembled tendon (Fig. 2). The nuclei of the muscle cells were long, dense, narrow and wavy.

Adventitia: This was 0.3 mm. thick, and relatively thin over the thick portions of the vessel wall. It was composed of large elastic fibers and bundles

of collagenous fibers, arranged for the most part longitudinally. A few bundles of longitudinally disposed smooth muscle cells could be seen. No adventitia was discernible in those parts that had become thinned.

Case 3.—W. W., a man, colored, aged about 41, was subjected to a knee-joint amputation, Oct. 28, 1921. At this time, the specimen for study was obtained.

Microscopic Findings.—Internal saphenous vein from calf of leg. Outstanding features of vessel wall: The wall was 1.6 mm. in thickness. The vessel had the proportions of an artery, a very thick wall and a relatively small lumen. The intima appeared somewhat thickened and thrown into folds. This condition was in all probability due to contraction of the muscle in the media, which was very thick and contained a relatively small amount of connective tissue. The internal elastic membrane was incomplete. The adventitia was very thin.

Intima: This layer was 0.1 mm. thick. There was no distinct internal elastic membrane, but in its place there were two or three relatively incomplete layers of coarse elastic fibers, alternating with bundles of collagenous fibers, longitudinally disposed. The intima was thrown into deep folds. There were a few smooth muscle cells, none of which showed amitosis or clear areas about their nuclei. The muscle cells were cloudy and poorly defined.

Media: The thickness was 1.1 mm., and there was a relatively small amount of connective tissue, only an occasional incomplete lamina being discernible. The muscle cells were cloudy and unhealthy in appearance. Each cell appeared to be enveloped by a delicate connective tissue reticulum, the elastic fibers of which were very fine, and almost as numerous as the collagenous fibers. The nuclei of the muscle cells were in the form of a close spiral.

Adventitia: This was 0.4 mm. in thickness, relatively narrow, and composed of alternating lamina of coarse elastic and collagenous fibers longitudinally disposed. An occasional small group of longitudinal smooth muscle cells could be observed. This tissue, however, was less conspicuous here than at higher levels in the leg.

Case 4.—X., a man, white, aged about 60, presented a varicose condition of long standing, quite extensive and severe. There was no history of a phlebitis or thrombosis. No family history was obtained.

Microscopic Findings.—Internal saphenous vein near femoral opening. Outstanding features of vessel wall: Thickness was 0.9 mm. The intima was slightly thickened in areas. There was a relatively great amount of coarse elastic fibers. At the outer edge of the media, the adventitia was composed of alternating layers of coarse elastic and large bundles of collagenous fibers.

Intima: The thickness was from 0.1 to 0.2 mm. In places, this layer was slightly thickened internally to the internal elastic membrane. The thickened areas were composed of fine elastic fibers and small bundles of collagenous fibers, irregularly disposed, between which were interspersed many smooth muscle cells. These muscle cells were less numerous in the unthickened areas. The clear area about the nucleus was quite marked. Many of the nuclei showed amitotic division.

Media: Thickness was 0.3 mm. This layer was composed of small bundles of circularly disposed smooth muscle, alternating with strata of connective tissue, the collagenous fibers of which were longitudinally disposed. The coarser elastic fibers were longitudinal, while the more numerous delicate ones were irregularly arranged. The outline of the muscle cells was poorly defined; the nuclei were spiral in form for the most part, and many nuclei had a relatively large clear space surrounding them.

Adventitia: This layer was 0.4 mm. thick. An occasional small group of longitudinally disposed smooth muscle cells, as well as a few rather isolated cells, could be observed. There seemed to be a slight increase in the amount of muscle as compared with other specimens. Some of the cells had the characteristic vacuolar area about their nuclei. Nearest the media, there were alternating layers of coarse elastic fibers and large bundles of collagenous fibers, the majority of which were circularly disposed.

COMMENT

As indicated above, my purpose in this investigation is to endeavor to throw some light on the etiology of varicose veins. In addition to the histopathology and the gross picture, both of the normal and the abnormal vein, there is the experimental side of the problem. Zancani[1] undertook some experimental work on dogs. He made five end-to-end anastomoses between the proximal end of the severed femoral artery and the distal end of the femoral vein. Only two of his animals survived over forty-eight hours. One of these died on the twelfth day, the other was chloroformed on the seventy-ninth. Of the two, only the latter was of experimental value. In brief, Zancani found that the veins had become greatly distended under the arterial blood pressure, which was 110 to 120 (mean). On sectioning, the vessel gave one the impression of an artery. Microscopically, there was apparently considerable hypertrophy, especially of the media. The muscle was greatly increased in volume, while the connective tissue was relatively scanty. Zancani concluded that there was a true hypertrophy and that therefore varicose veins were not due primarily to venous pressure or incompetent valves, but to some toxic substance in the venous blood. This toxin he thought could be derived either from intestinal absorption or metabolic processes. If this were true, we would expect varices to occur more often in the upper extremities. As a matter of fact, their infrequency in these parts can readily be explained on a purely mechanical basis.

In view of the siphonic action of the column of blood extending from above the level of the elbow to the opening of the superior vena cava into the right atrium, it is quite obvious that only a slight static pressure could be exerted on the walls of the veins in the forearm. This is almost conclusive proof that there is a static-pressure element concerned in the development of varicose veins. This factor, however, is not the primary cause. Zancani's experimental findings are obviously not conclusive. His experiment did not continue for a sufficient length of time. Had it been allowed to continue a year or more, I am inclined to believe there would have been an atrophy instead of an hypertrophy. The condition obtained was probably similar to an early varicose process.

In an extensive search of the literature only one other piece of experimental work could be found. This was done at the Johns Hopkins Hospital by Dr. S. H. Watts,[19] who was experimenting with the suturing, transplantation, and anastomosing of blood vessels. He made a number of arteriovenous anastomoses both in the neck and the hind legs of dogs. Most of his anastomoses, especially those in the neck, were successful. Some of the experiments continued for as long as four months. He gives a histologic description of the veins of the neck, after they had been subjected to arterial blood pressure for varying lengths of time. Unfortunately, however, the dilated saphenous was not described histologically. During his study he observed that, at the end of three hours, the saphenous vein in the foot could be felt to pulsate as an artery. This is quite significant when one stops to consider that for nearly three hours the valves were withstanding a pressure of at least 110 mm. of mercury, which represents about 148.5 gm. per square centimeter. On the other hand, the weight of a column of blood 1 meter high (comparable to the length of the saphenous vein) would be only about 7.4 gm., which is about one twentieth as much as the arterial pressure.

When the physics along with the physiology of the circulation of the lower extremities is considered, one is confronted with several interesting facts. The motive force that drives the blood through the veins may be resolved into three factors: (1) arterial pressure transmitted through the capillaries into the venules and veins; (2) a very slight negative pressure exerted at the orifice of the inferior vena cava, and (3) more or less pumping action resulting from contraction and relaxation of the muscle groups of the leg. Of these three, the first is of greatest importance, for the circulation can be maintained without either the second factor or the third. However, the converse of this does not hold.

The negative pressure created through the respiratory excursions of the thoracic wall is slight, and can for all practical considerations be neglected. While the pumping action of the muscles is quite important, it alone cannot maintain the circulation. All is dependent on the arterial pressure exerted by the ventricles of the heart. The muscle action becomes effective only when the blood has been driven into the lower branches by the arterial pressure, thus placing it above some of the lower valves. In connection with this pumping action of the muscles, the valves serve one of their most important functions. It is due to their presence that the blood is not forced downward. In the case of an absence of valves, the muscles would actually hinder circulation rather than aid it. As it is, however, the moment the pressure

19. Watts, S. H.: The Suture of Blood Vessels, Bull. Johns Hopkins Hosp. **18**:153-177 (May) 1907.

exerted on the vessel wall by the contracting muscles exceeds that exerted by the arterial pressure, the valves below the point at which the muscles are acting close, and the muscular pressure forces the blood to a higher level. During the short interval that the valves below the contracting muscles are closed, the weight of the column of blood above is taken off the vessel wall; and only during this interval is this true. One can readily understand that when the leg is at rest as regards muscular activity, the venous blood is raised only by virtue of the arterial pressure transmitted through the capillaries. Under such circumstances, the valves cannot possibly take any of the static pressure off the vessel wall; for, in order to get the blood into the heart, the arterial pressure must lift a column of blood extending from the foot to the opening of the inferior vena cava; and so long as there is any flow toward the heart the valves of necessity must be open along the entire length of the blood stream. When the valve flaps are thrown back, they can afford no support to the column of blood above.

A further function of the valves is that of directing the blood toward the heart. As stated above, each of the branches entering a larger vessel has its mouth guarded by a pair of valves. Were it not for these, the blood in the main channel might be forced through the branches and anastomoses, thus imposing more or less delay in reaching the heart. This would be especially true during muscular activity, when the pressure of the contracting muscles is exerted equally in all directions. If for any reason the valves should become incompetent, the blood would be greatly retarded in reaching the heart, for it would tend to be thrown back through smaller branches and anastomoses. Furthermore, the pumping action of the muscles would be lost, or might even become an adjunct to the morbid process. Those branches which are unprotected by valves would receive much of the blood, which under normal conditions would be forced to the heart. Under such circumstances, there would be a more or less vicious cycle set up in the veins of the leg. The impure blood would be retained in contact with the vessel wall for a longer time and, according to Zancani [1] and others, might actually produce injury by reason of the impurities which it carries. Aside from this, the sluggish and retarded circulation would impair the nutrition of the vessel wall itself. The moment that perfect nutrition begins to fail, the vessel musculature will fatigue more easily; and, following fatigue, dilatation ensues. As dilatation increases, the nutritional condition becomes progressively worse, and thus the vicious cycle is established.

CONCLUSIONS

1. Since the saphenous opening is always protected by two or more valves, and the saphenous wall must at least intermittently bear the

weight of the contained column of blood, it appears that the primary cause for varicose veins is not valvular insufficiency and static pressure.

2. On the other hand, valvular insufficiency, which allows an ill-directed and retarded blood flow, is a very important secondary factor.

3. The infrequency of varices in the arms, where the weight of the column of blood in the veins is from a level only a little above the elbow, proves that static pressure is a secondary factor. Similarly, the relatively less severe process in the upper saphenous, as compared with lower levels, supports this conclusion.

4. The primary cause may be mechanical, trophic, inflammatory or toxic.

5. Valves in the veins of the leg do not relieve the vessel wall of the static pressure exerted by the contained column of blood.

6. During the brief interval of contraction of the muscles of the leg, the static pressure of the column of blood above the site of contraction is not exerted on the vessel wall below. Even during this interval the vessel wall is not relieved of any pressure, for the arterial pressure in the lower part of the vessel must be greater than the static pressure normally exerted by the column of blood in the saphenous.

7. The chief functions of the valves are: (*a*) to aid the muscles as they contract in pumping the blood toward the heart; (*b*) to direct the blood toward the heart; (*c*) to protect the openings of small branches from a backward flow, and (*d*) to prevent blood from being forced backward by intermittent muscular or mechanical pressure.

8. An erect posture, demanding little activity of the legs, tends to induce varicosis, or aggravates the condition, if already present.

THE PHYSIOLOGY OF AN ARTERIOVENOUS FISTULA *

EMILE HOLMAN, M.D.

BALTIMORE

Cardiac hypertrophy and proximal dilatation of the artery have been so frequently associated with arteriovenous fistulas that it has long seemed highly probable that there must be some causative relationship between the two. That such a relation exists has been denied by clinicians, both ancient and modern, and the association of the two conditions clinically has been attributed to a coincidence. It was a problem that aroused the interest of the late Professor Halsted many years ago, and was for him a subject of constant speculation. Speaking before the American Surgical Association [1] in 1918, he said:

> If the assumption is correct that the heart dilates in consequence of the fistula, it is important that the fact should be brought to the attention not only of surgeons but also of pathologists and internists who apparently have altogether overlooked it. . . . When a causative relationship . . . shall have become convincingly established, we may find that some unexplained dilations of the heart are referable to hitherto undetected changes in the walls and lumen of the blood vessels.

Dr. Halsted's interest in the subject prompted him to collect all the clinical evidence bearing on the subject in the 447 arteriovenous fistulas of the larger vessels recorded in the medical literature of the world. These data, published by Dr. Curle L. Callander,[2] make an absorbingly interesting story of a comparatively rare clinical picture. The article carries an excellent bibliography.

Among these 447 cases, there occurred fifty-seven instances of proximal dilatation of the artery, a percentage of 12.7. Nine of the twenty-one cases studied in the Johns Hopkins Hospital showed proximal dilatation, a percentage of 43. It is obvious that observations

---

* Read at a meeting of the Johns Hopkins Hospital Medical Society, Nov. 20, 1922.

* From the surgical clinic of the Johns Hopkins Hospital and the Hunterian Laboratory of Experimental Surgery.

1. Halsted, W. S.: Cylindrical Dilatation of the Common Carotid Artery Following Partial Occlusion of the Innominate and Ligation of the Subclavian, Tr. Am. S. A. **36**:501, 1918; Surg., Gynec. & Obst. **27**:547 (Dec.) 1918.

2. Callander, C. L.: Study of Arteriovenous Fistula with an Analysis of Four Hundred and Forty-Seven Cases, Johns Hopkins Hosp. Rep. **19**:260, 1920; Ann. Surg. **71**:428 (April) 1920.

in the 447 described cases are probably incomplete. William Hunter [3] in 1757, in giving us our first description of an arteriovenous aneurysm, noted proximal dilatation in the two cases recorded by him.

Broca [4] has described one of the most remarkable instances of proximal dilatation of the artery to be found in the literature:

> The wall of this brachial artery is extremely thin, hardly one half millimeter in thickness; semitransparent, flabby and collapses like the wall of a vein . . . When flattened out, the vessel has a circumference of 80 mm. When the artery was distended by means of a cone (as it would have been if filled with blood) the circumference was 86 mm., much larger than the humerus. Below the arteriovenous communication, the artery suddenly narrowed and all at once resumed its normal caliber. . . .

In a symposium on the subject of arteriovenous aneurysm at the Radcliffe Infirmary, Oxford, England, March 26, 1915, at which I was fortunate enough to be present, Sir William Osler [5] hesitated somewhat to attribute cardiovascular changes to the presence of the fistula:

> The changes in the arteries on the proximal side of the lesion are less striking, but sooner or later sclerosis occurs with dilatation, and sometimes with saccular aneurysm opposite the orifice of communication. Even within two months of the injury, the femoral artery may be felt to be larger and with stronger pulsation (Paignton case). Remote effects on the general circulation are rare, particularly in aneurysms of the head and arms. One of my patients (Case 3) died from heart disease which may have had some connection with his long-standing lesion. In the leg, progressive dilatation of the vessels may lead to serious effects. In the case of Captain Mosher (reported in Lagarde's Gunshot Injuries, 1914, p. 281), wounded in the middle of Scarpa's space in 1898, at the time of death (1911) the dilated arteries extended from the bifurcation of the common iliac to the lower third of the thigh. Hypertrophy of the heart followed, and death from progressive failure of the circulation.

In the 447 recorded cases, cardiac dilatation and hypertrophy, of more or less marked degree, are noted in sixteen instances, accompanied occasionally by auricular fibrillation and myocardial decompensation. Six of our twenty-one cases showed enlargement of the heart, a percentage of about 28 as compared to a published percentage of 4. Two of Dr. Halsted's cases exhibited an enormous cardiac hypertrophy and dilatation, together with auricular fibrillation and evi-

---

3. Hunter, William: The History of an Aneurysm of the Aorta, with Some Remarks on Aneurysms in General, M. Observations & Inquiries **1**:323, 1757; Further Observations Upon a Particular Species of Aneurysm, ibid. **2**:390, 1762.

4. Broca: Anévrysme artério-veineux du pli du coude. Enorme dilatation des artères humérale, axillaire et sous-clavière. Rupture du sac. Amputation, Bull. et mém. soc. de chir. de Paris **4**:392, Series 2, 1864.

5. Osler, William: Remarks on Arteriovenous Aneurysm, Lancet **1**:949, 1915.

dences of chronic passive congestion, although previous to the formation of the fistula they had been entirely well.

Among the large number of interesting aneurysms treated at the Johns Hopkins clinic, the following case revealed certain phenomena which undoubtedly throw light upon the question of cardiac hypertrophy and proximal dilatation of the artery.

REPORT OF CASE

History.—C. W., a West Virginia miner, aged 41, was admitted to the Johns Hopkins Hospital, Aug. 9, 1922, complaining of vomiting, shortness of breath and weakness. He had been perfectly well until the age of 16, when he accidentally shot himself with a revolver carrying a 38 caliber bullet. The bullet entered the left thigh 4 inches above the knee, the knee being flexed at an angle of 45 degrees. Profuse bleeding from the wound of entrance followed the shot, the blood spurting 2 feet. A tourniquet was applied at once. Slight oozing continued until a physician removed the bullet, which was found lying beneath the skin on the anterolateral aspect of the leg, about 3 inches below the knee. A dressing was applied to the leg. There was a slight stain on the bandage after the removal of the tourniquet, but no further profuse bleeding. There was no noticeable swelling of the knee or of its under surface, and the patient could not recall any discoloration of the skin. He was able to stand on the leg immediately after the accident, but on the physician's advice remained in bed for a week and returned to work in the mine within ten days.

The patient apparently suffered no difficulty until five years previous to admission, when he was compelled to give up underground mining because he could not endure the bad air of the mines; he felt "knocked out" after only a short period of work. He began to be troubled with abdominal pains, which he attributed to the stomach. He was able, by changing to an open-air job, to do a full day's work during the next three years. For the last two years, he had done very little work, and none at all since January, 1922, when vomiting, extreme weakness, shortness of breath and smothering spells around the heart confined him to bed and kept him incapacitated until his admission to the hospital.

He could not remember the onset of the thrill which he himself felt around the knee. It had been present a long time, and he believed that it had appeared coincidentally with the swelling of the leg, which he noticed soon after the accident, apparently beginning just above the knee and extending gradually down the leg. This swelling appeared to be an actual increase in the size of the leg. The patient had noticed that his heart pounded rather forcibly, causing considerable distress in his head accompanied by a feeling of dizziness and faintness whenever he stooped over to raise things from the ground. He had also experienced marked discomfort in the epigastrium, which was accentuated with each beat of the heart.

Examination.—The patient was a muscular, well developed man, with slight cyanosis of the face, but no respiratory distress. The pulse rate was 97; respiration, 24; blood pressure (left arm), systolic, 118, diastolic, 55. The erythrocytes numbered 3,844,000; leukocytes, 5,700. The hemoglobin was 70 per cent.; Wassermann reaction, negative; urine, negative.

The first of many striking features was the extraordinary difference in size of the two limbs, the left thigh and lower leg being approximately half again as large as the right (Fig. 1); another, the difference in the skin of the two legs, the right being perfectly normal in appearance throughout, the left thigh showing numerous small, dilated venules over the posterior and anterior surfaces, from Poupart's ligament down to the toe, these venules being in the skin. In addition, there were numerous large, dilated veins in the subcutaneous tissue of the lower leg, and on close inspection it was evident that these veins were pulsating, an observation which was corroborated by palpation and by sphyg-

Fig. 1.—Appearance of patient, showing difference in size of the two legs, with measurements before and after operation, and also the remarkable difference in the size of the right and left femoral arteries before operation. Measurements are given in centimeters. Those taken after operation are in parenthesis.

mographic records. There was also a tan, spotted, freckled discoloration of the skin of the anterior surface of the lower leg and dorsal surface of the foot, such as one finds in varicose veins. The toes on the left showed a dark blue, purplish discoloration.

The third striking feature was the very forceful beating of the heart, which fairly shook the bed, lifted the cover, and caused a distinct movement of the entire thorax and abdomen with each beat. The visible pulsation over the precordial area was greatly increased, the region of relative cardiac dulness measuring 16.5 by 5 cm. The apex beat was in the fourth interspace, 15 cm. from the median line. There was a very forceful impulse at the apex, a well marked shock of the first sound, with a vibratory sensation following the shock. A soft systolic murmur accompanied the first sound all over the body of the heart. The extraordinary pulsation noted just below Poupart's ligament on the left was found, on palpation, to be due to a greatly dilated femoral artery, which measured approximately 2 cm. in diameter. The right femoral artery measured approximately 0.6 cm. in diameter (Fig. 1). The dilated portion of this artery could be followed well down the thigh to a point where it entered the aneurysmal swelling in the popliteal space. About 2 inches below Poupart's ligament, there was noted, with each beat of the heart, a lifting of the skin along the course of a branch of the femoral artery, which was probably the lateral circumflex. The pulsation noted above the knee in the artery was visible below the knee in the greatly enlarged surface veins, which had formed small pulsating lakes of blood in the subcutaneous tissue. Above Poupart's ligament, there was a lifting of the abdominal wall with each heartbeat, and on palpation a large, strongly pulsating common iliac and abdominal aorta could be definitely made out. Liver dulness extended a finger's breadth below the costal margin on deep inspiration. The liver did not seem enlarged and no pulsation could be felt in it.

In the popliteal space (Fig. 2), there was a soft, pulsating, lemon-sized mass, which on palpation gave the characteristic thrill found in arteriovenous fistulas. This could be followed along the course of the artery into the abdomen, almost to the umbilicus, and downward as far as the ankle. With the stethoscope, a loud, whirring noise was heard, with systolic intensification. This bruit, which was heard best at the upper pole of the mass, extended along the vessels to the ankle and upward almost to the xiphisternum. There was no bruit over the liver area. The area of swelling in the popliteal space measured 6 cm. wide and 7 cm. in the vertical diameter. Pressure at the point of the greatest thrill, namely, at the superior pole of the swelling, resulted in complete obliteration of the continuous thrill, and presumably of the fistula.

This obliteration of the fistula was followed immediately by a remarkable reduction in pulse rate. Numerous observations were made, and a pulse which ranged around 88 before obliteration was reduced to 56 immediately on closure of the fistula. It was also noted that there was a definite increase in the force of the pulse immediately after obliteration of the fistula. This observation was confirmed by a series of blood pressure readings, which will be discussed later. Below the pulsating mass, an artery was felt leading down between the heads of the gastrocnemius muscle, considerably smaller in size than the artery which entered the mass at its upper apex. The posterior tibial pulse on the left was absent when the fistula was open, but on obliteration of the fistula a definite pulse was felt posterior to the internal malleolus. With the fistula open, there was a very slight pulse to be felt in the dorsalis pedis artery, which was markedly increased by obliteration of the fistula. There was a good posterior tibial and dorsalis pedis pulse on the right.

The reduction in pulse rate and increase in blood pressure were produced also by simply obliterating the left femoral pulse just below Poupart's ligament. An interesting feature was a recorded blood pressure in the right leg of 160 systolic, 86 diastolic; and in the left leg of 220 systolic, 70 diastolic. The high systolic reading on the left was of necessity taken with obliteration of the left femoral pulse (with closure of the fistula), and the diastolic reading was obtained with the fistula open.

Fig. 2.—Appearance of the patient, showing the position of the aneurysm, the pulsating venous lakes (circled) and the difference in size of the two legs. The site of the fistula is indicated by a cross.

The surface temperature was remarkably increased on the left lower leg and foot as compared to the right, there being a recorded difference of as much as 2 degrees (F.). The calf of the leg felt hot, and the patient stated that the left leg always felt warmer than the right.

The following special examinations were made: A teleroentgenogram, August 17, gave a combined measurement of 15.8 cm. (Fig. 3). An electrocardiogram revealed a normal mechanism. A second electrocardiogram (Fig. 4) was taken to illustrate the very significant changes in the pulse rate which occurred on obliteration of the fistula. Before closure, the cardiac rate averaged 72, with a P-R interval of 0.18. After closure of the fistula, the heart rate fell as low as 35, with a P-R interval of 0.20.

Fig. 3.—Teleroentgenogram taken before operation.

Numerous observations were then made to determine the variations in the general blood pressure on closing and on opening the fistula (Fig. 5). Within five seconds after the fistula was closed by digital pressure, the general systolic blood pressure rose from a uniform level of 120 to 164, dropping within sixty seconds to a uniform level of 126. When the fistula was opened, the general blood pressure dropped 30 points, to 96, returning within twenty seconds to a level of 116.

The same phenomenon was noted with respect to diastolic pressure; an immediate rise from 66 to 90 was noted on closing the fistula, with a fall to a constant level of 84 within forty seconds. A drop to 48 was noted on opening the fistula, with a rapid return to the usual level of 66. Figure 5 is one of numerous identical observations.

Operation.—August 31, the patient was operated on by me, with the assistance of Dr. Mont R. Reid, formerly of the Johns Hopkins Hospital, and now at the Cincinnati General Hospital. The pulsating mass in the popliteal space proved to be a large sacculation of the vein just distal to the arteriovenous opening. (Fig. 6). Running distally from this sacculation was a vein greatly diminished in size, 0.8 cm. in diameter. The exposed portion of the vein proximal to the fistula was greatly dilated, with another sacculation above the first. Above these sacculations, the vein had a diameter of 1.8 cm. The artery was dilated, and its walls were markedly thinned, with a diameter, proximal to the fistula,

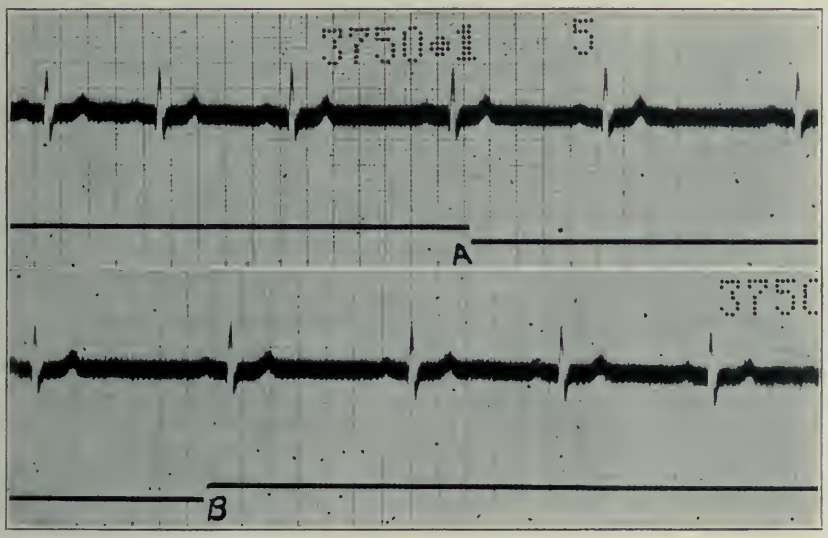

Fig. 4.—Electrocardiogram recording the effect of closing fistula (*A*), and opening fistula (*B*). Before closure, the cardiac rate averaged 72 with a P-R interval of 0.18; after closure, the heart rate fell as low as 35 with a P-R interval of 0.20. The mechanism is normal. (Record in Lead I.)

of 1.8 cm., and a distal diameter of 0.8 cm. The fistulous opening led directly from the artery into the vein and had a diameter of 2.1 cm. as measured from the outside.

The operation was performed under a tourniquet. The artery and vein were separated, and the two slitlike lateral openings closed with fine silk, reestablishing the lumen of each vessel. The wound was closed with silk, and healed by first intention. Drainage in vascular surgery must be scrupulously avoided.

Course.—Immediately after operation, a vigorously pulsating posterior tibial artery could be felt on the left, considerably stronger than on the right. Nine hours after operation, the patient said he felt much better than at any time previously, the distress of the vigorous pulsation in his head, which he had

felt continuously before, having disappeared. Within five days, there was a marked change in the patient's general wellbeing. The precordial heave, which formerly shook the bed, had disappeared entirely, and he no longer complained of the constant throbbing in his abdomen and head.

Careful examination of the heart seven days after operation revealed no change in the relative cardiac dulness, but the large pulsating femoral artery, so strikingly visible in the left groin before operation, had greatly diminished. On palpating the femoral artery just below Poupart's ligament, one was struck by a remarkable decrease in its size; its approximate diameter appeared to be 1 cm., as contrasted with a preoperative diameter of 2 cm. September 12,

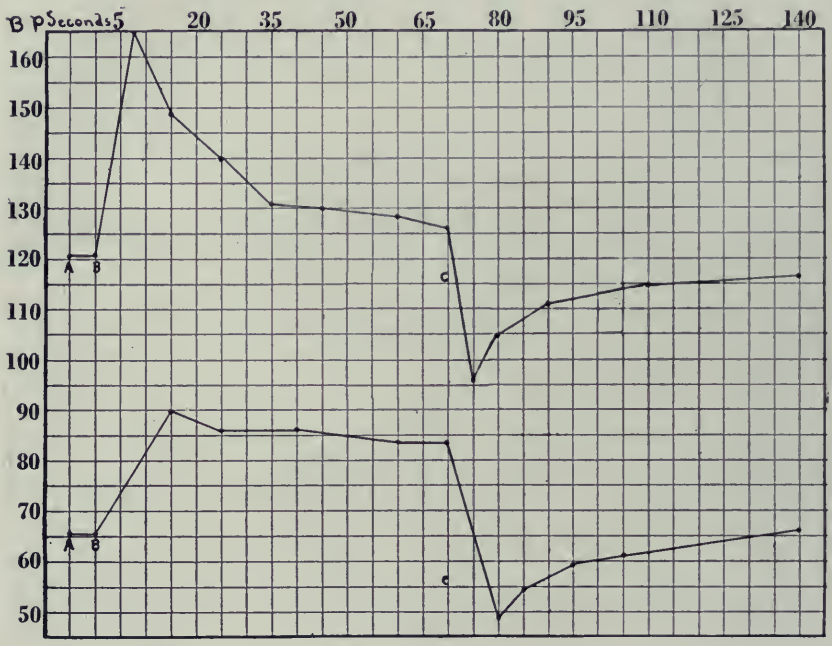

Fig. 5.—Changes in blood pressure (left arm) on closing and opening fistula. The lower line represents the fluctuations in diastolic pressure; the upper, in systolic pressure; *A*, fistula open; *B*, fistula closed by digital compression; *C*, fistula opened by release of compression.

thirteen days after operation, a teleroentgenogram (Fig. 7) recorded a heart shadow of a total width of 13.5 cm. as compared to a preoperative reading of 15.8 cm.

A gradual readjustment of blood pressure occurred as indicated in Figure 8. On the first day after operation, the systolic reading was 132, the diastolic, 105. The preoperative reading was: systolic, 120, diastolic, 66. This high reading gradually fell until the day of discharge, when it was: systolic, 104, diastolic, 73, the systolic reading being considerably lower than before operation, the diastolic somewhat increased. An apparent readjustment in the blood picture also followed the operation. Previous to operation the red cells totaled 3,880,000 per cubic centimeter. The second day after operation, the total was

5,500,000, indicating a concentration of blood. This high red cell count gradually fell until the day of discharge, when it was 4,480,000. The significance of this will be made clear later.

COMMENT

The most startling feature in connection with the case was the behavior of the general blood pressure dependent on conditions at the fistula. In looking through the hospital records, I could find very little information comparable to our present observations.

C. B., operated on by Dr. Halsted in 1916 for a fistula in the right Hunter's canal, had a very large heart with a hugely dilated proximal artery. Previous

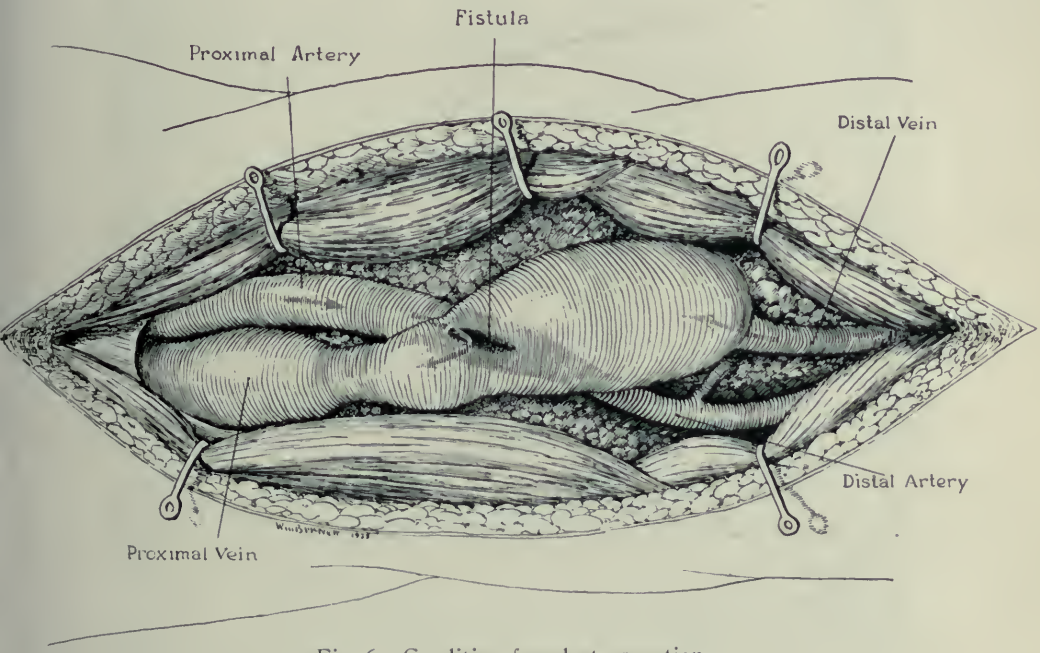

Fig. 6.—Condition found at operation.

to operation, blood pressure readings ranged around 120 systolic, 60 diastolic (left brachial). No further comparable observations were made until six weeks after operation, when a blood pressure of 145 systolic, 114 diastolic in the left brachial artery was recorded; a rather remarkable increase, and apparently sustained over a long period of time.

Bramann[6] records a case of arteriovenous fistula of the ulnar vessels in which blood pressure readings were 58 to 69 systolic before operation, and 116 to 130 systolic after operation, as read by a Ludwig's manometer. In one of Dr. Reid's cases of arterio-

6. Bramann, F.: Das arteriell-venöse Aneurysma, Arch. f. klin. Chir. **33**:1, 1886.

venous fistula of the carotid and jugular vessels an unexplained bradycardia was present for several days after operation. Injury to the vagus at the time of operation was considered as a possible cause of this bradycardia, but it was most probably due to the altered condition in the general circulation following closure of the fistula.

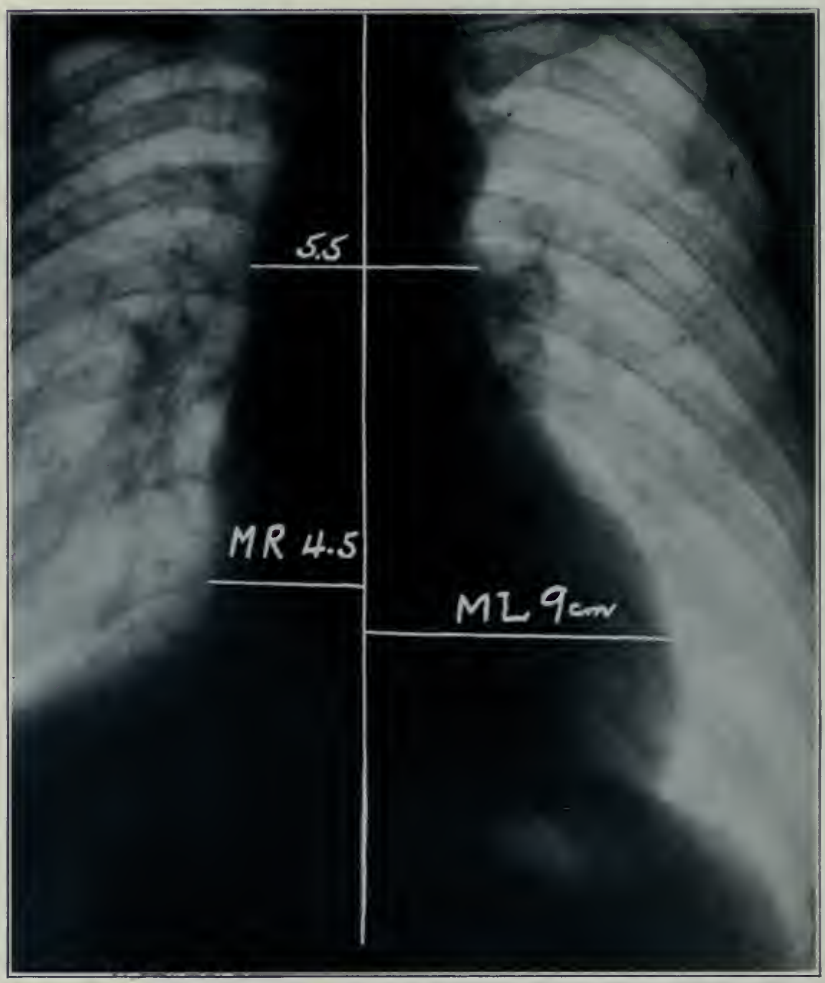

Fig. 7.—Teleroentgenogram taken thirteen days after operation, showing marked reduction in size of heart.

CAUSE OF BLOOD PRESSURE VARIATIONS

In seeking a cause for these blood pressure variations, I find that one can postulate what seems to be a well justified explanation on the basis of the physiology of the circulatory system. The same physiologic

basis leads us to certain important and clarifying conclusions with reference to cardiac hypertrophy and proximal dilatation of the artery. Normally, the circulatory system, with reference to blood pressure, is a single closed system, namely, heart, arteries, capillary bed and veins, with a single pressure and a single peripheral resistance. The mean systemic pressure in such a system varies according to alteration in (1) total capacity of the system either by contraction or dilatation of the vessel walls; (2) total volume of circulating fluid; (3) heartbeat and cardiac output, or (4) peripheral resistance. An alteration in any one factor may call into action alterations in another, and the mean systemic pressure is dependent on a proper balance of these four factors.

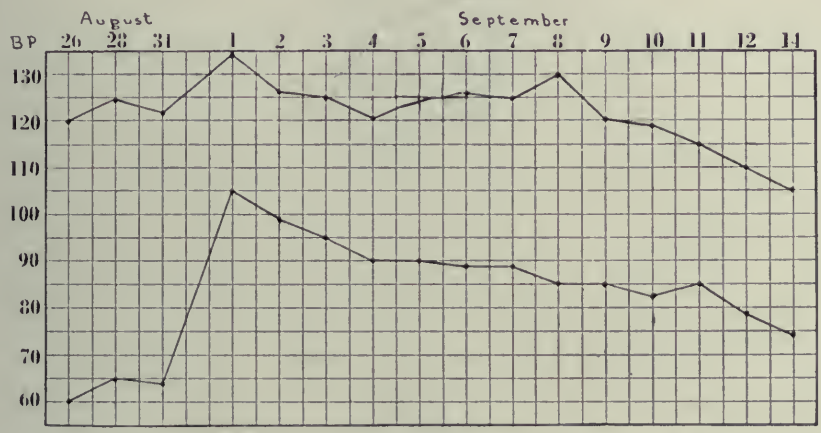

Fig. 8.—Gradual readjustment of blood pressure (left arm) following operation. The lower line represents fluctuations in diastolic pressure; the upper, in systolic pressure. Operation was performed August 31.

Following the production of an arteriovenous fistula, there is an upset of this balance and a number of compensating changes are called into action (Fig. 9). The original system (*a*), consisting of heart, arteries, capillary bed and veins, now gives place to two systems supplied from a common source, the second system (*b*) consisting of heart, artery, fistula and vein. The two systems may be pictured as two columns of blood with a common source of supply, but with a tremendous difference in peripheral resistance. It is an axiom that water will flow along the line of least resistance. Hence there would be a tendency for practically the entire blood volume to flow through system *b* if the difference in resistance to flow through the two systems is great enough. To maintain a flow through system *a*, therefore, it is absolutely essential to maintain a comparatively normal general pressure so that blood will flow through *a* as well as *b*.

READJUSTMENTS FOLLOWING PRODUCTION OF FISTULA

Recalling the four factors concerned in maintaining a normal blood pressure, the readjustments which occur on production of a fistula may be enumerated as follows:

1. There is a great decrease in peripheral resistance, resulting in an immediate fall in blood pressure. Of course, blood pressure is not

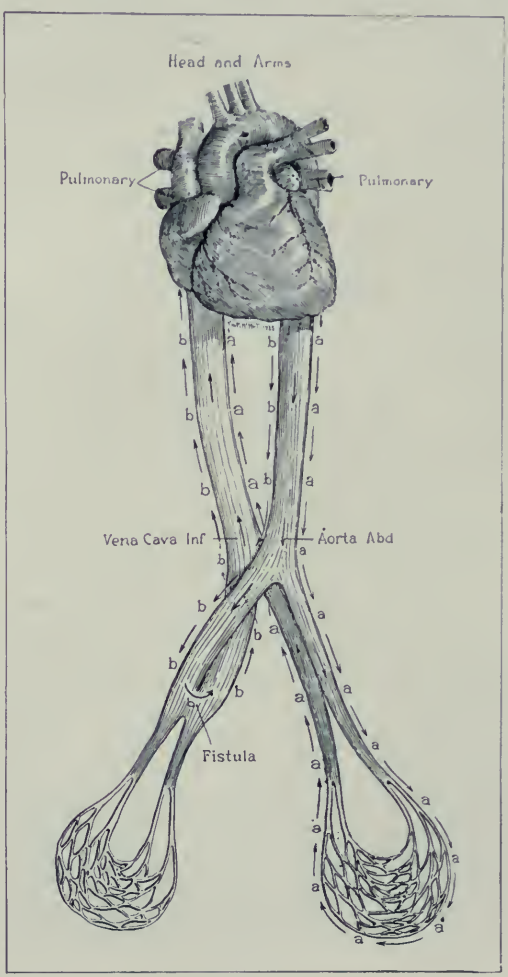

Fig. 9.—Schema of circulation following production of arteriovenous fistula.

the result of peripheral resistance, but the general effect of the presence of such a peripheral resistance is to enable the heart to produce a high arterial pressure. Remove that resistance and blood pressure falls.

Efforts to compensate for this fall in pressure are several. Arterial pressure reduced to its simplest terms is the resultant of two factors:

(1) the amount of blood entering the arterial system from the heart, and (2) the amount of blood leaving the arterial system through the capillaries, and in this case through the fistula. Therefore, to offset the greater volume of blood leaving the arterial system through the fistula, we must increase the amount of blood entering the arterial system from the heart.

2. Cardiac output, in turn, depends on several factors: (*a*) the amount of blood contained in the heart at the beginning of each contraction; (*b*) the strength with which the heart beats, and (*c*) the number of contractions per unit of time. The filling of the heart at the beginning of each beat is in turn dependent on the amount of blood which is available to fill the cavities, and therefore on the pressure in the great veins. Increased frequency of heart rate alone need not necessarily increase the total output of the heart into the arterial system. If the veins are not filled more rapidly, it is not possible to obtain more blood to put into the arterial side, however frequent the heart beat. There will be, therefore, an optimum frequency of heartbeat which will depend on the state of filling of the great veins. The fuller these are, the more rapidly the heart may beat without diminution of total output.

In a fistula, there is a marked increase in venous pressure, a rapid filling of the great veins, and a probable dilatation also of the right side of the heart, which receives the increased blood from the overfilled veins. Bayliss [7] states that "the inflow from the veins is, practically, the determining factor in the work done by the heart." In a fistula, the inflow from the veins is greatly increased. This is due in part to the increase in velocity of flow around the system *b*. Velocity of flow varies directly as the difference in pressure between two points and inversely as the resistance between two points. In a fistula, there is a marked sudden difference in pressure between the two connecting points, the artery and vein, and a marked diminution in resistance, both factors favoring an increased velocity of flow from artery to vein, and therefore around the system *b*. If the work depends on the inflow from the veins, as Bayliss states, the work of the heart is greatly increased in an arteriovenous fistula, and the physiologic response to increased work is hypertrophy. The volume of blood which flows through the heart per unit of time is obviously greatly increased when a short circuiting of the flow occurs, as in a fistula. To take care of this increased volume of blood, the heart works more rapidly and with greater force, but, in the presence of a fistula, without a rise in blood pressure.

---

7. Bayliss, W. M.: Principles of General Physiology, New York, Longmans, Green and Company, 1918.

The great increase in cardiac effort was well illustrated in our clinical case in which the bed shook with each systole and in which operation brought relief from the excessive pounding of the heart. Following the operation, the blood pressure was maintained at a higher level in spite of a tremendous decrease in cardiac effort. The increase in pulse rate, and therefore in cardiac effort, is well shown in a number of experiments performed by me three years ago, under the direction of Dr. Mont Reid, in which fistulas were produced between the carotid and jugular vessels in a dog. The pulse rate was noted before and after opening the fistula, and at each operation there was an immediate rise in pulse to an almost uncountable rate: in Dog 1, from 140 to 220; in Dog 2, from 160 to 220; in Dog 3, from 150 to 180; in Dog 4, from 100 to 190; in Dog 5, from 110 to 192.

3. The third factor to be considered as taking part in the readjustment of arterial pressure in the presence of a fistula is the alteration in the volume of circulating fluid. Any lowering of blood pressure causes an absorption of fluid from the tissues into the blood. For example, the blood content during the last stages of bleeding may contain little more than from 50 to 60 per cent. of the blood which was present in the first specimens, pointing to a corresponding dilution by tissue lymph. Our clinical case gives some slight evidence of this adjustment. A red cell count of 3,880,000 before operation is increased to 5,500,000 immediately after operation, pointing to a concentration of blood by loss of plasma when the larger volume was no longer needed owing to the repair of the fistula. This high red cell count dropped within two days to 4,800,000, indicating a gradual readjustment of blood volume. Experimental results are not available as yet, but blood volume studies are being made on our experimental animals by Dr. Harry P. Smith of the department of pathology. It is a point which should be demonstrable, as it is on the increase in total quantity of blood and primarily on the increase in volume of blood flowing through system *b*, that the dilatation of the artery depends. The sequence of events, which may again be explained on a physiologic basis, is probably as follows:

The fistula results in such a lowering of pressure in system *b* that the tendency is to divert a larger volume of blood through this route. To accommodate this increased volume of blood, there must be a widening of the blood stream, and particularly of the distensible elastic arterial wall and vein. With a fistula sufficiently large, it is obvious that practically the entire blood stream would be diverted through *b*, if it were not for the resistance to distensibility offered by the vessel walls. That the entire blood volume is not diverted through *b* depends, therefore, on the resistance offered by the fistulous opening and by the limited distensibility of the vessel walls. The volume of blood through

b will increase until the resistance to its flow through *b* equals the resistance to its flow through *a*. If the fistulous opening is small or if it is a mere slit, a point is soon reached at which the resistance at the fistula to the flow of the increased volume of blood equalizes the arterial resistance in *a*, thus establishing an equilibrium in the two systems. If the opening is large, the only resistance which can be developed is that offered by increasing the column of blood flowing through the opening, the size of this column of blood being limited only by the distensibility of the vessel wall; that is, the volume of blood flowing through *b* will need to be increased until the resistance offered by the fistula can be supplemented by the resistance to the flow of a larger volume through a tube of limited capacity. Hence, the dilatation of the vessel will depend in great measure on the cross section of the fistula—a narrow slit will afford considerably more resistance than a rounded opening, a small opening more than a large opening.

This increase in blood volume through system *b* is furnished from two sources: (1) an increase in total volume of circulating blood, (2) at the expense of blood flowing through *a*. That this increase in blood volume flowing through *b* is partly at the expense of blood flowing through *a* is suggested in our clinical case by (1) the dizziness and faintness of the patient on rising from a sitting posture, and (2) his inability to work in a mine, apparently owing to imperfect oxygenation of the tissues due to an inadequate flow of blood through them.

4. The last factor in the maintenance of pressure to be considered is the alteration in the total capacity of the system by contraction or dilatation of the vessel walls. Vasoconstriction occurs with fall in blood pressure, but contraction of the vessel walls in the presence of a fistula results only in a diversion of even more blood through system *b* and the fistula.

The extent to which these various factors are called into play in any fistula depends primarily on the size of the fistula and the resistance offered to the flow of blood through it. The fall in blood pressure depends wholly on the amount of blood which can be diverted through the fistula, and back to the heart. Similarly, any compensatory changes in cardiac output, in an increased blood volume and in alteration in capacity of the system will depend on the volume of blood diverted through the fistula, and hence on the size of the fistula. A small opening is easily taken care of, but a large opening suddenly acquired can conceivably result in immediate death; in fact, while we were working on the problem in 1919, as many dogs died on the table as lived following the opening of the fistula. These deaths were then unexplained, but they were probably due to too great a diversion of blood through the fistula.

The dilatation of the artery is then, I believe, dependent primarily on the cross-section size of the fistulous opening; and dilatation will continue until the resistance at the fistula prevents any further increase in the quantity of blood passing through the fistula. I believe it can be proved experimentally that the artery will dilate over a period of years until the cross section of the artery equals the cross section of the fistula. In our clinical case, there was a history of gradual cardiac decompensation over a period of five years, and the reported cases emphasize the fact that the dilatation is dependent on the duration of the fistula.

EXPERIMENTAL DATA

Our experimental evidence is still meager, but if our assumption that the entire process can be explained on physiologic grounds is correct, one should be able not once but always to reproduce our clinical picture in animals. Accordingly, a fistula was produced between the femoral vessels of a large mongrel (L 1), and numerous blood pressure readings were made by Dr. Alfred C. Kolls of the department of physiology, who collaborated with me in this experimental study. The tracings have been obtained by means of a modified Erlanger blood pressure apparatus which Dr. Kolls has adapted for use on a dog. Just previous to the release of the clamps used in producing the fistula, the following observations were made: pulse, 148; respirations, from 40 to 44; blood pressure, 204 systolic, 124 diastolic. The clamps were removed, and an immediate acceleration of pulse occurred from 140 to 224. Respirations were slightly increased, and the blood pressure had dropped from 204 systolic, 124 diastolic to 176 systolic, 80 diastolic.

On closing the fistula by digital pressure, the blood pressure readings revealed an immediate recovery to 208 systolic, 110 diastolic. A reading with the fistula opened again was 200 systolic, 80 diastolic. Pressure readings below the fistula read 103 systolic, 30 diastolic, 135 systolic, 30 diastolic. November 3, readings showed a pressure of 190 systolic, 80 diastolic with the fistula open, and 205 systolic, 96 diastolic with the fistula closed. On the same day, a tracing (Fig. 10) showed the profound effect on systemic pressure produced by opening and closing the fistula. Digital pressure over the site of the fistula sufficient to obliterate the opening resulted in an immediate response, with an increased blood pressure and a diminished pulse rate. Readjustment occurred within a few seconds, and on opening the fistula, there was an immediate fall in pressure and an increase in pulse rate. Repeated identical observations were made (Fig. 11), all illustrating the same variations in pulse and general blood pressure on the opening and closing of the fistula.

It is interesting to speculate on the reasons for the fall in pulse rate incident to closure of the fistula. Closure of the fistula results in a filling up of the aorta by the volume of blood which formerly leaked through into the veins. This produces an increase in aortic pressure which stimulates the depressor fibers of the vagus in the arch of the aorta, and reflex slowing of the heart is the result.

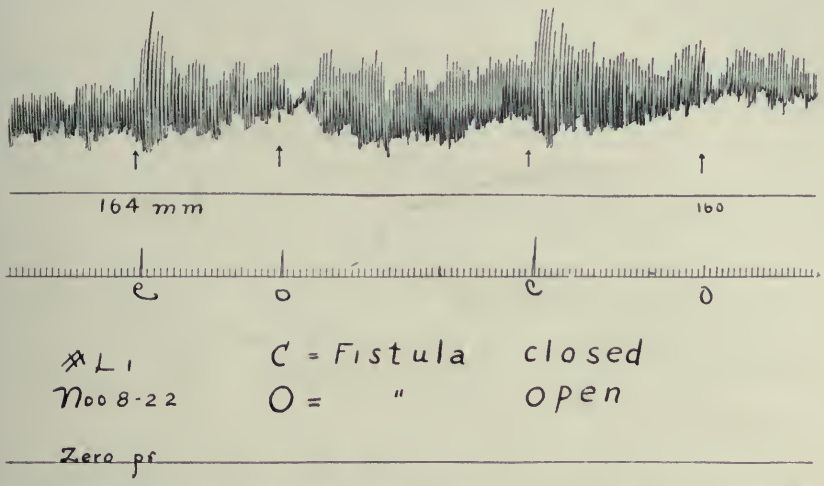

Fig. 10.—Changes in general blood pressure on closing and opening an artificially produced arteriovenous fistula in a dog, twenty-four days after formation of fistula. The effect on pulse rate is also shown.

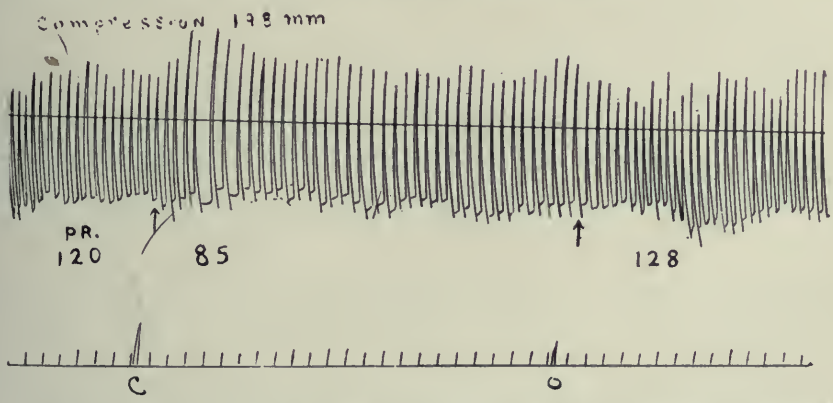

Fig. 11.—Pulse rate variation on closing and opening an artificially produced arteriovenous fistula; *C*, fistula close; *O*, fistula opened. (Dog L 1, Nov. 3, 1922.)

It is obvious from these records that very definite experimental evidence is available, confirming the clinical observations. Experiments are now under way to determine the effect of the size of the fistula on subsequent dilatation of the artery and on cardiac response. One can

almost venture the prediction that dilatation will occur only if the fistula is larger in cross section than the cross section of the artery, and that the dilatation will then proceed until these cross sections are approximately equal.

CONCLUSIONS

1. Proximal dilatation of the artery is explicable on purely physiologic grounds. It is dependent primarily on an increase in the total volume of circulating blood and more particularly on an increase of blood flowing through the system of heart, artery, fistula and vein, an increase in volume which is one of the compensatory changes necessary to rectify the fall in blood pressure incident to the greatly decreased peripheral resistance in the presence of a fistula.

2. Cardiac hypertrophy and dilatation are also explicable on purely physiologic grounds, hypertrophy being a response to the increased work necessary in handling the increase in volume of blood flowing through the heart per unit of time; and dilatation being the result of a general dilatation of the system, heart, artery, fistula and vein produced by the increased volume of blood flowing through it.

THE SKIN SIGNS OR VISCEROSENSORY PHENOMENA IN ACUTE APPENDICITIS *

EDWARD M. LIVINGSTON, B.Sc., M.D.
Adjunct Assistant Visiting Surgeon, Bellevue Hospital
NEW YORK

The viscerosensory phenomena are altered responses to stimuli, applied to the superficial structures of the body wall; these altered responses being caused by acute diseases of certain internal organs. Such manifestations are referred to, in this article, as skin signs. The explanation of these phenomena is difficult. The presence of an acute disease within a viscus causes afferent impulses, which pass through the paravertebral ganglions (thoracicolumbar outflow of the autonomic system), reaching the spinal cord through the posterior root ganglions of the central nervous system and passing thence to the brain, as shown in Figure 1. Within the spinal cord and the sensory ganglions, the fibers carrying these impulses lie in close proximity to, or synaptic relation with, the central endings of sensory fibers originating in the body wall. During an acute disease within a viscus, the patient may—because of this central connection of visceral afferent fibers with sensory fibers from the body wall—believe that the impulses causing his pain have their source in the associated areas of the body wall (Fig 1, *b*) rather than within the viscus, where they actually originate (Fig. 1, *a*). For the same reason, stimuli applied to the associated skin area, during such a visceral disease, give more marked responses than the same grades of stimuli applied to other portions of the skin. Such associations of skin areas with viscera follow the segmental distribution of the "cord zones" of the skin, as described by Head.[1]

The present conception of the innervation of the viscera with reference to the so-called reflex phenomena, which may be observed within other organs and on the body wall as the result of a disease within a viscus, is relatively new. The clinical application of this knowledge is still more recent and incomplete. Since the initial comprehensive study of the autonomic nervous system published by Langley, he,[2] Gaskell,[3]

---

* From the Third Surgical Division of Bellevue Hospital and the Department of Experimental Surgery, New York University and Bellevue Hospital Medical College.

1. Head, Henry: A Disturbance of Sensation, with Special Reference to the Pain of Visceral Disease, Brain **16**:1-122, 1892.

2. Langley: The Autonomic Nervous System, Brain **26**, 1903.

3. Gaskell, W. H.: The Involuntary Nervous System, New York, Longmans, Green & Company, 1916.

Sherrington,[4] Bayliss,[5] Starling[6] and other physiologists have carried to its present status our knowledge in this field of neurology. The chief clinical applications have been made by Head,[1] MacKenzie,[7] Sherren,[8] Eppinger and Hess.[9] In the United States, the outstanding contribution to the subject is that of Pottenger,[10] whose book "The Symptoms of Visceral Disease" contains a large amount of original work, particularly with reference to diseases of the chest.

Our interest in the subject of the viscerosensory phenomena was aroused by isolated observations of skin signs in acute appendicitis. The present studies followed, and aim at the appraisal of such signs in disturbances of the following tubular structures: the appendix,

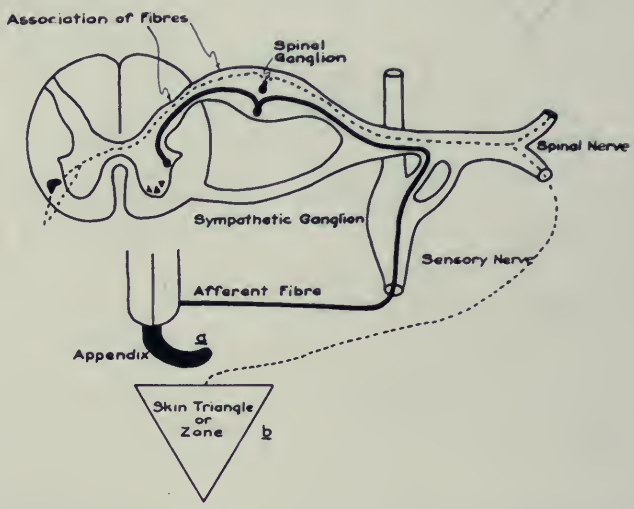

Fig. 1.—Schematic representation of the viscerosensory phenomena (skin signs) of acute appendicitis.

---

4. Sherrington: The Integrative Action of the Nervous System, New York, Charles Scribner & Sons, 1906.

5. Bayliss: Principle of General Physiology, New York, Longmans, Green & Company, 1915.

6. Starling: Principles of Human Physiology, Philadelphia, Lea & Febiger, 1915.

7. MacKenzie, James: Associated Pain of Visceral Disease, Medical Chronicle **16**:295, 1892; Symptoms and Their Interpretation, London, Shaw & Sons, 1909; The Theory of Disturbed Reflexes in the Production of Symptoms of Disease, Brit. M. J. **1**:147 (Jan. 29) 1921.

8. Sherren: On the Occurrence and Significance of Cutaneous Hyperalgesia in Appendicitis, Lancet **2**:816-821 (Sept. 19) 1903.

9. Eppinger and Hess: Vagotonia, Washington, D. C., Nerv. & Ment. Dis. Pub. Co., 1917.

10. Pottenger, F. M.: Symptoms of Visceral Disease, Ed. 2, St. Louis, C. V. Mosby Co., 1922.

ureter, fallopian tube and biliary ducts. This work has been done on the Third Surgical Division of Bellevue Hospital (service of Dr. George David Stewart) and in the clinics and surgical laboratory of New York University and Bellevue Hospital Medical College.

The present article deals with acute appendicitis. It aims (1) to evaluate the skin signs in acute appendicitis; (2) to indicate a cutaneous triangle for use in differential diagnosis, and (3) to suggest, a simple technic for testing skin signs, which will give the most satisfactory results. Four tabulations are presented. Tables 1 and 2 present the earlier work; Table 3 and Figure 2, the more recent work. In these tabulations, the typical symptoms of appendicitis—pain, tenderness,

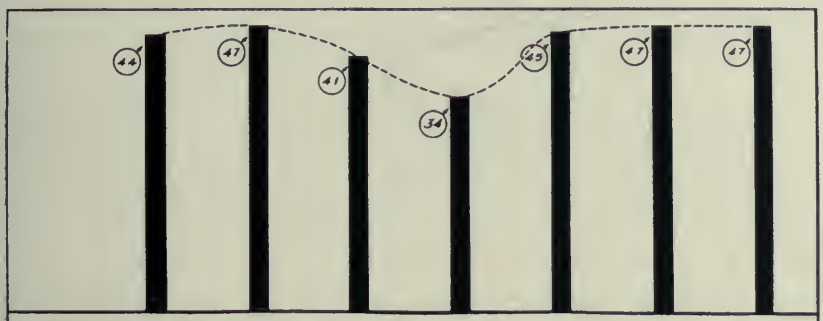

	Pain	Nausea or Vomiting	Tenderness	Rigidity	Temperature	Leukocytosis	Skin signs
Typical.....	44	47	41	34	45	47	47
Atypical or negative.....	10	7	13	20	9	7	7
Total.....	54	54	54	54	54	54	54

Fig. 2.—Comparative frequency of classic signs of acute appendicitis in fifty-four cases (all cases in Table 3 except Cases 2, 5, 8, 51, 56, 59 and 61), in which skin tests were not made.

nausea or vomiting, elevated temperature, leukocytosis, etc.—are presented, and the presence or absence of skin signs noted in all cases coming under observation. Table 1 covers all patients operated on under the diagnosis of acute or subacute appendicitis on the Third Surgical Division of Bellevue Hospital during the period from March, 1919, to July, 1920. All skin signs presented in this table were observed by me. They carried no weight in arriving at the diagnosis, being made solely as a matter of investigation. Table 2 concerns those cases from Table 1 in which the skin signs were negative or atypical. Table 3 covers all cases discharged with the diagnosis of acute appendicitis on the same division between the months of January and December, 1922. In the latter series, the cutaneous observations were made by more than twenty observers—attending surgeons, interns and student clerks—only two observations being made by me. In the latter series also, these signs were utilized in arriving at the final diagnosis.

TABLE 1.—*Analysis of Symptoms of Patients Operated on for Acute Appendicitis on the Third Surgical Division of Bellevue Hospital, March 1, 1919, to July 10, 1920**

Case	Patient	Age, Yrs.	Date	Duration. Days	Pain	Nausea or Vomiting	Previous Attacks	Tenderness	Rigidity	Mass	Temperature	Leukocytosis	Polymorphonuclears, per Cent.	Skin Signs	Preoperative Diagnosis	Findings
1	R. M.	29	3/15	3	+	—	1	+	—	—	99	7,000	76	+	Chr appendicitis.....	Tuberculosis of appendix; tuberculous peritonitis
2	M. R.	38	4/19	10	Lower abdomen	0	0	Bilateral	Bilateral	—	100.2	11,500	78	+	Subac. appendicitis...	Subac. exudative
3	F. C.	43	11/12	2	General	0	—	Entire Rt.	Entire Rt.	—	102.2	0	0	+	Rupt. appendix.....	Ac. suppurative
4	T. H.	25	5/ 3	2	General	2	0	Epigastric	0	—	105	0	0	—	Rupt. appendix.....	Pneumonia
5	O. N.	29	5/ 1	2	+	1	0	0	+	—	101.2	18,200	85	+	0	Ac. suppurative
6	P. D.	21	5/28	1	+	N	—	+	+	—	100	14,400	87	+	Ac. appendicitis.....	Ac. suppurative
7	M. H.	51	6/ 7	4	General	1	1	+	Bilateral	—	102	28,800	80	—	Ac. appendicitis.....	Gangrenous
8	C. K.	32	6/ 8	3	General	0	2	+	0	—	100	10,400	90	+	Ac. appendicitis.....	Ac. exudative
9	M. K.	16	6/20	3	+	3	0	General	General	+	102.6	28,000	78	—	Rupt. appendix.....	Gangrenous
10	M. D.	47	6/30	3	General	0	0	+	+	—	100.2	0	0	+	Ac. appendicitis	Ac. suppurative
11	E. S.	30	7/ 8	2	+	—	4	General	General	—	100.6	12,000	80	+	Ac. appendicitis	Ac. hemorrhagic
12	P. H.	38	7/27	2	+	2	—	General	General	—	101.2	15,000	94	+	Rupt. appendix.....	Ac. suppurative
13	H. S.	48	7/12	7	+	—	0	General	General	—	102.3	19,000	82	+	General peritonitis....	Ac. suppurative
14	M. M.	47	7/11	16	+	—	0	Rt. lumbar	Rt. lumbar	+	101.2	13,000	83	+	Tumor of kidney.....	Ac. suppurative (retrocecal)
15	R. M.	19	7/ 7	1	+	2	0	+	+	—	102.2	0	0	—	Rupt. appendix.....	Gangrenous
16	E. Z.	32	7/23	Indef.	Lumbar	—	0	Entire Rt.	Entire Rt.	+	101.2	0	0	+	0	Ac. suppurative (retrocecal)
17	A. M.	24	7/30	7	+	3	0	+	+	—	100.2	19,000	83	+	Ac. appendicitis.....	Ac. suppurative
18	J. M.	40	8/14	1	Epigastric	4	0	Bilateral	Bilateral	—	101.4	22,400	90	—	Ac. appendicitis	General peritonitis (unknown origin)
19	M. G.	30	8/30	1	+	6	0	+	General	—	100.4	12,000	78	+	Ac. appendicitis.....	Ac. hemorrhagic
20	D. M.	20	9/16	2	+	1	—	General	General	—	100.6	17,000	78	+	0	Gangrenous
21	H. G.	42	10/ 9	1	General	N	0	+	General	—	103	20,800	82	—	0	Pneumonia; appendix negative
22	F. N.	35	10/ 8	6	+	1	0	+	+	+	100.6	12,000	0	+	Rupt. appendix.....	Ac. suppurative
23	M. D.	24	10/ 7	4	+	3	0	+	Left lower	—	100	26,000	86	—	App. abscess.....	Ac. suppurative
24	N. P.	17	10/31	7	+	N	6-7	+	+	—	99.8	9,000	68	+	Chr. appendicitis.....	Tuberculosis of appendix
25	G. S.	24	10/16	5	+	—	0	+	—	?	99.2	12,000	82	—	Subac. appendicitis...	Tabes mesenterica
26	W. D.	22	10/29	2	+	2	0	+	Bilateral	+	101	17,000	91	+	Rupt. gastric ulcer....	Ac. suppurative
27	J. S.	14	10/15	2	+	4	0	+	+	—	101.4	26,000	85	—	Ac. appendicitis.....	Gangrenous
28	G. C.	61	10/ 2	4	+	1	1	General	General	—	100.2	25,000	93	+	Intestinal obstruction	Gangrenous
29	P. J.	24	10/28	1	+	4-6	0	Epigastric	General	—	99.4	12,000	76	—	Ac. appendicitis.....	Ac. gastritis
30	M. T.	17	10/15	4	+	2	0	+	0	—	100	12,600	71	+	Subac. appendicitis...	Subac. exudative
31	J. M.	29	11/20	4	+	3	0	+	General	—	101	19,000	80	+	Gangrenous app.....	Ac. suppurative
32	A. O.	32	11/12	1	+	2	0	+	Bilateral	—	101.8	23,000	92	—	0	Gangrenous
33	L. J.	56	11/17	2	+	1	0	+	+	—	102	7,800	92	+	Perf. app.....	Ac. hemorrhagic

34	S. W.	26	11/25	1	+	1	0	+	+	—	100	6,200	88	+	0	Ac. suppurative
35	R. S.	?	12/30	3	+	6	0	+	General	0	100.4	12,000	78	+	Ac. appendicitis.....	Ac. exudative
36	J. O.	12	12/13	4	+	N	2	+	+	+	102.2	23,800	88	—	0	Ac. suppurative
37	Y. E.	12	12/24	3	+	2	0	+	+	—	100.4	14,000	76	+	Ac. appendicitis.....	Ac. exudative
38	P. S.	48	12/ 2	21	Inguinal	0	0	Inguinal	Bilateral	Inguinal	102	0	0	+	Inguinal adenitis.....	Ac. suppurative; cellulitis of thigh
39	C. O.	38	12/17	3	+	—	0	+	+	+	101.2	12,600	78	+	App. abscess.....	Ac. suppurative
40	J. H.	34	9/30	3	+	3	2	+	Entire Rt.	+	101.2	10,200	66	+	App. abscess.....	Ac. suppurative
41	H. S.	43	1/14	14	+	—	2	+	—	—	98.6	9,800	60	—	Chr. appendicitis; nephrolithiasis	Nephrolithiasis
42	N. B.	22	1/ 6	4	+	2	0	General	General	—	102.2	16,000	94	+	Rupt. appendix.....	Ac. suppurative
43	G. O.	36	1/26	7	+	—	—	+	+	—	100	13,000	78	+	Chr. appendicitis.....	Ac. exudative
44	T. M.	44	2/16	1	+	1	0	+	+	—	98.8	18,000	81	—	Ac. suppurative.....	Gangrenous
45	M. E.	18	2/ 6	4	+	N	2	+	+	—	98.8	16,000	85	+	Ac. appendicitis.....	Ac. exudative
46	S. P.	28	2/13	6	+	2	0	General	General	—	102.2	20,000	94	—	General peritonitis....	Gangrenous
47	A. B.	21	3/22	?	General	—	2	+	—	—	98.8	9,400	80	+	Chr. appendicitis.....	Ac. exudative
48	I. J.	18	3/ 7	1	+	1	0	+	+	—	99.4	13,000	88	+	Probable appendicitis	Ac. hemorrhagic
49	S. L.	25	3/25	21	+	1	4-5	+	—	—	98.6	10,000	75	—	Subac. appendicitis...	Tabes mesenterlea
50	O. B.	33	3/23	1	+	1	0	+	+	—	99.2	16,000	80	+	Ac. appendicitis.....	Ac. exudative
51	A. T.	22	3/10	3	+	—	2	+	+	—	98	15,000	78	—	Subac. appendicitis...	Ovarian cyst
52	B. A.	23	3/27	2	General	—	0	General	General	—	99.2	18,000	94	+	Ectopic gestation.....	Ac. hemorrhagic
53	C. H.	35	3/27	90	General	3	2	General	General	—	99	9,300	78	—	Gastric carcinoma; chr. appendicitis	Pulmonary tuberculosis
54	J. M.	25	4/20	2	+	1	0	+	+	+	101.6	18,400	86	+	Ac. appendicitis.....	Ac. suppurative
55	J. C.	15	4/22	3	+	2	0	0	General	0	101	13,500	90	+	General peritonitis....	Ac. suppurative
56	M. B.	29	5/14	2	+	5	0	General	General	—	101	16,000	90	+	General peritonitis....	Ac. exudative
57	J. F.	29	5/20	1	+	2	0	General	General	—	100	15,200	87	+	General peritonitis....	Ac. suppurative
58	J. B.	16	4/20	3	+	2	0	+	+	—	101.8	18,900	90	+	Ac. appendicitis.....	Ac. suppurative
59	M. R.	38	5/10	1	+	3-4	0	+	+	—	100.6	18,500	92	+	Ac. appendicitis.....	Ac. suppurative
60	A. S.	27	5/16	3	+	3-4	0	General	+	—	99.2	11,000	64	+	Ac. appendicitis.....	Ac. exudative
61	J. F.	24	6/27	3	Epigastric	3	0	General	General	—	99.4	7,800	62	+	Subac. appendicitis...	Ac. exudative
62	J. H.	28	6/23	3	Rt. upper	—	0	+	—	—	101.6	22,000	87	—	General peritonitis....	Ac. suppurative
63	E. M.	19	6/23	1	+	2	0	+	General	—	100.2	14,000	80	+	Ac. appendicitis.....	Ac. suppurative
64	W. T.	54	6/20	2	General	2	—	+	+	—	101.2	22,000	87	+	Strangulated hernia..	Ac. suppurative
65	S. E.	17	6/25	1	+	2	0	+	+	—	99.4	20,000	90	+	Ac. appendicitis.....	Ac. hemorrhagic
66	M. G.	66	6/15	1	+	—	2	+	+	—	101	17,400	85	+	Subac. appendicitis...	Ac. exudative
67	A. D.	41	6/19	180	Epigastric	N	4	+	Entire Rt.	—	99.2	7,800	80	—	Subac. appendicitis...	Pulm. tuberculosis
68	A. B.	49	6/10	2	General	N	0	+	+	—	101.2	18,800	88	+	Ac. appendicitis.....	Ac. hemorrhagic
69	W. M.	16	3/21	6	General	—	0	General	General	—	100.8	16,200	87	+	General peritonitis ...	Ac. exudative
70	C. M.	21	3/21	18	+	—	0	+	+	—	100.8	10,200	77	+	Subac. appendicitis...	Ac. exudative
71	J. B.	25	6/15	1	+	—	0	+	+	—	99	13,600	84	+	Subac. appendicitis...	Ac. exudative
72	J. N.	17	7/ 9	2	+	2	2	+	+	—	101.8	10,000	85	+	Ac. supp. appendicitis	Ac. suppurative
73	G. R.	29	7/ 9	3	General	—	0	+	+	—	100.4	0	0	+	Subac. appendicitis...	Ac. exudative
74	F. M.	36	7/ 6	10	+	0	0	+	+	+	101	18,200	76	—	Appendicular abscess.	Ac. suppurative
75	B. M.	28	6/26	1	+	N	—	General	+	—	100.2	16,400	84	+	Ac. appendicitis.....	Ac. suppurative

* 0, not charted; —, negative; +, present and typical; +, skin signs: those localized within triangle previously described.
The date is the discharge date. The duration is the number of periods of twenty-four hours each since onset. All data were taken from the charts of the general record room of Bellevue Hospital.

The skin signs found in appendicitis are enumerated toward the close of this article, with a suggested technic for their use, and a review of the work previously done in this field. The typical signs, as recorded in the charts are localized within a triangle. A line from the umbilicus to the highest point on the right iliac crest forms the upper side; a line carried from this point to the right pubic spine forms the lower side, and a line from the right pubic spine to the umbilicus closes the triangle (Fig. 3). Though this triangle does not correspond to any

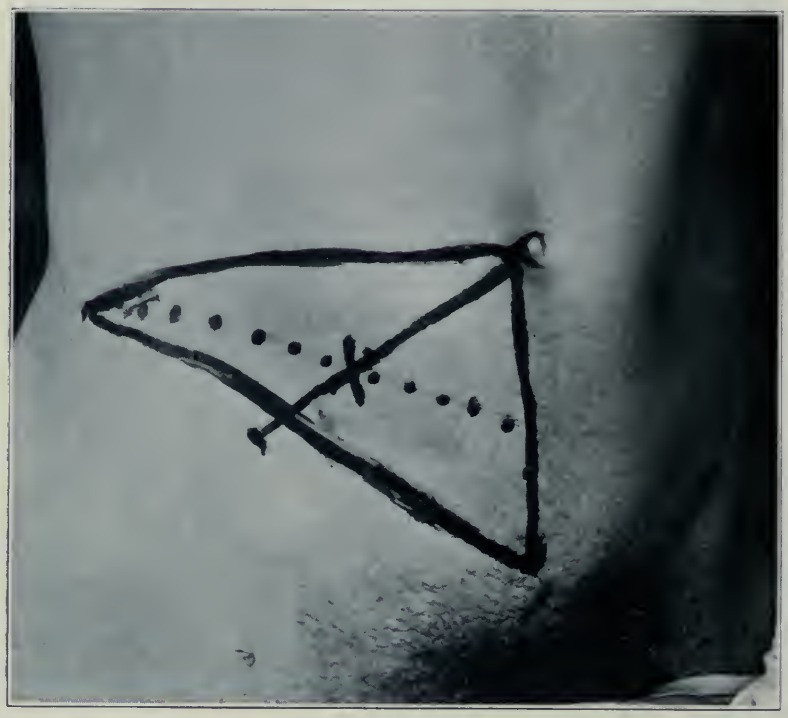

Fig. 3.—Skin triangle for acute appendicitis: Superior limb of triangle: umbilicus to summit of right iliac crest; inferior limb: summit of right iliac crest to right pubic spine; base of triangle: umbilicus to right pubic spine. The line from the anterior superior spine of the ilium to the umbilicus bisects the triangle. Skin signs present within triangle only and maximal at its center are considered confirmatory of appendicitis (disregarding posterior hyperesthesia). Those maximal beyond this triangle are considered negative for acute appendicitis.

cord zone or zones and does not include the region of hyperesthesia which is present dorsally, it is of great clinical value. Skin signs within this triangle and maximal at its center constitute confirmatory evidence of appendicitis. When the signs extend definitely beyond its borders upon the anterior abdominal wall or are maximal elsewhere, they are

TABLE 2.—*Cases from Table 1 Presenting Negative Skin Signs, Exclusive of Those with Gangrenous or Ruptured Appendix* *

Case	Patient	Age, Yrs.	Date	Duration, Days	Pain	Nausea or Vomiting	Previous Attacks	Tenderness	Rigidity	Mass	Temperature	Leukocytosis	Polymorphonuclears, per Cent.	Skin Signs	Preoperative Diagnosis	Findings
4	T. H.	25	5/ 3	2	General	2	0	Epigastric	0	—	105	0	0	—	Ruptured appendix...	Pneumonia; congestion; abdomen, appendix negative
18	J. M.	40	8/14	1	Epigastric	4	0	Bilateral	Bilateral	—	101.4	22,400	90	—	Ac. appendicitis.....	General peritonitis, unknown origin; appendix negative
21	H. G.	42	10/ 9	1	General	N	0	+	General	—	103	20,800	82	—	0	Pneumonia; general abdominal congestion
25	G. S.	24	10/16	5	+	—	0	+	0	?	99.2	12,000	82	—	Subac. appendicitis...	Tabes mesenterica
29	P. J.	24	10/28	1	+	4-6	—	Epigastric	General	—	99.4	12,000	76	—	Subac. appendicitis...	Ac. gastritis
41	H. S.	43	1/14	21	+	—	2	+	—	—	98.6	9,800	60	—	Chr. appendicitis, possible nephrolithiasis	Nephrolithiasis
49	S. L.	25	3/25	21	+	1	4-5	+	—	—	98.6	10,000	75	—	Subac. appendicitis...	Tabes mesenterica
51	A. T.	22	3/10	3	+	—	2	+	+	—	98	15,000	76	—	Subac. appendicitis...	Hemorrhagic; ovarian cyst
53	C. H.	35	3/27	90	General	3	2	General	General	?	99	9,500	78	—	Gastric carcinoma; subac. appendicitis	Abdomen negative; pulm. tuberculosis
67	A. D.	41	6/19	180	Epigastric	N	4	+	Entire Rt.	—	99.2	7,800	80	—	Subac. appendicitis...	Pulm. tuberculosis

* +, typical; —, negative; 0, not charted.

considered negative for appendicitis. Skin signs above the superior line of this triangle suggest cholecystitis, etc., while those below its inferior line suggest right renal colic, etc.

Table 1 presents a series of seventy-five consecutive cases clinically diagnosed as acute appendicitis. The skin signs were positive in fifty-four and negative in twenty-one instances. All patients presenting positive signs had acute appendicitis; eleven of those presenting negative signs had gangrenous or perforative appendicitis. In the remaining ten negative cases, the findings were: general peritonitis of unknown origin, one case (18); pneumonia, two cases (4, 21); acute gastritis, one case (29); pulmonary tuberculosis, two cases (53, 68); right renal calculus, the skin signs being present on the upper and inner portion of the right thigh, one case (41); hemorrhagic ovarian cyst, the skin signs being present over the middle of Poupart's ligament only, one case (51). In none of these ten cases was acute appendicitis present.

Table 2 presents negative cases, excluding those of gangrenous or perforative appendicitis.

This earlier study led to the following conclusions:

1. All cases of acute appendicitis in which the organ has not become gangrenous or necrotic present localized skin signs.

2. The presence of skin signs within the triangle described confirms the diagnosis of appendicitis.

3. Not all cases of gangrenous or perforative appendicitis present skin signs.

4. If skin signs are negative or are present elsewhere, in the absence of signs of gangrene or rupture of the appendix, the case is not one of acute appendicitis.

These conclusions were based on results more definite than those reported by other investigators, and for this reason were not published until confirmed by a large group of observers having no special interest in the subject. Accordingly, rubber stamps for the charting of skin tests were provided for the wards of the Third Surgical Division, and interns and student clerks were asked to include such tests in the routine examinations. After an interval of two years, during which no special interest was maintained in reference to these tests, the charts from the hospital record room were reviewed in order to ascertain the results of these routine sensory examinations.

Table 3 records all cases discharged from the Third Division with the diagnosis of acute appendicitis during the period from January 1 to December 1, 1922. There are sixty-one cases of acute appendicitis in the series. More than twenty observers recorded the sensory observations. Skin signs were positive in forty-seven cases and negative in seven. Tests were not made in seven cases of the series. In every

tested case of appendicitis in which the organ was not gangrenous or perforated (forty-seven) positive skin signs were present in the triangle described. Approximately half the cases of necrotic or gangrenous organs presented no skin signs. The result of this case series, then, was identical with our previous findings.

Furthermore, when the latter series is reviewed, the skin signs appear as constant and as valuable as any other sign or symptom. Figure 2 represents graphically the basis for this opinion. Excluding those cases in which sensory observations were not made (seven), the classic signs were present in fifty-four cases, as follows: pain, in 44; vomiting or nausea, 47; local tenderness, 41; local rigidity, 34; increased temperature, 45; leukocytosis, 47; skin signs, 47. The skin signs, then, were as frequent as leukocytosis or nausea and vomiting, and more frequent than typical pain, local tenderness, rigidity or temperature elevation. An analysis covering both series, or 136 cases, shows an almost identical relative frequency.

In several instances, early in the investigation, the reliability of skin tests was questioned because of the presence of positive cutaneous signs for acute appendicitis when other findings pointed to another diagnosis. However, at operation an acute appendicitis was always found. This point is illustrated in the following case:

W. T. (Case 65, Table 3), a man, aged 54, Irish, admitted, June 20, 1920, suffering from an incarcerated right scrotal hernia, had a normal temperature and pulse and had not vomited. The hernia, which had been present for twelve years, had always been reduced with ease until the morning of admission, when a physician, after unsuccessful attempts at reduction, had referred the patient to Bellevue Hospital. That evening, after several attempts, the hernia was reduced. On the second day after admission, the patient vomited twice. Rigidity of the entire lower abdomen developed and the temperature rose to 101.2 F. The blood count showed a leukocytosis of 22,000, with 87 per cent. polymorphonuclear leukocytes. The skin signs were localized within the triangle previously described. In a patient, 54 years of age, with no history of previous abdominal attacks, and with a recently reduced incarcerated hernia, the diagnosis of acute appendicitis did not seem probable, yet the skin signs were positive for that condition and the clinical picture could be explained by that diagnosis. At operation, there was found an acute hemorrhagic and suppurative appendicitis. The appendix and cecum were in the hernial sac.

The earlier studies included tests for all forms of cutaneous sensibility. Stimuli for light touch, deep touch, heat and cold were separately employed. Tests of epicritic sensibility, with cotton wool, very light scratching, temperatures of small variations, etc., gave uncertain results. Many cases that were negative to such stimuli were positive to vigorous scratching, deep pinching and the extremes of heat and cold. We finally eliminated from our routine all carefully graded stimuli and all tests employing a light grade of stimulus. The technic has narrowed to one

TABLE 3.—*Analysis of Symptoms of Patients Operated on for Acute Appendicitis on the Third Surgical Division of Bellevue Hospital, Jan. 1 to Dec. 1, 1922* *

Case	Patient	Age, Yrs.	Date	Duration, Days	Pain	Nausea or Vomiting	Previous Attacks	Tenderness	Rigidity	Mass	Temperature	Leukocytosis	Polymorphonuclears, per Cent.	Skin Signs	Findings
1	M. D.	22	1/ 3	2	+	1	2	+	+	—	101	11,800	80	+	Acute exudative
2	L. A.	13	1/16	2	+	1	Several	Bilateral	Bilateral	+	102	26,000	89	0	Acute suppurative
3	M. T.	62	1/24	6	+	2	0	+	+	+	100.2	10,200	80	+	Acute suppurative
4	E. B.	18	1/20	2	+	2	0	+	+	+	100.6	18,000	89	—	Gangrenous
5	C. L.	18	2/ 7	1	Rt. upper	N	3	+	+	—	100	15,400	79	0	Acute exudative
6	L. H.	17	2/ 2	3	General	N	0	+	+	0	100	12,800	72	+	Acute exudative
7	R. H.	21	2/14	5	+	2	0	+	—	—	100.2	11,000	81	+	Acute exudative
8	W. Z.	42	2/10	1	+	4	2	+	+	—	100	11,000	85	0	Acute exudative
9	H. W.	22	2/10	4	+	2	0	+	+	—	102	17,000	92	+	Acute suppurative
10	B. T.	24	2/15	2	+	—	0	+	—	—	102	26,000	80	+	Acute suppurative
11	A. M.	39	2/26	1	+	3	1	+	+	—	100.5	12,400	85	+	Subacute exudative
12	J. P.	35	2/20	3	+	1	0	+	+	+	101	15,800	84	+	Acute suppurative
13	O. F.	33	2/16	5	+	2	0	+	+	—	100.4	22,000	82	+	Acute suppurative
14	C. C.	36	2/28	2	+	3	0	General	General	—	101.6	22,000	84	+	Acute suppurative
15	H. C.	13	2/25	4	+	1	0	+	General	—	102	16,000	76	—	Gangrenous
16	A. H.	18	3/ 8	1	+	1	1	+	General	—	100.6	20,000	87	+	Acute suppurative
17	R. M.	34	3/ 8	1	+	N	2	+	+	—	100	16,000	85	+	Acute exudative
18	A. D.	25	3/10	0	Atypical	—	1	+	—	—	99.6	9,600	82	+	Subacute exudative
19	J. C.	37	3/27	4	+	1	0	+	0	0	99	9,000	74	+	Subacute exudative
20	A. T.	19	3/27	2	+	2	0	+	0	—	99.8	12,400	74	+	Subacute exudative
21	A. M.	23	3/28	2	+	3	1	Entire Rt.	—	—	99.4	9,200	86	+	Subacute exudative
22	G. M.	27	4/ 3	4	+	2	2	+	+	—	101	16,000	84	+	Acute hemorrhagic
23	C. D.	18	4/ 4	1	Left lower	2	0	Bilateral	+	—	100	16,600	86	+	Acute exudative
24	V. T.	33	4/14	1	+	2	0	+	+	+	102	20,400	87	—	Gangrenous
25	D. H.	43	4/16	6	+	8	0	+	+	+	100	15,000	80	+	Acute suppurative
26	L. G.	22	4/22	1	+	2	1	+	+	—	101.8	14,400	80	+	Acute exudative

27	L. P.	19	4/25	1	+	—	1	+	—	—	100.2	12,600	83	+	Acute exudative
28	P. M.	45	4/25	1	+	2	0	+	0	—	100.2	13,000	83	—	Acute suppurative
29	J. Z.	33	4/28	3	+	N	0	+	+	—	102	13,600	88	+	Acute hemorrhagic
30	W. R.	41	4/27	2	+	3	1	+	+	—	101	13,000	89	+	Gangrenous
31	P. P.	40	5/ 5	1	+	2	0	+	+	—	102.2	18,200	93	+	Acute suppurative
32	P. G.	17	5/ 7	1	+	1	0	General	+	+	101.2	14,400	81	+	Acute suppurative
33	S. B.	19	5/16	10	General	2	1	General	+	—	102	9,600	72	+	Acute exudative; tuberculous peritonitis
34	F. G.	19	5/ 5	6	General	4	Several	+	—	—	102.8	28,800	84	+	Gangrenous
35	A. T.	45	5/17	3	+	N	0	+	+	+	100.6	15,200	82	+	Acute suppurative
36	N. R.	29	6/ 4	1	+	2	0	+	—	—	100.6	9,000	95	+	Acute suppurative
37	A. H.	56	6/ 9	6	+	2	0	+	+	—	101	11,400	87	+	Acute suppurative
38	Rh. B.	38	6/ 9	1	+	1	0	+	+	—	101.4	17,000	94	+	Acute suppurative
39	W. E.	14	6/ 9	2	+	0	0	+	+	—	100.8	13,000	90	+	Acute suppurative
40	G. P.	32	6/18	1	+	1	0	Umbilical	+	—	100.2	17,000	85	+	Acute suppurative
41	K. M.	30	6/18	4	Lumbar	N	1	Rt. lumbar	Entire Rt.	—	101	14,800	88	+	Acute hemorrhagic
42	K. R.	56	6/16	2	General	1	0	+	+	—	102.2	12,800	85	—	Acute suppurative
43	J. R.	18	6/23	14	Bilateral	—	2	Umbilical	—	—	99.4	12,200	78	+	Acute exudative
44	J. O.	17	7/19	5	+	3	0	+	+	—	102.2	0	0	+	Gangrenous
45	W. W.	22	8/ 8	1	Epigastric	3	1	General	0	—	99.4	14,200	90	+	Acute exudative
46	W. S.	16	8/15	1	+	1	1	+	+	—	101.2	17,800	84	+	Acute hemorrhagic
47	A. F.	14	8/17	3	+	2	0	+	+	—	99.5	16,800	82	—	Gangrenous
48	A. R.	25	8/24	1	+	6	0	+	+	—	101	12,000	75	+	Acute exudative
49	C. L.	45	8/27	3	+	1	3	+	+	—	100.2	18,000	84	+	Acute suppurative
50	W. W.	28	9/ 2	1	+	—	1	Entire Rt.	Entire Rt.	—	99.2	17,600	87	+	Acute exudative
51	T. P.	56	9/ 6	2	General	0	0	General	General	0	100.5	9,000	77	0	Abscess, pelvic; appendix not found
52	J. M.	43	9/29	4	+	1	0	General	+	—	101	19,800	85	+	Acute suppurative
53	V. M.	23	10/10	21	+	2	0	General	—	—	99.2	9,400	72	+	Acute exudative
54	R. P.	13	10/16	2	General	4	0	+	+	—	103	29,000	94	+	Gangrenous
55	M. P.	35	10/18	1	+	1	1	+	+	—	100.2	13,000	85	+	Acute suppurative
56	J. G.	23	11/20	1	+	1	2	+	+	—	101	12,800	80	0	Acute exudative
57	L. B.	19	10/31	5	+	—	1	+	General	—	102	20,000	92	+	Acute suppurative
58	J. R.	30	10/29	3	+	1	1	+	+	—	101	16,000	78	—	Gangrenous
59	I. L.	33	11/ 4	3	+	2	0	+	+	—	101	17,600	87	0	Gangrenous
60	J. B.	18	11/ 3	1	+	6	1	+	+	—	101.2	16,000	91	+	Acute suppurative
61	J. R.	30	11/27	1	+	3	0	Bilateral	+	—	100.4	14,000	93	0	Acute suppurative

* 0, not charted; —, negative; +, present and typical; +, skin signs: those localized within triangle previously described.
The date is the discharge date. The duration is the number of periods of twenty-four hours each since onset. All data taken from the charts of the general record room of Bellevue Hospital.

form of test; namely, a vigorous twisting pinch of sufficient intensity to produce discomfort on normal skin. Such an uncomfortable pinch becomes exceedingly painful when applied with the same intensity on an involved zone. The basis of the test is the comparison of the slight discomfort on noninvolved skin with the severe pain on involved skin. One variation of this method consists in having the patient himself do the testing. Before any cutaneous tests have been made, he is shown how to pinch himself with this severe, twisting, irritating pinch and is then asked to apply it with equal intensity to all parts of his abdomen. If hyperesthetic zones are present, he will usually designate the fact and quite exactly delimit the involved area. Other methods of checking up the presence and degree of hyperesthesia are: the use of extremes of heat and cold (test tubes), deep scratching with a dull instrument, pulling the skin strongly away from the abdomen, deep pressure, etc. There is a great variety of methods of making such sensory tests, and each observer soon develops his method of choice. The essential point, regardless of methods employed, is to use a deep grade of stimulus.

The novice in sensory examinations will experience as great difficulty with the first few cases tested as does the medical student in learning properly to detect the presence and the degree of muscular rigidity. Those using these tests for the first time should familiarize themselves with the details necessarily involved in sensory examinations. Several factors causing variations in skin signs must be borne in mind, such as the effect of morphin and of the local application of an ice bag, a toxic condition in the patient, gangrene of the appendix and early herpes zoster. The skin signs must be intelligently correlated with the other phenomena of the clinical picture.

MacKenzie [7] and Head [1] wrote, in 1892, concerning skin signs in visceral disease. It was Sherren,[8] however, in 1903, who first adequately drew attention to such signs in appendicitis. His admirable paper still forms the outstanding contribution to the subject. Four years later, Robinson [11] conducted extensive studies, reviewing each point brought out by Sherren. Since that time, numerous references have been made to the subject, but no marked disagreement with the conclusions of these authors has been expressed. Among the conclusions reached by Sherren concerning hyperalgesia in appendicitis are: 1. Such cutaneous phenomena are probably present in all first attacks of appendicitis and are due to pressure within the appendix. 2. They may be absent in attacks following the first. 3. They gradually disappear during convalescence. 4. The absence of hyperalgesia in initial attacks

11. Robinson: The Clinical Bearing of Cutaneous Tenderness in Various Acute Abdominal Disorders, Especially Appendicitis, Quart. J. Med. **1**:387-416, 1908.

indicates that the appendix has become gangrenous or necrotic. 5. The position of the appendix has no bearing on the location and occurrence of hyperalgesia. 6. Hyperalgesia is occasionally of use as an aid in the diagnosis of appendicitis. Robinson's investigations agreed essentially with those of Sherren. The former, however, stated that he frequently found positive signs in the presence of gangrene or perforation of the appendix; that they were as frequent during subsequent attacks as in the initial attack, and that causes other than intralumenary pressure might give origin to the referred pain. He held that the prognostic value of such signs in cases of appendicitis was slight, but added that doubtful cases showing the hyperesthesia described by Sherren were almost always acute appendicitis. Sherren observed 124 cases, forty of which presented positive skin signs (32.3 per cent.). Robinson observed 123 cases, twenty-six being positive (21.1 per cent.).

The present article concerns observations on 136 patients of whom ten did not have appendicitis and did not have positive skin signs. Seven were not tested. Of the remaining 119, 101 presented positive signs (84.9 per cent.) and eighteen negative. In all negative cases with appendicitis the organ was either gangrenous or ruptured. The more positive findings presented in this article are due chiefly to the difference in the method of testing. Sherren stated that cutaneous hyperalgesia is tested by gently stroking the skin and that all pressure on deep structures must be avoided. Robinson wrote "It is obviously essential that pressure shall be exerted on no structure other than the skin," and that "the best way is to pinch very lightly or to stroke the skin with a common pin." We have found that such light forms of stimuli yield exceedingly uncertain results, with a percentage of positive cases closely parallel to that reported in the articles quoted. The essential of the technic here proposed is to use a twisting pinch, which is uncomfortable on any part of the skin, and undoubtedly stimulates subcutaneous and muscular sensory fibers as well as those of the skin. The severe pain caused by this grade of pinch in hyperalgesic zones is obvious, and the sign an objective one. It is likewise important to consider as positive only those cases in which the increased sensitiveness upon the anterior abdominal wall is within the triangle described; while cases in which the maximal intensity is beyond the borders of this triangle should be considered negative. Skin signs thus elicited and thus localized constitute evidence of great value in the diagnosis of acute appendicitis.

340 Lexington Avenue.

STUDIES IN EXPERIMENTAL TRAUMATIC SHOCK

VIII. THE INFLUENCE OF MORPHIN ON THE BLOOD PRESSURE AND ALKALI RESERVE IN TRAUMATIC SHOCK *

McKEEN CATTELL, Ph.D.

BOSTON

Morphin was used extensively in the treatment of the wounded during the recent war, and at the present time it is almost routinely employed by many surgeons preparatory to operative procedures in civilian practice. The experiments herein reported were made in an attempt to determine the influence of morphin on the development of shock. The problem was studied from the point of view of a possible influence on the blood pressure and on the carbon dioxid capacity of the blood. Most of the observations were made at the Central Medical Department Laboratory, Dijon, France, during the summer of 1918. Preliminary reports [1] have already been published, since which time a number of other articles have been added to the literature on the subject, and it seems worth while to present the results of these experiments in more detail.

THE EFFECT OF MORPHIN ON THE BLOOD PRESSURE

Literature.—The early work dealing with the action of morphin on the circulation has been reviewed in a paper by Witkowski,[2] published in 1877. In summing up the evidence, this author states that morphin does not affect the vagus or vasomotor centers, but that its administration results in some depression of the blood pressure through a dilatation of the vessels, especially those of the skin, which is brought about by the inhibition of impulses which normally come from the higher centers and are responsible for the tone of the blood vessels. There is no evidence that morphin exerts any important action on the vasomotor system or blood vessels in ordinary therapeutic doses. It is a matter of common observation that the skin becomes flushed after the employment of morphin, probably owing to some obscure central action, as suggested by Witkowski and also by Cushny.[3] In the isolated

---

* From the Laboratories of Physiology, Harvard Medical School.

1. Cattell, McKeen: Am. J. Physiol. **51**:197, 1920. Cannon, W. B., and Cattell, McKeen: Experimental Traumatic Shock, Arch. Surg. **4**:316 (March) 1922.

2. Witkowski: Arch. f. exper. Path. u. Pharmakol. **7**:47, 1877.

3. Cushny, A. R.: Textbook of Pharmacology and Therapeutics, Ed. 7. Philadelphia, Lea & Febiger, 1918, p. 247.

organs it has been definitely established that morphin increases the tone of smooth muscle. Macht [4] has made an extended study, using smooth muscle from the ureters, uterus, gallbladder, stomach and intestines, arteries, bronchioles, etc., and has uniformly found that morphin tends to increase peristalsis or the contractions of the organs and to raise or heighten their tonicity. Similar conclusions were reached by Okamoto,[5] using the isolated uterus.

With regard to the action of morphin on the heart in dogs and other mammals, all recent workers are agreed. Geschleiden,[6] Anders,[7] van Egmond [8] and Guinard [9] have shown that the administration of morphin results in a slowing of the heart through a central influence on the vagus center. There may be a primary increase in rate, which is not due to a direct effect of morphin but to the effect of nausea. Along with the decrease in pulse rate, there is likely to be some irregularity, but this at once disappears and the heart returns to its normal rate after double vagus section. Similar conclusions have been reached by Einthoven and Weiringa,[10] and by Eyster and Meek,[11] from investigations carried on by the use of the electrocardiograph, it being shown that the slowing and irregularities resulting from morphin injection disappeared after vagus section or the employment of atropin. Thus, there is definite evidence that in the dog morphin strongly stimulates the vagus center, but in man, with therapeutic doses, no such action has been observed. At most, there is but a slight slowing of the pulse, and this may be associated with the decreased activity. Observations on the effect of morphin on the isolated heart all point to the same conclusion: The experiments of Vinci [12] and of van Egmond [8] on the isolated mammalian heart and of Snyder and Andrus [13] and Hanzlik [14] on the coldblooded heart show that the employment of morphin results in an augmentation of tone, with an initial increase in rate followed by some slowing.

The influence of morphin on the circulation as a whole appears to be somewhat uncertain, but in any case the changes of pressure which

---

4. Macht, D. I.: J. of Pharm. & Exper. Therap. **11**:389 (June) 1918.
5. Okamoto, S.: Acta scholae med. univ. imp., Kioto **2**:307 (March) 1918.
6. Geschleiden: Unters. auf dem physiol. Lab. **2**:1, 1869.
7. Anders: Arch. f. exper. Path. u. Pharmakol. **72**:331, 1913.
8. Van Egmond: Arch. f. exper. Path. u. Pharmakol. **65**:197, 1911.
9. Guinard: Thèse de Lyon, 1898.
10. Einthoven, W., and Weiringa, J. H.: Arch. f. d. ges. Physiol. **149**:48, 1912.
11. Eyster and Meek: J. Pharmacol. & Exper. Therap. **3**:468, 1912.
12. Vinci: Arch. internat. de pharmacol. **17**:5, 1907.
13. Snyder, C. D., and Andrus, E. C.: J. Pharmacol. & Exper. Therap. **14**:1 (Sept.) 1919.
14. Hanzlik, P. J.: J. Pharmacol. & Exper. Therap. **17**:445 (July) 1921.

have been reported in man are very small. Christeller [15] finds a transitory fall in blood pressure. Frenkel,[16] on the other hand, found in man that the subcutaneous injection of 10 mg. of morphin caused either no change in blood pressure or a measurable increase. Capps and Matthews [17] were able to observe no considerable change in arterial or venous pressure following the use of moderate doses of morphin. Cushny [3] states that after the employment of morphin the blood pres-

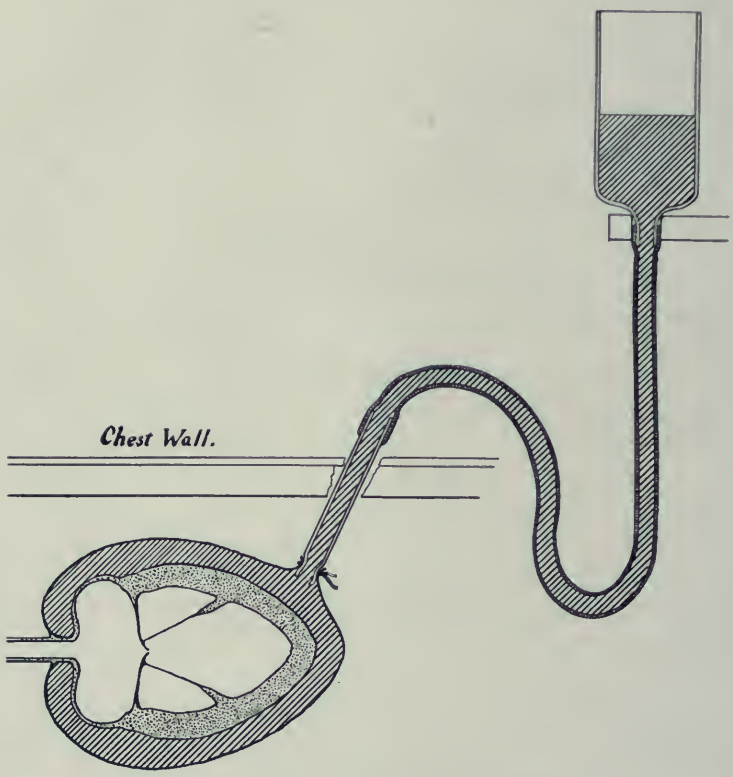

Fig. 1.—Arrangement for controlling the cardiac output and consequently the height of arterial pressure by means of increasing or decreasing intrapericardial pressure.

sure remains high and the peripheral arteries in general show no change in caliber, with the exception of those of the skin, which may be dilated. Thus, the evidence obtained from the literature gives us no reason to suppose that morphin has any deleterious action on the circulation, or that its use is contraindicated in shock.

15. Christeller: Ztschr. f. Klin. Med. **3**:33, 1881.

16. Frenkel: Deutsch. Arch. f. klin. Med. **46**:542, 1890.

17. Capps, J. A., and Matthews, S. A.: Venous Blood Pressure as Influenced by the Drugs Employed in Cardiovascular Therapy, J. A. M. A. **61**:388 (Aug. 9) 1913.

Method.—Most of the experiments were performed on cats, but in a few cases dogs were used. Except when otherwise stated, the animals were anesthetized with ether. Morphin was administered subcutaneously in the form of a solution of morphin sulphate, rather large doses being used. In all the later experiments a uniform injection of 20 mg. per kilogram of body weight was made. A series of experiments was carried out in which the blood pressure of the animal was reduced to 60 mm. of mercury for varying periods of time—a procedure which soon produces a permanent shocklike condition of low blood pressure—and comparisons made of the effect on the treated and untreated animals. The arterial pressure was reduced by a method for producing shock described in an earlier paper of this series;[18] it consisted

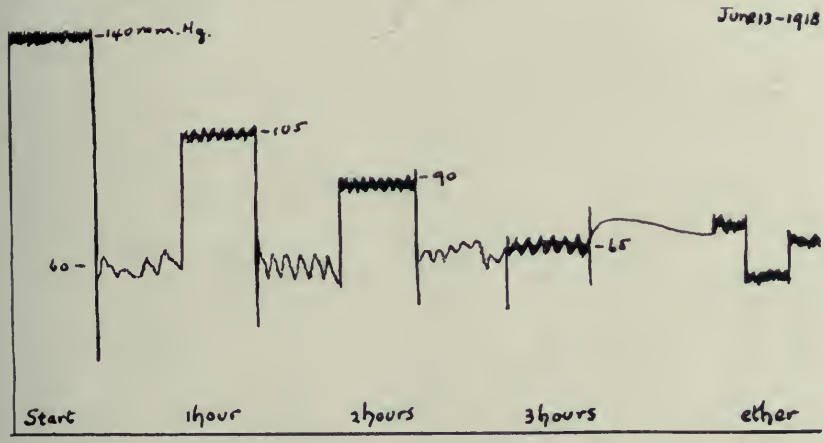

Fig. 2.—Gradual failure of the blood pressure to rise as the pressure is held at 60 mm. of mercury for successive periods of one hour and then released for five-minute intervals.

of a cannula tied into the pericardial wall and connected with a reservoir of gum-salt solution. This is diagrammatically illustrated in Figure 1.

By raising the reservoir the heart was subjected to an increased pressure which resulted in a decreased output and consequent fall in blood pressure. In this way the pressure was kept at 60 mm. of mercury; but at intervals of an hour, all pressure was removed from the heart for five minutes, and a record was made of the blood pressure at the end of the five minute period. The height to which the blood pressure rose gave a rough indication of the development of

18. Cannon, W. B., and Cattell, McKeen (Footnote 1, second reference).

shock and served as a basis for comparing the morphinized with the unmorphinized animals.

In connection with experiments on metabolism, other observations were made on the effect of morphin on the blood pressure of normal animals. In these cases ethyl carbamate (urethan), 2 gm. per kilogram of body weight, given by stomach, was the anesthetic used.

Results.—The extent of recovery of the blood pressure after the one-hour intervals of artificial depression to 60 mm. of mercury showed considerable variation, but in general the recovery became less with each successive period, until, after four or five hours, there was practically no rise in blood pressure during the five minutes following the removal of the intrapericardial pressure. A record from a typical experiment is reproduced in Figure 2, which shows the extent of the

TABLE 1.—*The Extent of Recovery of the Blood Pressure During Five Minute Intervals, Following the Reduction of the Blood Pressure to 60 mm. of Mercury for Successive Periods of One Hour, in Thirteen Control Animals*

Date	Animal	Original Blood Pressure	Blood Pressure After One Hour	Blood Pressure After Two Hours	Blood Pressure After Three Hours
May 25	Dog	120	108	74	69
May 28	Cat	174	80	70	
May 29	Cat	128	96	98	102
June 13	Cat	140	104	88	64
June 14	Cat	168	114	108	80
July 11	Cat	134	98	88	82
July 13	Cat	118	106	122	130
July 15	Cat	136	120	102	74
July 18	Cat	80	70	60	60
July 20	Cat	122	90	96	80
July 23	Cat	132	84	94	82
July 26	Cat	104	80	78	88
July 27	Cat	142	86	107	102
Average		120	97	92	84

recovery of the arterial pressure after successive hours of reduced pressure. A tabulation of the results from the individual experiments in unmorphinized animals is given in Table 1.

In a second series of experiments, carried out in a similar manner, morphin was injected just before the blood pressure was reduced. Observations on the extent of recovery of the blood pressure in morphinized animals were made in eight cases, the average pressure at the start being 128 mm. of mercury. As before, the pressure was reduced to 60 mm. It rose during the five minute periods to an average height of 105, 105 and 110 mm. of mercury after the succeeding one, two and three hours of low blood pressure. Unfortunately, the original records for four of these experiments were lost during transportation from France and so are not included in the table (Table 2.).

Figure 3 presents a comparison of the two series of experiments. On account of the individual variations it would not be safe to conclude from these few observations that morphin has a beneficial effect; but there is certainly no indication that it accelerates the production of shock.

Blood pressure records were obtained from a few animals in which the only operative procedures were the insertion of tracheal and blood pressure cannulas. These cats were under ethyl carbamate anes-

TABLE 2.—*Extent of Recovery of the Blood Pressure During Five Minute Intervals, Following the Reduction of the Blood Pressure to 60 mm. of Mercury for Successive Periods of One Hour in Four Morphinized Cats*

Date	Animal	Original Blood Pressure	Blood Pressure After One Hour	Blood Pressure After Two Hours	Blood Pressure After Three Hours	Blood Pressure After Four Hours
June 10	Cat	150	96	98	106	110
July 6	Cat	122	106	99		
July 8	Cat	128	120	120	123	121
July 11	Cat	134	96	88	82	88
Average		134	105	101	104	106

TABLE 3.—*The Effect of Morphin on the Blood Pressure of Cats Anesthetized with Ethyl Carbamate*

Date	Blood Pressure Before and After Morphin				
	One-Half Hour Before, Mm.	Just Before, Mm.	One-Half Hour After, Mm.	One Hour After, Mm.	Two Hours After, Mm.
Nov. 26	134	115	92	88	88
Dec. 9	112	140	104	122	147
Dec. 11	132	112	88	96	104
Dec. 16	140	130	125	139	136
Dec. 18	122	100	105	116	114
Average	128	119	103	112	118

thesia, and morphin was given in the usual dose (20 mg. per kilogram), subcutaneously. The effect on the blood pressure is shown in Table 3.

These experiments show a slight drop in blood pressure during the first hour previous to the administration of morphin, possibly due to the effects of the anesthesia. Immediately after giving morphin, there is a considerable further drop, but this is quite temporary. The average figures show practically complete recovery of the blood pressure to the original height within two hours after the injection of morphin. It thus appears that, in the cat, even large doses of morphin cause only a temporary depression of the blood pressure.

THE EFFECT OF MORPHIN ON THE ALKALI RESERVE

During the last few years, several investigations have appeared in the literature on the influence of morphin on the alkali reserve, all of which agree in finding an increased carbon dioxid content of the blood. As long ago as 1895, Filehne and Kionka [19] reported that blood in morphinized rabbits was richer in carbon dioxid, which they concluded was due to a respiratory depression. Barbour, Maurer and von Glahn [20] in 1916 found that the injection of morphin in human subjects resulted in an increase of alveolar carbon dioxid, indicating an increased alkali reserve. Since then Underhill, Blatherwick and Goldschmidt [21] have reported that the subcutaneous injection of mor-

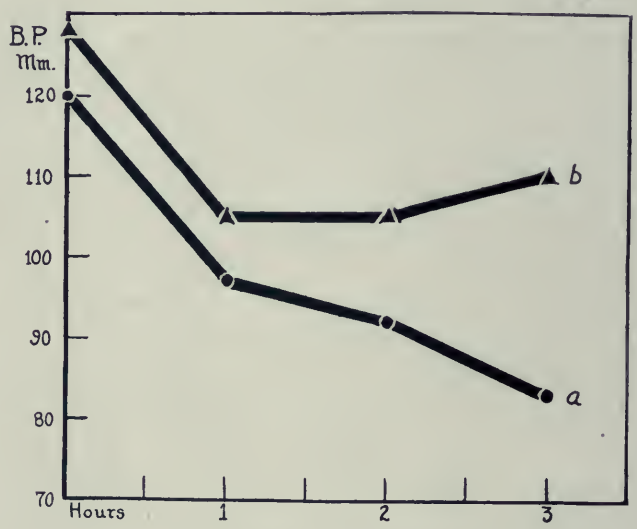

Fig. 3.—Average recovery of the blood pressure after successive hours of artificially reduced pressure in *a*, the control series, and in *b*, those animals that received morphin before pressure was reduced.

phin in dogs results in the secretion of a strongly alkaline urine, owing to the presence of carbonates; but such an effect was not obtained in rabbits. Henderson and Haggard [22] observed that morphin raises the carbon dioxid capacity of the blood, an effect which they attribute entirely to an increased alveolar carbon dioxid tension resulting from

19. Filehne and Kionka: Arch. f. d. ges. Physiol. **62**:201, 1895.

20. Barbour, Maurer and von Glahn: J. Pharm. & Exper. Therap. **8**:124, 1916.

21. Underhill, Blatherwick and Goldschmidt: Proc. Soc. Exper. Biol. & Med. **14**:83, 1917.

22. Henderson, L. J., and Haggard, H. W.: J. Biol. Chem. **33**:333 (Feb.) 1918.

the depression of the respiration. The first direct observations on the action of morphin on the alkali reserve were made by Hjort and Taylor [23] in 1919. These investigators found that in dogs gassed with fatal concentrations of chlorin there is a rapidly advancing acidosis, and that in this condition the subcutaneous injection of morphin temporarily prolongs the maintenance of a high alkali reserve. Even in normal dogs the alkali reserve was increased by morphin injections. Quite recently two other papers on the subject have appeared; Gauss [24] has found that morphin, administered subcutaneously to rabbits, dogs and sheep, distinctly increases the alkali reserve of the blood plasma, and slightly increases the hydrogen ion concentration. In four trials in man a dose of from one-quarter to one-half grain of morphin produced but a slight and uncertain increase in the alkali reserve. Stehle, Bourne and Barbour,[25] working on dogs, found that with ether-morphin anesthesia there was, as a rule, practically no fall in the carbon dioxid capacity of the blood, whereas with ether alone the carbon dioxid capacity was distinctly reduced.

Method.—In the following experiments an effort was made to determine the effect of morphin on the reduction of the alkali reserve which occurs in shock and low blood pressure. The method used was similar to that carried out in another research [18] in determining the effect of uncomplicated low blood pressure on the alkali reserve, and some of the results of this work were used as a basis for comparing the morphin effects in the present research. Most of the experiments were performed on cats, but in a few cases rabbits or dogs were used. Ether was found to be a satisfactory anesthetic, preliminary observations showing that under the conditions of the experiments, it produced but a slight decrease or no effect on the alkali reserve. A cannula was placed in the pericardium for the control of the arterial pressure, which in these experiments was uniformly reduced to 60 mm. of mercury. The details of the method are outlined in the first section of this paper. The blood pressure was recorded by a mercury manometer connected to one carotid, and a second cannula was placed in the other carotid or the femoral artery to obtain blood samples for the bicarbonate determinations. For each analysis about 3 c.c. of blood was taken in a graduated tube, centrifuged and the alkali reserve of the plasma determined by the Van Slyke [26] method. Just before

23. Hjort, A. M., and Taylor, F. A.: J. Pharmcol. & Exper. Therap. **13**:407 (Aug.) 1919.

24. Gauss, H.: J. Pharmacol. & Exper. Therap. **16**:475 (Jan.) 1921.

25. Stehle, R. L., Bourne, W. and Barbour, H. G.: J. Biol. Chem. **53**:341 (Aug.) 1922.

26. Van Slyke, D. D.: J. Biol. Chem. **30**:347 (June) 1917.

reducing the blood pressure and at intervals of an hour throughout the course of the experiment, a blood sample was taken. Usually, no difficulty was experienced in keeping the arterial pressure at the desired level of 60 mm. of mercury. Sometimes, just after reducing the blood pressure, it was necessary to adjust the pressure on the heart repeatedly in order to hold it constant, but usually an equilibrium was reached in a short time. A few experiments had to be discarded on account of irregularities of pressure. Morphin was given by subcutaneous injection, in large doses; i. e., from 10 to 20 mg. per kilogram of body weight. In some of the experiments this injection was given

TABLE 4.—*Blood Pressure Reduced to Sixty Millimeters for One Hour*

Date	Animal	Original Blood Pressure	Alkali Reserve	
			Start	One Hour
May 10	Cat	178	38	35
May 11	Cat	124	31	20
May 24	Rabbit	...	27	18
June 5	Cat	...	37	20
July 15	Cat	136	30	19
July 16	Cat	114	26	19
Average	....	...	31.5	21.8

TABLE 5.—*Blood Pressure Reduced to Sixty Millimeters for Three Hours*

Date	Animal	Original Blood Pressure	Alkali Reserve				
			Start	One Hour	Two Hours	Three Hours	Four Hours
May 9	Cat	130	39	36	32	32	
May 25	Dog	120	33	22	20	19	20
May 29	Cat	128	35	32	33	33	
June 13	Cat	140	31	14	18	19	
July 13	Cat	118	37	29	29	27	29
July 20	Cat	109	33	30	25	27	
Average	....	...	34.7	27.1	26.1	26.1	

before the reduction of the blood pressure, and in others, not until after the animal had been subjected to the low pressure for an hour.

Results.—The results of the determinations of the alkali reserve for the whole series of animals, with and without morphin, are summarized in Tables 4, 5, 6 and 7.

Tables 4 and 5 give figures obtained from animals in which the pressure was reduced to 60 mm., but to which no morphin was given. It will be seen that there is quite uniformly a marked decrease in the alkali reserve, which occurs largely during the first hour of reduced blood pressure and remains low throughout the course of the experiment. Table 6 shows the result of injecting morphin after the pres-

sure had been low for one hour and the alkali reserve already at a low reading. The average figures show a recovery of the alkali reserve, which during the following two hours nearly reaches the normal figure. The prevention of the usual acidosis, when morphin is injected before reducing the blood pressure, is shown by the averages given in Table 7, in which there is but a slight reduction of the alkali reserve during the first hour, and after three hours the figure is actually above that at the start before the blood pressure is reduced. The averages for these experiments are plotted in the curves illustrated in Figure 4.

TABLE 6.—*Effects of Morphin Given One Hour After Reduction of Blood Pressure to Sixty Millimeters of Mercury*

Date	Animal	Original Blood Pressure	Alkali Reserve				
			Start	One Hour	Two Hours	Three Hours	Four Hours
June 7	Dog	138	24	15	11	12	18
June 8	Dog	128	23	16	20	22	23
June 10	Cat	150	35	21	27	29	34
June 17	Cat	120	35	35	37	42	
June 18*	Cat	118	30	20	21	31	
June 19*	Cat	150	32	23	23	28	
June 20	Cat	156	36	21	23	22	22
June 24	Cat	120	26	24	29	35	36
Average	....	...	30.1	21.9	23.9	27.6	

TABLE 7.—*Effects of Morphin Given Just Before Reducing Blood Pressure to Sixty Millimeters of Mercury*

Date	Animal	Original Blood Pressure	Alkali Reserve				
			Start	One Hour	Two Hours	Three Hours	Four Hours
June 26	Cat	100	32	34	39	37	35
June 27	Cat	134	35	32	36	37	39
June 29	Cat	142	29	27	27	31	33
July 8	Cat	114	41	33	35	34	
Oct. 27*	Cat	128	30	34	33	32	
Oct. 29*	Cat	120	34	33	34	37	35
Average	....	...	33.5	32.2	34.0	34.7	

Comment.—The explanation of the influence of morphin in preventing the development of acidosis and in increasing the alkali reserve is not clear. Henderson and Haggard [22] have shown that changes in the carbon dioxid capacity of the blood follow changes in the respiration, and explain the action of morphin by its effect in depressing the respiratory center. This, however, cannot be the whole explanation, as similar changes were found in those experiments carried out under artificial respiration at a uniform rate. In Tables 6 and 7 the experiments marked with an asterisk were carried out under artificial respiration, and the changes in the alkali reserve do not differ markedly from

the general averages. It seemed possible that the recovery of the alkali reserve under the influence of morphin might be associated with a reduction of the oxygen requirements, through a fall in metabolism, so that the circulation even at the low pressure became adequate, and a few experiments on the effect of morphin on the metabolism have been carried out to test this view.

THE INFLUENCE OF MORPHIN ON METABOLISM

The experiments described under this heading were carried out in collaboration with Dr. J. C. Aub and Miss E. M. Bright.

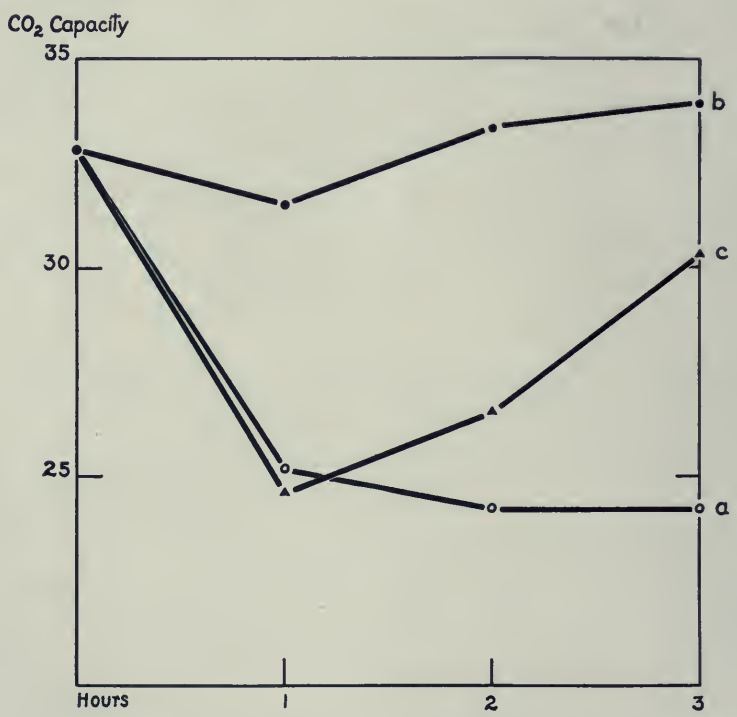

Fig. 4.—Changes in percentage by volume of carbon dioxid (the alkali reserve) of the blood plasma in cases in which the blood pressure was lowered to 60 millimeters of mercury for three hours, in *a* without other action, in *b* with previous injection of morphin and in *c* with morphin injected after one hour of low pressure.

Literature.—A recent paper by Hjort and Taylor [23] opens with the statement that "the depressant action of morphin upon the various bodily functions leads, as is well known, to a diminished metabolism, as indicated, for example, by lessened carbon dioxid excretion by the lungs." It is generally assumed that morphin and other narcotics

depress the metabolism, and such statements occur frequently in the literature, but the experimental evidence upon which they are based is not evident. As long ago as 1874 Boeck and Bauer [27] made observations on the respiratory exchange under morphin in a cat and dog, finding an increase in the cat and a reduction of about 30 per cent. in the dog. From these experiments it was concluded by Voit [28] that morphin depressed the metabolism by decreasing muscular activity. Fubini [29] obtained a drop of nearly 50 per cent. in the metabolism of dogs and rabbits during the twenty-four hours following the subcutaneous injection of 10 mg. of morphin sulphate. On the other hand, there was but a slight drop with guinea-pigs, and with lemmings and doves there was a slight increase. Grehant [30] observed a similar drop in dogs in morphin sleep. Impens [31] and Dreser [32] report a depression in the metabolism from diacetylmorphin. Tangl and Versar [33] found the effects of morphin on the metabolism of dogs and rabbits small and inconstant, it being increased in many cases, the result depending on the activity of the animal. The oxygen consumption in two men in normal and morphin sleep was studied by Loewy,[34] the conclusion being reached that the respiratory exchange was not materially affected. The effect of morphin on the metabolism of man has been investigated by Higgins and Means,[35] who found that the total gaseous metabolism showed, as a rule, no change in oxygen consumption or a very slight diminution and a marked drop in carbon dioxid elimination after the administration of both morphin and diacetylmorphin. Chanutin and Lusk [36] have recently published the results of a careful study on the influence of morphin upon the heat production in two dogs. One animal showed an average reduction of 6.2 per cent. of the heat production below the basal level following the administration of 15 mg. per kilogram of body weight, with no change in the respiratory quotient. In the other dog the metabolism was increased on an average of 10 per cent. and the respiratory quotients were higher. There is evidently no great uniformity in the results obtained by the

27. Boeck and Bauer: Ztschr. f. Biol. **10**:336, 1874.
28. Voit, Carl: Handbuch der Physiologie, Leipzig, F. C. W. Vogel, 1881, p. 178.
29. Fubini: Untersuch. z. Naturl. d. Mensch. u. d. Thiere **12**:563, 1881.
30. Gréhant: Comp. rend. Soc. de Biol. **110**:221, 1882.
31. Impens: Arch. f. d. ges. Physiol. **78**:527, 1899.
32. Dreser: Arch. f. d. ges. Physiol. **72**:72, 1898.
33. Tangl and Versar: Biochem. Ztschr. **92**:318, 1918.
34. Loewy: Berl. klin. Wchnschr. **28**:434, 1891.
35. Higgins, H. L., and Means, J. H.: J. Pharm. & Exper. Therap. **7**:1, 1915.
36. Chanutin, A., and Lusk, G.: J. Pharm. Exper. & Therap. **19**:359 (June) 1922.

different investigators, but, on the whole, the conclusion reached by Voit, forty years ago, that morphin affects metabolism only indirectly by decreasing muscular activity best fits the evidence at hand.

Method.—Our experiments on the influence of morphin on the gaseous exchange were all carried out on cats, anesthetized with ethyl carbamate (urethan), 2 gm. per kilogram of body weight given by stomach. Observations on the body temperature were made by means of a rectal thermometer, and the temperature of the animal was kept uniform by the use of an electric heating pad. Blood pressure records were obtained by means of a mercury manometer through a cannula in one carotid. A T-shaped glass cannula was inserted in the trachea, to which Tissot valves were attached for obtaining the expired air. This was collected in two 8-liter copper spirometers. Immediately after collection, air samples were withdrawn from the spirometer and preserved under pressure in the usual type of glass sampling tube. Analyses were made in a Haldane gas apparatus. After two preliminary control periods, morphin was given by the subcutaneous injection of a solution containing 20 mg. per kilogram of body weight. Details of the experimental procedure were described by Aub [37] in an earlier paper of this series.

Results.—Experiments on the effect of morphin on the gaseous exchange have been carried out in five animals. The results are summarized in Table 8. The figures represent the number of cubic centimeters of carbon dioxid expired each minute. The times for the successive periods represent the time before or after the morphin injection, and are approximate, there being a variation of a few minutes in the time the periods were started in different experiments.

An examination of the average of the results for the five animals shows that there is a fall of about 13 per cent. in oxygen consumption immediately after the injection of morphin, but this is temporary, the average amount of oxygen used returning to the original figure by the end of two hours. The carbon dioxid elimination per minute shows a more marked decrease after the administration of morphin, and consequently a lower respiratory quotient, indicating a considerable retention of carbon dioxid. As in the case of the oxygen, there is a return to the normal figure in the course of two hours. The normal ratio between the oxygen and carbon dioxid is recovered even more quickly, the average figure for the respiratory quotient showing a return almost to the original level by the end of the first hour after the administration of morphin.

---

37. Aub, J. C.: Am. J. Physiol. **54**:388 (Dec.) 1920.

Comment.—While these experiments are too few to permit the deduction of any general conclusions, as far as they go they do not indicate that the increase in the alkali reserve caused by morphin in reduced blood pressure is brought about by depression of the metabolism. The decrease in oxygen utilized is not very great, and is probably partially accounted for by the depression of the respiration, the minute volume being decreased, on the average, by nearly 50 per cent. Moreover, immediately after the administration of morphin there is a fall in arterial pressure, which might account for a slight decrease in the oxygen consumption. Further, the very short duration of the depression of the metabolism does not correspond to the increased alkali

TABLE 8.—*Utilization of Oxygen and the Carbon Dioxid Elimination in Cubic Centimeters per Minute Before and After the Injection of Morphin*

Date	Control Periods				Periods Following Morphin							
	First Period —¾ Hour		Second Period 0 Hours		Third Period ¼ Hour		Fourth Period 1 Hour		Fifth Period 2 Hours		Sixth Period 2½ Hours	
	Oxygen	Carbon Dioxid	Oxygen	Carbon Dioxid	Oxygen	Carbon Dioxid	Oxygen	Carbon Dioxid	Oxygen	Carbon Dioxid	Oxygen	Carbon Dioxid
Nov. 26.....	26.73	20.37	25.37	18.25	24.69	16.32	24.88	17.75	23.50	16.58		
Dec. 9.....	23.31	16.35	21.35	15.68	20.45	13.38	23.59	16.62	28.45	20.48	26.38	20.55
Dec. 11.....	21.03	15.96	20.75	15.50	18.81	13.51	16.53	10.93	18.57	12.77		
Dec. 16.....	28.07	16.91	29.65	19.36	21.31	11.73	23.59	15.07	28.86	19.63	25.99	17.70
Dec. 18.....	25.00	17.09	24.75	17.69	20.15	12.54	26.07	18.07	25.16	17.26	28.45	21.78
Average.....	24.83	17.34	24.37	17.30	21.08	13.50	22.93	15.79	24.91	17.34		
Respiratory quotient.....	0.70		0.71		0.64		0.69		0.70			
Average blood pressure.....	128		119		103		112		118			

reserve which occurs over a much longer period; and this speaks against it as a cause of the change. It should also be mentioned in this connection that normal animals, as well as animals with a low blood pressure, react to morphin with an increase in the alkali reserve, and in these animals there is no reason why a depression of the metabolism should improve the adequacy of the circulation.

The lowered respiratory quotients occurring immediately after the injection of morphin are of interest. A similar condition in human subjects was observed by Higgins and Means [35] after the injection of therapeutic doses of morphin. These authors considered the possibility that this decrease in the elimination of carbon dioxid was due to a change in the character of the metabolism such as incomplete combustion, or to the changing of fat to sugar, or to storage of carbon dioxid because of respiratory depression. Since the retention of the carbon dioxid following the injection of morphin, in our experi-

ments, occurs during the same period as the increase in the alkali reserve, it seems possible that there is some relation between the two effects, the increasing carbonate content of the blood being responsible for the lessened output of carbon dioxid through the lungs. This leaves us still without any explanation, however, as to how morphin brings about an increase in the alkali reserve.

SUMMARY

1. In the cat, morphin does not accelerate the production of shock, as measured by the blood pressure, and in the normal animal, even in large doses, it causes only a temporary depression of the blood pressure.

2. The reduction of the blood pressure to 60 mm. of mercury in control animals resulted in a rapid fall of the alkali reserve which remained at a low level. With morphin, however, in the large doses used, the low pressure resulted in practically no reduction of the alkali reserve, or, if the morphin was injected after an hour of low pressure, when the carbon dioxid capacity of the blood was already low, there was recovery almost to normal during the following two hours.

3. Experiments, carried out in collaboration with Dr. J. C. Aub and Miss E. M. Bright, indicate that in the cat the injection of morphin in large doses results in only a slight and temporary fall in gaseous metabolism. The changes in the gaseous exchange are probably not sufficient to explain the increase in the alkali reserve through a decrease in the oxygen requirements of the tissues.

PROLONGED INTRAVENOUS INFUSION AND THE CLINICAL DETERMINATION OF VENOUS PRESSURE *

WILDER G. PENFIELD, M.D.
AND
DAVID TEPLITSKY, M.D.
NEW YORK

"Force fluids" has come to be a therapeutic maxim with the medical profession. For a patient with almost any acute condition, whether it is infection, toxic absorption or surgical shock, the sovereign remedy in most clinics is more water. There is quite a large group of patients who are, for the time being, unable to take liquids satisfactorily by mouth or by rectum, or for whom these routes of administration are too slow. In such cases, a method of administering large amounts of liquid directly into the blood stream slowly and with sufficient safeguards is of great service. The method presented was worked out at the suggestion and with the helpful criticism of Professor Whipple. It provides for automatic control of the rate and temperature of the infusion and makes it possible to observe, at frequent intervals, the recipient's venous pressure, the all important index of his reaction to infusion.

METHOD

After a number of trials and failures, the present method of controlling the rate of flow of the infusion was at last worked out, along lines proposed by one of us (D. T.). The apparatus consists of a liquid reservoir connected in the ordinary way with a venipuncture needle by rubber infusion-tubing (Fig. 1).

In this tubing is inserted a needle valve (*N*), so made that turning the handle alters the size of the aperture for the liquid very gradually. This needle valve, which was made of Monell metal so it would not corrode, regulates the flow. Between the needle valve and the vein, there is inserted, by means of a T tube, a simple manometer (*M*), held in a split rubber cork, which can be raised or lowered on a meter stick. The height of the fluid in this manometer required for any particular rate of flow would depend principally on the bore of the needle used, provided the smallest diameter in the system was that of the needle. It was decided to use large venipuncture needles (size 16) with an adapter (*A*) whose bore is smaller. The adapter is a metal connecting piece between tubing and needle. It is well to secure unbored adapters and bore all with the same drill. (A No. 65 drill was used, giving a diameter of 0.034 inch.) Thus, the bore will remain unchanged in case a substitution has to be made for the original adapter. An infusion thermometer (*T*) may be inserted

* From the Department of Surgery, Columbia University, and the Presbyterian Hospital.

into the tubing at a short distance from the needle. It is best to use one which registers above the boiling point of water, so that it may be boiled with the rest of the apparatus. It must have a large diameter to avoid an increase in the resistance to the flow of fluid.

A coil of the rubber tubing is placed in the water of the bath to maintain a constant temperature in the liquid entering the blood stream. This heating chamber is a most important part of the equipment (Fig. 2). It is made of an inner and outer wall of copper, completely separated by a lining of asbestos. A wooden cover is provided with holes for entrance and exit of the tubing, and to admit a thermometer. A solid copper bar (*C*), 2 cm. square, is beaten out into the shape of a fan at one end. As the bar passes through the outer wall, it is completely surrounded by asbestos. It touches and is soldered to the inner wall

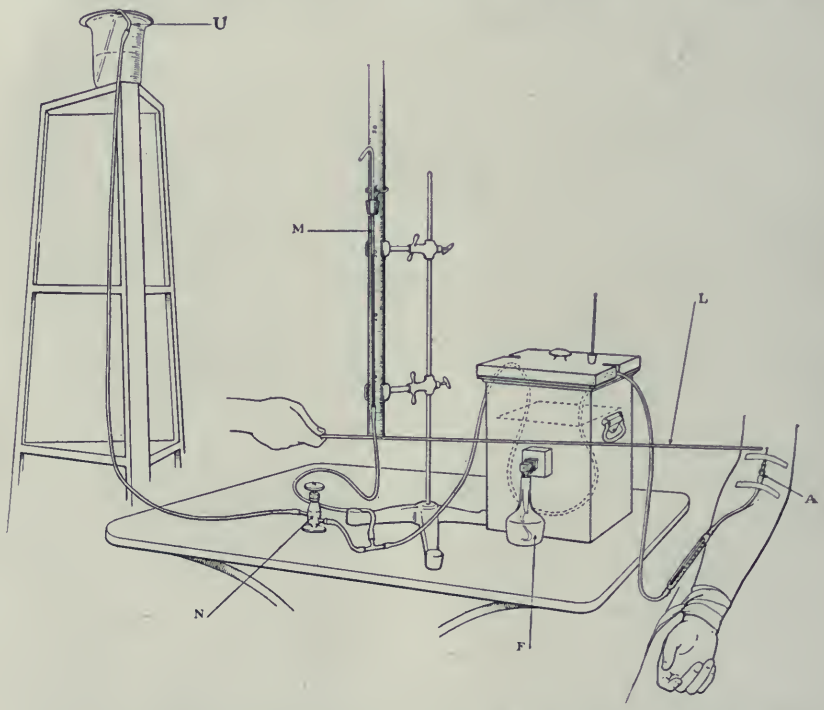

Fig. 1.—Continuous infusion apparatus; *N*, needle valve; *M*, manometer; *F*, alcohol lamp heating the end of the copper bar; *L*, level; *A*, adapter.

Thus, heat applied to the external end of the copper bar is conducted directly into the fluid, without any of it being lost on the outer wall. If the container is filled with water at a temperature of 120 F., and an ordinary alcohol lamp with metal chimney is placed so that the flame licks the projecting end of the copper bar, the temperature in the bath is maintained for three or four hours during an infusion, with little variation. The temperature of the infusion fluid as shown by the infusion thermometer is thus kept at from 98 to 100 F. It can be varied by altering the amount of tubing in the water of the heater.

Electrical heaters of various kinds were devised and tried out, but they were all discarded. Either a hot plate or an immersion heater provided with resistance wire grows dangerously hot in time. If a resistance outside the water heater is used to reduce the heat, this new resistance coil may become

dangerously hot. If a resistance outside the water heater is used that will reduce the current with sufficient accuracy, the apparatus is rendered complex. Hot air boxes heated by electric light bulbs are satisfactory except that, when the infusion is stopped for a time and then resumed, the infusion liquid which had been halted in the box will be delivered at the needle dangerously near boiling. Various types of gas and electric thermoregulators are satis-

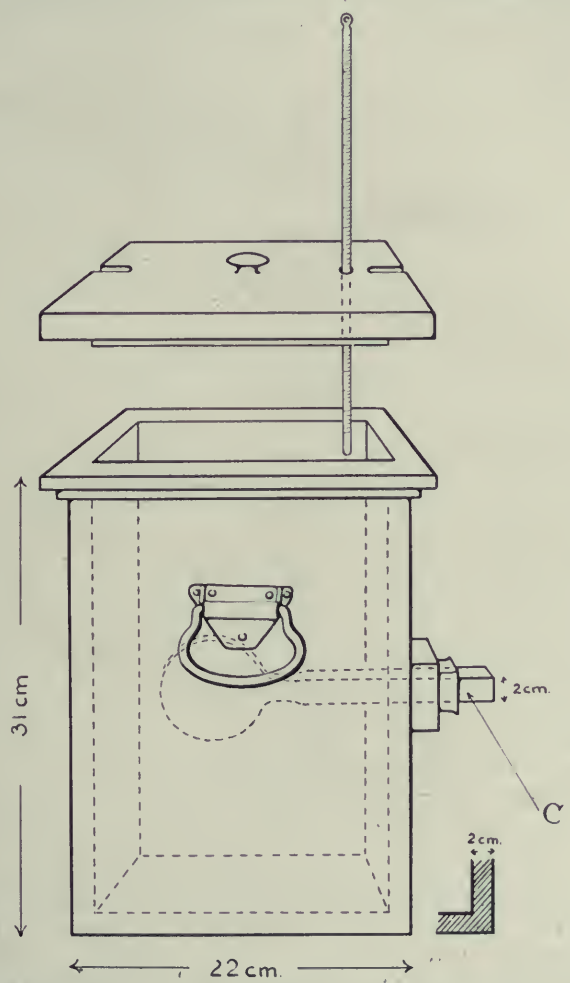

Fig. 2.—Heating bath: *C*, solid copper which conducts heat into the bath. The double walls are separated by asbestos.

factory under laboratory conditions but are not sufficiently "fool proof" for routine, clinical use. It must be possible for the heater to be handed over from one hospital intern to another without its becoming a source of danger.

The amount of heat desired is small; the heat of the source should therefore be small, for safety's sake. The ideal heater should be pro-

vided with a large amount of substance of a high specific heat maintained at a low temperature. Thus, if the infusion is halted, the temperature of the heater rises a negligible amount, and the fluid which has been halted in the heater is not dangerously hot even at the heater's full temperature. The heater should be little influenced by the temperature of the room and should be as close to the patient as possible. It must be simple. All of these requirements are fulfilled by the hot water bath described.

Procedure of Infusion.—At the close of each infusion, the apparatus is thoroughly cleaned and dried by the nursing staff, and all the tubing is reconnected ready for sterilization. The following instructions were drawn up (with the help of Miss M. W. Wilson) and are kept on a card with the apparatus.

LIST OF APPARATUS

To be sterilized (in distilled water):
- Infusion tubing including the needle valve
- T tube, thermometer and special adapter
- 1 short glass U tube
- 1 long glass U tube (manometer)
- 1 20 c.c. syringe
- 1 medicine glass
- 4 venipuncture needles No. 16
- 2 artery clamps

Already sterilized:
- Graduated 2,000 c.c. beaker
- Watch glass cover

Not to be sterilized:
- Ring stand with 2 clamps
- Meter stick with sliding carrier
- Level (glass tube with bubble)
- Tourniquet
- Water bath with cover and thermometer
- Alcohol flame with metal chimney

CARE OF SET

At close of infusion:
- Disconnect tubing, clean, wash through and test as for other sets.
- Also clean needle valve, connecting tube and thermometer.
- Unscrew needle valve to clean.
- Carefully remove, clean out and replace the special adapter, leaving needle wire in it.
- Replace tubing as before:
- Tubing from adapter to thermometer, 15 cm.
- Tubing from thermometer to T tube, 100 cm.
- Tubing from T tube to needle valve, 15 cm.
- Tubing from needle valve to short U tube, 160 cm.
- Tubing from T tube to manometer, 60 cm.
- Beaker and watch glass to be cleaned and dried, and sent for sterilization in a drum.

The steps in the infusion procedure are briefly as follows:

The heater and ring stand with meter stick are placed on a table by the bedside. A bandage is tied about the patient's wrist and fastened to the bed spring. The 2,000 c.c. graduated beaker is filled with infusion fluid and covered with a large watch glass. Gloves are then put on and a sterile towel is spread on the table over the foot of the ring stand. The infusion apparatus is taken from an adjacent bedside table, where it has been placed by the nurse. The short U tube (*U*, Fig. 1) is placed in the reservoir and the manometer tube in the split rubber cork. Siphonage is started with a syringe, and the liquid is allowed to flow until the tubing is well washed out. The tubing is shut off near the adapter with an artery clamp. The needle valve is then closed. Liquid will now be standing in the manometer tube ready to wash out the venipuncture needle as soon as the needle and adapter are connected after making the puncture. It is important to remove the artery clamp in order to wash out the needle as soon as the connection is made, for a clot in the adapter alters the rate of flow. The needle valve is opened enough to maintain a small flow, and the puncture needle and adapter are strapped to the arm with adhesive.

By means of a long sealed glass tube of liquid containing a bubble which may be used as a level (*L*), the lower end of the meter stick is brought to the same level as the punctured vein (Fig. 1). The lower end of the meter stick is then zero for venous pressure estimation; and the needle valve is shut off. The level of fluid in the manometer will then fall, showing respiratory and cardiac variations, to a level which, when read on the meter stick, gives the venous pressure in centimeters of water. The needle valve is opened until the level of the fluid in the manometer is a sufficient distance above the venous pressure height to deliver the desired quantity of fluid per hour. The number of centimeters above venous pressure necessary to deliver any particular amount of fluid may be learned by reference to a graphic chart previously prepared (Fig. 3). This graph must be worked out for the bore of adapter and needle which it is decided to use. This can be done in the laboratory once for all, and the accuracy of the method can be tested by using a rubber tube attached to a hydrant as a substitute for the patient's vein.

After the infusion apparatus is set to run at the desired rate, the venous pressure should be reread by pinching the tubing between manometer and reservoir at the end of a half hour, and at least every hour thereafter. If the pressure has varied, the height of the liquid in the manometer should be altered accordingly. If clotting in the needle and adapter is avoided as described above, the delivery of the fluid will be found quite accurate. At times there may be a variation of as much as 100 c.c. per hour.

A small rise in the venous pressure is always associated with a corresponding automatic rise in the manometer level, the rate of flow remaining very nearly constant. A larger rise, which is an indication of

an unfavorable reaction to an infusion, will be signalized by an overflow of liquid from the top of the manometer. This, as will be shown below, is of the utmost importance. A kink in the tubing or other obstruction has, of course, the same result.

INFUSION SOLUTIONS

In the continuous infusions recorded here, physiologic sodium chlorid solution and glucose solution (less than 10 per cent.) were used. These solutions are prepared each day from freshly distilled water and weighed

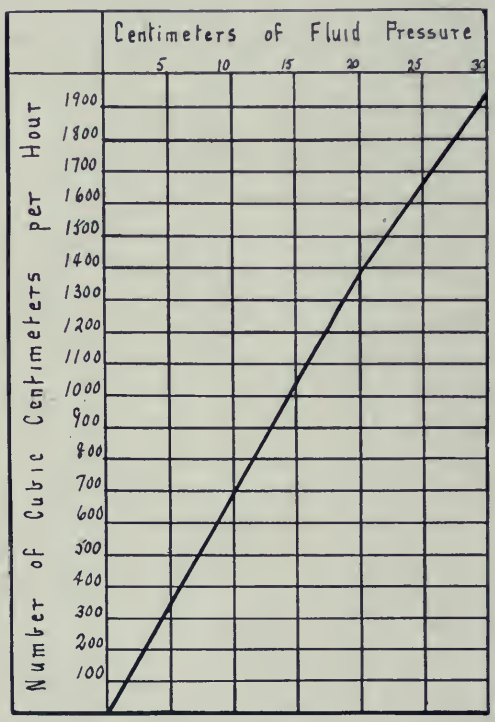

Fig. 3.—Graphic chart for setting the infusion rate. This graph would be changed by alteration in the bore of adapter and needle used.

amounts of sodium chlorid or glucose. The fluids are used within twenty-four hours after sterilization. The infusion fluids thus prepared for routine use were examined at intervals over a period of several months, and the hydrogen ion concentration was found to average from 6.0 to 6.2, the extremes being 5.8 and 6.6. These values, obtained by the colorimetric method, make it clear that the infusion fluids were consistently acid as compared with blood. At the present time, investigation is in progress to produce a simple clinical method of adjusting the intravenous fluids to a p_H approximating 7.4, the normal for whole human

blood. The use of buffer salts or correction with a weak basic salt, such as disodium phosphate, is being studied.

There have been three reactions in this series of prolonged intravenous infusion.

One patient (Case 20) presented the following picture. One half hour after the infusion had been started, the intravenous pressure had risen 4 cm. Shortly thereafter, the patient began to feel cold and developed a real shaking chill of about ten minutes' duration. The temperature rose from 100 to 103.4 F.; the pulse rate increased from 108 to 140, and the respiratory rate, from 30 to 50. In addition, there seemed to be dilatation of the stomach. By lavage the patient was relieved of a moderate amount of gas and stomach contents. She felt much relieved, and there were no remote effects noted. The other two patients showed the same rise in venous pressure, chill, fever, and rise in pulse and respiratory rates. The reaction in these cases all came within the first hour. There were no gastric symptoms.

It is of interest to consider what caused, or contributed to, such reactions. Three factors appear to deserve special attention: (1) the temperature of the infusion fluid; (2) the hydrogen ion concentration of the solutions, and (3) the possible introduction of foreign substance into the blood stream.

To study the effect of extremes of temperature in infusion solutions, a limited number of experiments were undertaken.

A normal adult dog weighing 5.5 kg. was anesthetized with ether after receiving one eighth grain of morphin hypodermically. A cannula was placed in the right jugular vein. Anesthesia was stopped at the end of the operative procedure, which was of not more than fifteen minutes' duration. The infusion was begun when the dog was conscious and quiet. Seven hundred cubic centimeters of Ringer's solution, freshly prepared and sterilized, was infused slowly. The temperature of the infusion was maintained at 115 F., but there was no reaction to this high temperature. The solution was cooled to as low as 60 F., also without change. The dog's rectal temperature fell gradually from 97.1 to 95 F. If cooling of the blood stream acts directly on the temperature control centers, one would expect a rise in temperature in response to cooling the infusion, but none resulted.

In order to rule out the possible effect of sedatives and anesthetics, two dogs from whom one half of the brain had been removed six and seven days previously, and who had preserved their capacity for temperature control, were studied. In one, the saphenous vein of the limb opposite the side of decerebration was perfused with Ringer's solution varying between 115 and 68 F. No chill was produced. The rectal temperature rose slowly throughout the experiment, being apparently little influenced by alterations in the temperature of the infusion. In the other semidecerebrate animal, heat and cold were applied in turn to an exposed carotid, without upsetting the animal's heat regulating mechanism.

These experiments lead to the conclusion that an infusion liquid may vary greatly in temperature without producing a reactionary chill in dogs.

Variation in hydrogen ion concentration was next considered as a possible cause of reaction. Williams and Swett [1] called attention to the fact that fluids introduced into the vascular system varied a great deal in their hydrogen ion concentration. They had examined distilled water, physiologic sodium chlorid solution and glucose solutions, and had found them all to be of a rather low hydrogen ion concentration; i. e., acid to that of blood. They also showed that the p_H was lowered when fluids were heated or allowed to stand for any length of time. On the other hand, Mellon, Slagle and Acree [2] mention the high p_H of sodium citrate (i. e., a p_H of 10.5 in one sample), and attribute the reactions that sometimes occur in the citrate method of transfusions to such high p_H figures. Van Slyke [3] has shown the constancy with which whole human blood is kept at p_H 7.4. A higher hydrogen ion concentration in the blood (7.8) is associated with tetany (alkalosis). A lower hydrogen ion concentration (6.95) is accompanied by coma (acidosis). In the light of this work, it would seem difficult to explain the reactionary chills reported here on a basis of the rather low p_H of the fluid used (6.0 and 6.2), and animal experiments were performed which bore out this conclusion.

An interesting and striking example of the effects of introducing highly acid fluid into the vascular system was afforded in one of our experiments. An adult dog weighing 9.8 kg. was anesthetized with ether. After a cannula had been tied into the right external jugular vein, the animal was allowed to recover from the anesthetic. Infusion with fluid having a calculated p_H of 4.49 was then begun. The rectal temperature at the start of the infusion was 96 F. At the end of fifteen minutes, nothing extraordinary was noted; there were no chills and no rise in temperature; respiration and cardiac rate seemed normal. Two minutes later, respirations ceased rather suddenly, though the heart continued to beat. The infusion was stopped and artificial respiration instituted. The animal gasped several times, and then the heart stopped beating. Up to the time of the interruption of the infusion, 450 c.c. of fluid had been given. Examination failed to show anything more than engorgement of the right auricle and its tributary veins. The picture was that of a sudden respiratory failure. In this instance, the buffers of the blood stream were probably unable to cope with the sudden influx of highly acid fluid.

This experiment emphasizes the danger of too acid infusions. On the contrary, in another experiment, the p_H of the infusion fluid was

1. Williams, J. R., and Swett, Madeleine: Hydrogen Ion Concentration Studies on Distilled Water, Physiologic Sodium Chlorid, Glucose and Other Solutions Used for Intravenous Medication, J. A. M. A. **78**:1024 (April 8) 1922.

2. Mellon, R. R.; Slagle, E. A., and Acree, S. F.: The Practical Application of "Buffers" in the Regulation of Hydrogen Ion Concentration of Intravenous Solutions, J. A. M. A. **78**:1026 (April 8) 1922.

3. Van Slyke, D. D.: Studies of Acidosis; Normal and Abnormal Variations in Acid Base Balance of Blood, J. Biol. Chem. **48**:153 (Sept.) 1921.

raised to 9.18 without untoward symptoms of any sort. Therefore, neither change in temperature of infusion fluid nor low p_H is a likely cause of reactionary chill.

The third suspected factor remains to be considered; i. e., the introduction of foreign substance into the fluid. In at least two of the three cases of chill, new tubing had been introduced into the apparatus, which was then being perfected. By some oversight, this tubing did not receive the careful cleansing which has always been a routine procedure [4] in the Presbyterian Hospital. New tubing is found to contain considerable amounts of powder. This we have assumed to be the cause of reactions in our cases, and since we have taken pains to see that all new tubing is adequately cleansed, there have been no reactions. Although we feel that acid solutions used intravenously do not cause reactionary chills, this opportunity is taken to emphasize their danger.

As has been stated, further work is being done to render practicable a method of securing physiologic hydrogen ion concentration after sterilization, as suggested by the work of Williams and Swett.[1]

CLINICAL RESULTS

It is not possible to express the improvement resulting from continuous infusions in figures, though in many cases improvement was very great, as in patients suffering from surgical shock or from dehydration due to vomiting. There was also evidence of improvement in patients with renal insufficiency after glucose infusions.

The practical application of long continued infusions deserves some consideration. Patients have objected very little to leaving an arm extended on the bed for three or four hours at a time. A good deal of freedom of movement is permissable if flexion at the elbow is rendered impossible. The infusions were run from two to four hours, usually about three, and the rate of flow was regulated so that from 800 to 1,500 c.c. of fluid would be delivered per hour.

Venous pressure determinations were made at the start of the infusion; at the end of the first and second half hours, and every succeeding hour. This has proved to be a much more reliable and delicate index of the patient's condition and the effect of the infusion than arterial pressure, pulse or temperature. The normal pressure in the veins of the anticubital fossa varies with the posture of the subject. Taking as an arbitrary point the sternal notch, we found that the pressure in centimeters of water was about equal to the height of the

4. New tubing for intravenous use is first thoroughly washed in soap and water. It is then rinsed with distilled water. After being boiled, it is rinsed again with distilled water and boiled for the second time. Only after this procedure is it considered safe to incorporate the tubing in intravenous sets.

sternal notch above the vein. This was roughly true, in semireclining postures, for patients suffering from some chronic condition, with a normally functioning cardiovascular system.

Almost every considerable rise in the venous pressure was accompanied by some untoward condition, as shown in the following cases:

REPORT OF CASES

Case 2.—This was the second case in the series, and the venous pressure at the start was not recorded. At the end of a half hour, it was 25 cm., a figure unusually high, as we learned later. At the end of another half hour, the pressure had reached 43 cm. The patient began to shiver and had a typical chill, which we afterward attributed to a fault in the infusion fluid.

Case 6.—The venous pressure rose from 6 cm., at the start, to 12 cm., at the end of the first hour, when the patient had a chill.

Case 20.—The venous pressure was 14 cm. at the start. It rose to 18 cm. at the end of the first half hour. This should have been considered a signal to stop, but the infusion was continued, and the temperature rose from 100 F. at the start to 103 at the end of the first hour. The patient complained of cold, and it was recognized that she was probably having a chill. The venous pressure had not continued to rise, but fell to 16 cm.

The causation of these chills is discussed above. It is of passing interest that in each of these three cases of reactionary chill, the systolic arterial pressure remained constant, while the diastolic pressure fell, thus: systolic, 168, diastolic, from 108 to 88; systolic, 120, diastolic, 40 to 20; systolic, 128, diastolic, 86 to 70.

In Case 18, the venous pressure rose from 11 cm. to 20 cm. This accompanied untoward pulmonary signs, as will be explained below. In only two other cases was there a rise of over 2 cm. in venous pressure. In one this pressure rose from 15 to 20 cm. of water, while the arterial pressure fell from 220 systolic, 190 diastolic, to 200 systolic, 150 diastolic. This was a case of extensive vascular syphilis. In another instance, the pressure rose from 11 cm. to 14 cm. No explanation can be offered for either rise. Possibly, the patient's posture was markedly altered. The two infusions were given by a hospital intern who had had little experience in such work and did not record the posture.

In the great majority of instances, the venous pressure remains unchanged throughout the infusions or occasionally, as in cases of surgical shock, it falls. For example, in Case 16, the patient, who had been subjected to a protracted brain operation, had sustained a considerable loss of blood and was almost pulseless. A continuous infusion with physiologic sodium chlorid solution was begun. Three thousand cubic centimeters of fluid was administered in three hours and twenty minutes. The venous pressure was 20 cm., although the sternal notch was only 4 cm. above the needle. The pressure, which fell promptly

after the start of the infusion, was 15 cm. at the end of one hour, 12 cm. at the end of the second hour and 15 cm. at the end of the third. The pulse fell from 144 to 108, and the blood pressure changed from 90 systolic and 42 diastolic, to 95 systolic and 65 diastolic. There was great improvement in the general condition as well.

The easy determination of the venous pressure by the method described provides a most important index of the gravity of the patient's condition and the degree of surgical shock present. This condition, as has been frequently shown, depends on dilatation of the smallest channels in the arteriovenous tree. After a large hemorrhage, there results a primary constriction of the peripheral vessels. If the low arterial pressure continues, this constriction passes over into dilatation and the venous pressure rises (Penfield [5]). This rise of venous pressure associated with falling arterial pressure of course demands instant treatment by infusion with one of the various fluids used in shock. When the heart is supplied directly with an increased amount of fluid, steadily, over a long period, the vicious circle of surgical shock is broken. The volume of circulating blood is increased and the increase maintained; thus the result aimed at by the infusion of viscous fluids is secured. Improvement is signalized by falling venous pressure resultant on increase in the tone of the peripheral vessels. The fall of venous pressure, therefore, is the most valuable indication of improvement.

In cases of marked dehydration due, for example, to continued vomiting, slow continuous infusion of fluid by the method described has been found of great help, and large amounts may be administered; e. g., 4,500 c.c. in three or four hours. In such cases, it seems better to employ physiologic sodium chlorid or Ringer's solution, as the diuretic effect of glucose is not desirable. The administration of large amounts of fluid should be carried out with some caution, however, if there is any suspicion as to the functional ability of the pulmonary circulation. Here again a rising venous pressure is a sign of danger.

In a case of fulminating fibrinopurulent peritonitis, a continuous glucose infusion was given, with apparently beneficial result. On the following day, however, the patient was almost moribund. Another infusion was given. The venous pressure, which was 11 cm. at the start, rose toward the end of the infusion to 20 cm. Breathing became more difficult and there was mucus in the throat. Moist râles could be heard at the bases of both lungs. The infusion was discontinued at once. The patient died later in the day. The respiration rate was 42 at the beginning of the infusion, and only increased to 44 at the end. The outcome of the case was not influenced by the intravascular therapy. Nevertheless, the fluid, 3,000 c.c. in three hours, of which the patient

5. Penfield, W. G.: The Treatment of Severe and Progressive Hemorrhage by Intravenous Injections, Am. J. Physiol. **48**:121, 1919.

eliminated 820 c.c. in the urine during that time, may have been a contributing cause to the development of the pulmonary edema which was present at death. No definite evidence of pneumonia could be found, and postmortem examination was not permitted.

No other patient showed any similar symptoms; but it seems wise to watch the venous pressure and proceed with caution when there is danger of embarrassment of the pulmonary circulation.

Woodyatt [6] has shown with normal subjects that 0.85 gm. of glucose per hour for each kilogram of body weight can be administered intravascularly without the appearance of glucose in the urine. Anything over this figure causes glycosuria. It has been shown also that the metabolism varies directly with the temperature (Du Bois [7]). We assumed, therefore, that patients with an elevated temperature might possibly be able to utilize an increased amount of sugar by virtue of their hyperpyrexia. This was found not to be the case, although the number of trials carefully controlled is limited. To study this point, the theoretical glucose tolerance of each patient for one hour was computed according to the weight of the patient, from Woodyatt's figure of 0.85 gm. per hour for each kilogram of body weight. The glucose solution was then diluted so that an amount of glucose would be administered equal to the patient's theoretical tolerance, together with the desired amount of fluid per hour. The rectal temperature was then recorded, and the patient was urged to void each hour. Because of the diuretic effect of the glucose infusion, these urine specimens could usually be obtained punctually.

Case 22.—This patient was suffering from carcinoma of the stomach and had been vomiting a good deal. Theoretical tolerance was 59 gm. of glucose per hour. She was given exactly that amount of glucose in 1,000 c.c. of fluid the first hour; and likewise, the second and the third hour. The rectal temperature was 102 F. at the beginning of the infusion, and gradually fell to 101 F., at the end of the fourth hour. In the urine collected at the end of the first hour, there was 1.26 gm.; at the end of the second hour, 2.39 gm.; at the end of the third hour, 2.32 gm., and at the end of the fourth hour, 3.60 gm. The total amount in the urine of the succeeding twenty-four hours was 3.5 gm. There was a total output of 13.07 gm. of glucose. It is not possible for us to figure so accurately as one might in a laboratory experiment. But certainly there was no increase in ability to utilize sugar in this case in spite of the hyperpyrexia.

Case 19.—The patient was suffering from acute peritonitis. The temperature averaged a little over 101 F. during the experiment. The theoretical glucose

6. Woodyatt, R. T.: An Improved Volumetric Pump for Continuous Intravenous Injections, J. Biol. Chem. **41**:315 (March) 1920. Woodyatt, R. T.; Sansum, W. D., and Wilder, R. M.: J. A. M. A. **65**:2067 (Dec. 11) 1915.

7. Du Bois, E. F.: The Basal Metabolism in Fever, J. A. M. A. **77**:352 (July 30) 1921.

tolerance was 59.1 gm. per hour. Forty-six grams was given in the first hour, 47 in the second, and 44 in the third, 13 gm. being given in the first fifteen minutes of the fourth hour. There was an output of 1.1 gm. of glucose in the urine during the first hour, 6 gm. during the second, 5 gm. during the third, and 5.85 gm. during the fourth. The urine of the succeeding twenty-four hours contained no sugar. The patient received, together with 4,450 c.c. of fluid, glucose at the rate of about 12 gm. per hour less than the limit of the theoretical tolerance and, in spite of hyperpyrexia, there was an output of 17 gm. of glucose.

Case 3.—The patient had acute appendicitis with peritonitis. The theoretical tolerance was approximately 53 gm. per hour. One thousand nine hundred and forty-five cubic centimeters of 10 per cent. glucose was administered over a period of three hours, averaging about 12 gm. per hour above the theoretical tolerance. For the five hours following the start of infusion, the output of glucose in the urine was 7.5, 18.42, 16.75, 15.21 and 6.03 gm. In the succeeding twenty-four hours, 1 gm. of glucose was excreted. The patient's rectal temperature varied between 103 and 103.4 F. during the period of observation.

None of these patients had a history of diabetes or renal disease.

In general, infusions of about three hours' duration produced the maximum output of glucose in the urine during the fourth hour. During the first hour, only a very small amount of sugar was eliminated. Continued administration gives rise to a cumulative elimination. The conclusion is that patients with a hyperpyrexia from ordinary surgical diseases have not an increased ability to utilize intravenous sugar.

The effect of glucose infusion was studied from another point of view: diuresis. In the six hours following the start of a glucose infusion, the urinary output was, as a rule, greater than the total output of the preceding twenty-four hours. In one case, it was as much as nine times greater. The hour of maximum output was usually the third or fourth, and not infrequently the urine collected in the first three or four hours was greater than that of the succeeding twenty-four hours. One example will be given:

Case 8.—The patient was suffering from suppurative pyelonephritis and chronic uremia. A continuous infusion of 2,675 c.c. of fluid was given him by Dr. B. H. Kennedy, Jr., containing 155 gm. of glucose, of which 15 gm. in all was eliminated in the urine. The infusion was continued for three hours. The patient had an indwelling catheter. Specimens of urine could, therefore, be collected at exact hourly intervals. During the first six hours after the start of the infusion, 2,130 c.c. of urine was eliminated, the maximum output occurring in the third hour. The specific gravity of the urine in the first five hourly specimens was: 1.010, 1.012, 1.012, 1.010 and 1.014. The total fluid intake for that day was 2,925 c.c., and the total urinary output, 3,505 c.c., as compared with an output of 1,030 c.c. on an intake of 2,400 c.c. without infusion on the succeeding day. On the day previous to this glucose injection, the patient had had a similar infusion, when the blood urea at the start was 3.03 gm., at the close 2.68 gm. per thousand cubic centimeters, and on the following day, i. e., before the infusion described in full above, it was still

down to 2.58 gm. He was given a number of such infusions. Subjectively, he was always much improved, and his life seemed to be remarkably prolonged. The blood urea varied between 2.33 and 3.84 gm. per thousand cubic centimeters for three weeks before death.

SUMMARY

In the method of regulating the rate of flow of prolonged intravenous infusions described, it has been found that the apparatus and warming bath are sufficiently simple to provide a practicable method for general hospital use.

Clinically, the most marked improvement after physiologic sodium chlorid infusions is seen in cases of surgical shock and marked dehydration. The diuretic effect of prolonged intravenous injection of glucose is remarkable, producing not infrequently a twenty-four-hour urinary output, which is larger than the intake, even though as much as 3,000 c.c. of fluid may have been administered by infusion alone. In this respect, it has afforded a valuable therapeutic service, but it seems better to use saline or Ringer's solution in cases of dehydration. In general, febrile patients seem to be able to assimilate glucose about as readily as nonfebrile patients, but not in any greater amounts. The elimination of glucose in the urine is cumulative, the maximum output from a three-hour infusion occurring usually in the fourth hour.

It was shown experimentally that wide variations in the temperature of the infusion fluid do not disturb the temperature regulating mechanism in animals, and the danger of allowing infusion solutions to become very acid was illustrated.

Fluid in amounts as high as 4,500 c.c. can be administered during the course of three or four hours with safety, when the method described is employed. Rising venous pressure, however, must be considered a sign of unfavorable reaction to infusion and a signal for its discontinuance. The essential feature of the apparatus is that the venous pressure can be easily read, and any considerable rise of this pressure is signalized by overflow from the manometer. In general, small changes in venous pressure constitute the most delicate index of the patient's condition.

BLOOD TRANSFUSION: A STUDY OF TWO HUNDRED AND FORTY-FIVE CASES*

GLOVER H. COPHER, M.D.

ST. LOUIS

The rational basis of blood transfusion was established by the discovery of the phenomenon that the serum of one individual frequently agglutinates the corpuscles of another individual's blood. This discovery of so-called isohemagglutination was made simultaneously in 1899-1900 by the Englishman Shattock,[1] and the Austrian Landsteiner.[2] Following this, Jansky,[3] in 1906, was able to classify human blood into four groups according to their agglutinating reactions. In 1910, Moss[4] independently made a similar classification of serum agglutinins. The two classifications differ, however, in that Moss's Group IV corresponds to Jansky's Group I and Jansky's Group IV corresponds to Moss's Group I. In order that there might be a universal classification of blood groups, eliminating confusion and accident incident to the use of different classifications, a committee appointed by the American Association of Immunologists, the Society of American Bacteriologists and the Association of Pathologists and Bacteriologists has recommended the adoption of the Jansky classification.[5] To avoid confusion, laboratories in making their reports of blood grouping should state the methods of classification, in addition to the blood group. The Moss classification of grouping is referred to throughout this article unless otherwise stated.

BLOOD GROUPING

No one is ever justified in performing a blood transfusion without first making an agglutination test of the blood of the donor and of the recipient, except when laboratory facilities are not available. The few minutes demanded for the test are well spent, even when the procedure

---

* From the Department of Surgery, Washington University School of Medicine and the Surgical Service of the Barnes and St. Louis Children's Hospitals.

1. Shattock: Chromocyte Clumping in Acute Pneumonia and Certain Other Diseases and the Significance of the Buffy Coat in Shed Blood, J. Path. & Bacteriol. **6**: 303, 1900.

2. Landsteiner, C.: Zur Kenntniss der antifermentativen lytischen, etc., Zentralbl. f. Bakteriol. u. Parasitenk. **27**:361, 1900; Ueber Agglutinationserscheinungen normalen menschlichen Blutes, Wien. klin. Wchnschr., 1901, p. 1132.

3. Jansky: Hämatologische Studien bei Psychiatikern, Sborn. klin. **8**:85, 1906-1907; abstr. Jahresb. f. Neurol. u. Psychiat., 1907.

4. Moss: Studies in Iso-Agglutinins and Isohemolysins, Bull. Johns Hopkins Hosp. **21**:63, 1910.

5. Isohemagglutination, J. A. M. A. **76**: 130 (Jan. 8) 1921.

is one of dire emergency. The chance of the recipient's receiving incompatible blood is too great to omit proper tests.

The technic of blood grouping has undergone many modifications, all based on the phenomenon of iso-hemagglutination, which occurs usually independently of hemolysis, the reverse of which, i. e., hemolysis without simultaneous or preceding agglutination, rarely if ever occurs, if in the test proper dilutions of serum and cells are made. No one has been able to classify specimens of blood according to their isolytic action. In general, the agglutination tests are sufficient. Iso-agglutinins occur in the blood serum of about 97 per cent. of adults, while iso-hemolysins occur in approximately 25 per cent. A few are of the opinion that hemolysis is not necessarily preceded by agglutination of cells. Such a reaction in human blood has not been observed in our laboratory. Ottenberg and Thalheimer [6] have produced isohemolysins in cats whose serum did not agglutinate. Autohemagglutinins have been observed in certain anemias, and there is experimental evidence that they do occur. The relationship of autohemolysins to paroxysmal hemoglobinuria is known. Landsteiner explained the occurrence of interagglutination of bloods on the Ehrlich hypothesis, as did Hektoen,[7] later. It is possibly based on physicochemical laws. Bechhold [8] has recently advanced a theory in explanation of hemolysis in which he regards the red blood cell as consisting of a stroma of protein network with a skin of emulsified lecithin and cholestrin across the meshes. He regards hemolysis as occurring when one of these three components is removed. The hemolytic action of hypertonic and hypotonic solutions is not based on their osmotic effect but on a lowering of the surface tension of the lecithin emulsion, whereby lecithin is less securely attached to the protein framework. It has been noted that red blood cells conduct electrical current less well than serum and that hemolysis is accompanied by a sudden rise in conductivity.[9] Iso-agglutination is dependent on both serum and cells. It affects the cell as an entity, in contrast to hemolysis, which affects some of the components of the cell. The H-ion concentration of the serum and the cell membrane are the important factors in agglutination rather than changes of the cell content.[10]

---

6. Ottenberg and Thalheimer: Studies in Experimental Transfusion, J. Med. Res. **33**: 213 (Nov.) 1915.

7. Hektoen, Ludvig: Isoagglutination of Human Corpuscles, J. Infect. Dis. **4**: 297, 1907.

8. Bechhold, H.: Bau der roten Blutkörperchen und Hämolyse, München. med. Wchnschr. **68**: 127 (Feb. 4) 1921.

9. Tangl and Bodon: Beitrag zur physikalischen Chemie der weissen Blutkörperchen, Biochem. Ztschr. **84**: 183, 1917.

10. Coulter, C. B.: Agglutination of Red Blood Cells in the Presence of Blood Sera, J. Gen. Physiol. **4**: 403 (March) 1922.

Of the various laboratory methods, the microscopic examination of fresh cells and serums is preferred. The grouping may be done in a variety of ways. In the Moss [11] technic, which is in use in the Barnes Hospital, serums from the blood of persons in Groups II and III are used, with the red cells of the unknown group. In the Brem [12] method, the serum and a corpuscle suspension of either a known Group II or Group III and a like collection of the unknown blood are employed. Brem found that isohemolysins may interfere with group determination by breaking the agglutinating corpuscles so rapidly that they may obscure the agglutination reaction. He obviated this by using the anti-hemolysin which Moss found constantly present in the serum of the blood whose corpuscles are hemolyzed by a serum belonging to another group. Serums contain no antiagglutinins. Epstein and Ottenberg [13] devised a test for agglutination and hemolysis on small amounts of blood by the use of capillary pipets. Rous and Turner [14] also use capillary tubes in their agglutinating test. The clotting of the blood offers some difficulty in the use of capillary tubes. Percy [15] has described a simple method for making the hemolysis test. Lee,[16] on the basis that the important consideration in blood grouping is that the serum of the recipient does not agglutinate the red blood cells of the donor, used only the serum of the recipient and the cells of the donor.

Various macroscopic tests are described. Weil [17] uses citrated blood in test tubes. Vincent [18] places the serum of Group II at one end of a glass slide and serum of Group III at the other end. To each of these he adds a drop of the fresh blood to be tested. The reaction is macroscopic. The emulsions on the ends of the slides may be allowed to dry, and preserved as permanent records. If a mixture of 0.5 c.c. of blood of a recipient and the same amount of blood from a possible donor is

---

11. Moss, W. L.: Simplified Method for Determining the Iso-Agglutinin Group in the Selection of Donors for Blood Transfusion, J. A. M. A. **68:** 1905 (June 23) 1917.

12. Brem, W. V.: Blood Transfusion, J. A. M. A. **67:**190 (July 15) 1916.

13. Epstein, A. A., and Ottenberg, Reuben: A Method for Hemolysis and Agglutination Tests, Arch. Int. Med. **3:**286 (May) 1909.

14. Rous, Peyton, and Turner, J. R.: A Rapid and Simple Method for Testing Donors for Transfusion, J. A. M. A. **64:** 1980 (June 12) 1915.

15. Percy: A Simplified Method of Blood Transfusion, Surg. Gynec. & Obst. **21:** 261, 1915.

16. Lee, R. I.: A Simple and Rapid Method for the Selection of Suitable Donors for Transfusion by the Determination of Blood Groups, Brit. M. J. **2:** 684 (Nov.) 1917.

17. Weil, Richard: Sodium Citrate in the Transfusion of Blood, J. A. M. A. **64:** 425 (Jan. 30) 1915.

18. Vincent, Beth: A Rapid Macroscopic Agglutination Test for Blood Grouping and Its Value in Testing Donors for Transfusion, J. A. M. A. **70:** 1219 (April 27) 1918.

injected into the heart of a guinea-pig, incompatible blood is said to kill the animal.[19]

The compatibility of specimens of blood may be determined by "matching" one blood directly with another without the determination of the group of either. The donor's serum is added to the recipient's corpuscles and observed microscopically for agglutination, as are the donor's corpuscles and the recipient's serum. During the past two years, this procedure has been carried out in our laboratories in addition to the grouping of the patients. This procedure serves as a reliable check when the grouping is done by various laboratory workers. Prospective donors are chosen from the same group as the recipient and their blood matched. Occasionally, in matching the blood of persons of the same blood group, a few scattered agglutinating clumps of red blood cells will be observed under the microscope. Such types of blood should be regarded as incompatible and not used for transfusion because of the great likelihood of reaction.

The matching of specimens of blood has restricted the use of Group IV as a universal donor. Until 1920, the universal donor was used for transfusion of any group. The practice was discontinued because of reactions traceable to the use of such blood. In spite of the high dilution to which the incompatible plasma is brought after introduction into the veins of the recipient, fatal accidents are recorded from the agglutination of the red blood cells of the recipient by the donor's plasma when the recipient belonged to a group other than that of the universal donor. However, in some clinics the agglutination of the patient's corpuscles by the donor's serum is disregarded, and the only danger considered lies in the action of the recipient's serum on the donor's corpuscles. Reports of the Inter-Allied Surgical Congress[20] state that fatal accidents have occurred from hemolysis of the blood corpuscles of the recipient by the donor's plasma.

It is important to know whether there can ever be a change in the blood group of a person. We have no personal knowledge of a temporary or permanent change of a blood group. Personal instances of supposed changes have proved to be the result of some error in technic of grouping. There has been proved a variation in the agglutinating ability of serums from different persons of the same group, as well as a variation in the ability of corpuscles of the same group to be agglutinated by the same serum.[21] This variation of strength of human blood iso-agglutinins can best be explained by the hypothesis

19. Tzanck: Blood Transfusion, Paris méd. **12**: 249, 1921.

20. Review of War Surgery and Medicine **2**, 1919.

21. Dyke, S. C.: On the Medicolegal Importance of the Blood Groups, Lancet **203**: 1271 (Dec. 16) 1922.

originally advanced by Dungern and Hirschfeld.[22] They assumed two agglutinable factors present in the corpuscles and two agglutinable factors in serum. The group of any blood is determined by the distribution of these factors, which may be illustrated by representing the agglutinating units in the corpuscles as "A" and "B" and the corresponding factors in the serum as "a" and "b", as shown in the accompanying table. This hypothesis has been confirmed many times by adsorption tests.[23]

Variations noted in individuals of the same group may be ascribed to differences in strength of "A", "B", "a" and "b". Though agglutinins vary in their relative strength, it has always been possible to classify them into the four groups in many thousands of tests by many different workers.[24] This variation of titer of agglutinins is another good reason for the direct testing of serum and corpuscles from both donor and recipient and for care in the selection of individuals from whom is obtained the standard serums of Groups II and III for testing.

Determination of Groups of Blood

	Serum	Corpuscles
Group I	a + b	O
Group II	b	A
Group III	a	B
Group IV	o	A + B

From evidence in the recent literature, it is probable that there may be other factors that may change agglutinins. Certain drugs, roentgen-ray irradiation and general anesthesia have been reported as the cause of temporary change of blood from one group to another.[25] In three cases, Levine and Segall[26] found, after a prolonged ether anesthesia, an alteration in the patients's serum as regards its hemagglutinin property. In such cases, the blood serum had a pinkish tinge when with-

22. Dungern and Hirschfeld: Ueber Vererbung gruppenspezifischer Strukturen des Blutes, Ztschr. f. Immunitätsforsch. u. exper. Therap. **6**: 284, 1910.

23. Koeckert, H. L.: J. Immunol. **5**: 529 (Nov.) 1920; Hooker, S. B., and Anderson, L. M.: J. Immunol. **6**: 419 (Nov.) 1921; Gichner, M. G.: Biologic Mechanism of Human Isohemagglutination, J. A. M. A. **79**: 2143 (Dec. 23) 1922; Dyke, S. C.: Brit. J. Exper. Path. **3**: 146 (June) 1922.

24. Culpepper, W. L., and Ableson, M.: Report on Five Thousand Bloods Typed, Using Moss's Grouping, J. Lab. & Clin. Med. **6**: 276 (Feb.) 1921.

25. Vorschütz, Joseph: Group Agglutination in Blood Transfusion, Ztschr. f. klin. Med. **94**: 459 (June 30) 1922; Eden, R.: Bedeutung der gruppenweisen Hämagglutination für die freie Transplantation und über die Veränderung der Agglutinationsgruppen durch Medikamente, Narkose, Roentgenbestrahlung, Deutsch. med. Wchnschr. **48**: 85 (Jan. 19) 1922.

26. Levine, E. C., and Segall, H. M.: Posttransfusion Reactions, Surg. Gynec. & Obst. **35**: 313 (Sept.) 1922.

drawn immediately after the operation, and agglutinated the donor's corpuscles. These changes disappeared in about twenty-four hours after the anesthesia. They conclude it is unsafe to perform a transfusion during this period, even when the donor's blood has been found suitable previous to the anesthesia. In twenty-six of our patients in whom transfusion was performed during, or immediately after, ether anesthesia lasting more than one hour, the percentage of reactions was no higher than in any other group of cases. There were twelve transfusions given by the sodium citrate method, twelve by syringe cannula and two with waxed tubes in the twenty-six cases. These were all cases of hemorrhage or shock or a combination of them.

Disease is thought by Bond to alter the iso-agglutinins. He observed that iso-agglutinins formerly absent in the serum of a given person may appear in that serum after the person has successfully withstood a systemic infection.[27]

Certain iso-agglutinins may be dependent somewhat on diet. Harper and Byron find that diet apparently affects the serum of Group III, and interferes with the proper agglutination of cells of Group III blood in Group II serum.[28]

There are various opinions as to the effect on blood compatibility of repeated transfusions from the same donor to the same recipient. It is probably true that multiple transfusions from the same donor to the same recipient occasionally develop, in the blood of the latter, specific agglutinins and hemolysins against the donor's cells rather than a change in the recipient's original blood group agglutinins. Such transfusions have not been frequent in our series. In one case, a severe hemolytic reaction took place after a second transfusion from a donor who had previously acted as such without reaction. Similar cases have been reported by Thalhimer,[29] Astrowe and others.[30] We now determine the compatibility of the blood of such donors and recipients before each transfusion.

In carrying out blood tests, auto-agglutinins (cells agglutinated by their own serum) should be looked for; especially in cases of severe anemia and in patients that have had numerous transfusions over a short period from the same donor, or when the test is made at a low temperature. Cases of autohemagglutination of human red cells have been

---

27. Bond, C. J.: Brit. M. J. **2**: 751 (Dec. 8) 1917.

28. Harper, John, and Byron, W. C.: Influence of Diet on Blood Grouping. J. A. M. A. **79**: 2222 (Dec. 30) 1922.

29. Thalhimer, William: Hemoglobinuria After a Second Transfusion with the Same Donor, J. A. M. A. **76**: 1345 (May 14) 1921.

30. Astrowe, P. S.: Hemolysis Following Transfusion, J. A. M. A. **79**: 1511 (Oct. 28) 1922; Libman and Ottenberg: Recent Observations on Blood Transfusion, Tr. Coll. Phys., Philadelphia **39**: 266.

reported by Clough and Richter,[31] Kligler [32] and others.[33] One case has been observed in this hospital in a patient suffering from pernicious anemia. It apparently occurs in animals more frequently than in human beings. Serum separating from blood clot at 37 C. will yield antibodies not demonstrable in serum taken in the cold, and, conversely, agglutinating mixtures examined at room temperature are far more likely to yield positive findings than those kept at blood heat.[34] Blood containing auto-agglutinins will clump its own cells when the temperature is lowered.[35] The clumping disappears when the temperature is raised to 37 C. This phenomenon might result in the blood's being erroneously placed in Group I. Such cells should be washed repeatedly in warm saline solution until a suspension shows no auto-agglutination when placed in the icebox.

Rouleaux of cells are at times confusing. These may be eliminated by varying the dilution of the serum and the cells. No ill-effects have been noted when such blood has been used for transfusion.

In blood grouping, the specificity and strength of the standard serums used should be proved frequently. The blood to be tested should not have stood for more than twenty-four hours. Only clean glassware should be used, for it has been found that contact hemolysis is most marked on slightly soiled glass when washed cells are used.[36] Our agglutination tests have been made at room temperature. It has been shown that macroscopic agglutination of red blood cells takes place more readily at low than at high temperatures and that they adsorb a larger amount of iso-agglutinins at a low than at a higher temperature.[37] The cell and serum mixtures should not be allowed to dry while the tests are being made, or there may be nonspecific agglutination. Bloods that show atypical reactions in grouping and matching had better be discarded and a new donor sought.

During the war, interest in the preservation of standard serums was aroused. Our method has been to collect 20 c.c. of blood from individuals in Group II and Group III, respectively, under sterile condi-

---

31. Clough, M. C., and Richter, T. M.: Bull. Johns Hopkins Hosp. **29**:86 (April) 1918.

32. Kligler, T. J.: Autohemagglutination of Human Red Blood Corpuscles, J. A. M. A. **78**:1195 (April 22) 1922.

33. Gilbert and Weinberg: Traite du sang, Paris **2**, 1921.

34. Robertson, O. H., and Rous, P.: Sources of Antibodies Developing After Repeated Transfusions, J. Exper. Med. **35**:141 (Feb.) 1922.

35. Unger, S. J.: Precautions Necessary in the Selection of a Donor for Blood Transfusion, J. A. M. A. **76**:9 (Jan. 1) 1921.

36. Fenn, W. O.: Hemolysis of Erythrocytes in Contact with Glass, J. Exper. Med. **35**:271 (Feb.) 1922.

37. Jervell, F.: The Influence of Temperature upon the Agglutination of the Red Blood Corpuscles, J. Immunol. **6**:445 (Nov.) 1921.

tions. When the blood has coagulated, the serum is pipetted into two sterile flasks and 2 c.c. of a 1.5 per cent. solution of sodium citrate is added to prevent coagulation of the small amounts of fresh blood mixed with the serum in making the tests. The cells may be centrifuged from the serum instead of waiting for the clot separation. The serums will keep in an icebox for five or six weeks without deterioration. A few drops of a 0.25 per cent. tricresol solution may be added as a preservative. Such standard serums may be kept for months in an icebox in sealed glass tubes or in sealed bottles, without deterioration. After a few weeks, serum exposed to the air tends to lose its specific agglutinating power. Iso-agglutinins are thermostabile. Sanford [38] has dried standard serums on clean cover slips, wrapped them in paper and preserved them in an icebox. He found that after two months the dried serums retained their agglutinating properties. The unknown blood to be tested is used in dissolving the dried serum. Another method is to dry the blood serum and store it in sealed containers, using a small portion of it in solution with physiologic sodium chlorid solution when desired for grouping.[39] Hartman [40] has preserved serums by the use of filter paper. Blood serum from a known group is evaporated to dryness in a porcelain dish, and to the residue is added the smallest amount of physiologic sodium chlorid solution that will dissolve the residue. Pieces of heavy filter paper are saturated with this solution and allowed to dry. The filter paper is preserved in a moisture-proof container. Such serums are said to keep indefinitely. It is thought, however, that dessication of serum leads to deterioration of the agglutinins and that the serum soon acquires the power of nonspecific agglutination.[41] Recently, Holt and Reynolds [42] have shown, by separating pseudoglobulin, euglobulin and albumin from serum, that the hemagglutinating property is contained in the pseudoglobulin content, euglobulin and albumin apparently playing no part. They found that pseudoglobulin retains its potency for about two and one half months. Fresh, nondesiccated serums are undoubtedly preferred for routine use.

Familial relationship has no bearing on blood grouping other than that which has been demonstrated by von Dungern and Hirschfeld [22]

---

38. Sanford, A. H.: A Modification of the Moss Method of Determining Isohemagglutination Groups, J. A. M. A. **70**:1221 (April) 1918.

39. Gill, W. D.: The Use of Dessicated Blood Serum in the Selection of Donors for Transfusion, Mil. Surgeon **51**:285 (Sept.) 1922.

40. Hartman, F. W.: New Methods for Blood Transfusion and Serum Therapy, J. A. M. A. **71**:1658 (Nov. 16) 1918.

41. Kolmer, J. A.: Influence of Dessication upon Natural Hemolysins and Hemagglutinins in Human Serum, J. Immunol. **4**:393 (Nov.) 1919.

42. Holt, R. L., and Reynolds, F. H. K.: The Hemagglutinating Fraction of Human Serums, J. A. M. A. **79**:1684 (Nov.) 1922.

and others [43] that human iso-agglutinins are inherited according to Mendel's law. In confirmation of the hereditary nature of human blood groups, Ottenberg [44] collected data from a new series of families, and points out the possible medicolegal application of the fact for the determination of parentage. Buchanan [45] holds that Ottenberg's criteria for determination of legitimacy of offspring by means of the blood groups are dangerous. Further observations are necessary before the question can be answered.[46] These units of inheritance cannot be investigated in experimental animals because tests made on dogs, cats, cattle, horses, swine, rabbits, guinea-pigs, rats and mice fail to show blood groups.[47] In the blood of certain ones of this variety of animals, however, nonspecific agglutinins have been found. There seems to be a definite racial distribution of isohemagglutinin groups.[48]

The difference between the blood of a mother and that of her infant was first noted by Halban.[49] The agglutinating power of the mother's serum is far greater than that of the blood taken from the umbilical cord of the infant. Ninety-seven per cent. of adults have agglutinins in their serums, while it is present in the serums of only 13 per cent. of new-born infants. Only 25 per cent. of new-born infants have cells that can be agglutinated in contrast to 50 per cent. among adults. In animals, agglutinins and hemolysins tend to come to essentially the same concentration in the maternal and fetal blood.[50] Agglutinins identical with those of her blood are present in a mother's milk, but they are not transmitted through the milk to the infant, since bottle-fed infants appear to develop iso-agglutinins in the same manner as do breast-fed

---

43. Gichner, M. G.: A Biologic Mechanism of Human Isohemagglutination, J. A. M. A. **79**:2143 (Dec. 23) 1922; Helsingfors Letter, J. A. M. A. **77**: 1668 (Nov. 19) 1921; Keynes, Geoffrey: Blood Transfusion, Oxford Medical Publications, 1921, p. 90; Learmonth: The Inheritance of Specific Iso-Agglutinins in Human Blood, J. Genetics **10**:141, 1920; Schütze, H.: Hemagglutination and Its Medicolegal Bearing, with Observations Upon the Theory of Iso-Agglutinins, Brit. J. Exper. Path. **2**:26 (Feb.) 1921; Tebbutt, A. H., and McConnel, S. V.: M. J. Australia **1**:201 (Feb. 25) 1922.

44. Ottenberg, Reuben: Medicolegal Application of Human Blood Grouping, J. A. M. A. **79**:2137 (Dec. 23) 1922.

45. Buchanan, J. A.: The Medicolegal Application of Blood Groups, J. A. M. A. **78**:89 (Jan. 14) 1922; ibid. **79**:180 (July 15) 1922.

46. Is Parentage Determinable by Blood Tests? editorial, J. A. M. A. **79**:1246, (Oct. 7) 1922.

47. Fischbein: J. Infect. Dis. **12**:133, 1913; Hektoen, Ludvig: J. Infect. Dis. **4**:297, 1907; Ingebristen: München. med. Wchnschr. **59**:1475, 1912; MacDowell and Hubbard: Proc. Soc. Exper. Biol. & Med. **20**:93, 1922; Rohdenburg: Proc. Soc. Exper. Biol. & Med. **17**:82, 1920.

48. Lewis, J. H., and Henderson, D. L.: The Racial Distribution of Isohemagglutinin Groups, J. A. M. A. **79**:1422 (Oct. 21) 1922.

49. Halban: Wien. klin. Wchnschr. **13**:545, 1900.

50. Bourquin, D.: Am. J. Physiol. **59**:122 (Feb.) 1922.

infants. Group characters are established in the corpuscles before they are established in the serum and are subject to change until the group of the serum has been established.[51] The exact group is not determinable before the end of the first year and is not necessarily the same group as that of the mother. In thirty-four tests on the blood of mothers and their infants, Cherry and Langrock[52] found no agglutination or hemolysis. They concluded that all mothers may be used as donors for their respective infants, provided no contraindication exists on the part of the mother. In an unpublished article, O'Keefe and Fenton find, on testing the bloods of thirty infants and their mothers on the obstetric service of Barnes Hospital, that in four cases the blood was incompatible. This percentage agrees approximately with that of some other observers. The blood cells of most children under 1 year of age cannot be agglutinated, and their serum cannot agglutinate alien cells; yet incompatibility between the blood of a mother and her new-born infant undoubtedly may occur, so that the testing of the blood should not be omitted even though the mother is a prospective donor. Owing to the variations of the cells and serums of infants, their blood should be tested directly against that of the donor.

There has been noted some differences in the agglutinating action between serums obtained from normal individuals and those from patients suffering from a severe anemia. It is generally considered that this fact has no diagnostic value. Buchanan and Higley[53] have found that there is no relationship between blood groups and malignancy or any other disease, but conclude that nationality may be a feature in distribution of blood groups. Alexander[54] believes that there is a blood group and disease relationship. He is of the opinion that all four groups are liable to malignancy, but that Groups II and III are peculiarly susceptible.

METHODS OF TRANSFUSION

The choice of method of transfusion is largely dependent on local conditions. The citrate method seems to have the greatest number of posttransfusion reactions, regardless of which one of the innumerable

---

51. Happ, W. M.: Iso-Agglutinins in the Blood of Infants and Children, J. Exper. Med., **31**:313 (March) 1920.

52. Cherry, T. H., and Langrock, E. G.: Relations of Hemolysis in the Transfusion of Babies with the Mothers as Donors, J. A. M. A. **66**:626 (Feb. 26) 1916.

53. Buchanan, J. A., and Higley, E. T.: Relationship of Blood Groups to Disease, Brit. Jour. Exper. Path. **2**:247 (Dec.) 1921.

54. Alexander, W.: An Inquiry Into the Distribution of the Blood Groups in Patients Suffering from "Malignant Disease," Brit. Jour. Exper. Path. **2**:66 (April) 1921.

variations [55] of citrate technic is used. However, the citrate method can readily be a one man procedure, in contrast to other methods, which require two and three operators, and it does not demand the speed in transference of the blood from donor to recipient that the other methods do. The blood may be taken from a donor in one part of the hospital and given to a recipient in another part. Robertson,[56] in 1918, using the method of preserving red blood cells described by Rous and Turner, was able to preserve blood for several days and then transfuse it successfully. Many features make the citrate method particularly

---

55. Abelmann, H. W.: Blood Transfusion Simplified by the Use of Citrate Ointment, Surg. Gynec. & Obst. **27**:88 (July) 1918. Agote, L.: La transfusion du sang, par la méthode "Agote," An. d. Inst. Mod. de clin. Méd., Buenos Aires **3**, 1918. Ameuille, P.: Blood Transfusion, Bull. de l'Acad de méd. **79**:140 (Feb. 12) 1918. Bell, W. B.: Blood Transfusion: An Automatic Method of Citration at Body Temperature, Lancet **2**:501 (Sept. 2) 1922. Beraud, H. M.: Transfusion of Citrated Blood, Presse méd. **30**:568 (July 5) 1922. Byford, W. H.: Simplified Apparatus for Transfusion of Blood by Citrate Method, Surg., Gynec. & Obst. **35**:229 (Aug.) 1922. Carter, W. S.: An Experimental Study of the Use of Sodium Citrate in the Transfusion of Blood by the Direct and Indirect Methods, Southern M. J. **9**:427 (May) 1916. Dupuy de Frenelle and Paychère: Presse méd., May 13, 1918. Girand: Recherches hematologiques sur la transfusion du sang citrate, Arch. de méd. et pharm. mil. **69**, 1915. Hartman, F. W.: Transfusion Reactions and Citration Within the Needle, J. A. M. A. **78**:15 (Jan. 7) 1922. Hedon, E.: Sur la transfusion du sang citrate, Presse méd. **26**:57 (Feb. 4) 1918. Hoffman, M. H., and Habein, H. C.: Transfusion of Citrated Blood, J. A. M. A. **76**:358 (Feb. 5) 1921. Hustin: Ann. et bull. Soc. med. et nat. de Bruxelles **4**:104, 1914. Janeway: Blood Transfusion; oCurse of Instruction on War Surgery, Cornell University Medical School, 1918, p. 440. Jeanbrau: Technic simple du transfusion du sang stabilisé par let citrate de soude, Presse méd. **26**:58 (Feb. 4) 1918. Lewisohn, R.: Med. Rec. **87**:41, 1915; Surg., Gynec. & Obst. **21**:37, 1915; Presse méd. **27**:593 (Oct. 15) 1919; Am. J. M. Sc. **157**:253 (Feb.) 1919. Marble, H. C.: Technic of Citrated Blood Transfusion, Boston M. & S. J. **182**:153 (Feb. 5) 1920. Mumey, N.: Apparatus for Transfusion of Blood by the Sodium Citrate Method, J. Arkansas M. S. **13**:158 (Jan.) 1917. Pond, D. B.: Improved Needle and Method for Citrate Blood Transfusion, J. A. M. A. **78**:650 (March 4) 1922. Rieux, J.: Simplified Method of Blood Transfusion, Paris méd. **8**:229 (March 23) 1918. Robertson, O. H.: Method of Citrated Blood Transfusion, Brit. M. J. **1**:477 (April 27) 1918; Transfusion with Preserved Red Blood Cells, ibid. **1**:691 (June 22) 1918. Sebastini: Nota preventativa sopra un metodo semplice di Transfusione del sange, Riv. Osp. **8**, 1918. Singleton, A. O.: A Reliable Method of Blood Transfusion, Southern M. J. **9**:439 (May) 1916. Stansfeld, A. E.: An Apparatus for the Transfusion of Blood by the Citrate Method, Lancet **1**:334 (March 2) 1918. Thévenard, P.: An Emergency Method of Transfusion of Citrated Blood, Presse méd. **26**:237 (May 9) 1918. Weil, Richard: Sodium Citrate in Transfusion of Blood, Med. Rec. **87**:164, 1915; J. A. M. A. **64**:425 (Jan. 30) 1915. Wolf, W.: Zur Technik der Bluteinflössung, München. med. Wchnschr. **66**:288, No. 1, 1919. Zingher, Abraham: A Simple Syringe Method for Transfusion of Blood in Children, Med. Rec. **87**:440, 1915.

56. Robertson, O. H.: Footnote 55, twenty-first reference.

adaptable to war conditions. It is, moreover, the method of choice in transfusion in all cases of septicemia and of syphilis in which there is danger of infecting the donor from the recipient. The citrate method is particularly adapted for transfusion in infants and young children. In infants in whom a superficial vein cannot be obtained, the blood may be introduced through the anterior fontanel into the superior longitudinal sinus. We have found no increase in the fragility of red blood cells from the use of sodium citrate. Mellon, Hastings and Casey [57] have been unable to find an anticomplementary action or a decrease in the phagocytic index of leukocytes following citrate transfusion as described by Unger.[58]

Because of the fewer posttransfusion reactions, which we hold to be harmful, the transfer of whole blood without the addition of a chemical is desirable in most cases in which assistants and apparatus are available. We have found the syringe-cannula method, as described by Lindeman,[59] the easiest method of transferring undiluted blood and have now used this technic without regret for two years. Experience and teamwork make this procedure no more difficult than the citrate method. In our hands, the transfer of blood by the use of waxed tubes has been more difficult than by syringes.

One still reads an occasional report of a direct transfusion by vessel to vessel anastomosis in this country [60] and abroad.[61] Horsley, Vaughan and Dodson, in using this method recently in twenty-four cases, did not observe even a chill in any of the patients. This method has not been used in this clinic because of its many obvious disadvantages.

REACTIONS TO TRANSFUSION

No method of blood transfusion has been devised that is not followed by a varying percentage of reactions. Reactions are manifested by fever, malaise, nausea, vomiting, chilly sensations or actual rigor, muscular pains, dyspnea, cyanosis, pruritis, urticaria and headaches. The fever varies from 2 to 10 degrees. It may subside rapidly within twenty-four hours or it may prolong itself as a low grade fever for

---

57. Mellon, R. R., Hastings, W. S., and Casey, G. W.: Observations on the Effect of Sodium Citrate on the Blood, J. A. M. A. **79**:1678 (Nov. 11) 1922.

58. Unger, L. J.: The Deleterious Effect of Sodium Citrate Employed in Blood Transfusion, J. A. M. A. **77**:2107 (Dec. 31) 1921.

59. Lindeman, Edward: Simple Syringe Transfusion with Special Cannulas; a New Method Applicable to Infants and Adults, Am. J. Dis. Child. **6**:28, (July) 1913.

60. Horsley, J. S.; Vaughan, W. T., and Dodson, A. I.: Direct Transfusion of Blood, Arch. Surg. **5**:301 (Sept.) 1922.

61. Hempel, E.: Vein to Vein Transfusion in Surgical Cases, Deutsch. med. Wchnschr. **48**:316 (March 10), 352 (March 17) 1922. King: Direct Vein to Vein Transfusion, Brit. M. J. **1**:498, 1918.

several days. Following transfusion by the use of syringes, it is noted that a small percentage of patients have a rise of temperature on the following day of from 2 to 3 degrees, apparently due to the transfusion. The very high temperatures are usually accompanied by chills. Chills are seemingly less frequent in children than in adults with a corresponding rise of temperature. Those patients that had fever previous to transfusion have no more reactions than those that do not have it. Severe reactions following transfusion have undoubtedly been the precipitating factor in the death of very sick patients. Reactions have been no more frequent in patients that have had multiple transfusions than in those that have had one transfusion; nor does the degree of anemia of the recipient seem to be a factor. It is to be borne in mind, however, that in nearly all cases, the blood of our recipients and donors have been matched previous to every transfusion. The blood of certain donors on our list seems to give rise to more reactions than does that of others. This fact has been noted in other clinics. The greatest factor controlling reactions, assuming the compatibility of the blood, lies in the technic employed for the transfer of the blood.

The onset of a reaction may occur during the transfusion, especially after the injection of the first few cubic centimeters. Some of these reactions seem to be of an anaphylactic nature, the most striking feature of which is the dyspnea, cyanosis and the altered pulse. Relief is afforded by the injection of epinephrin and morphin. The recipient should receive no more blood from that donor after such reaction is first manifest. The reaction usually occurs from one half hour to four hours afterward. We have observed no chills after four hours following transfusion. Treatment for such reactions is symptomatic. Butsch and Ashby [62] find that the length of time elapsing after meals or abstainance from food, before giving a transfusion, has no effect on the probability of reaction.

That the addition of sodium citrate to blood increases the number of reactions is demonstrated by the difference between the percentage of reactions following citrate transfusion and that following unadulterated blood transfusion. This holds true, even though the citrate is added to the blood in the needle probably before incipient coagulative changes have taken place. Whether the reaction following citrate transfusion is due to the intravenous injection of the citrate alone, its action on the transferred blood or its action on the blood already possessed by the recipient is not clear. Many explanations has been offered for the causation of such reactions. Incipient coagulative changes, as the modification in the blood platelets and the formation of thromboplastin and

62. Butsch, J. L., and Ashby, W.: The Effect of the Digestive Period and Other Factors in Reactions After Blood Transfusion, New York M. J. **113**:513 (April 6) 1921.

thrombin, are believed by some writers [63] to be the factors. Mellon, Slagle and Acree [64] have called attention to the possible rôle of the variable p_H of sodium citrate in the causation of reactions in sodium citrate transfusions.

Blood is not toxic at the moment of removal but becomes so during the early clotting changes and its toxicity is increased by contact with foreign substances.[65]

The introduction of a foreign protein is looked on as a cause of reaction in a small percentage of cases. A protein solution, such as blood serum, intravenously injected, may be harmless alone but may be activated sufficiently by the patient's blood to become toxic. Skin reactions, such as urticaria, following injection of alien blood may be looked on as foreign protein reactions. We have noted several cases in which urticaria was the only manifest reaction. The possibility of free hemoglobin in the blood being a cause of reactions following transfusion has been eliminated by the work of Sellards and Minot [66] and of Bayliss.[67]

Many cases of hemolysis following transfusion are recorded, many of which have been fatal. We have had no cases of hemolysis in which there were no errors in the preliminary blood testing. From the number of cases of hemolysis that have occurred since the advent of blood grouping, one may imagine the number that must have occurred before its introduction. Hemolysis may be due either to the action of the donor's serum on the recipient's cells or to the action of the recipient's serum on the donor's cells. The latter is probably more frequent because of the dilution of the donor's serum by the recipient's blood.

---

63. Brem, W. V.: Footnote 12. Clough, M. C., and Clough, P. W.: A Study of the Reactions Following the Transfusion of Blood, Southern M. J. **14**:104 (Feb.) 1921. Drinker, C. K., and Brittingham, H. H.: The Cause of the Reactions Following Transfusions of Citrated Blood, Arch. Int. Med. **23**:133 (Feb.) 1919. Meleney, H. E.; Stearns, W. W.; Fortuine, S. T., and Ferry, R. M.: Posttransfusion Reactions, Am. J. M. Sc. **154**:933 (Nov.) 1917. Minot, G. R., and Lee, R. I.: Treatment of Pernicious Anemia, Boston M. & S. J. **177**:761 (Nov. 29) 1917. Satterlee, H. S., and Hooker, R. S.: Transfusion of Blood, with Special Reference to the Use of Anticoagulants, J. A. M. A. **66**:618 (Feb. 26) 1916. Sydenstricker, P. V. W.; Mason, V. R., and Rivers, T. M.: Transfusion of Blood by the Citrate Method, J. A. M. A. **68**:1677 (June 9) 1917. Unger, L. J.: Footnote 58.

64. Mellon, R. R.; Slagle, E. A., and Acree, S. F.: The Practical Application of Buffers in Regulation of Hydrogen Ion Concentration of Intravenous Solutions, J. A. M. A. **78**:1026 (April 8) 1922.

65. De Kruif, P. H.: Primary Toxicity of Normal Serum, J. Infect. Dis. **20**:717 (June) 1917.

66. Sellards, A. W., and Minot, G. R.: Injection of Haemoglobin in Man and Its Relation to Blood Destruction, with Especial Reference to Anemias, J. M. Res. **49**:469 (July) 1916.

67. Bayliss, W. M.: Is Hæmolysed Blood Toxic? Brit. J. Exper. Path. **1**:1 (Feb.) 1920.

Red blood cells of each may be destroyed by the other's serum. Bernheim[68] collected statistics on 800 transfusions by twelve different operators and found fifteen cases of hemolysis with four deaths. Percy[15] reports two cases in which fatal hemolysis occurred when the preliminary hemolysis tests were negative. Minot and Lee[69] have reported three cases of isohemolytic reactions in patients in whom transfusion had previously been performed. There was no agglutination or hemolysis of the donor's or recipient's blood before or after transfusion. This suggested the formation, through previous transfusions, of some unknown antibodies. Boidin had a case in which severe shock and hemolysis occurred in a transfusion with perfectly matched blood. Many other cases of hemolysis have been reported.[70]

In two of our cases, fatal hemolysis followed transfusion. In the first patient, transfusion was performed because of loss of blood by a secondary hemorrhage following a nasal operation. The blood of both the donor and the recipient was reported to be in Group IV, their blood matching perfectly. The patient was given 620 c.c. of blood by the syringe-cannula method, without immediate untoward effect. Shortly after the transfusion, persistent vomiting began together with suppression of urine. At the end of twenty-four hours, she voided 30 c.c. of urine containing a few red and white blood cells, much hemoglobin and many casts. Icterus followed shortly, accompanied by an enlargement of the liver. The spleen could not be felt, and there was no fever. A hemorrhagic retinitis developed. Before transfusion, the erythrocyte count was 3,100,000; the leukocyte count, 19,000; hemoglobin, 60 per cent. The day after transfusion, the erythrocyte count was 2,500,000; the leukocyte count, 25,000; hemoglobin, 60 per cent. The erythrocytes were normal in contour; there was some unusual achromia, but no granular degeneration of cells. Fragility tests showed hemolysis of the blood of the recipient and of the donor by sodium chlorid to be within normal limits. The blood of the donor and of the recipient was rematched and found not to be compatible. The recipient died eleven days after

68. Bernheim, B. M.: Blood Transfusion, Hemorrhage and the Anemias, Philadelphia, J. B. Lippincott Company, 1917.

69. Minot, G. R., and Lee, R. I.: Footnote 63, fifth reference.

70. Bogardus, F. B.: Influenza Pneumonia Treated by Blood Transfusion, New York M. J. **109**:765 (May 3) 1919. Crile, G. W.: Transfusion, with a Note on Hemolysis, Surg., Gynec. & Obst. **9**:16, 1909. Flörcken, H.: Direct Transfusion of Blood, München. med. Wchnschr. **59**:2657 (Dec. 3) 1912; abstr. J. A. M. A. **60**:250 (Jan. 18) 1913. Gray, F. D.: Direct Transfusion, Med. Rec. **79**:192, 1911. Pepper, William, and Nisbet, Verner: A Case of Fatal Hemolysis Following Direct Transfusion of Blood by Arteriovenous Anastomosis, J. A. M. A. **49**:385 (Aug. 3) 1907. Rehling and Weil: Avoidance of Hemolysis in Transfusion, Am. J. Surg. **22** (March) 1909. Suttner: Arteriovenous Transfusion by the Crile Method, Northwest M. J. **3**:192, 1911. Watts: Suture of Blood Vessel, Ann. Surg. **46**:373, 1907.

receiving the blood. The second fatal case, due to an error in laboratory technic of blood testing, followed transfusion in a patient suffering from myelogenous leukemia. Forty cubic centimeters of blood had been given by the syringe-cannula method, when the patient became nauseated and restless. She vomited and became unconscious. Transfusion was stopped simultaneously with the first symptoms. A chill occurred, with a rise of temperature to 108 F.; the pulse became weak; blood pressure fell from 130 to 90 systolic. She voided 90 c.c. of urine containing erythrocytes and hemoglobin. Death ensued fourteen hours after the transfusion. The first patient received 620 c.c. of blood, transfusion being followed by an insidious onset of hemolysis; while the second received only a small amount of blood, its transfusion resulting fatally for her in a short time. Lindeman believed 10 per cent. of his reactions were due to hemolysis in vivo.

No recipients among our cases have developed symptoms of acute cardiac dilatation. When massive transfusions are given, the last few hundred cubic centimeters of blood are given slowly, regardless of the method employed, and the patient is watched for ill-effects.

Rubber tubing used in citrate transfusions has been found by Busman [71] to be a factor in the number of reactions. The brand of supposedly pure gum rubber tubing, which was found to produce reactions in arsphenamin injections, is apparently able, when new, to produce reactions if used in blood transfusion. The toxic agent is removed by soaking the tubing in normal sodium hydroxid for six hours.

Reactions may be further minimized by the use of only absolutely clean and sterile syringes, glassware, etc. The amount of saline used in the tubing for citrate transfusion, or in syringes when the latter are used, should be the smallest possible. The blood should be introduced before cooling has taken place.

In seventy-nine sodium citrate transfusions for various indications at the Barnes Hospital, thirty-seven, or 46.8 per cent., were followed by rise of temperature of more than 1 degree, either accompanied or unaccompanied by other symptoms. Twenty-four of the thirty-seven patients had chills. In seventy-nine transfusions by the use of syringe cannulas, eleven patients, or 13.6 per cent., had a similar reaction. All except three of the foregoing transfusions were performed on adults. In another group of cases extending over the same length of time at the St. Louis Children's Hospital, there was a much lower percentage of reactions. The majority of these patients were infants, and all were under the age of 14 years. Seventy-three blood transfusions were given to fifty-two patients. In sixty-five sodium citrate transfusions, there was a posttransfusion reaction, as interpreted in the preceding cases, in nineteen cases, or 29.2 per cent. In six transfusions by means

71. Busman, G. J.: Rubber Tubing as a Factor in Reaction to Blood Transfusion, J. Lab. & Clin. Med. **5**:693 (Aug.) 1920.

of syringes, there were no reactions. No reaction followed the use of waxed tubes in two transfusions. As practically the same technic of the three methods was carried out in all cases, it seems that children are not so prone to transfusion reactions as adults.

There is a wide variation in the percentage of reactions at other clinics. Pemberton,[72] in 1,000 citrate transfusions at the Mayo Clinic, found that 21 per cent. of the patients had reactions consisting of chills and fever in from fifteen minutes to one hour afterward; another group, 15 per cent., had a rise of temperature to 100 F. In seventy-five citrate transfusions by Lewisohn,[73] 10 per cent. of the patients had a chill. In 129 other citrate transfusions by him, 15 per cent. of the patients had chills, while in 200 other transfusions, 20 per cent. of the patients had chills and in the last 365 transfusions by the citrate method 24 per cent. of the patients had chills. Lewishon, in a special series of cases, found posttransfusion reactions in 23 per cent. following citrate transfusion and in 34 per cent. after the employment of Unger's method. Meleny, Sterns and Fortuine [74] report 64.8 per cent. of reactions in 280 transfusions by the sodium citrate method, and 64.4 per cent. of reactions following seventy-three syringe-cannula transfusions. Sydenstricker, Mason and Rivers [75] in 100 citrate transfusions in thirty-four patients had 17 per cent. mild reactions. In 1914, Lindeman,[76] in 150 syringe-cannula transfusions, observed chills in 33 per cent. of the patients. In 1916, he reported 146 transfusions, in which he had personally supervised the blood tests, with only 9 per cent. of chills. In 1919, he had performed 214 transfusions, with no resultant chills. Minot and Lee,[69] in ninety-two transfusions, in most of which paraffin tubes were used, observed 40 per cent. reactions. Drinker and Brittingham,[77] in eighty-three transfusions by the citrate method, observed a rise in temperature of 2½ degrees in 60 per cent. of cases, and 47 per cent. of these patients had chills.

INDICATIONS FOR TRANSFUSION

In considering the indications for transfusion, the fate and function of the different elements of the transfused blood in the donor are an

---

72. Pemberton, J. de J.: Blood Transfusion, Surg., Gynec. & Obst. **28**:262 (March) 1919.

73. Lewisohn, R.: Sodium Citrate in Blood Transfusion, Ann. Surg. **64**:618 (Nov.) 1916; Chills Following Transfusion of Blood, J. A. M. A. **80**:247 (Jan. 27) 1923.

74. Meleny, H. E.; Stearns, W. W.; Fortuine, S. T., and Ferry, R. M.: Footnote 64, fourth reference.

75. Sydenstricker, P. V. W.; Mason, V. R., and Rivers, T. M.: Footnote 63, seventh reference.

76. Lindeman, E. E.: Blood Transfusion, J. A. M. A. **62**:913, 1914; Reactions Following Blood Transfusion by Syringe Cannula System, ibid. **66**:624 (Feb. 26) 1916; Blood Transfusions Without a Chill by Syringe Cannula System, ibid. **72**:1661 (June 7) 1919.

77. Drinker, C. K., and Brittingham, H. H.: Footnote 63, third reference.

important physiologic problem. The blood volume, an important factor in pathologic states, is believed to be reduced in the majority of the severe anemias. During transfusion, the blood volume may be calculated by the method given by Lindeman.[78] There is a tendency toward a constant plasma volume, which is attained only by the withdrawal of tissue fluids. The advisability, following an acute hemorrhage, of restoring blood volume with blood is highly desirable. It is just as essential in the chronic anemias, for variations seem to be most marked in individuals with a low hemoglobin content. When the total blood volume may not be markedly lowered, there can be demonstrated in severe anemia, by hematocrit readings, a relative increase in the plasma and decrease in the red blood cells. Clinically, this decrease of red blood cells is evidenced often by an increased blood flow and dyspnea, which are an effort on the part of the tissues to rid themselves of accumulated carbon dioxid.

Hemoglobin, as well as blood volume, then becomes a decisive factor in the anemias. Corpuscles make up about one half the volume of the normal blood; but to be of value the transfused cells must continue to be able to carry oxygen. The ability of any red blood cell to carry oxygen is dependent on the age of the cell, the rate of the circulation and the salt content of the plasma. Clinical improvement, following transfusion, of symptoms attributable to asphyxiation argues for the retention of the ability of the red blood cell to function normally. Blood estimations, furthermore, show increases, and smears of the blood of the recipient show no morphologic changes in the cell bodies. There is no clinical or laboratory evidence of the immediate destruction of such transferred cells.

The long life of the transfused cell is striking evidence of the continued functioning of the cells. Transfused cells were found by Ashby[79] in the circulation of a normal person after thirty days. The length of life of transfused cells may be even greater in the anemias than in the normal. Wearn, Warren and Ames[80] found that the life of the transfused cells in primary and secondary anemias averaged eighty days. It is reasonable to assume they would soon be extruded from the circulation as other foreign bodies were they not functioning. Large quantities of fine particles of india ink disappeared from the blood stream of a rabbit within an hour.[81] The mode of the final elimi-

---

78. Lindeman, Edward: A New Method for Estimating Blood Volumes in Anemias, J. A. M. A. **70**:1209 (April 27) 1918.

79. Ashby, W.: Transfused Blood; Periodicity in Eliminative Activity Shown by Organisms, J. Exper. Med. **34**:127 (Aug.) 1921.

80. Wearn, J. T.; Warren, Sylvia, and Ames, Olivia: The Length of Life of Transfused Erythrocytes in Patients with Primary and Secondary Anemia, Arch. Int. Med. **29**:527 (April) 1922.

81. Tait, J.: "Marrow Pains" in Malaria and in Other Acute Fevers, Canad. M. A. J. **12**:134 (March) 1922.

nation of the red cells is not known. Fragmentation, phagocytosis and hemolysis are factors. Evidence that red blood corpuscles enter the circulation and function after an intraperitoneal transfusion of blood has been presented.[82] The reinfusion of free blood in the peritoneal cavity is practiced by several.[83] Subcutaneous injection of blood may even cause a rise in the percentage of hemoglobin.

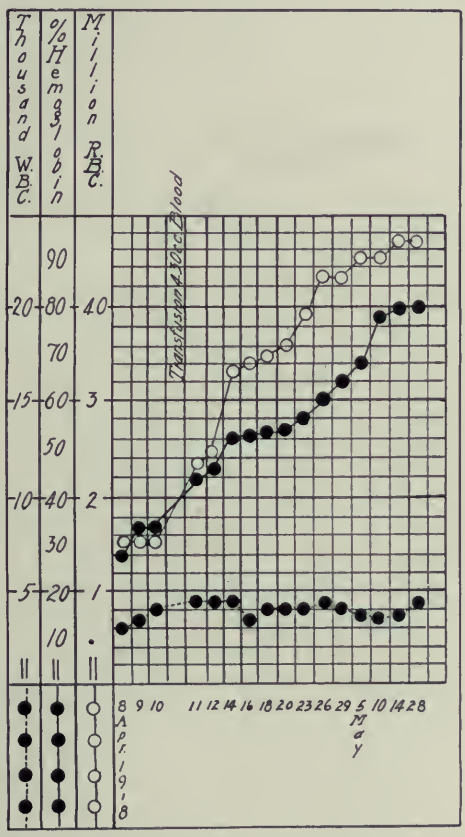

Chart 1.—Marked response to a blood transfusion for a secondary anemia resulting from a thigh amputation for epithelioma of the leg. There was little blood lost at operation.

---

82. Siperstein, O. M., and Sansby, J. M.: Intraperitoneal Transfusion of Citrated Blood, Proc. Soc. Exper. Biol. & Med. **20**:111, 1922.

83. Goder: Transfusion of Blood and Autotransfusion, Deutsch. Ztschr. f. Chir. **170**:384, 1922. Rietz: Effusion of Blood into the Abdomen and its Use for Transfusion, Lyon chirurg. **19**:34, 1918. Töpler, B.: Ueber Blutinfusion bei 24 Fällen von Graviditas extrauterina rupta, Deutsch. med. Wchnschr. **48**:92 (Jan. 19) 1922. Zimmerman, R.: Indications for Retransfusion of Blood Which Has Escaped into the Abdominal Cavity. Ztschr. f. Geburtsh. u. Gynäk. **84**:335, 1921.

Thromboplastic material is transferred from donor to recipient; which can alter the coagulating mechanism. In certain injections, the transference of immune bodies has been of value, both from specifically and from nonspecifically immunized donors.

The improvement noted clinically in well chosen cases of transfusion is not due to the bulk of the transferred blood alone but to its stimulation of the hematopoietic organs as well. Immediately following a transfusion there is an increase in the red cell count and in the hemo-

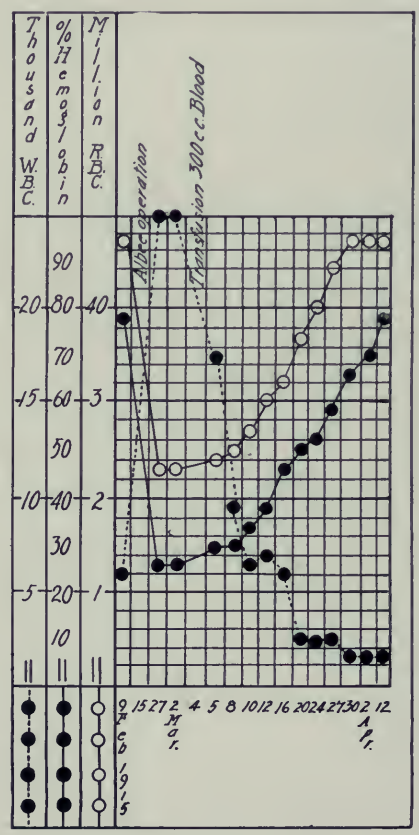

Chart 2.—Remarkable blood changes following a transfusion for secondary anemia following an operative wound infection. There was a fall in leukocytes subsequent to transfusion.

globin reading, which is accounted for by the volume of the blood transferred. Following this initial rise, there may be a slight fall in the readings during the first twenty-four hours. The subsequent steady rise, as seen in the simple anemias (Charts 1 and 2), and, undoubtedly, initiated by the transfusion, must be due to the stimulated production of blood-forming organs. The increase of cells is evidenced by the finding of new formed cells in smears by vital staining.

HEMORRHAGE AND SHOCK

There has been accumulated during the war, and in the period since, a vast amount of clinical and experimental facts concerning the value of blood transfusion in hemorrhage and shock. It has been established as almost a specific in acute hemorrhage, and its great value in shock, associated with hemorrhage, and in shock alone, has been established. The rationale of the procedure is based upon the experimental work of Erlanger, Cannon and Bayliss, together with their collaborators, and others.[84] Many clinical observations have been made.[85]

---

84. Erlanger, Joseph; Gessell, Robert; Gasser, H. S., and Elliott, B. L.: Surgical Shock, J. A. M. A. **69**:2089 (Dec. 22) 1917. Erlanger, J., and Gasser, H. S.: Hypertonic Gum Acacia and Glucose in the Treatment of Secondary Traumatic Shock, Ann. Surg. **69**:389 (April) 1919. Cannon, W. B.; Fraser, John, and Hooper, A. N.: Some Alterations in Distribution and Character of Blood in Shock and Hemorrhage, J. A. M. A. **70**:526 (Feb. 23) 1918. Cannon, W. B.: Nature of Wound Shock, J. A. M. A. **70**:611 (March 2) 1918; Course of Events in Secondary Wound Shock, ibid. **73**:174 (July 19) 1919; Studies in Experimental Traumatic Shock, IV, Arch. Surg. **4**:1 (Jan.) 1922. Bayliss: Proc. Roy. Soc. London, Series B, **89**:380, 1915-1916. Gasser, H. S., and Erlanger, J.: Plasma Volume and Alkaline Reserve in Shock, Am. J. Physiol. **50**:104 (Oct.) 1919. White, H. L., and Erlanger, J.: Am. J. Physiol. **54**: (Nov.) 1920. Gessell, Robert: Factors Controlling Volume Flow of Blood, Am. J. Physiol. **47**:438 (Jan.) 1919. Dale: Reports of the Special Investigating Committee on Surgical Shock and Allied Conditions, M. Res. Special Rep., Series 25-26. Dale, H. H., and Laidlaw, P. P.: Histamine Shock, J. Physiol. **52**:355 (March) 1919.

85. Archibald, E.: A Note on the Employment of Blood Transfusion in War, Lancet **2**:429 (Sept. 2) 1916. Archibald, E. W., and McLean, W. S.: Shock as Seen at the Front, Tr. Am. S. A., June, 1917. Armstrong, G. E.: Gastric Hemorrhage, Surg., Gynec. & Obst. **34**:466 (April) 1922. Bernheim, B. M.: Hemorrhage and Blood Transfusion in the War, J. A. M. A. **73**:172 (July 19) 1919, Charles, R., and Sladden, A. F.: Resuscitation Work in a Casualty Clearing Station, Brit. M. J. **1**:402 (April) 1919. Fullerton, A.; Dreyer, G., and Bazett, H. C.: Direct Transfusion of Blood with Description of a Simple Method, Lancet **1**:715 (May 12) 1917. Harrison, B. I.: Blood Transfusion at the Front Area, J. A. M. A. **71**:1403 (Oct. 26) 1918. Herhold: Die Bluttransfusion im Kriege, München. med. Wchnschr. **66**:288, 1919. Interallied Surgical Congress, Paris, March, 1918, discussed by Rieux, J.: Present Status of Transfusion of Blood, Paris méd. **8**:349 (May 4) 1918. Lee, R. I.: Field Observations on Blood Volume in Wound Hemorrhage and Shock, Am. J. M. Sc. **158**:570 (Oct.) 1919. Munroe, A. R.: Rational Treatment of Surgical Shock Based on Proven Physiological Data, Canad. M. J. **12**:136 (March) 1922. Primrose, A.: The Value of Transfusion of Blood in the Treatment of the Wounded in War, Ann. Surg. **68**:118 (Aug.) 1918. Robertson, O. H.: Footnote 55, twenty-first reference. Robertson, O. H., and Bock, A. V.: Blood Volume in Wounded Soldiers, J. Exper. Med. **29**:139, 155 (Feb.) 1919. Robertson, L. B.: A Contribution on Blood Transfusion in War Surgery, Lancet **1**:759 (June 1) 1918. Robertson, L. B., and Watson, C. G.: Further Observations on the Results of Blood Transfusion in War Surgery, Ann. Surg. **67**:1 (Jan.) 1918. Wallace, C.: A Study of One Thousand Two Hundred Cases of Gunshot Wounds of the Abdomen, Brit. J. Surg. **4**:679 (April) 1917.

Whatever may be the essential factors in the cause of shock, there is found, among other changes, a reduction in the effective blood volume and in the volume flow due to vasoconstriction, with resulting capillary stasis. There is associated a low venous pressure and a low or falling arterial pressure. With this knowledge, we rely on blood pressure readings, together with the clinical picture, as an index for the need of a transfusion. Blood counts and hemoglobin readings have proved unreliable. If a patient with a persistently low pressure (systolic, 80), coupled with a rapid, weak pulse, subnormal temperature, cold, moist skin, thirst, rapid respiration, restlessness, etc., does not respond decidedly within a half hour to such measures as the application of heat, fluids subcutaneously and by mouth, morphin if restless or in pain, elevation of the foot of the bed, a transfusion of blood is performed. This is carried out following an actual hemorrhage, or when the patient is in shock or is suffering from a combination of them. Early restoration of the circulating blood volume is of prime importance before there is damage to asphyxiated tissue, especially the central nervous system. The longer the interval of low blood pressure, the less marked will be the effects of the transfusion. Mild cases of hemorrhage and hemorrhage with shock require a restoration of blood volume for the depleted blood and other body fluid reserves, while the severer cases require, in addition to the increase of blood volume, an increase of oxygen-carrying elements.

The amount of blood to be transfused depends on the indication and the size of the patient. In acute hemorrhage, the largest amounts of blood have been given. Two thousand cubic centimeters is the most that has been given to one patient. It is not essential that the same bulk of blood that is lost be restored. The blood volume is to be sustained by fluids introduced subcutaneously and by mouth. Robertson and Bock [86] have emphasized the great value of giving fluids by mouth in these cases.

The effects of a successful transfusion on this group of patients are immediate, and are usually permanent. With the restoration of blood volume and of erythrocytes, there is a rise of arterial pressure; the cardiac rate is slowed with the establishment of normal venous return, and the respiration rate lessens with the reduction of anoxemia.

In fourteen transfusions for acute hemorrhage, eleven were followed by recovery of the patient. One death resulted from hemolysis; one death occurred because the transfusion was delayed too long, and one death occurred during transfusion following an operation for carcinoma of the uterus. In eleven transfusions for hemorrhage, associated with phenomena interpreted as shock, there were four recoveries; three additional recoveries from the hemorrhage, but with subsequent death in

86. Robertson, O. H., and Bock, A. V.: Footnote 85, fourteenth reference.

the hospital from other causes, and four immediate deaths. In twelve transfusions for shock, there were eight recoveries; three deaths, and one recovery from the shock, with subsequent death from another cause.

Since we consider time an important factor in the results of transfusion, we keep a list of available grouped donors, and before every operation in which there is likely to be considerable loss of blood or in which factors conducive to shock are present, a suitable donor, usually

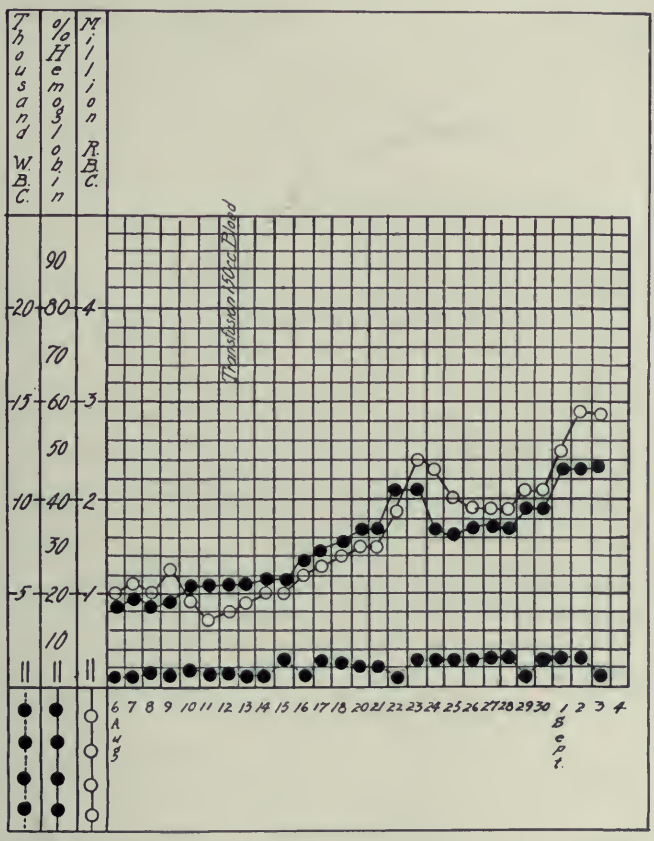

Chart 3.—Transfusion in a case of pernicious anemia, followed by a remission.

from the patient's family, is held in readiness. Operating room facilities should be such that a transfusion can be started fifteen minutes after it has been decided on.

PERNICIOUS ANEMIA

Blood transfusion in pernicious anemia replaces red blood cells, whose production, except in remissions, does not equal their destruction. Either from a failure or erythrogenesis or because of an increased blood destruction, the anemia progresses to a fatal termination. Blood trans-

fusion increases the blood volume, which is reduced in the majority of cases [87] of pernicious anemia. A further action of transfusion is the stimulation of the hematopoietic organs. That there is a stimulation of erythrocyte production may be demonstrated by the increase of polymorphonuclear neutrophils, platelets and reticulated cells following transfusion.[88]

Both small and large amounts of blood have been used, with varying results, for transfusion in cases of pernicious anemia (Charts 3 and 4). Some have been strikingly improved by small amounts and others by

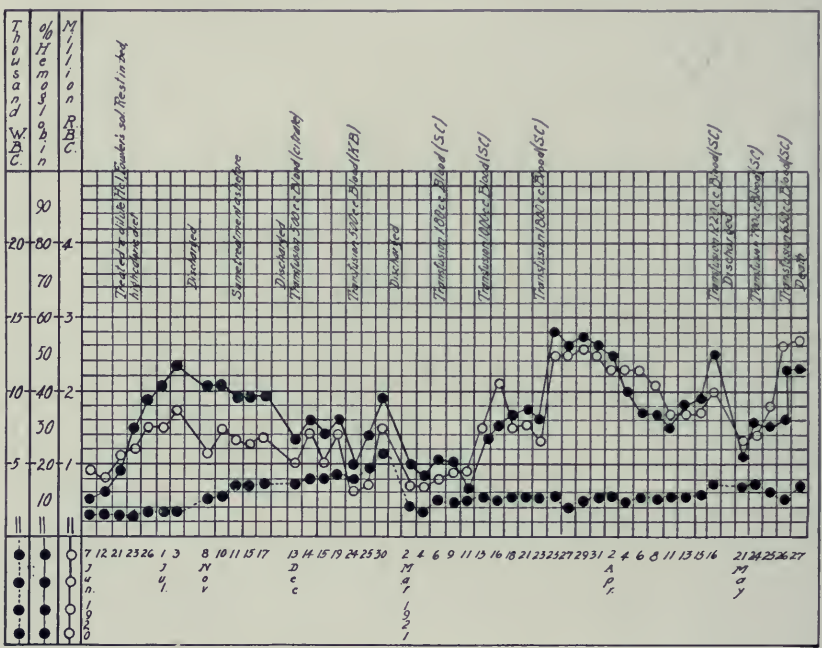

Chart 4.—Poor response to a blood transfusion in a case of Streptococcus viridans septicemia.

large amounts.[69] The average amounts of blood now used varies between 400 c.c. and 800 c.c. During the transfusion of these patients, the blood should be given slowly and the patient watched particularly for cardiac symptoms. Fahr and Ronzone [89] have found that in severe

87. Denny, G. P.: Blood Volume in Pernicious Anemia, Arch. Int. Med. **27**:38 (Jan.) 1921. Lindeman, E.: Total Blood Volume in Pernicious Anemia, J. A. M. A. **70**:1292 (May 4) 1918.

88. Roessingh, M. J.: Test of Bone Marrow Function, Deutsch. Arch. f. klin. Med. **138**:367 (Feb.) 1922.

89. Fahr, G. E., and Ronzone, Ethel: Circulatory Compensation for Deficient Oxygen Carrying Capacity of the Blood in Severe Anemias, Arch. Int. Med. **29**:331 (March) 1922.

anemias increased minute volume of blood is the largest compensatory factor for the loss of oxygen-carrying elements of the blood. The proportional increase of red blood cells and hemoglobin varies in different cases in which the same amount of blood is transfused.

Transfusion should not be performed during a remission, and it should not be delayed until the patient is too weak for the procedure. Posttransfusion reactions have been fatal to such weakened patients. The hemoglobin should never be allowed to fall below 40 per cent.

We have had forty-seven blood transfusions in fifteen patients suffering from pernicious anemia. The length of time the beneficial effect lasts varies widely in the individual and in different patients. Transfusion is not regarded as curative, nor does it have a permanent value. However, it is supportive, may prolong life, and offers more when associated with removal of foci, rest, a rich diet, and the administration of arsenic and hydrochloric acid than any treatment employed at present. Transfusion seems to hasten and prolong remissions of the disease. Anders [90] collected the reports of a total of 450 cases from the literature, in which 1,084 transfusions were performed, and found an initiation of remissions in 56 per cent. of cases. Improvement clinically is usually immediate; in a few cases, this is delayed until the second and third day.

Reactions have been no more frequent in pernicious anemia cases than in any other type of case. Those patients that have had a moderate reaction following transfusion have not been improved more than those that did not.

Splenectomy, in addition to transfusion, before and after, has been carried out in too few cases to permit of any definite conclusions. The impression has been gained that it is of value in selected cases. Mayo [91] believes that the spleen should never be removed while the patient is in a crisis, but that the patient should be brought as nearly as possible to normal by transfusions before operation. The blood curve of such a patient is shown in Chart 5.

SIMPLE ANEMIA

Good results have followed blood transfusion in numerous cases of simple anemia. When there has been long continued loss of blood in small amounts, it is especially indicated. Anemic and cachectic patients may be made good operative risks by the procedure. The transferred blood functions in the simple anemias as in the primary anemias. Frequent transfusions may be necessary to restore the normal blood picture.

---

90. Anders, J. M.: Transfusion of Blood in Pernicious Anemia, Am. J. M. Sc. **158**:659 (Nov.) 1919.

91. Mayo, W. J.: Diseases of the Spleen, Ann. Clin. Med. **1**:141 (Nov.) 1922.

OTHER DISEASES OF THE BLOOD

No alteration in the course of the disease followed transfusion in seven cases of chronic leukemia.

The use of injections of serum in the treatment of hemophilia is well known.[92] Serum from any mammalian species, except the ox and the dog, appears to be effectual. Intravenous injection of human serum apparently produces the longest effect. Clinically, whole blood appears to be better than serum. It is just as easily administered and has the advantage of the addition of corpuscles and platelets. While the effects

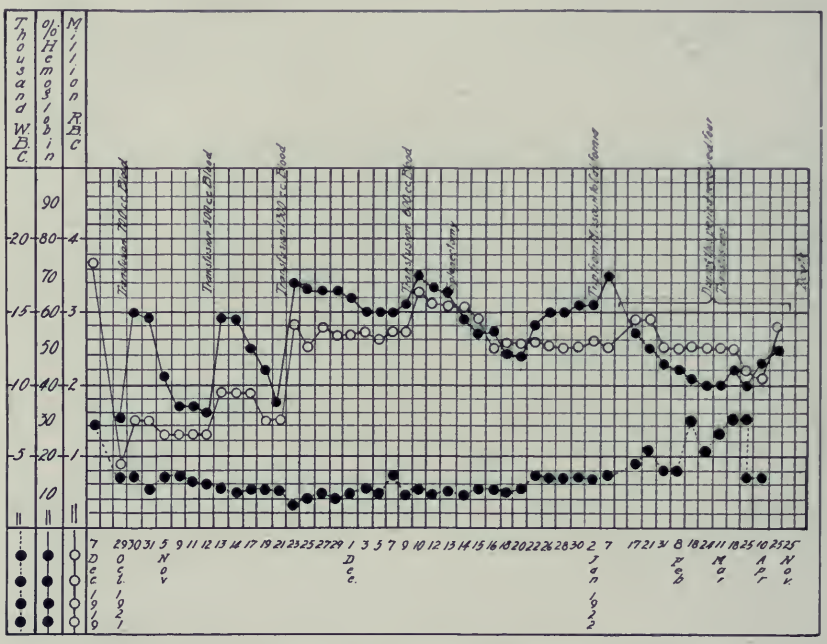

Chart 5.—Blood changes in a case of pernicious anemia in which the patient received multiple transfusions before and after a splenectomy.

are usually immediate, it does not permanently increase the coagulating time. Every hemophiliac should have an available donor.

The hemorrhages of purpura have been temporarily stopped by transfusion. In purpura, the bleeding time is prolonged in contrast to the prolongation of the coagulating time in hemophilia.

---

92. Chalier, J.: Traitment de l'hemophilie congénitale par la sérothérapie maternelle, Rev. de méd. **36**:522, 1919. Lewisohn, R.: Blood Transfusion in Hemophilia Neonatorum, Am. J. Obst. **77**:933 (June) 1918. Peterson, E. W.: Results from Blood Transfusion, J. A. M. A. **66**:1291 (April 22) 1916. Sicard, J. A.: Subcutaneous Homohemotheraphy, Presse méd. **26**:304 (June 13) 1918. Weil, P. E.: Serum Treatment of Hemophilia, Lancet **2**:300 (Aug. 7) 1920.

In hemorrhagic diseases of the new-born, transfusion has been efficacious. If difficulty is experienced in entering a superficial vein, it should be given into the superior longitudinal sinus. If the bleeding is not controlled by transfusion, whole blood or serum should be given intramuscularly.[93] Only small amounts of blood are necessary.

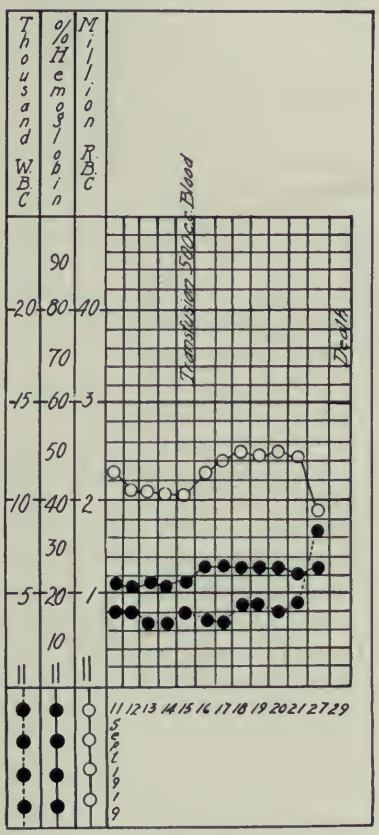

Chart 6.—Blood changes in an advanced case of pernicious anemia in which the patient received multiple blood transfusions.

In nutritional conditions in infants in which the blood proteins are reduced to danger limits, Marriott[94] has used repeated transfusions of

93. Gelston, C. F.: Etiology of Hemorrhagic Diseases of the Newborn, Am. J. Dis. Child. **22**:351 (Oct.) 1921. Green: Boston M. & S. J. **171**:715, 1914. Lespinasse, V. D.: Treatment of Hemorrhagic Diseases of the Newborn by Direct Transfusion of Blood, J. A. M. A. **62**:1866 (June 13) 1914. Schloss, O. S., and Commiskey, L. J. J.: Spontaneous Hemorrhage of the Newborn, Am. J. Dis. Child. **1**:276 (April) 1911. Walthall, D.: Review of the Literature of Hemorrhagic Diseases of the Newborn, J. Missouri M. A. **19**:100 (March) 1922. Welch: Am. J. M. Sc. **139**:800, 1910.

94. Marriott, W. M.: Some Phases of the Pathology of Nutrition in Infancy, Am. J. Dis. Child. **20**:461 (Dec.) 1920.

small amounts of blood, thus tiding over the critical periods by raising the blood protein artificially. He has repeatedly seen good results from the use of blood transfusion in the case of athreptic infants.

ICTERUS

In an attempt to add to the blood of patients suffering from obstructive jaundice those absent elements that are responsible for the prolongation of the coagulating time, we have performed transfusions in these patients preoperatively with moderate amounts of blood. This procedure has been carried out in the deeply jaundiced even though the coagulating or bleeding time was not increased. There has been no postoperative hemorrhage in those that have had this preliminary treatment. The factors affecting the prolongation of the coagulation time in jaundice are not clear. Haessler and Stebbins [95] find that bile interferes with the conversion of fibrinogen into fibrin and not with the formation of thrombin, while Gram [96] finds no decrease in the percentage of fibrin in jaundice.

INFECTIONS

In transfusion in seven cases of streptococcic septicemia from nonspecifically immunized donors, there was no permanent improvement, death following shortly in each instance. Chart 6 shows the poor response of one of our patients. The interesting observation has been made by Kinsella [97] that the reduction in the bacteriemia following transfusion is dependent on the patient's febrile reaction. If there is no posttransfusion reaction, there is no reduction in the bacteriemia. He concludes that no benefit results in either case. Hooker [98] favors the transfusion of immunized blood in cases of chronic staphylococcus septicemia, especially in those associated with bone conditions. We have performed only one transfusion for an acute infectious process, in which, presumably, there was no blood stream infection. The Fourth Interallied Surgical Congress concluded that transfusion is ineffectual and even dangerous in the treatment of acute infections because of the hemolysis that develops in the blood of the infected individual. In chronic infections with a secondary anemia, transfusion has been used

---

95. Haessler, H., and Stebbins, Marianne G.: Effect of Bile on the Clotting Time of Blood, J. Exper. Med. **29**:445 (May) 1919.

96. Gram, H. C.: On the Causes of the Variations in the Sedimentation of the Corpuscles and the Formation of the Crusta Phlogistica ("Size," "Buffy Coat") on the Blood, Arch. Int. Med. **28**:312 (Sept.) 1921.

97. Kinsella, R. A.: Bacteriologic Studies in Subacute Streptococcus Endocarditis, Arch. Int. Med. **19**:367 (March) 1917.

98. Hooker, R. S.: Treatment of Staphylococcus Septicemia by Transfusion of Immune Blood, Ann. Surg. **66**:513 (Nov.) 1917.

with benefit in several cases. Experimentally, the bactericidal action of whole blood is better than that of serum or defibrinated blood.[99] Convalescent human serum has been used by several in the treatment of influenzal pneumonia, with good results.[100]

---

99. Heist, G. D., and Solis-Cohen, S.: The Bactericidal Action of Whole Blood, J. Immunol. **3**:76 (July) 1918.

100. O'Malley, J. J., and Hartman: Treatment of Influenzal Pneumonia with Plasma of Convalescent Patients, J. A. M. A. **72**:34 (Jan. 4) 1919. Hartman, F. W.: Footnote 40. Redden, W. R.: Treatment of Influenza and Bronchopneumonia with Human Serum, Med. Rec. **95**:541, 1919. Ross, C. W., and Hund, E. J.: Transfusion in Pneumonia Complicating Influenza, J. A. M. A. **71**:1992 (Dec. 14) 1918.

STUDIES IN EXHAUSTION: V. HEMORRHAGE

G. W. CRILE, M.D.

CLEVELAND

The conception of many investigators, notably Cannon, Dale, Mann, Erlanger and Gasser, that the primary cause of surgical shock is a loss of blood volume, renders a comparative study of the effects of physical trauma—especially of the abdomen—without hemorrhage, and of hemorrhage without physical trauma, of especial significance, the essential point being to determine what are the primary and what are the secondary factors in the end-results of each. As has been stated in the preceding sections of these studies, the limited space at our disposal prevents specific reference to the work of the many investigators in this field; nor would a review of the literature be appropriate in a presentation, without discussion, of the findings in our own researches. Throughout these studies, however, the literature has been studied, as evidenced by the bibliographic references appearing in previous publications.

Our first separate studies of the effects of hemorrhage unassociated with trauma were begun in 1904. Since then, the phenomena of exhaustion from this cause have been included in various phases of the researches which are still in progress.

A. Blood Pressure Observations

The protocols of this group of experiments have been given in detail in previous publications.[1] The purpose of the earlier experiments was to determine the limits of "compensatory recovery" after hemorrhage; that is, the level to which the blood pressure could be reduced without loss of the power of the circulatory system to maintain an efficient vascular content. We shall not include here any discussion of our experiments in counteracting the effects of hemorrhage. Methods of combating shock and exhaustion, however produced, will be considered together in a later section of these studies.

Our findings in this earlier group of experiments may be summarized as follows:

1. A rapid hemorrhage at a constant rate produced an irregular fall in the blood pressure, the greatest fall occurring just after, or toward the end of, the loss of the first third of the blood removed. When the blood was withdrawn slowly, the blood pressure fell at a more uniform rate.

---

1. Crile, G. W.: Surgical Shock, 1899; Blood Pressure in Surgery, 1903; Hemorrhage and Transfusion, 1909; Anemia and Resuscitation, 1914.

2. In death from hemorrhage, the respiratory center failed first.

3. After a hemorrhage of about six tenths of the total amount of blood, spontaneous compensation sometimes brought the blood pressure back to a level at which life could be maintained (Figs. 1 and 2).

4. The power of compensation after hemorrhage was related to the degree of activity of the vasomotor center. If the hemorrhage was continued until the vasomotor center no longer responded to reflex stimulation, the power of compensation was lost (Fig. 3).

5. After severe hemorrhage, manipulation of the larynx produced respiratory inhibition but did not affect the blood pressure (Fig. 3, *A*).

6. It was impossible to estimate, with any degree of accuracy, the amount of blood in proportion to body weight that any individual

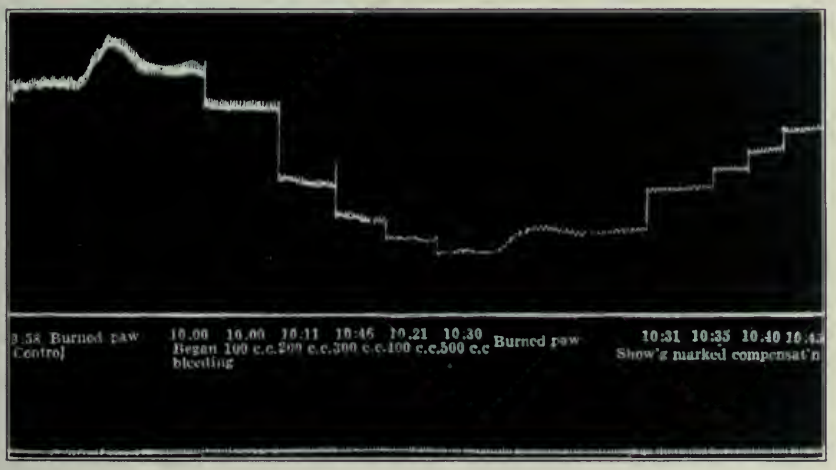

Fig. 1.—Almost complete compensatory restoration of the blood pressure after an acute hemorrhage.

animal could lose before the power of compensation was finally lost. This depended largely on the physical state of the animal.

7. In animals in which a degree of exhaustion had previously been induced by trauma, malnutrition or disease, the power of compensation after hemorrhage was reduced.

B. Studies of the Constituents of the Blood

In order to determine the effect of hemorrhage on the corpuscular and hemoglobin content, blood examinations were made before and after single and repeated hemorrhages.

The findings which are included in Tables 1 and 2 indicate that, after a single hemorrhage of from 4 to 6.6 per cent. of the body

TABLE 1.—*The Effect of a Single Acute Hemorrhage on the Constituents of the Blood and on the Brain Cells*

Experiment	Experimental Data	Length of Life After Hemorrhage	Hemoglobin		Red Corpuscles		Differential Purkinje Cell Count		
			Before, per Cent.	After, per Cent.	Before	After	Active, per Cent.	Fatigued, per Cent.	Exhausted, per Cent.
1	Weight of dog, 5.4 kg.; bled once only; amount, 270 c.c.	6 hours	100	80	7,208,000	4,556,000	82	17	1
2	Weight of dog, 4.3 kg.; bled once only; amount, 250 c.c.	6 hours	100	80	7,280,000	5,296,000	81	18	1
3	Weight of dog, 7.5 kg.; bled once only; amount, 300 c.c.	6 hours	100	95	5,616,000	4,768,000	70	12	18
4	Weight of dog, 4.4 kg.; bled once only; amount, 293 c.c.	6 hours	100	95	5,040,000	4,864,000	68	29	3
5	Weight of dog, 6.6 kg.; bled once only; amount, 444 c.c.	1 hour	100+	..	6,600,000	.....	82	15	3
6	Weight of dog, 6.0 kg.; bled once only; amount, 406 c.c.	2½ hours	100+	..	7,200,000	.....	76	21	3
Average							76.5	18.7	4.8
Normal average							71.2	28.1	0.7

weight, the red cells showed a diminution in number of from 3.5 to 36.8 per cent., with a loss of hemoglobin of from 5 to 20 per cent. After from three to five repeated bleedings, with a total blood loss of from 9.2 to 15 per cent. of the body weight, the red cells showed a diminution in number of from 68 to 78.7 per cent., with a loss of hemoglobin of from 45 to 65 per cent.

In another group of experiments, dogs were bled from the femoral artery, at irregular intervals, and the cell counts and hemoglobin content were compared with those of dogs which had been subjected to shock-producing manipulations of the intestines. The findings are shown in Table 3, and a graphic comparison is made in Figures 4, 5 and 6. In the dogs subjected to hemorrhage, a marked increase in the coagulability of the blood was noted; so that the more a dog was bled, the more

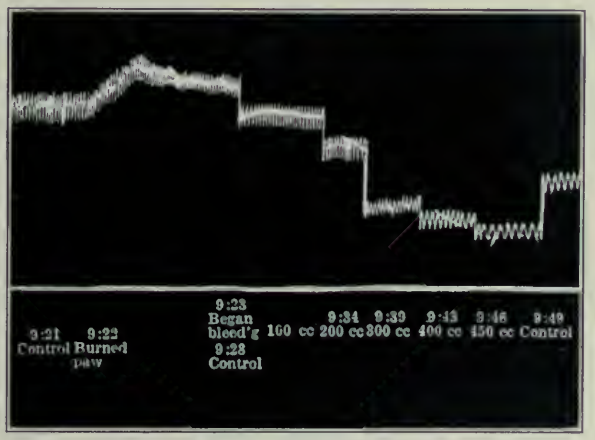

Fig. 2.—Compensatory restoration of the blood pressure after acute hemorrhage, less marked than in Figure 1.

difficult it became to obtain blood from the peripheral circulation. No alteration in the coagulability of the traumatized dogs was noted.

In a group of clinical cases, an examination of the blood of the donors before and after transfusion gave the following results:

Red Cells: In eighteen observations, the number of red cells was decreased in seventeen cases, unchanged in one.

White Cells: In thirteen observations, the number of white cells was increased in twelve cases, decreased in one.

Hemoglobin: In eighteen observations, the hemoglobin was decreased in twelve cases, unchanged in six.[2]

2. A detailed account of these observations is given in Crile, G. W.; Hemorrhage and Transfusion, 1909, pp. 90-123.

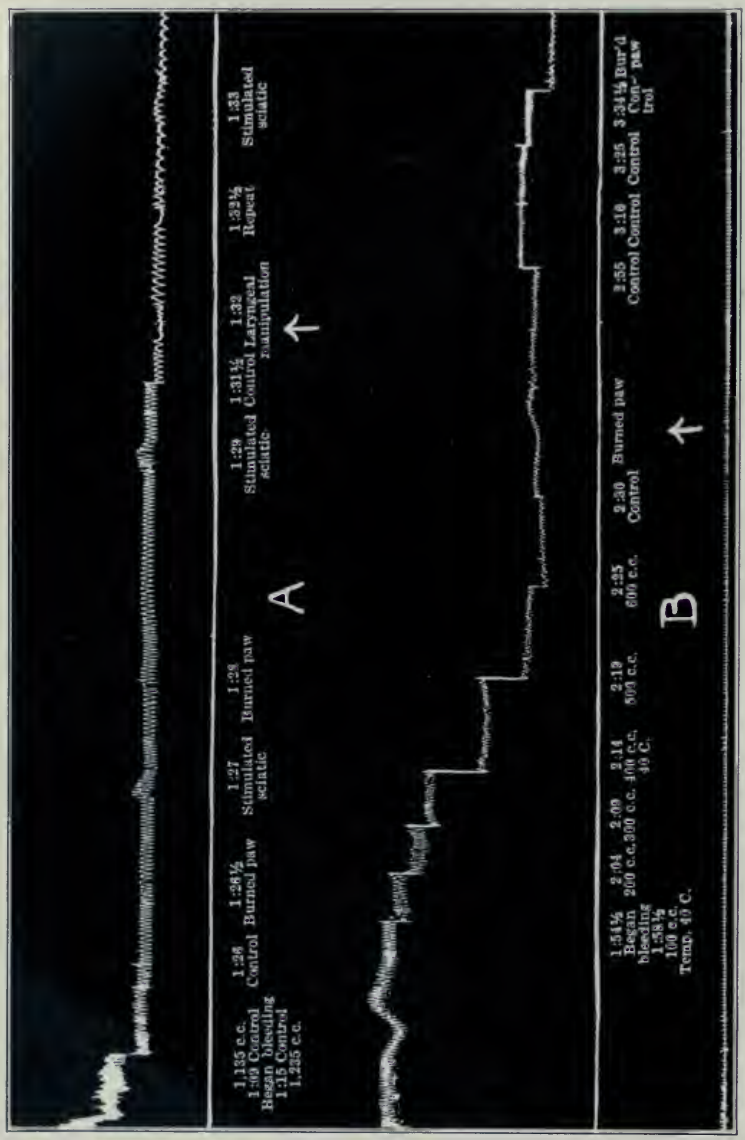

Fig. 3.—Loss of compensatory power after hemorrhage when power of response to reflex stimulation is lost. The lack of response to stimulation at the points indicated by arrows may be noted.

TABLE 2.—*The Effect of Repeated Hemorrhages on the Constituents of the Blood and on the Brain Cells*

Experiment	Experimental Data	Length of Life After Last Hemorrhage	Hemoglobin		Red Corpuscles		Differential Purkinje Cell Count		
			Before, per Cent.	After, per Cent.	Before	After	Active, per Cent.	Fatigued, per Cent.	Exhausted, per Cent.
1	Weight of dog, 10 kg. Amount Bled, C.c. 1..... 500 2..... 270 Total..... 770	4 hours, 22 minutes after second bleeding	100	..	6,392,000	.....	16	51	33
2	Weight of dog, 16.2 kg. Amount Bled, C.c. 1..... 700 2. ..... 350 3..... 450 Total.....1,500	24 hours after last bleeding	100+	50	6,896,000	2,100,000	44	50	6
3	Weight of dog, 6 kg. Amount Bled, C.c. 1..... 250 2..... 150 3..... 100 4..... 200 Total..... 700	4 hours after last bleeding	100—	35	7,432,000	1,584,000	33	56	11
4	Weight of dog, 12.2 kg. Amount Bled, C.c. 1..... 500 2..... 250 3..... 200 4..... 250 Total.....1,200	24 hours after last bleeding	100	45	6,504,000	1,592,000	24	56	20
5	Weight of dog, 10.3 kg. Amount Bled, C.c. 1..... 425 2..... 270 3..... 300 4. ..... 100 5..... 300 Total.....1,395	2 hours after last bleeding	100+	55	7,600,000	2,032,000	27	64	9
6	Weight of dog, 6 kg. Amount Bled, C.c. 1..... 300 2..... 150 3..... 150 4..... 100 5..... 100 6..... 100 Total..... 900	4 hours after last bleeding	100	40	6,800,000	2,168,000	46	45	9
Average.....							31.7	53.7	14.6
Normal average.....							71.2	28.1	0.7

TABLE 3.—*The Comparison of the Effects of Abdominal Trauma and of Hemorrhage on the Constituents of the Blood*

Experiment	Time	Traumatized Dog				Dog Subjected to Hemorrhage			
		Blood Pressure, Mm. Hg	Red Cells	White Cells	Hemoglobin, per Cent.	Blood Pressure, Mm. Hg	Red Cells	White Cells	Hemoglobin, per Cent.
1	Before trauma or hemorrhage	110	7,500,000	8,000	100	105	7,856,000	6,000	98
	After trauma or hemorrhage (200 c.c.):								
	Count 1	62	6,400,000	16,000	100	82	5,888,000	8,000	90
	Count 2	60	7,660,000	11,500	98	34	7,160,000	18,200	85
2	Before trauma or hemorrhage	114	8,440,000	23,800	100	128	6,440,000	16,000	100
	After trauma or hemorrhage:								
	Count 1 (after hemorrhage 180 c.c.)	105	8,304,000	12,400	100	33	5,832,000	11,500	90
	Count 2 (after hemorrhage 180 c.c.)	92	8,944,000	9,100	100	87	6,248,000	23,000	80
	Count 3 (after hemorrhage 40 c.c.)	88	8,933,000	8,200	100	79	4,792,000	19,200	75
	Total hemorrhage, 400 c.c.								
3	Before trauma or hemorrhage	144	6,184,000	25,000	100	148	5,480,000	21,000	100
	After trauma or hemorrhage:								
	Count 1 (after hemorrhage 200 c.c.)	91	6,608,000	6,900	100	120	5,128,000	4,600	100
	Count 2 (after hemorrhage 100 c.c.)	40	6,968,000	6,400	100	100	5,088,000	17,000	80
	Count 3	...	.....	.....	...	52	5,664,000	10,200	75
	Count 4 (after hemorrhage 50 c.c.)	...	.....	.....	...	42	5,760,000	22,400	77
	Total hemorrhage, 350 c.c.								
4	Before trauma or hemorrhage	128	5,920,000	23,600	100	126	8,288,000	7,500	100
	After trauma or hemorrhage:								
	Count 1 (after hemorrhage 325 c.c.)	92	6,240,000	10,400	100	75	7,872,000	5,200	80
	Count 2 (after hemorrhage 225 c.c.)	60	5,216,000	14,000	100	70	8,576,000	4,100	77
	Count 3	84	7,200,000	25,000	100	76	7,784,000	11,500	85
	Count 4	...	.....	.....	...	58	7,520,000	26,000	80
	Total hemorrhage, 550 c.c.								

C. Histologic Studies

The effects of single and of repeated hemorrhages on the brain cells are shown in Tables 1 and 2. In two later experiments, the cerebrum, cord, liver and suprarenals, as well as the cerebellum, were examined (Table 4).

These tables show that exhaustion due to hemorrhage is marked by the histologic changes that are found in exhaustion from physical trauma, shock, emotion, etc. (Fig. 7). Of particular note is the early effect of an acute hemorrhage, as shown in Table 2—an increased per-

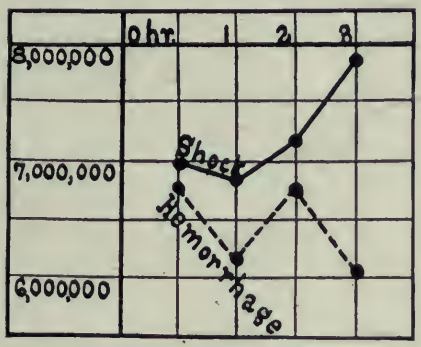

Figure 4

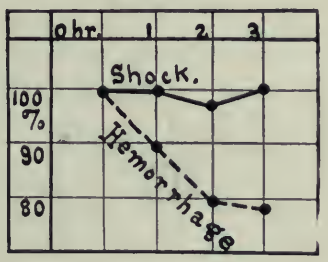

Figure 5

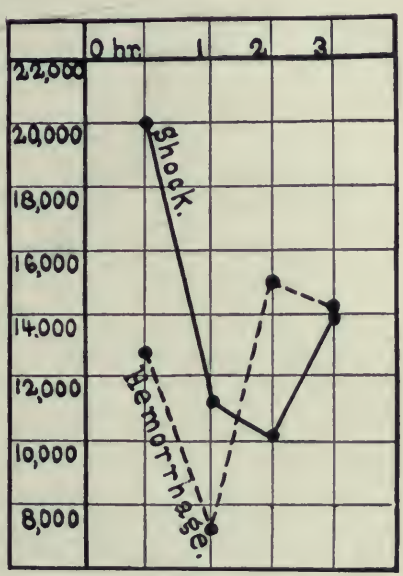

Figure 6

Fig. 4.—Comparison of the effects of hemorrhage and of abdominal shock on the blood of dogs; the red corpuscles.

Fig. 5.—Comparison of the effects of hemorrhage and of abdominal shock on the blood of dogs; the hemoglobin.

Fig. 6.—Comparison of the effect of hemorrhage and of abdominal shock on the blood of dogs; the white corpuscles.

centage of active cells, thus corresponding to the incipient effects of physical trauma, emotion, etc.

D. Physicochemical and Functional Studies

Studies of the Suprarenal Output.—A limited series of observations confirmed Cannon's finding that hemorrhage causes increased activity of the suprarenals.

TABLE 4.—*Effect of Hemorrhage on the Central Nervous System, the Liver and the Suprarenals*

Experiment	Experimental Data	Cerebrum	Cerebellum	Spinal Cord	Liver	Suprarenals
1	Female mongrel; ether anesthesia; 540 c.c. of blood taken during 5 hours; killed immediately after last bleeding	An occasional hyperchromatic and active cell; almost all fatigued, some exhausted	An occasional hyperchromatic cell; some active cells; many fatigued and exhausted	No hyperchromatic cells in anterior horn; some active and some fatigued cells	Moderate and uniform loss of cytoplasm in all cells; no large vacuoles	Loss of cytoplasm and vacuolation in outer half of cortex; medulla normal
2	Young male mongrel; ether anesthesia; abdomen opened for Eck fistula; on account of accidental tear in portal vein, dog used for hemorrhage experiment; bleeding continued at intervals for 4 hours; total amount taken not recorded; killed immediately after last bleeding	An occasional hyperchromatic cell; many active cells and some fatigued	An occasional hyperchromatic cell; some active cells and many fatigued	Cells in anterior horn hyperchromatic	Congested; slight loss of cytoplasm in some areas but no vacuolation; granular appearance of cells not marked	Loss of cytoplasm and vacuolation in outer half of cortex

Measurements of the H-Ion Concentration.—Three measurements of the H-ion concentration of the blood after an acute hemorrhage were made by Dr. Menten, with the following results:

Experiment 1: Before bleeding, p_H 7.453; after bleeding, 7.335, 7.371.

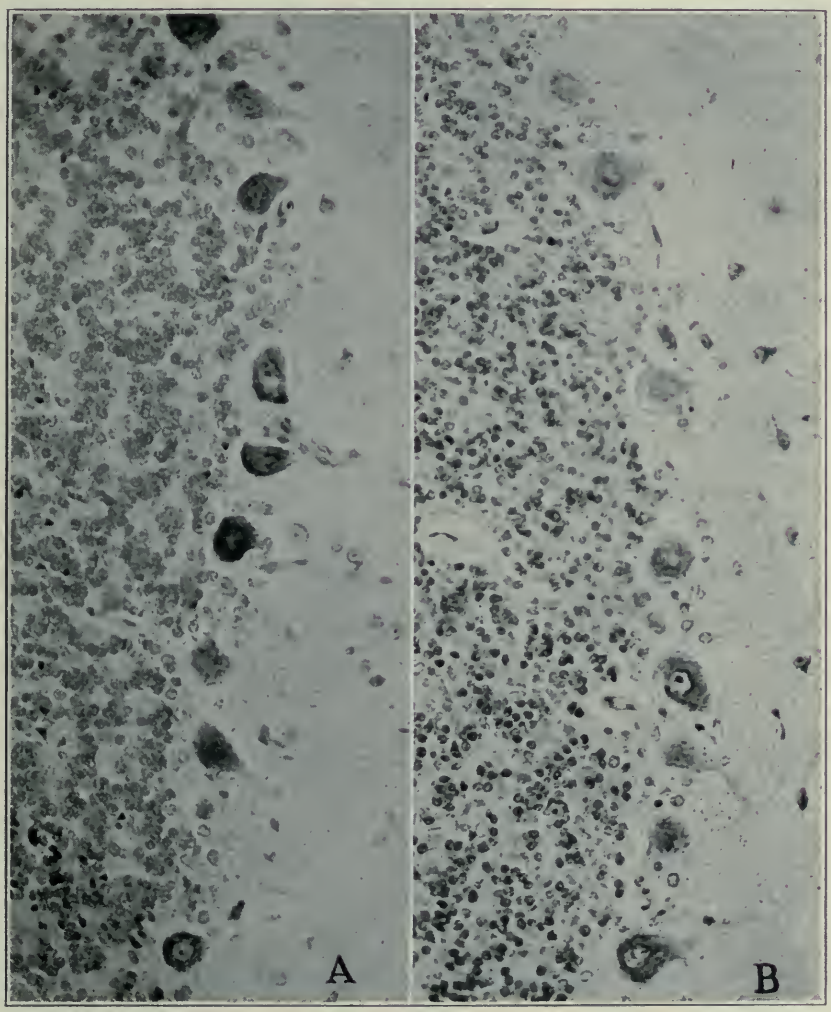

Fig. 7.—Changes in the brain cells resulting from hemorrhage reduced from photomicrographs, × 310. *A*, section of normal cerebellum of a dog; *B*, section of cerebellum of a dog after two hemorrhages on two successive days (Table 2, Experiment 1).

Experiment 2: Before bleeding, p_H 7.58, 7.58; after bleeding, 7.39. 7.38.

Experiment 3: Before bleeding, p_H 7.53, 7.56; after bleeding, 7.39, 7.36.

THERMO-ELECTRIC STUDIES OF TEMPERATURE VARIATIONS IN THE BRAIN AND THE LIVER

In two animals, direct measurements of the variations in the temperature of the brain and liver during a comparatively protracted and a short severe hemorrhage were made. In the first of these experiments (Fig. 8, *A*), the femoral vein was opened; in the second (Fig. 8, *B*), an artery was accidently torn during manipulation of the viscera for the purpose of locating and removing the suprarenals. The comparatively slow progressive fall in the temperature of the brain in the first instance and the abrupt rise in the second are strikingly in accord with the clinical phenomena of a slow hemorrhage and of the immediate effect of an abundant acute hemorrhage. The rise in temperature in

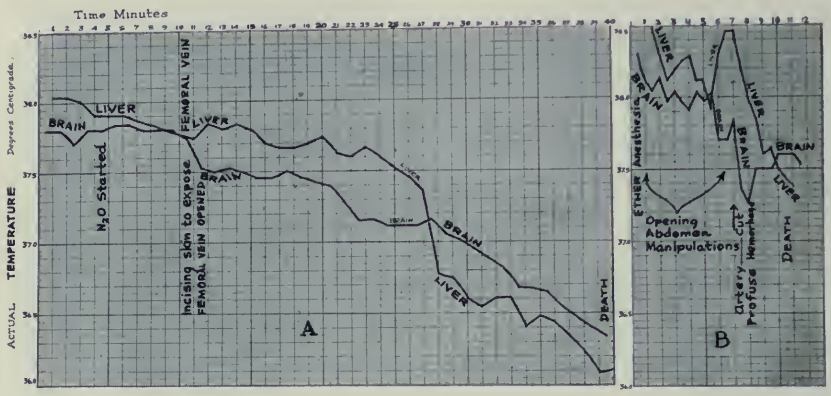

Fig. 8.—Variations in the temperature of the brain and the liver: *A*, during a comparatively protracted hemorrhage; *B*, during a very rapid acute hemorrhage.

the second case corresponds also to the hyperchromatism of the brain cells which is observed in like cases, and to the period of compensatory recovery.

E. Clinical Observations

The clinical results of acute and of chronic hemorrhage would seem too well known for any but passing mention here. It is pertinent to this discussion, however, to call attention to the identity of many of the clinical phenomena due to hemorrhage with those due to exhaustion from other causes; in particular, that form of exhaustion generally designated as "surgical shock," since, as these studies have shown, the primary causes of these clinical phenomena are identical.

Summary

1. The immediate effect of an acute hemorrhage on the cardiovascular system is a stimulation to compensatory activity. If the hemorrhage is protracted, the power of compensation is gradually lost.

2. The immediate effect of an acute hemorrhage on the brain is an increased functional activity, which is manifested by an increase in the percentage of active cells, and an increased temperature of the brain.

3. A prolonged hemorrhage or repeated hemorrhages decrease the functional activity of the brain, as is manifested by a decrease in the percentage of active cells, an increase in the percentage of fatigued and exhausted cells and a decreased temperature of the brain.

4. After hemorrhage, histologic changes characteristic of exhaustion appear in the cortex of the suprarenals and to a lesser degree in the liver. The activation of the suprarenals in the response of the organism to hemorrhage is expressed also by an increased output.

5. The H-ion concentration of the blood is increased by hemorrhage.

6. The effects of hemorrhage as determined in the laboratory and as observed in the clinic, with the exception of the effect on the constituents of the blood, are identical with the effects of physical trauma or of any other exhaustion-producing agent.

7. A slight hemorrhage may be more dangerous in a debilitated patient than a massive hemorrhage in a vigorous subject. There is, therefore, no practical value in the categorical statement that a certain proportion of blood may be lost with safety.

THE CHEMICAL PATHOLOGY OF PYLORIC OCCLUSION IN RELATION TO TETANY

A STUDY OF THE CHLORID, CARBON DIOXID AND UREA CONCENTRATIONS IN THE BLOOD *

HENRY A. MURRAY, JR., M.D.
NEW YORK

Gastric tetany, that form of nerve hyperirritability associated with vomiting, dilatation of the stomach and pyloric occlusion, has interested and puzzled physicians for years. The condition is included in the realm of surgery, since it is usually the result of a gross lesion near the pylorus, and, consequently, its cure depends on operative measures. The clinical literature on the subject has established no definite etiology and the various theories proposed to explain the relationship between the disturbance of gastric physiology and tetany have been unconvincing.

In this paper are recorded the clinical histories and blood analyses of seven cases of obstruction at or near the pylorus, with a summary of the results of some experimental work on dogs. The facts to be presented support the theory that directs attention to the loss of hydrochloric acid from the stomach as the cause of critical changes in the composition and physiochemical properties of the blood. Thus is altered profoundly the "milieu interieure"—the disturbance of whose regulated balance produces such profound changes in the dynamics of protoplasm. In this case, the tissue most conspicuously affected is that of the peripheral nervous system, which shows a progressive increase in irritability. The outward manifestation of this hyperirritability is the clinical condition known as tetany. As other cells of the body are similarly exposed to the disequilibrated blood, there are probably further significant derangements, the nature of which is still a matter of conjecture. These may overshadow in critical importance the nervous condition, and might, if known, be more justly held accountable for the frequently fatal outcome.

HISTORY

Kussmaul,[1] who seems to have been one of the first to differentiate and describe gastric tetany, once believed it to be the result of tissue desiccation. Bouveret and Devie,[2] and later Mayo-Robson,[3] suggested that the absorption of stagnant stomach contents produced the carpopedal spasms. Germain-Sée [4] favored the idea that the somatic nervous

---

* From the Presbyterian Hospital and the laboratories of the Department of Surgery, College of Physicians and Surgeons, Columbia University.

1. Kussmaul, A.: Deutsch. Arch. f. klin. Med. **6**, 1869.
2. Bouveret and Devie: Rev. de méd. **12**:48, 1892.
3. Mayo-Robson, A. W.: Lancet **2**:1392, 1898.
4. Germain Sée, quoted by Mayo-Robson and Moynihan (Footnote 5).

disturbance was a reflex arising from a dilated and hyperirritable stomach.

In many cases there is undoubtedly considerable dehydration, as evidenced by thirst, oliguria, loss of tissue turgor, dry tongue and increased proportion of cellular elements in the blood; but that desiccation is not the cause of the tetany is shown by the fact that experimental tetany develops after pyloric occlusion, in the absence of any apparent thirst and without a change in the normal ratio of cells to plasma. The fluid balance is easily maintained by introducing water into the duodenum, i. e., below the obstruction.

As regards autointoxication, one receives a contrary impression in reviewing clinical case histories, namely, that the emptying of the stomach either through persistent vomiting or by frequent gastric lavage is a significant factor in the production of tetany. MacCallum found that tetany could be rapidly initiated after experimental pyloric occlusion in dogs by frequent washings, and in our experiments the most marked example of tetany developed in a dog whose stomach was thoroughly lavaged two or three times a day. In the face of this evidence, it does not seem that the absorption of stagnating stomach contents could be the cause of tetany, since the latter condition developed when there was no stagnation. In fact, it would seem that the expulsion of stomach contents rather than their introception precipitated the seizures. Moreover, there is normally little absorption from the stomach. In many of the cases in human beings little food was taken, and in all cases of dogs, no food was taken; so that the absorption of products from the fermentation and putrefaction of exogenous substances can be eliminated as a factor. Mayo-Robson's autointoxication theory is possible only on the assumption of vascular absorption of poisonous products from a stomach wall showing no signs of a gross or microscopic pathologic condition, the inner lining of which is being regularly irrigated. The reflex theory has no direct experimental evidence to substantiate it and seems to have few advocates among modern surgeons.

These views were presented at a time when experimental methods of a certain type were crude and speculation was rife. It seems hardly necessary at present to subject them to more detailed and analytic scrutiny.[5]

---

5. I have been unable to find any recent or comprehensive accounts of gastric tetany. For a short general description of the symptoms, course and treatment, the reader is referred to Mayo-Robson and Moynihan (Surgical Treatment of Diseases of the Stomach, Ed. 2, New York, 1904, p. 408); for a bibliography and a discussion of the experimental work and the theories of etiology to Trevelyan, E. F.: Lancet **2**:79, 1898; Halliburton, W. D., and McKendrick, J. S.: Brit. M. J. **1**:1607, 1901, and McKendrick, J. S.: Scot M. & S. J. **21**:253, 1907; and for clinical reports to Cunningham, J. H. Ann. Surg. **39**:527, 1904; Brown, J. Y., and Engelbach, W.: Am. J. Obst. **58**:970, 1908, and Rodman, W. L.: Gastric Tetany, J. A. M. A. **62**:590 (Feb. 21) 1914.

EXPERIMENTAL WORK AND THEORETICAL CONSIDERATIONS

The original impetus to the study of tetany from the standpoint of the acid-base equilibrium was given by Wilson and his co-workers,[6] who investigated the form which follows parathyroidectomy. MacCallum[7] first studied chemical changes after pyloric occlusion, and discovered that there was a marked rise in the carbon dioxid capacity of the blood after this operation. This work, together with the investigations of McCann[8] and some performed in the surgical research laboratories of this college,[9] constitutes the only experimental work published on the subject within recent years. There were no important disagreements in data. The results indicated that, after pyloric occlusion in dogs, there was a rapid and marked increase in the carbon dioxid capacity, and a significant fall in the concentration of chlorids in the plasma. The calcium and the sodium content of the blood was not thoroughly investigated, but the few tests made seemed to show a slight rise in calcium and a fall in sodium. Some support for the high calcium values has been presented in a recent clinical report by Grant,[10] and for the subnormal sodium figures by the analyses of Tisdall.[11] A definite rise in sulphur and phosphorus was found. In our series of experiments, there was a moderate increase in p_H as measured electrometrically in three out of four dogs, a change which was considered too small to account for the nervous hyperirritability.

With the above mentioned findings at hand, we were inclined to believe that the increased irritability was the result of a disturbance in the relative concentration of anions, i. e., decrease of chlorid, and increase in carbonate, phosphate and sulphate ions, rather than a change in hydrogen concentration. The effect of anions of different valences on the colloidal state has been studied by biochemists, and was found significant in numerous instances. MacCallum called attention to the low chlorid concentration as a possible etiologic factor when he found that sodium chlorid was more effective than hydrogen chlorid in preventing canine gastric tetany. Collip,[12] and later Tisdall,[11] emphasized the effect of an increased concentration of $^{-}HCO_3$ ions, and Green-

6. Wilson, D. W.; Stearns, T., and Janney, J. H.: J. Biol. Chem. **21**:169, 1915. Wilson, D. W.; Stearns, T., and Thurlow, M. deG.: J. Biol. Chem. **23**:89, 1915.

7. MacCallum, W. G.; Lintz, J.; Vermilye, H. N.; Leggett, T., and Boas, E.: Bull. Johns Hopkins Hosp. **31**:1 (Jan.) 1920.

8. McCann, W. S.: J. Biol. Chem. **35**:553 (Sept.) 1918.

9. Hastings, A. B.; Murray, C. D., and Murray, H. A., Jr.: Biol. Chem. **46**:223 (March) 1921.

10. Grant, S. B.: Tetany, Arch. Int. Med. **30**:355 (Sept.) 1922.

11. Tisdall, F. F.: J. Biol. Chem. **54**:35 (Sept.) 1922.

12. Collip, J. B.: Am. J. Physiol. **52**:483 (July) 1920.

wald,[13] in a summary of existing hypotheses, stressed the anion equilibrium to which he assigned a control over the permeability of the nerve sheath to the cations.

More definite and applicable data is available dealing with cations, particularly the effect of changes in the sodium : calcium ratio on the irritability of nerves.[14] The increase of the ratio, i. e., the relative increase in the concentration of the sodium was found to increase the irritability of nerve tissue; whereas, the addition of calcium would depress it. The importance of this ratio, or, more generally, the monovalent cation : divalent cation ratio, was affirmed by Fühner,[15] and later reemphasized.[16] This view seems to be supported by the studies of tetany following parathyroidectomy,[17] and of idiopathic infantile tetany,[18] and by experimental infusions of sodium salts in dogs,[19] the injection of calcium precipitants [20] and the results of too vigorous saline or bicarbonate therapy in human beings,[21] intravenously [22] or by rectum.[23]

But it is evident that, by the injection of sodium bicarbonate and sodium phosphate, salts that have been used most frequently in experiments, not only is the sodium increased and calcium decreased, more than can be accounted for in the blood by mere dilution, but also there are added alkaline factors which may be sufficient to increase the p_H

---

13. Greenwald, I.: Proc. Soc. Exper. Biol. & Med. **18**:228, 1921.

14. Mines, G. R.: J. Physiol. **37**:408, 1908. Keith-Lucas; J. Physiol. **40**:225, 1910. Loeb, Jacques.: J. Biol. Chem. **23**:423, 1915. Loeb, Jacques, and Ewald, W. F.: J. Biol. Chem. **25**:377 (July) 1916.

15. Fühner, H.: Arch. f. exper. Path. u. Pharmakol. **58**:1, 1907-1908

16. Hastings, A. B., and Murray, H. A., Jr.: J. Biol. Chem. **46**:233 (March) 1921. Kramer, B.; Tisdall, F. F., and Howland, J.: Infantile Tetany, Am. J. Dis. Child. **22**:431 (Nov.) 1921. Gross, E. G., and Underhill, F. P.: J. Biol. Chem. **54**:105 (Sept.) 1922.

17. MacCallum, W. G., and Voegtlin, C.: J. Exper. Med. **11**:118, 1909.

18. Howland, J., and Marriott, W. McK.: Quart. J. Med. **11**:289 (July) 1918. Jacobowitz, S.: Jahrb. f. Kinderh. **92**:256, 1920. Brown, Alan; MacLachlan, I. F., and Simpson, R.: Effect of Intravenous Injections of Calcium in Tetany and Influence of Cod Liver Oil and Phosphorus in Retention of Calcium in Blood, Am. J. Dis. Child. **19**:413 (June) 1920.

19. Münzer, E.: Arch. Exper. Path. u. Pharmakol. **41**:74, 1898. Binger, C.: J. Pharm. & Exper. Therap. **10**:105 (Aug.) 1917. Greenwald, I.: J. Pharm. & Exper. Therap. **7**:57, 1915; **11**:281 (May) 1918. Starkenstein, E.: Biochem. Ztschr. **32**:243, 1911; Arch. f. Exper. Path. u. Pharmakol. **77**:45, 1914.

20. Starkenstein, E. : Footnote 19, fourth reference.

21. Grant, S. B.: Footnote 10. Tileston, W., quoted by Palmer, W. W., and Van Slyke, D. D.: J. Biol. Chem. **32**:499 (Dec.) 1917.

22. Harrop, G. A., Jr.: Bull. Johns Hopkins Hosp. **30**:62 (March) 1919.

23. Healy, W. P.: Am. J. Obst. & Gynec. **2**:164 (Aug.) 1921. Campbell, O. H.: A Peculiar Case of Common Salt Poisoning, J. A. M. A. **59**:1290 (Oct. 5) 1912.

of the blood and thus affect nerve irritability. There is evidence to show that nervous irritability is a function of the hydrion concentration and that increasing the p_H may cause tetany. The most substantial proof is afforded by the valuable studies of Grant and Goldman,[24] who showed that tetany could be produced experimentally in man by forced breathing. The disturbance in the acid-base equilibrium which was probably responsible for the neuromuscular irritability was evidently caused by the rapid expirations by which carbon dioxid was thrown off. This diminished the carbonic acid in the plasma and disturbed the usual ratio of free carbon dioxid: combined carbon dioxid on which the hydrogen-ion concentration of the blood depends. The changes noted as a result of hyperpnea were an increase in p_H, a fall in plasma and alveolar carbon dioxid, and a cloudy alkaline urine, with a decrease in ammonia and titratable acid. Some of these results confirm earlier investigations.[25]

We have laid emphasis heretofore on ionic equilibrium other than the hydrogen ion: hydroxid ion ratio, because, in the instance of parathyroid tetany, the concentration of calcium was markedly decreased, whereas, the acid-base equilibrium, as determined by hydrogen-ion potentiometer readings and by estimations of the plasma content and capacity of carbon dioxid, was not essentially disturbed;[26] and because, in gastric tetany, the normal relationship of anions was deranged, and the noted rise in p_H we erroneously believed to be insignificant.[9] The findings in parathyroidectomized dogs need reinvestigation. MacCallum[7] and Togawa[27] got results very similar to our carbon dioxid values; whereas McCann[8] found a high carbon dioxid capacity after operation, and Howland and Marriott,[28] using the rather inaccurate dialysis-indicator method, corroborated our p_H findings, but Wilson's[29] conclusions were at variance. Wilson developed the alkalosis theory after measuring the equilibrium constant of oxyhemoglobin (i. e., Barcroft's K, the index of the oxygen capacity of hemoglobin solutions and a function of the hydrogen-ion concentration[30]). It was found that after parathyroidectomy, the value of K rose. Wilson's results seemed to be fairly consistent, but the possibility was not ruled out that the marked disturbance of electrolytes which has been shown to occur after para-

24. Grant, S. B., and Goldman, A.: Am. J. Physiol. **52**:209 (June) 1920.

25. Davies, H. W.; Haldane, J. B. S., and Kennaway, E. L.: J. Physiol. **54**:32 (Aug. 19) 1920. Leathes, J. B.: Brit. M. J. **2**:165 (Aug. 9) 1919. Collip, J. B., and Backus, P. L.: Am. J. Physiol. **51**:568, 1920.

26. Hastings, A. B., and Murray, H. A., Jr.: Footnote 16, first reference.

27. Togawa, T.: J. Lab. & Clin. Med. **5**:299 (Feb.) 1920.

28. Howland, J., and Marriott, W. McK.: Footnote 18, first reference. Cushny, R.: J. Physiol. 391 (May) 1920.

29. Wilson, D. W.: Footnote 6, second reference.

30. Barcroft, J.: The Respiratory Function of the Blood, Cambridge, 1914.

thyroidectomy might account for the increased K. It is known that the salt concentration influences the affinity of hemoglobin for oxygen.[31]

There is another line of thought which harmonizes the two latter views outlined above. As the concentration of free cations, which is the result of the dissociation of the various electrolytes and salt-protein compounds in the blood, has been found in simpler colloidal systems to be a function of the hydrogen-ion concentration, the hypothesis states that a shift in p_H of the plasma may disturb the sodium: calcium ratio. This theory was suggested by Collip[32] in 1920, but without proof. It is known that lowering the p_H tends to release basic ions from combination with amphoteric substances such as proteins.[33] This phenomenon is turned to account in quantitative methods of analysis for calcium and sodium in the plasma. The blood is strongly acidified when the proteins are precipitated, so that the ions will be freed and appear in the clear filtrate. As regards dialysis, calcium ions seem to be different from others (sodium, potassium, etc.) in the blood, as there is a certain fraction which will not pass out of collodion sacs immersed in distilled water, and is always found in the residue, possibly inseparably linked with protein.[34] In 1913, Rona and Takahashi[35] presented evidence on the basis of dialysis experiments with serum to show that increasing the hydrogen-ion concentration would augment the percentage of calcium ions in the dialysate. They insisted on the constancy of the equation $[Ca] = \frac{k[H]}{[HCO_3]}$ for blood serum. This view was reaffirmed by Brinkman,[36] and apparently substantiated by the work of Freudenberg and György,[37] who were led to believe that a rise in p_H is accompanied by the abstraction of calcium ions by serum proteins, their concentration being thus diminished in the fluid surrounding living tissue. As no determinations of the comparative degree of sodium abstraction were made, nothing can be said about the sodium : calcium ratio. A question to be solved is: Does an increase in p_H cause proteins to combine with calcium to a proportionately greater degree than with sodium?

The concentration of active, i. e., free, dissociated ions in a complex system such as the blood can be determined only by direct measurements. An accurate value for the sodium : calcium ratio in any given

---

31. Adolph, E. F., and Ferry, R. M.: J. Biol. Chem. **47**:547 (Aug.) 1921.
32. Collip, J. B.: Canad. Med. J. **10**:935 (Oct.) 1920.
33. Loeb, Jacques: Proteins and the Theory of Colloidal Behavior, New York, McGraw-Hill Book Company, 1922.
34. Rona, P., and Takahashi, D.: Biochem. Ztschr. **31**:336, 1911. Meysenberg, L. von; Pappenheimer, A. M.; Zucker, T. F., and Murray, M.: J. Biol. Chem. **47**:529 (Aug.) 1921. Cushny, A. R.: J. Physiol. **53**:391 (May) 1920.
35. Rona, P., and Takahashi, D.: Biochem. Ztschr. **49**:370, 1913.
36. Brinkman, R.: Biochem. Ztschr. **95**:101, 1919.
37. Freudenberg, E., and György, P.: Jahrb. f. Kinderh. **96**:5, 1921.

case can be obtained in no other way. An electrometric method of measurement, similar in principle to that used for hydrogen determinations, which makes use of sodium and calcium amalgam electrodes has recently been introduced by Newhausen and Marshall.[38] These investigators found that sodium ions and chlorid ions are present in the serum in approximately the same state of dissociation and activity as they are in a simple aqueous solution of sodium chlorid and that when the pressure of carbon dioxid is varied from 0 to 44 mm. of mercury, the concentration of free sodium ions rises from 1 to 2 per cent. at most. This result was interpreted by Neuhausen and Marshall to mean that the amount of sodium normally bound to protein, and freed, by increasing the acidity of the medium, is minimal. Determinations of calcium ion activity were less satisfactory, owing to difficulty with a very reactive amalgam electrode; but the results indicated that only about 10 per cent. of the calcium in serum is dissociated.

These conclusions seem to confirm the work of the German physiologists. However, there are these serious objections to accepting their conclusions: 1. The formula on which their theoretical considerations are based, namely, $[Ca] = \frac{k\,[H]}{[HCO_3]}$ is only true for a saturated solution of calcium carbonate, and therefore probably cannot be applied to plasma. 2. More recent researches to detect a change of dialysable calcium with varying carbon dioxid tensions gave negative results.[39] 3. The assumption that proteins combine more readily with calcium than with sodium has no experimental basis. 4. The assertion on which the entire theory depends, namely, that increasing base-proteinates decreases free calcium ions, is probably incorrect, since proteins ionize freely.

The foregoing paragraphs abstract in bare outline various researches which are relevant to the question of the etiology of tetany from the standpoint of the relative concentration of various electrolytes and the acid-base equilibrium in the blood. The significance of the anions (Cl^-, HCO_3^-, HPO_4^-, etc.) of the cations (Ca, Na, K, etc.) and of the p_H has been discussed. Our results and their bearing on the theories summarized will be reviewed after presentation of the case histories.

It is not to be thought that all possible hypotheses to explain this or other forms of tetany have been included. There are exhaustive investigations of experimental parathyroid tetany which point to the accumulation of large amounts of some toxic compound of nitrogen, believed to be methyl guanidin, as a cause, or at least an accompaniment, of

38. Neuhausen, B. S., and Marshall, E. K.: J. Biol. Chem. **53**:365 (Aug.) 1922.

39. Meysenberg, L. Von, and others: Footnote 34, second reference.

tetany.[40] These findings have been verified in a few cases of infantile tetany,[41] and adult idiopathic tetany.[42] As no studies have been made along these lines in gastric tetany, speculation at this time is idle. However, the fact that the injection of methyl guanidin will cause the calcium concentration of the blood to fall and tetany to ensue is of interest as pointing to a possible relationship between p_H, calcium activity and guanidin metabolism.[43]

In our dogs, no convulsions in any way compared to the tetanic seizures after parathyroidectomy developed, and there was doubt at first that the condition known clinically as gastric tetany had been reproduced. It seems to us probable that the shivering, fibrillary twitchings, muscle spasms and clonic contractions which occurred to a greater or less extent in some of the animals on which operation was performed represent a condition comparable to tetany in human beings. In the first place, there is no evident reason why a convulsion should be selected as determinative of whether or not tetany is present in a dog; in fact, the spasms of the forelegs and feet which frequently come on after pyloric occlusion resemble the carpopedal spasms of human tetany more closely than the generalized convulsions seen after parathyroidectomy. Secondly, MacCallum tested the electrical irritability of the nerves after pyloric occlusion and found it markedly increased; particularly was the current necessary to produce a contraction with cathodal opening much diminished. This has been generally regarded as the most reliable test for tetany. Finally, in the cases to be reported, the dogs that developed unmistakable clinical tetany showed the same blood changes as the dogs that gave the above mentioned signs of hyperirritability.

It is concluded, then, that tetany can be produced in dogs by obstructing the pylorus; and that the operation causes certain chemical changes in the blood: (1) a rise in the carbon dioxid capacity of the plasma; (2) a fall in the chlorid content of whole blood and plasma; (3) an increased concentration of phosphorus and sulphur, and (4) a slight rise in p_H. The few blood analyses made for sodium and calcium were not decisive or consistent enough to be reported with any assurance.

---

40. Paton, D. N., and Findlay, L.: Quart. J. Exper. Physiol. **10**:203, 1916; Brit. M. J. **1**:575 (May 5) 1917.

41. Burns, D., and Sharpe, J. S.: Quart. J. Exper. Physiol. **10**:345, 1916.

42. Findlay, L., and Sharpe, J. S.: Quart. J. Med. **13**:433 (July) 1920. Nattrass. F. J., and Sharpe, J. S.: Brit. M. J. **2**:238 (Aug. 13) 1921. Koch. W. F.: J. Biol. Chem. **12**:313, 1912; **15**:43, 1913.

43. Watanabe, C. K.: J. Biol. Chem. **35**:553, 1918; **36**:531, 1918.

In the cases [44] studied, interest was centered on the carbon dioxid and chlorid concentrations of the blood. Subjects with a carbon dioxid tension of 70 per cent. by volume or over, or with a chlorid concentration below 5.5 gm. per liter for plasma or 4.3 gm. per liter for whole blood, were considered abnormal, and so were included in the group. The urea estimations were made routinely at first, but later, when these appeared to be invariably high, interest was aroused and, in a few cases, the other nitrogen fractions were also determined. The urea, uric acid and creatinin of the blood have been shown to be increased in cases of acute intestinal obstruction, but no study has been made of these substances after pyloric occlusion. Parts of the histories have been omitted as inconsequential to the main subject.

REPORT OF CASES [45]

CASE 1.—*History.*—P. K., aged 71 years, Irish, a retired policeman, admitted, Feb. 8, 1922, complained of persistent vomiting of from three to four weeks' duration. At first, the vomiting followed taking of food, but later it became almost incessant, in small amounts at a time. On three occasions, he had abdominal pain localized in the left epigastrium; in each instance, it was dull, did not radiate and came on after eating. He was very constipated, the bowels moving only after salts were given, and then variably (patient thought about six times in the preceding three weeks). The urine had become scanty. The patient was always thirsty and at times hungry, but he could retain nothing. During the last year, he had lost about 80 pounds (36.3 kg.). Cardiac, respiratory, genito-urinary and nervous histories were essentially negative.

Examination.—The patient was a dyspneic, cyanotic, emaciated man of dull mentality, evidently acutely ill. Loss of subcutaneous fat, emaciation, diminution of tissue turgor and signs of dehydration were evident. There was a feeble pulse and distant heart sounds. The apex beat was not felt, and the borders could not be percussed with surety on account of an overlying hyperresonant lung. The patient had a barrel-shaped chest with prominent flaring costal margins, and prolonged expirations indicated emphysema. There were râles at both bases. The abdomen was flat. There was no distention and no gas. The abdominal wall was quite thick, but a mass seemed to be just palpable in the left epigastrium. Carcinoma of the stomach with stenosis of the pylorus was diagnosed.

February 8: The arterial sounds were practically inaudible. The systolic pressure seemed to be between 70 and 95. The diastolic pressure was not obtained. The plasma carbon dioxid capacity was 68.1 per cent. by volume. The vomitus and stool gave positive guaiac reactions for blood. The patient was given a glucose infusion (3,000 c.c.).

---

44. With one exception, the patients included in this group were treated in the surgical wards of the Presbyterian Hospital. I wish to thank Prof. Allen O. Whipple for his direction and encouragement. Most of the chemical analyses were made by Miss Chudnoff and Miss Kurland in the laboratories of the Hospital. Dr. Baumann initiated investigation in several cases and gave much practical assistance.

45. A short summary of the series was read before the Society for Experimental Biology and Medicine, Proc. Soc. Exper. Biol. & Med. **19**:273, 1922.

*Summary of Cases**

Patient	Diagnosis	Admission Date	Duration of Vomiting	Course	Highest CO_2 Vol. %	Lowest Cl., Gm. per Lit'r	Highest Urea per 100 C.c.	Symptoms of Tetany
1 P. K.	Carcinoma of pylorus; roentgen ray showed complete retention	2/ 8/22	From 3 to 4 weeks	Date: 2/8; 2/10; 2/13; 2/14; 2/16 CO_2: 68.1; 70.0 (1 day after 5.500 c.c. of 0.8 NaCl sol. by clysis); 23.4; 21.2; Death Cl: ; 4.3 Urea: ; 152 N. P. N.: ; 133	70	4.3	152	None
2 M. S.	Carcinoma of jejunum	7/23/21	Occasionally for 6 mos.; frequently for 2 mos.	Date: 7/28; 8/1; 8/3; 8/4; 8/5; 8/6; 8/8; 8/12; 9/10; 9/12 CO_2: 67.1; 63.6; Operation partial jejunectomy; ; ; 73; 71.1; 50.4; 64.2; Discharged. Improved Cl: 3.75; 3.5; 4.2; 5.0; 4.9; ; ; 4.8; 5.4 Urea: 58; 54; ; ; 82; 80; 37; 40; 31 Uric acid: 3.1	73	3.5	82	None
3 J. S.	Postoperative gastric dilatation; acute appendicitis	3/23/21	10 days	3/23: Appendectomy Date: Stomach lavaged 9 times in 5 days 4/1; 4/2; 4/4; 4/6; 4/27 CO_2: 86.2; 82; 82.4; 76.6; Discharged, improved Cl: ; 4.6; 4.5; 5.1 Urea: 97; 80; 110; 40 Creatinin: 1.8; 1.9; 2.2 Uric acid: ; 8; 7.5; 2.6	86.2	4.5	110	Slight twitching
4 I. M.	Ulcer of pylorus with stenosis	5/27/21	From 4 to 5 weeks	Date: 5/28; 5/29; 5/30; 5/31; 6/8; 6/11; 6/14; 6/22; 7/9 CO_2: 80.6; NaCl infusion; 80.6; 76.8 NaCl 73 infusion; Operation, gastroenterostomy; 59.8; Glucose infusion; 65.5; 40.9; 44.7; 40.9; 55.1; Discharged, improved Cl: 4.7; 5.1; 5.38; 5.38; 5.16; ; ; 14 Urea: 105; 101; 110; 109; 280; 191; 167; 2.3 Uric acid: ; ; ; ; 14.5 Creatinin: ; ; ; ; 3.8; 2.8; 1.75	80.6	4.7	280	Slight spasm
5 J. W. (Johns Hopkins Hosp.)	Carcinoma of pylorus with stenosis	3/ 3/22	Occasionally for 2 to 3 mos.; frequently for 1 week	Gastric lavage followed by tetany Date: 3/8; 3/11; 3/22; 3/23; 4/15 CO_2: 103; Operation, gastroenterostomy; 58.7; ; Discharged, improved Cl: ; 3.7; ; ; 6.3 N. P. N.: ; 82.2; ; ; 55.5 Urea N.: ; ; ; ; 22.7	103	3.7	N. P. N 82.2	Tetany; Chvostek and Trousseau signs
6 J. McD.	Ulcer of pylorus with stenosis	6/23/20	Occasionally for 1 mo.; frequently for 4 days	Convalescence from operation for acute appendicitis Date: 7/27; 7/28; 7/29; 7/30 CO_2: Over 100; Muscular hyperirritability; Chvostek sign 104; 86 Glucose and saline infusion with 12 c.c. tenth normal HCl 64; Death	104	...	...	Tetany; Chvostek sign
7 E. L.	Carcinoma of stomach with stenosis	2/17/22	For several weeks, no record	2/10: Operation, gastroenterostomy Postoperative gastric hemorrhage with dilatation; lavaged 7 times in 5 days; vomited frequently CO_2: ; 2/25: ; 2/27: 107.6 Frank tetany; Infusion 500 c.c. tenth normal HCl in 500 c.c. of saline 86.2; 2/28: Death Cl: 4.0; 2.5 Chvostek and Trousseau signs; 3.31 Urea: 247; 334	107	2.5	334	Tetany; Chvostek and Trousseau signs

* The concentration of carbon dioxid is given in percentage by volume; of chlorid in grams per liter; of urea, creatinin, nonprotein nitrogen and uric acid in milligrams per hundred cubic centimeters. Chlorid values are for whole blood except in Cases 3 and 4, and in the lowest reading in Case 5. In Cases 3, 4 and 5, the plasma was used.

February 9: Blood examination showed: hemoglobin, 95 per cent.; red blood count, 6,560,000; white blood count, 23,800; polymorphonuclears, 86 per cent. A glucose hypodermoclysis (5,500 c.c.) was given through six needles simultaneously. Roentgen-ray examination of the stomach after a barium sulphate meal showed complete obstruction, with no peristaltic waves evident. The lesser curvature showed an irregular outline. The pylorus did not fill.

February 10: The blood pressure was 72 systolic, 34 diastolic. The plasma carbon dioxid capacity was 70 per cent. by volume; the whole blood chlorids amounted to 4.34 gm. per liter; the nonprotein nitrogen was 1.33 gm. per liter, and urea to 1.52 gm. per liter. The Wassermann test was negative with both antigens.

February 13: Since entrance, the patient had been almost semicomatose, with a few lucid moments and occasional periods of restlessness and irrationality. He was incontinent, so it had not been possible to collect urine specimens previously. The reaction of the specimen obtained was neutral. There were no casts and no albumin. The plasma carbon dioxid capacity was 23.4 per cent. by volume.

During the last three days, the patient was given hypodermoclyses to maintain his fluid intake. Gastric lavage was carried out several times, food and barium sulphate ingested three or more days previously being recovered. Despite colonic irrigations, enemas and administration of cathartics through the stomach tube, complete obstipation persisted. There were no signs of intestinal contents in the returns from gastric lavage, and there was no abdominal distention, so that it seemed fair to assume that there was a practically complete obstruction at the pylorus.

February 14: The plasma carbon dioxid capacity was 21.2 per cent. by volume. The urine was again neutral, showing no casts and no albumin. A large abscess, apparently from a tooth, developed in the submaxillary region on the left side. Vomiting became incessant. Operation was considered inadvisable because of the manifold complications and patient's poor general condition, efforts to improve which had been unavailing; and because it seemed almost certain that there was present an incurable carcinoma of the stomach.

February 16: The patient died. Necropsy was refused.

In this case, although there was no verifying operation or necropsy, pyloric obstruction seemed certain, probably due to carcinoma. As in the other cases, the carbon dioxid capacity and the concentration of the protein metabolites were increased in the blood. The chlorids were a little low despite the fact that, the previous day, the patient had received over 5 liters of sodium chlorid, subcutaneously. Near the end of the illness, the carbon dioxid content changed rather suddenly from a high to a low figure, possibly owing to a terminal nephritis with acidosis. This sudden reversal of an abnormality in blood reaction was noticed in two of our dogs at the approach of death. Owing to the patient's incontinence, frequent tests could not be made of the urine, but the two specimens examined were neutral in reaction and were negative for albumin and casts. No symptoms of tetany developed.

Case 2.—*History.*—M. S., aged 52 years, an American housewife, entered the hospital, July 23, 1921, complaining of vomiting continuing over a period of four months. Up to six months previously the patient said, she had been quite

well. Suddenly one morning, without any apparent cause, she became nauseated and vomited her breakfast. She had no more trouble for a month, and then suffered a similar attack. There was an accompanying sense of pressure in the epigastrium, but no real pain. The patient said that, for the four months previous to admission, these periodic attacks of nausea and vomiting had been increasing in frequency. She often vomited food which she had eaten twenty-four hours previously. For a week before examination, she had vomited every day. Vomiting relieved the sense of fulness at first, and later the dull, twisting pain which occasionally developed. If she did not eat, she did not suffer. The pain, although not severe, became continuous, and she entered the hospital in a very weakened condition. She had noticed "bunches in the upper abdomen" moving across from left to right. She became more and more constipated. There had been a loss of from 20 to 30 pounds (9 to 13.5 kg.) in weight. The past history did not have any apparent bearing on the present condition. Family and personal histories were irrelevant.

Examination.—The patient was of poor physique, with evidences of loss of flesh. The sclera and cornea of the right eye were scarred, and the patient was blind in this eye (old injury). Carious teeth; coated tongue, with fine tremor, and easily palpable and tortuous arterial walls were noted. Abdominal examination disclosed a narrow costal angle, a sense of a mass near the midline, a slow peristaltic wave moving from left to right in the umbilical region, and kidneys palpable on both sides. The opinion on entrance was that the patient was suffering from chronic ileus, which was probably caused by a malignant growth of the colon. Examination of the blood revealed: blood urea, 58 mg. per hundred cubic centimeters; uric acid, 3.1 mg. per hundred cubic centimeters; chlorids, 3.75 gm. per liter and carbon dioxid, 67.1 per cent. by volume. Four days later, the blood urea was 54 mg. per hundred cubic centimeters; chlorids were 3.5 gm. per liter, and carbon dioxid capacity was 63.6 per cent. by volume. The blood Wassermann reaction was ++++ with both antigens on two examinations. The spinal fluid Wassermann reaction was negative. The roentgen-ray examination of the gastro-intestinal tract, six hours after a barium sulphate meal, showed a large atonic stomach without evidence of peristalsis. The duodenum, which seemed to be fixed, was deflected to the right; twenty-four hours after eating, the largest amount of the meal was in the rectum; the rest was in the cecum and splenic flexure. Roentgenograms and fluoroscopy of the colon after a barium sulphate enema did not reveal any abnormalities.

August 3: The analysis of a specimen of vomitus revealed free hydrochloric acid, 0; total hydrochloric acid, 20 per cent. These figures were confirmed by examination of an extracted sample. The patient underwent lavage frequently during the period of observation. The urine was always acid and at two out of four examinations showed albumin +. The patient received two infusions of 3 per cent sodium chlorid solution, after which the blood chlorid concentration was 4.2 gm. per liter. The preoperative diagnosis was difficult, the main points being (1) age (52 years); (2) a history of four months' of vomiting without any real pain; (3) a loss of from 20 to 30 pounds (9 to 13.5 kg.); (4) a four plus Wassermann reaction; (5) hypochloremia, with a slightly elevated carbon dioxid; (6) roentgen-ray evidence of gastric dilatation and atony with pyloric or duodenal obstruction; (7) marked visible peristalsis, which was believed to be in the transverse colon; (8) negative roentgen-ray examination of the colon.

Operation (Dr. St. John).—August 3: Partial enterectomy (jejunum), was performed, with end to side anastomosis. When the abdominal cavity was

opened, markedly distended and thickened loops of proximal jejunum presented. About 8 to 10 feet below the duodenojejunal angle, there was a pronounced constriction, caused by dense white scar tissue. Below this constriction, the intestines were shrunken and appeared like a flattened ribbon. The constricted portion was excised, and an end to side anastomosis was performed. A rubber tube was inserted in the distended jejunum above the anastomosis and held with a purse string suture. Microscopic examination of the specimen revealed irregular masses of atypical glandular cells. Carcinoma of the jejunum was diagnosed.

Course.—Recovery was rapid.

August 4: The blood chlorids were 5.3 gm. per liter.

August 5: The blood urea was 82 mg. per hundred cubic centimeters and the chlorids were 4.9 gm. per liter. The patient was apathetic and drowsy but was easily aroused. She was fed with glucose solution through the jejunal tube.

August 6: The blood urea was 80 mg., plasma carbon dioxid, 73 per cent. by volume, and blood sugar 1.35 gm. per liter.

August 8: The patient was still stuporous. An enormous discharge occurred through the intestinal tube, which was then removed and the abdomen exposed to the air under an electric bake. The patient was instructed to keep the skin clean with gauze. The blood urea was 37 mg. per hundred cubic centimeters and plasma carbon dioxid, 71.1 per cent. by volume. The patient had a mild post-operative psychosis. She seemed in a semistupor and spoke only in a whisper, with words run together in a monotone. She made unusual grimaces and showed the "catatonic" phenomenon; i. e., spastic extremities yielding slowly to pressure and remaining as placed.

August 9: The urine was alkaline and showed a faint trace of albumin.

August 12: The blood urea was 40 mg. per hundred cubic centimeters, the chlorids were 4.8 gm., and the plasma carbon dioxid was 50.4 per cent. by volume. The wound was dressed every day, the discharge became gradually less and granulations slowly closed the sinus.

September 10: The blood urea was 31 mg. per hundred cubic centimeters, the chlorids were 5.4 gm. per liter and the carbon dioxid was 64.2 per cent. by volume. In five out of seven examinations of urine after operation, the reaction was acid and tests showed albumin twice.

September 12: The patient was discharged, improved.

Thirteen months after operation, the patient was seen in the follow-up clinic. She looked well and said she had no symptoms.

The preceding case is an interesting one for a number of reasons, all of which are not relevant to the subject matter of this article. From a chemical standpoint, it is worthy of note that this case is different not only as regards the position of the occlusion—it is the only case of the series in which the obstruction was not at the pylorus—but also as regards the relative change in bicarbonate and chlorids. It will be noted that, although the chlorids were markedly decreased before operation, the carbon dioxid was not elevated beyond a high normal. The possibility of using this relationship as a point of diagnosis for determining the location of the obstruction is worth considering. In other words, hypochloremia will be found in all cases of persistent vomiting, but alkalosis will be present only when there is a greater amount of

acid than of alkali lost; i. e., in case of an obstruction near the pylorus. The urine was for the most part acid, and only occasionally gave a positive flame test for albumin, but the urea concentration of the blood was elevated. It may be significant to note that, in this case as well as in others, the urea which was found increased before operation rose still higher for a few days after operation, and later descended to within normal limits.

Case 3.—*History.*—J. S., aged 57 years, an Italian laborer, entered the hospital, March 23, 1921, with the typical signs and a history of acute appendicitis of twenty-one hours' duration, with pain, tenderness, spasm and a mass in right lower quadrant. Vomiting was minimal.

Operation.—At the emergency operation (appendicectomy with drainage), a gangrenous appendix, with localized peritonitis was found. The anesthesia was commenced with 0.5 per cent procain, but after the peritoneal cavity was opened, gas-oxygen was used.

Course.—The immediate postoperative recovery was satisfactory, but two days later the patient developed distention of the stomach.

March 26: Gastric lavage with warm 5 per cent. sodium bicarbonate solution was administered. Later, the patient received 1,000 c.c. of 10 per cent. glucose, intravenously. During the next four days, on account of recurring dilatation the patient was given lavage seven times. In that time, he also received five glucose infusions. Moderate amounts of turbid fluid and much gas were recovered at each lavage. At one time, 1½ ounces of castor oil was introduced through the stomach tube, with the hope of remedying what seemed to be a general atony of the entire gastro-intestinal tract. Enemas and colon irrigations were employed for the same purpose. The abdominal wound was treated with surgical solution of chlorinated soda (Dakin's solution), according to a modified Rulison technic. Drainage seemed to be adequate.

April 1: The patient seemed better. There was no distention and no vomiting. The last gastric lavage had brought away only clear fluid. Blood analysis revealed: plasma carbon dioxid, 86.2 per cent. by volume; urea, 97 mg. per hundred cubic centimeters; creatinin, 1.8 mg. per hundred cubic centimeters. Slight twitchings were noted in the extremities, but no real carpopedal spasms.

April 2: The following concentrations were determined in the blood: plasma carbon dioxid, 82 per cent. by volume; urea, 80 mg. per hundred cubic centimeters; creatinin, 1.89 mg. per hundred cubic centimeters; uric acid, 8 mg.; plasma chlorid, 4.6 gm. per liter. The general condition of the patient was about the same. There was no longer occasion for gastric lavage.

April 3: The patient had four bowel movements. He seemed to be much better. The wound was healing satisfactorily.

April 4: Chemical tests showed: plasma carbon dioxid, 82.4 per cent. by volume; urea, 110 mg. per hundred cubic centimeters; creatinin, 2.2 mg. per hundred cubic centimeters; uric acid, 7.5 mg., and plasma chlorids, 4.5 gm. per liter.

April 5: The concentration of calcium in the plasma was 10 mg. per hundred cubic centimeters.

April 6: The patient did not appear to be so well. He seemed unresponsive, tired and sleepy. He complained of anorexia and buzzing in the ears. Blood analysis showed; plasma, 76.6 per cent. by volume; urea, 40 mg. per hundred

cubic centimeters; uric acid, 2.6 mg., and chlorids, 5.1 gm. per liter. The urine diminished in quantity. The urine had been, and still was, consistently negative except on one occasion, when albumin and casts were noted. The reaction was always acid. The next day the patient felt much better, however, and improved rapidly thereafter.

April 8-9: The nitrogen intake was approximately 9.3 gm., the excretion 14.42 gm.

April 13: The phenolsulphonephthalein test showed 35 per cent. in two hours.

April 15: There was an unusually large urinary output. No more signs of renal insufficiency developed.

April 27: The patient was discharged, improved.

This was a case in which, in the course of convalescence from an operation for acute appendicitis, general gastro-intestinal paralysis developed. It was most conspicuous in the stomach, which became recurrently distended. Lavages were regularly resorted to, with considerable temporary relief. About one week after operation, chemical examination of the blood disclosed that the carbon dioxid, urea and uric acid concentrations were increased, and the plasma chlorids were subnormal, but the creatinin content, which is considered by some the most delicate test for pathologic conditions in the kidney, was within the usual limits. The patient did not have tetany, but he showed the hemic changes, though in a less degree, that occurred in other patients who did develop tetany. It is impossible to separate the gastric element and the possible effect of the paralytic ileus. We should be inclined to include this case in the series because of the high carbon dioxid (86.2 per cent. by volume), which would be an indication that hydrochloric acid had been removed. This is consistent with the idea that there exists in gastric dilatation a spasm of the pylorus, with relaxation of the body. Thus, the secreted hydrochloric acid, becoming stagnant in a dilated stomach instead of passing on into the intestines for reabsorption, is finally lost to the body through vomiting or by gastric lavage. The interference with the passage of hydrochloric acid limits the usual initiating stimulus to pancreatic secretion, and thus the abstraction of hydroxyl ions from the blood which otherwise would compensate for the hydrogen ions lost. Of course, we cannot feel sure that this view is correct.

Case 4.—*History.*—T. M., aged 60 years, Irish, a nightwatchman, entered the hospital, May 27, 1921, complaining principally of persistent vomiting of one month's duration. He said that ten years previously he began suffering from indigestion in the form of epigastric distress after meals, belching and occasional vomiting. He had always been constipated. For many years, he had indulged regularly in alcohol. During the previous year, he had been bothered with epigastric pain, which was relieved somewhat by eating. One month ago, while on his beat, he suddenly vomited many times after an attack of sudden severe epigastric pain. Since that day, he had been unable to retain anything

on his stomach. During the last month, he had lost about 50 pounds (22.7 kg.) in weight. The family history was of no importance. There was a history of headaches, dizziness with fainting, failing eyesight and precordial pain. The patient said that he had a chancre thirty years previously. The urinary history was negative.

Examination.—The patient was a large-framed, corpulent man of florid complexion. He showed loss of weight, but looked healthy. The arteries were tortuous. There was a transmitted systolic murmur at the apex. A slight cyanotic tinge of the mucous membranes was evident. The blood presure was 158 systolic, 74 diastolic. The liver edge could just be felt. Otherwise, the abdominal examination was negative. There were no masses and no points of special tenderness. Ulcer of the stomach with stenosis of the pylorus was diagnosed. Roentgen-ray examination, six hours after the ingestion of barium sulphate, showed that none of the meal had passed through the pylorus; but the twenty-four hour plate showed that the stomach was empty. The Wassermann test was negative with both antigens. The analysis of the gastric contents showed free hydrochloric acid, 10 per cent., and total acid, 35 per cent.

May 28: The patient felt quite weak. He said that earlier in the morning he had had spasms in his fingers so that he could not straighten them. He was given an infusion of physiologic sodium chlorid solution. Before the infusion, blood tests showed plasma carbon dioxid capacity, 80.6 per cent by volume; plasma chlorids, 4.7 gm. per liter; plasma phosphates, 5 mg. per hundred cubic centimeters; urea, 105 mg. per hundred cubic centimeters. After the infusion, the tests showed: plasma carbon dioxid capacity, 80.6 per cent. by volume; plasma chlorids, 5.09 gm. per liter; plasma phosphates, 4.5 mg. per hundred cubic centimeters; urea, 101 mg. per hundred cubic centimeters. The urine was acid and showed no albumin and no casts. Gastric lavage was performed twice, with the return of large amounts of fluid and food residue.

May 29: The patient was given a gastric lavage, a hypodermoclysis and an infusion of 1.7 per cent. sodium chlorid solution in 10 per cent. glucose. Before the infusion, the plasma carbon dioxid was 76.8 per cent. by volume. After the infusion, it was 73.0 per cent. by volume.

Operation.—May 30: Exploratory celiotomy, with posterior gastro-enterostomy was performed by Dr. Whipple. Examination revealed a very large indurated mass in the region of the pylorus adherent to the pancreas and the portal fissure. It was so tightly adherent that the removal of it was considered out of the question because of the patient's condition and the danger to vital structures, particularly the portal vein. There did not appear to be any hard glands indicative of carcinoma, and it was thought best to perform only a posterior gastro-enterostomy to relieve obstruction. Microscopic examination of some involved tissue from near the site of the ulcer showed no evidence of new growth.

Course.—After the operation, the patient was very sick and for two weeks went downhill steadily. He finally recovered in a dramatic fashion. He was treated by daily infusions and hypodermoclyses to maintain normal fluid content, and by gastric lavages for distention, vomiting and gastric retention.

May 31: The plasma carbon dioxid capacity was 59.8 per cent. by volume; plasma chlorids amounted to 5.38 gm. per liter; sugar, 1.17 gm. per liter; urea, 110 mg. per hundred cubic centimeters. The patient was then given an infusion (1,000 c.c.) of 10 per cent. glucose. The blood tests were then repeated, showing plasma carbon dioxid capacity, 65.5 per cent. by volume; plasma

chlorids, 5.38 gm. per liter; sugar, 6.5 gm. per liter; urea, 109 mg. per hundred cubic centimeters. During the next few days, the patient continued to vomit, so that oral feeding was impossible.

June 6: Roentgen-ray and fluoroscopic examinations showed that the gastro-enterostomy stoma was open and functioning, and, as the patient's bowels moved regularly, he was often incontinent. It was thought that the vomiting could not be explained on the basis of an obstruction.

June 8: Blood tests showed: plasma carbon dioxid capacity, 40.9 per cent. by volume; plasma chlorids, 5.16 gm. per liter; urea, 280 mg. per hundred cubic centimeters; uric acid, 14.5 mg. per hundred cubic centimeters; creatinin, 3.8 mg. per hundred cubic centimeters.

June 9: Phenolsulphonephthalein excretion was 22 per cent. in two hours.

June 11: The plasma carbon dioxid capacity was 44.7 per cent. by volume; urea, 191 mg. per hundred cubic centimeters; creatinin, 2.8 mg. per hundred cubic centimeters. The patient became drowsy and stuporous and at times irrational. He was evidently losing ground. Gastric lavages were necessary for the retention, hiccuping and recurrent dilatation.

June 14: The plasma carbon dioxid capacity was 40.9 per cent. by volume; urea, 167 mg. per hundred cubic centimeters; creatinin, 1.75 mg. per hundred cubic centimeters. The blood pressure was 75 systolic, 50 diastolic, and the heart sounds were poor. The patient was then given digitalis in rather large doses through the stomach tube. This seemed to be the turning point and in two days the man was transformed from a condition of semicoma with dyspnea and cyanosis to the convalescent state. Improvement was rapid.

June 22: The plasma carbon dioxid capacity was 55.1 per cent. by volume; urea, 142 mg. per hundred cubic centimeters; uric acid, 2.3 mg. per hundred cubic centimeters.

July 9: The patient was discharged, improved.

The chief interest in this case was the remarkable rise and the gradual fall in the protein metabolites. Nine days after the operation, the values for urea, uric acid and creatinin were near a fatal level prognostically, with a low carbon dioxid capacity; two weeks later, the concentration figures were normal. Before the operation, the man had a mild alkalosis and reported spasms of the fingers, but no signs of tetany were demonstrable.

Case 5.[46]—*History.*—J. O. W., aged 28 years, an American, entered, March 3, 1921, complaining of vomiting of about two months' duration. He first noticed that he had a "sour stomach," but soon afterward began to have spells of vomiting. These were preceded by a feeling of fulness and distress. The vomitus was enormous in amount, sour and frothy, and contained undigested food. Vomiting increased in frequency, finally occurring once a day. The patient also complained of eructations, flatulence and nausea after meals. The appetite had been poor, and the bowels constipated. He said he had never had pain in the epigastrium. The average weight was 185 pounds (84 kg.). Weight on admission was 137 pounds (62 kg.). Nothing relevant was learned from the family or personal history.

46. This case from the medical service of the Johns Hopkins Hospital is published with the kind permission of Dr. Longcope.

Examination.—The patient was quite thin, and flabbiness of the skin gave evidence of loss of weight. The right pupil was larger than the left, the tongue was thickly coated and there was pyorrhea. The heart and lungs were negative. The abdomen was slightly scaphoid. The liver edge was not felt. There was some resistance in the epigastrium. The stomach on percussion seemed to be markedly distended.

March 4: A rice and raisin meal was given the patient in the evening, but he vomited 1,200 c.c. early the next morning. The vomitus showed rice and raisins. The guaiac test was strongly positive. The blood Wassermann reaction was negative. In a phenolsulphonephthalein test, after one hour the urine (10 c.c.) showed 10 per cent.; after the second hour, the urine (35 c.c.) showed 37.5 per cent.; total, 47.5 per cent. Roentgen-ray examination of the gastrointestinal tract showed a wedge-shaped filling defect of the pylorus and a cowhorn shaped stomach, moderately ptosed. Peristalsis of the dilated stomach was very active, but no barium sulphate passed the pylorus, which seemed to be obstructed. There was no occult blood in the stool. The blood count showed: erythrocytes, 5,840,000; hemoglobin, 115 per cent.; leukocytes, 8,400. The blood pressure was 130 systolic and 80 diastolic. The specific gravity of the urine was 1.045. It was acid, and showed a faint trace of albumin, casts and a large amount of acetone.

March 7: The patient was able to retain very little by mouth. During a gastric lavage, he complained of cramps in his arms and feet, and, about five minutes later, he had a generalized tetanic convulsion. There was no loss of consciousness, and for a period of about five minutes, while the attack lasted, he seemed to suffer a great deal. About ten minutes after the convulsion, the signs of Trousseau and Chvostek were present.

March 8: The p_H was 7.42. The plasma carbon dioxid capacity was 103 per cent. by volume. The plasma chlorids amounted to 3.67 gm. per liter. The freezing point depression was 0.524 degrees (normal, about 0.54 degrees). The protein calculated from the refractive index was 8.9 per cent. and by the Kjeldahl method, 8.4 per cent. Other measurements were: specific conductivity, 96.9 (normal about 120); plasma sugar, 143 mg. per hundred cubic centimeters; nonprotein nitrogen, 82.2 mg. per hundred cubic centimeters; calcium, 10.8 mg. per hundred cubic centimeters; potassium, 20 mg. per hundred cubic centimeters; sodium, 282 mg. per hundred cubic centimeters. The urine contained a large amount of acetone.

Operation.—March 11: Pylorectomy with posterior gastro-enterostomy was performed. An old pyloric ulcer with a dense band of connective tissue was found, causing marked obstruction. The microscopic examination of the specimen showed carcinoma. The patient's immediate convalescence from operation was smooth. He took fluid and food well, and made no complaint. Suddenly, March 19, he began to talk irrationally and incessantly; he was disoriented as to time and place, and could not recall names of physicians or nurses. Later, he had hallucinations and delusions. Temperature, pulse and respirations were normal.

March 22: Plasma carbon dioxid capacity was 58.7 per cent. by volume.

March 23: The optic disks were a little indistinct and there were several fresh hemorrhages on both sides. The blood urea nitrogen was 22.7 mg. per hundred cubic centimeters; the nonprotein nitrogen, 55.5 mg. per hundred cubic centimeters; and the plasma chlorids amounted to 6.3 gm. per liter. Urinary examination showed albumin (a trace) many casts and a few leukocytes. The blood pressure was 110 systolic and 70 diastolic.

The rest of the patient's convalescence was marked by the development of a psychosis, but in all other respects his condition was excellent, and when dismissed, April 15, he could eat freely of a liberal diet. Six months later word was received from the family physician that the patient, had died, presumably from carcinomatosis.

This was a typical case, with definite signs of clinical tetany and marked changes in the blood. The one p_H estimation made was within the normal range, but the concentration of carbon dioxid was over 100 per cent. by volume and the protein catabolites above normal. The sodium was low. A particularly interesting finding was the very low figure for the specific conductivity of the serum which was about 20 per cent. subnormal.

Case 6.—*History and Examination.*—J. McA., aged 41 years, an Irish laborer, entered the hospital, June 23, 1920, with a typical history of acute appendicitis. Physical examination showed tenderness, rigidity and a small mass in the right lower quadrant. The patient told of ten years of epigastric pain radiating through to the back, coming on two hours after meals, relieved by bending over and by ingestion of sodium bicarbonate. This was suggestive of a pyloric ulcer. The Wassermann test was negative.

Operation.—An emergency operation was performed through a MacBurney incision, which revealed a gangrenous appendix and spreading peritonitis. The upper abdomen was not explored. The diseased area was drained by two rubber tubes.

Course.—The patient had a stormy convalescence. At first, he had difficulty in voiding.

June 29: He vomited blood.

July 1: He passed a tarry stool, and vomited more blood. It was believed that an ulcer, presumably of the pylorus, had commenced bleeding. The patient's outward condition seemed satisfactory, and the wound was healing rapidly. During the first week, the urine was acid and showed a trace of albumin in two out of three examinations.

July 8: A gastric lavage was given, with a return of brown fluid resembling old blood.

July 10: Analysis of the contents after a gastric lavage showed: free hydrochloric acid, 16; total acid, 42.0; guaiac test, positive. A blood count showed: erythrocytes, 3,346,000; hemoglobin, 65 per cent.

July 21: The sinus was healed and the patient was considered to have recovered from appendicitis. A roentgen-ray and fluoroscopic examination after a barium sulphate meal revealed marked retention in the stomach, but not a complete obstruction and no duodenal deformity. With a tentative diagnosis of duodenal ulcer, the patient was transferred to the medical division for treatment, under a careful dietary regimen.

July 23: The urine was alkaline to litmus. There was a trace of albumin. Analysis of the gastric contents after a serial test meal showed: free hydrochloric acid, 4 to 40; total acid, 14 to 72; guaiac test, positive. A guaiac test on a stool was also positive. For the next three days, the patient vomited steadily, despite withdrawal of a soft diet.

July 26: A blood count showed: erythrocytes, 2,920,000; hemoglobin, 50 per cent.

July 27: The stool was guaiac positive. The urine was acid and the microscopic examination revealed albumin and casts. The plasma carbon dioxid capacity was over 100 per cent. by volume.

July 28: The plasma carbon dioxid capacity was 104 per cent. by volume. The patient's condition was poor. He vomited once during the night. He seemed lethargic and weak. Breathing was quiet. Marked muscular hyperirritability was noted. Chvostek's sign was positive on the right side. He was thought to be suffering from mild tetany. No definite carpopedal spasm was present, and Trousseau's sign was negative.

July 29: A transfusion was given. The operation which was to follow was cancelled on account of a severe transfusion reaction. The patient became much worse. Respirations were slow and irregular; the pulse rapid and of low tension. Typical facial spasm and twitchings were noted. In the afternoon, he became comatose; the respirations dropped to about seven per minute, and the mucous membranes became cyanosed. The plasma carbon dioxid capacity was 86 per cent. by volume. An infusion of 900 c.c. of saline, 500 c.c. of 10 per cent. glucose, 1 c.c. of epinephrin and 12 c.c. of tenth normal hydrochloric acid was given. After the infusion, the plasma carbon dioxid was 64 per cent. by volume. There seemed to be some slight improvement in the general condition, but consciousness did not return.

July 29: A liter infusion of 10 per cent. glucose, 10 minims of epinephrin, and 3 c.c. of tenth normal hydrochloric acid was given.

July 30: The patient died. Request for necropsy was not granted.

The diagnosis of duodenal ulcer with pyloric stenosis was almost certain in this case. The patient gave a typical history. The roentgen-ray examination and the repeated finding of blood in the stool and vomitus completed the evidence. Tetany, which finally developed, was preceded by the gradually developing signs of pyloric obstruction; vomiting was frequent, and numerous gastric lavages were given. At the time of the appearance of muscular hyperirritability, facial twitchings and Chvostek's sign, on which the diagnosis of tetany was made, the plasma carbon dioxid capacity was 104 per cent. by volume. The chlorids were not determined. At the end of the illness, when the patient was practically comatose, infusions were administered, two of which contained minute amounts of hydrochloric acid (i. e., in concentrations of 0.0008 and 0.0003 normal, respectively). Even this infinitismal amount was given with some trepidation, and, of course, the dosage was far too small to produce a therapeutic effect. Unfortunately, the urea concentration of the blood was not tested, but the presence of albumin and casts in the urine suggests that, as in the other cases, a rise in urea might have been anticipated. It is easy to say now, in retrospect, that the temporizing policy adopted was unfortunate, when a simple gastro-enterostomy under local anesthesia might have prevented the onset of tetany and saved the patient's life. The decision was made difficult at the time by the fact that these fatal symptoms of pyloric obstruction were developing during the period of convalescence from an operation for acute appendicitis with peritonitis; that

severe bleeding from the ulcer had resulted in a secondary anemia, thus lowering the patient's general resistence to any operative procedure, and that careful dietary regulation had once been successful and had brought him well along the road to recovery at an earlier period of his convalescence.

Case 7.—*History.*—E. L., aged 62 years, an American housewife, entered the hospital as a private patient, February 17, 1922, complaining chiefly of upper abdominal pain of five months' duration. She said that in the beginning the pain came on about one-half hour after meals, and usually lasted for about an hour. It was relieved by bismuth and bicarbonate of soda, and by lying down. It was aggravated by eating. On entrance, the pain had become continuous and of a dull burning character. After meals, it often became knife-like. It was then rather definitely localizable on the right side of the abdomen at the umbilical level. With the pain, there had been some distention and gaseous eructations. The patient had been vomiting lately (extent and duration not recorded) and had lost about 13 pounds (about 6 kg.) in weight. The patient had been remarkably free of symptoms referable to the cardiovascular, respiratory, genito-urinary or nervous system. Her physician reported that the symptoms of pyloric occlusion had been steadily becoming more apparent and that gastric lavage had demonstrated some retention. Analysis showed: free hydrochloric acid, 20; total acid, 38.

Examination.—The patient was a rather thin, nervous, woman, without any definite outward signs of disease or evident loss of weight. She had lost all but four teeth. The tongue was coated and the pharynx slightly injected, but there were no significant abnormalities of the head, neck or chest. In the right upper portion of the abdomen, there was a small, hard, freely movable mass about 6 by 4 cm., which descended with respirations and which was somewhat tender. A diagnosis of carcinoma of the stomach with stenosis of the pylorus was made. Blood examination showed: hemoglobin, 80 per cent.; erythrocytes, 4,700,000. The urine was acid. Tests for albumin, casts and glucose were negative. The blood pressure was 130 systolic, 80 diastolic.

Clinical Course.—February 17: Gastric lavage was performed, with a clear return only after 6 quarts (liters) had been used. The patient vomited once. For the next three days, i. e., up to the day of operation, the patient was given lavage once a day, in each case with the return of considerable material having the appearance of coffee grounds.

Operation.—February 21: Exploratory celiotomy and posterior gastro-enterostomy were performed by Dr. Whipple. Examination showed that the mass felt before operation was a large, freely movable carcinoma in the pyloric end of the stomach. There was lymphatic extension through the gastrohepatic omentum and over the surface of the pancreas. The lymph nodes of both lesser and greater curvature were involved, with typical metastatic nodules. Because of the extensive ramifications of the growth, a complete removal with pylorectomy was considered impossible. As a temporary relief for the pyloric obstruction, a posterior gastro-enterostomy was performed in the usual manner, with a short jejunal loop. The patient stood the operation well. Microscopic examination of a piece of tissue from near the head of the pancreas showed carcinoma, evidently from the stomach.

During the three days after operation, the patient received two transfusions, a glucose infusion and a saline hypodermoclysis to relieve thirst and evident

dehydration. Bleeding into the stomach, which was noticed before operation, recurred and marked gastric dilatation ensued, relieved somewhat by lavage, which was performed once or twice daily. Despite the large amounts of fluid administered, there was oliguria. The urine remained acid, and albumin and many hyaline and granular casts were noted.

February 25: Blood urea amounted to 2.47 gm. per liter, whole blood chlorids, 4.00 gm. per liter. The usual gastric lavage was given, and was repeated twice the following day.

February 27: Blood urea amounted to 3.34 gm. per liter; whole blood chlorids, 2.51 gm. per liter; total plasma carbon dioxid capacity was 107.6 per cent. by volume. The patient developed twitchings of the hands and arms, which some thought were a manifestation of uremia and others of tetany. She became confused and disoriented mentally. The tongue was brown and dry. Albumin and casts were plentiful, and once more the urine became scanty. At 8 p. m., the patient received an infusion of 1 liter of a solution made by mixing 500 c.c. of tenth normal hydrochloric acid with 500 c.c. of tenth normal sodium (physiologic sodium chlorid solution). The blood then showed: plasma carbon dioxid capacity, 86.2 per cent. by volume; whole blood chlorids, 3.31 gm. per liter. One hour after the infusion, the patient showed unmistakable carpopedal spasm. Spontaneously, she assumed the attitude pathognomonic of tetany. The nurse said that she had definitely noted the same phenomenon the previous night, but it was not observed during the day. Twitchings of the mouth and fibrillary contractions of the muscles of the extremities were almost constant.

February 28, at 1 a. m., the carpopedal spasms were no longer present, but continuous fibrillary twitchings very much like those seen in dogs with alkalosis were marked. At 9 a. m., the patient died.

This was a case of carcinoma of the stomach with pyloric obstruction in an elderly woman, with a history of vomiting. On the fifth day, after a palliative gastro-enterostomy, the blood urea and carbon dioxid were inordinately high, and the chlorids very low. The next day, tetany developed. Before operation, the kidneys were apparently not damaged (i. e., the urine showed no albumin, and no casts; the output was satisfactory; the blood pressure was normal, etc.), but after the operation, albumin and casts appeared, the urine became scanty and the blood urea was higher than normal. It is of interest to note that the urine was always acid despite the very high alkaline reserve in the blood. (No cases have been found in the literature with such a high figure for the carbon dioxid capacity.) The carbon dioxid was lowered and the chlorids were increased by an intravenous injection of 1 liter of twentieth-normal hydrochloric acid in a saline solution, with no apparent deleterious effects. The number of cubic centimeters of tenth-normal (0.365 per cent.) hydrochloric acid solution (x), which must be added to neutralize the total excess bicarbonate in the whole circulating blood is obtained approximately by the following formula: $x = 0.15$ CW, where C = the total carbon dioxid in percentage by volume over and above the normal (60 per cent. by volume), and W = the weight of the patient in pounds. The constant (0.15) was obtained on

the assumption that the total blood weight is 8 per cent. of the body weight, the specific gravity of the blood, 1.05 per cent. and the bicarbonate content of the blood 95 per cent. of the total carbon dioxid. It must be understood that the injection of hydrochloric acid intravenously cannot be recommended, as we have had insufficient experience with its use. It is suggested as a therapeutic agent from theoretical considerations. We have never seen any toxic effects in dogs. It should be combined with an equal amount of physiologic sodium chlorid solution, so that the final concentration of hydrochloric acid is one twentieth normal.

In order that the chemical findings may be more easily reviewed, the cases have been summarized and presented in the accompanying table.

In brief, the series consists of seven patients, five of whom had obstructions at the pylorus, two from ulcer and three from carcinoma. One patient had an annular carcinoma of the jejunum, and another suffered from persistent postoperative gastric dilatation, with vomiting. All of the patients had an increased plasma carbon dioxid capacity; all but one had hypochloremia, and all of those tested showed an elevation in blood urea. The three patients who showed the greatest change in bicarbonate content developed spasms. Before further discussion of these findings, it might be of interest to take up the results of a few experiments with dogs, performed recently.

RECENT EXPERIMENTAL WORK

The pylorus was occluded in a number of dogs, and arterial and venous blood was examined at intervals before and after operation. In some dogs, a duodenal bucket-tube was introduced through the wall of the stomach, so that the contents of the stomach could be washed out regularly and the secretion analyzed. In three dogs, another tube was inserted into the duodenum below the obstruction, so that a high fluid intake could be assured.[47]

It was found that after operation there was a rapid rise in the plasma bicarbonate, which in the dogs that developed tetany was not compensated for by an equivalent rise in free carbonic acid, so that a decrease in hydrogen-ion concentration resulted according to the accepted formula: $[H] = \frac{k\,[H_2CO_3]}{y\,[BHCO_3]}$. The hydrion was measured by Cullen's new colorimetric method for plasma which dispenses with dialysis.[48] Precision in preparing the standard solutions, care in collecting unobstructed blood under oil and avoiding contact with air are

47. To Dr. W. E. Swift we are indebted for the suggestion of using these two procedures simultaneously. The method proved very satisfactory.

48. Cullen, G. E.: J. Biol. Chem. **52**:501, 1922.

essential, but otherwise the technic is short and presents no difficulties. The consistency of our results gave us confidence in their accuracy. In all the dogs in which there was a marked rise in p_H, tetany developed, and there was no dog with tetany whose p_H was not definitely increased. There was then, in the true sense of the word, an alkalosis. If the

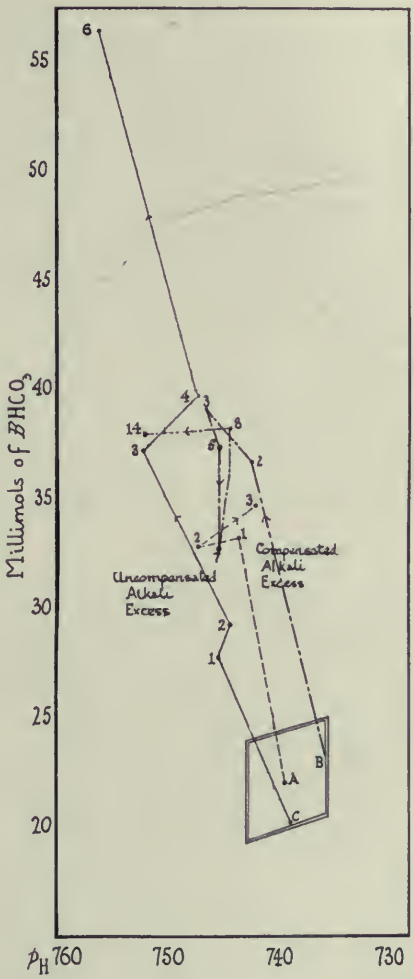

Values for $BHCO_3$ and p_H in the venous blood of three dogs who developed tetany after pyloric occlusion. The numbers refer to days after operation. The limits of normality as determined by blood analyses in seven dogs is indicated by the parallelogram.

series was not so small (seven), we might believe that an increased p_H was invariably present in gastric tetany. It might make clearer the effect of pyloric occlusion on the acid-base equilibrium if the results in

the three dogs that developed tetany were presented graphically according to the chart constructed by Van Slyke [49] to show all possible changes in the acid-base balance. The figures for combined carbon dioxid (bicarbonate) are plotted as ordinates, the p_H as abscissas. The parallelogram in the center includes all values for normal dog's blood found in the seven experiments.

It will be seen that, very soon after the operation, a compensated, and later an uncompensated, state of alkalosis developed. This change was associated with a state of tetany.

Measuring the chlorid content of the gastric secretion, it was found that, in each twenty-four hour period, more than enough chlorid was secreted, and thus lost to the body, than was necessary to account for the decrease in the concentration of this ion in the plasma.

It was also discovered that the concentration of urea and nonprotein nitrogen in the dog's blood increased after operation. The rise commenced on the second or third day (i. e., later than the change in p_H), and apparently fluctuated independently of the other factors (p_H, bicarbonate and chlorid).

In taking electrocardiograms of two dogs, it was found by chance that in both cases the electrical resistance of the skin and tissues had increased more than threefold after operation. This is of interest in connection with the decreased serum conductivity found in Case 5.

COMMENT

It is clear that experimental results corroborate clinical findings. The loss of hydrochloric acid from the body is evidently the primary cause of the hemic disorder. In lower intestinal obstruction, there is a loss of alkaline juices as well as acid, so that, although the plasma chlorid decrement is marked, there is no alkalosis. For instance, in the reported case of a chronic jejunal obstruction, there was only a slight rise in carbon dioxid, whereas the fall in chlorids was considerable. When the obstruction occurs at the pylorus, however, hydrochloric acid, for the most part, is expelled. Essentially, this means a loss of hydrogen ions and chlorid ions from the blood. Withdrawal of the former frees acid radicles (mostly $^-HCO_3$ ions) and of the latter, basic radicles (mostly Na^+ ions). The union of the freed ions ($NaHCO_3$) results in an increased value for total carbon dioxid, as obtained by the Van Slyke method in the cases described. The rise in plasma bicarbonate measured in mols, however, is not equivalent to the fall in chlorid, being usually only about one half as great. This fact is consistent with the finding that a large fraction of the chlorid in the stomach contents is not in the form of hydrochloric acid. The greater

49. Van Slyke, D. D.: J. Biol. Chem. **48**:153 (Sept.) 1921.

part of this excess chlorid is probably neutral salt derived from the saliva which has become mixed with gastric juice.

The rise in bicarbonate as explained above is evidently not compensated for by an equal rise in free carbon dioxid (carbonic acid); and the ratio carbonic acid : sodium bicarbonate is disturbed, with a result that the hydrogen-ion concentration is diminished (rise in p_H), and the blood is consequently more alkaline.

The significance of the increase in the nitrogen catabolites of the blood in pyloric occlusion is problematical. In intestinal obstruction, numerous observers [50] have found that all the nonprotein nitrogen fractions are high, but the reason for this is not certain. Chemical uremia has never been reported as an accompaniment of pyloric obstruction; but as it occurred to some degree in all our patients, and as it was also present in most of the dogs, it would seem that there was a definite association of the two. In neither dogs nor human beings was there any apparent relationship between the urea concentration and any of the other substances analyzed. The rise in urea, it seems, came on after the rise in total carbon dioxid, and in two of the human cases continued to increase after operation, despite the fact that the carbon dioxid returned to normal. As there is usually no ingestion of nitrogen in these cases, the rise in the blood has been taken to indicate either an increased protein catabolism in the tissues or a block in the portal of elimination.

Light might be thrown on the problem by comparative estimations of the blood urea and the amount excreted in the urine over a given period (MacLean index, etc.). From the fact that a rise in p_H has been found to accelerate metabolism in some lower forms of life, the hypothesis that alkalosis hastens protein catabolism in pyloric stenosis might suggest itself. This question cannot be answered at present. But in view of the fact that in our cases the ascent of urea continued for sometime after the total carbon dioxid had dropped to normal, the second theory, namely, that ingestion of alkali temporarily affects renal function, seems more acceptable. A mild nephritis has been thought to be present in intestinal obstruction since the experimental studies of McQuarrie and Whipple,[51] who found that the nitrogen and chlorid excretion was impaired and the phenolsulphonephthalein elimination was subnormal. In the clinical cases recorded, we have no estimations of

---

50. Tileston, Wilder, and Comfort, C. W.: Arch. Int. Med. **14**:620 (Oct.) 1914. Cooke, J. V.; Rodenbaugh, F. H., and Whipple, G. H.: J. Exper. Med. **23**:717 (June) 1916. Lourin, H. W.: Blood Urea Nitrogen in Acute Intestinal Obstruction, Arch. Int. Med. **27**:620 (May) 1921.

51. McQuarrie, I., and Whipple, G. H.: J. Exper. Med. **29**:397, 421 (April) 1919.

nitrogen metabolism, such as the ratio urea in blood: urea in urine. In one case, the phenolsulphonephthalein output was low (20 per cent.).

There is some evidence that ingestion of alkalis will damage the kidneys. Large amounts of alkili by mouth have been found responsible for albumin in the urine. Albumin and casts were frequently found in our human as well as in our animal cases. This coincides with the experience of Mayo-Robson, who calls particular attention to this finding in gastric tetany. It is possible, therefore, that a rise in bicarbonate (or p_H) causes a temporary functional nephropathy, and that subsequently, as in nephritis, the concentration of the nitrogen waste products in the blood rises.

It was thought at first that, with a more alkaline blood, less ammonia would be formed and excreted in the urine, and that the nitrogen thereby released would increase the urea factor. The rise of the urea nitrogen and the nonprotein nitrogen proportionately, however, were too great to be accounted for simply by a diminution in ammonia production. Nevertheless, we would confidently expect to find the urea : ammonia ratio in the urine increased. As has already been mentioned, a number of observers have found that, after overventilation, the urinary ammonia decreased markedly, but unfortunately these tests have not been made in cases of gastric tetany.

It is to be regretted that a more complete study of the urine was not made in our cases. The usual routine observations record the fact that it was almost invariably acid to litmus despite the increased alkalinity of the blood. Two tests on the urine of dogs with alkalosis showed that it was acid to phenol red and alkaline to methyl red; i. e., the p_H was about 5.8 to 6.4. Palmer and Van Slyke [52] noted in bicarbonate feeding experiments that, in disease, the urine did not become more alkaline than blood (p_H 7.4) until a higher plasma carbon dioxid had been reached than that of normal controls. In one diabetic, the carbon dioxid rose to 104.4 per cent. by volume before the urine became alkaline. This is difficult to explain, but is at least in agreement with our findings. Marshall [53] has recently found that it is practically impossible to raise the reaction of urine above p_H 8 by the ingestion of alkali.

Having settled on the important changes in the blood, namely, a rise in p_H, and total carbon dioxid, a fall in chlorids and an increased concentration of the nitrogeneous waste products, it would be satisfactory to be able to explain a causative relationship between one or more of these factors and the state of tetany. Unfortunately, this cannot be done with certainty.

---

52. Palmer and Van Slyke: Footenote 21.
53. Marshall, E. K., Jr.: J. Biol. Chem. **51**:3 (March) 1922.

The possible effect of chemical uremia on irritability cannot be entirely disregarded. Because of its association with terminal coma, the accumulation of waste products in the blood has often been regarded as depressing to the nervous system. It is striking that in all our cases, human and animal, there was invariably an increased concentration of urea in the blood when tetany developed. Also a large number of the reported cases of tetany following bicarbonate therapy occurred in patients with damaged kidneys. In Harrop's case [54] the woman was suffering from mercuric chlorid poisoning and developed tetany, with carbon dioxid around 80 per cent. by volume. Morse [55] reported a case of long-standing pyelitis in a child with a high blood urea who developed tetany after sodium bicarbonate therapy, even though the plasma carbon dioxid was constantly below normal.

As our results add nothing beyond what has already been proved experimentally bearing on the possible relationship between tetany and the anion or cation balance, no contribution can be made to this aspect of the question. Our clinical and experimental data direct attention to the acid-base disturbance as the primary causative factor in gastric tetany. Fundamental experiments have shown that the addition of alkali heightens irritability,[56] possibly by increasing the permeability of the nerve sheath; [57] the injection of basic carbonates and phosphates cause tetany, and in two clinical forms of tetany (that which follows overbreathing, and so-called gastric tetany), an increased p_H is found. With this evidence, it seems reasonable to conclude that preponderance of base may cause nerve hyperirritability. Whether this action is direct or indirect, i. e., acting through an influence exerted upon the sodium: calcium ratio, has not been certainly proved.

It has been pointed out that inferences based upon the work of Freudenberg and György to the effect that the shift in basic radicles from ionized salt compounds to less dissociated protein molecules, with rise in p_H, involves mostly the calcium ions, and consequently the sodium: calcium ratio in the plasma is increased, are probably erroneous. Explanations for the effect of p_H on the sodium: calcium ratio which involve peculiar properties of the calcium ion seem more likely, but cannot be appropriately discussed at present.

DIAGNOSIS AND TREATMENT

With a patient who gives a history of persistent vomiting, particularly in large amounts, it is well to determine the plasma carbon

54. Harrop, G. A., Jr.: Footnote 22, first reference.
55. Morse, J. L.: New York M. J. **112**:965 (Dec. 18) 1920.
56. McClendon, J. F.: J. Biol. Chem. **28**:135 (Dec.) 1916.
57. Osterhout, W. J. V.: Science **45**:97, 1917.

dioxid content or capacity. If it is much increased, i. e., over 80 per cent. by volume, without a history of alkali therapy, it is an indication that there is an obstruction, organic or functional, near the region of the pylorus and that the physicochemical balance of the blood is in jeopardy. If the carbon dioxid continues to rise, tetany can be predicted (in all our cases, the carbon dioxid was over 100 per cent. by volume before tetany ensued). But when sodium bicarbonate is rapidly injected intravenously, tetany may develop when the carbon dioxid is between 80 and 90 per cent. by volume; and at that point, death will be imminent unless relief measures are instituted. Mayo-Robson once wrote that "it has almost been made a criterion of the disease that it should end fatally."

In a case of tetany, a differential diagnosis must be made, especially between: 1. Hypoparathyroidism, which includes infantile tetany (often associated with rickets) and postoperative tetany (the occasional sequel of a thyroidectomy). This type is characterized by a low calcium content of the blood, and also, we are informed, by the presence of methyl guanidin in the blood and urine. 2. Tetany of hyperpnea, a condition which is marked by a high p_H but a low carbon dioxid content. This type, which seems frequently to be a manifestation of hysteria, has been clearly defined by Goldman,[58] and should be kept in mind in nervous patients. 3. Gastric tetany, which follows occlusion, at or near the pylorus and is characterized by a high p_H, a high carbon dioxid, a low chlorid and probably a high urea concentration. 4. Tetany following the intake of alkalis or sodium salts. In this instance, the diagnosis is made on the history. The blood, depending on the salt used, may show a high p_H and carbon dioxid content and a low calcium content.[59] In other words, a diagnosis can be made on purely chemical evidence. In fact, some cases can be diagnosed only on this basis. In one case reported from the Presbyterian Hospital,[60] the patient developed tetany in the course of an attack of sprue. It was found that the carbon dioxid content was normal, but the calcium content was definitely subnormal. Another case of sprue that had tetany as a complication had both an alkalosis and a low calcium content. At present, such forms can be classified chemically only. It is singular to us that tetany does not develop more frequently in cases of hypertrophic pyloric stenosis of children. Reports of two cases were found, but in both instances, soda had been used in the feedings.[61]

---

58. Goldman, Alfred: Clinical Tetany by Forced Respiration, J. A. M. A. **78**:1193 (April 22) 1922.

59. Tisdall, F. F.: Footnote 11. Binger, C.: Footnote 19, second reference.

60. Barach, A. L., and Murray, H. A., Jr.: Tetany in a Case of Sprue, J. A. M. A. **74**:786 (March 20) 1920.

61. Townsend, C. W.: Boston M. & S. J. **150**:154, 1904. Rice, C. V.: J. Oklahoma M. A. **14**:238 (Sept.) 1921.

For a complete diagnosis, then, the p_H and carbon dioxid content of the unobstructed venous (or preferably the arterial) plasma, and the chlorid and the calcium concentrations should be estimated. The blood urea is of interest. These findings suggest that the existing textbook classifications of tetany, which are based for the most part on its association with other clinical conditions, are confusing and might with benefit be revised.

The treatment of gastric tetany is operative, except in cases of pyloric spasm (which might theoretically cause tetany, but of which no proven case has been found in the literature). The indication for operation, of course, is the obstruction, which must be relieved; and the method chosen should be adapted to the pathology in the given case, i. e., gastro-enterostomy, pyloroplasty, pylorectomy, etc. As a supporting measure, administration of fluids is essential. Patients are frequently dehydrated, as little water passes through the pylorus in severe cases, and the absorption from the gastric mucosa is minimal. Granting that the loss of hydrochloric acid is the cause of the condition, rational therapy would seem to consist in the replacement of this acid, preferably by intravenous injections. Large amounts of acid can be given to dogs with safety; and 500 c.c. of tenth-normal hydrochloric acid solution plus 500 c.c. of 0.15 normal sodium chlorid solution was administered to one of our patients without deleterious effects. Although from this evidence we are inclined to think that a dilute solution of acid in saline solution can be injected with benefit, our experience has been too limited to create assurance. MacCallum states that infusions of normal saline were efficacious. The addition of a 0.5 per cent. solution of calcium chlorid would theoretically be of advantage, but the hemolysing power of these solutions will have to be tested before their administration is adopted as a therapeutic procedure. The amount of hydrochloric acid necessary to neutralize the excess bicarbonate can be roughly estimated as outlined in the discussion of Case 7. Calcium chlorid must not be injected subcutaneously, since it is irritating to the tissues.

SUMMARY

1. Five cases of pyloric stenosis are reviewed. Two other cases with somewhat comparable findings are included; one patient had postoperative gastric dilatation; the other, carcinoma of the jejunum with stenosis.

2. With stenosis of the pylorus, hydrochloric acid cannot pass into the intestines and be reabsorbed. It is expelled by vomiting or washed out by gastric lavage. The result is a disturbance of the acid-base balance in the blood and tissues.

3. The blood findings in our patients were similar to those in dogs after experimental pyloric occlusion, namely, an increased carbon dioxid

and urea and a diminished chlorid content. The most abnormal values found were: carbon dioxid, 107 per cent. by volume; chlorid, 2.5 gm. per liter, and urea 334 mg. per hundred cubic centimeters.

4. In the dog experiments, it was found that the blood was more alkaline than normal.

5. There is almost certainly a relationship between the recorded blood changes and the condition of tetany that may develop in severe cases.

6. It is considered that the cases presented, the experiments summarized and the literature cited make the assumption that nerve irritability is increased by a fall in the hydrion concentration of the blood or by a rise in the sodium: calcium ratio highly probable. The latter may be brought about by adding dissociable sodium compounds or precipitating calcium. Whether the hydrogen ion is active because of its effect on the cation ratio is still an open question.

7. The increased electrical resistance found in two dogs and the lowered serum conductivity in one patient are very suggestive and needs investigation.

8. The treatment of gastric tetany is operative. As far as we know, it is always the result of obstruction of the pylorus, due to gross pathologic changes. There are other forms of tetany that are not associated with pathologic gastric conditions, from which it must be differentiated. This can usually be done by suitable blood analyses.

CONCLUSION

Pyloric stenosis, particularly when attended by persistent vomiting, is followed by a rise in the total carbon dioxid and a fall in the chlorid content of the blood plasma, and later, it seems, by an increase in the nitrogen catabolites.

There appears to be a causative relationship between these findings and nerve hyperirritability.

TRAUMATIC LESIONS OF THE INTESTINE CAUSED BY NONPENETRATING BLUNT FORCE

B. M. VANCE, M.D.

Assistant Medical Examiner, New York; Instructor in the Department of Surgery, College of Physicians and Surgeons, Columbia University

NEW YORK

The observation of Aristotle [1] that the intestine of deer is so fragile that a slight blow will cause it to rupture without injuring the skin is probably the first record that we have of injuries of the intestine following an abdominal contusion.

However, it was not until the seventeenth century, when the making of postmortem dissections first became widely practiced, that traumatic intestinal perforation was given its due recognition as an important surgical condition. Bonetus [2] describes the case of a huntsman who was dashed violently against a tree by a stag. Later, necropsy disclosed five circular holes in the ileum and cecum, presumably the result of violence sustained by the intestine when distended by fluid.

Morgagni [3] mentions several cases of ruptured intestine following the kick of a horse, or a blow from a stick. He believes the predisposing cause of the rupture is the fragility of the intestinal wall and its distention by fluid at the time of the casualty. His observations on the clinical course are quite shrewd, and he warns especially against too great optimism in those cases in which the symptoms of abdominal distress are slow in making their appearance.

Many cases of intestinal rupture have been reported since the days of Morgagni, and the modern literature on the subject is now extensive. This consideration and the fact that the case reports are not equally valuable make a detailed review of the literature difficult. For that reason only a general discussion of the subject will be attempted here.

The different types of violence that cause intestinal perforation without necessarily penetrating the abdominal wall may be divided into (1) direct violence, (2) indirect violence and (3) muscular action. The last two types are not common and may be considered more advantageously later. The great majority of cases are the the result of direct violence, which may be further subdivided into generalized and local trauma.

---

1. Aristole, cited by Morgagni (Epistola **54**:140-142).
2. Bonet, Théophile: Medicina septentrionalis collatitia **1**:644, 1686.
3. Morgagni: Epistola **54**:140-142, 1761.

Generalized trauma results from such casualties as a highway accident in which the wheel of an automobile passes over a man's body, a fall from a height, violent crushing of the trunk between two colliding objects or sudden burial beneath a falling mass of earth. In all such accidents, while only the intestine may be injured, it is more likely that rupture of other viscera or fractured bones will be associated with it, and these lesions may govern the clinical picture. Tearing of the mesentery is perhaps the most important accompanying injury.

The impression is given that in cases of generalized trauma the trunk as a whole is affected by the violence and that the intestine favored by its mobility and position is only occasionally involved.

It is quite different in those cases in which local trauma is the cause of the trouble. Here the force that is exerted on the anterior abdominal wall has a limited area of impact, and, if it is applied at the proper point, the intestine will rupture rather readily. Unlike the solid abdominal viscera, the intestine lacks the protection of the ribs or spine, and is thus more vulnerable. Local trauma may result, above all from the kick of a horse, the kick of a man, treading on the body, a blow from the fist, a blow with a stick, the impact of a thrown missile, running or falling against a sharp corner and the like. The kick of a horse causes the largest number by far. Hertle [4] and Tschistosserdoff [5] assert that one third of all published cases are due to this casualty alone.

The small intestine is the portion most often injured, probably because it is most exposed. The jejunum and ileum are about equally involved, and the most frequently affected sites are the points of natural fixation, namely the duodenal junction and the cecal junction. Coils of small intestine enclosed in a hernial sac are also vulnerable, and in a large proportion of cases there is a hernia of some sort. The duodenum and large intestine are not so often injured, perhaps because they are better protected. In a total of 221 cases collected from London hospitals, Berry [6] records 177 injuries of the small intestine, twenty-nine of the duodenum, and fifteen of the large intestine. Other statistics give practically identical results.

More than 90 per cent. of the cases occur in males, and most of these are between the ages of 20 and 50 years, the period of man's greatest activity, and the time when he is most exposed to injury. Women, children and the aged form a minority.

Weakness of the abdominal parietes is very often present. In many instances, the lower part of the trunk is thin or the abdominal muscles are lax and inefficient, so that they are not able to protect the abdominal contents from the applied force.

---

4. Hertle, J.: Beitr. z. klin. Chir. **53**:257, 1907.
5. Tschistosserdoff: Beitr. z. klin. Chir. **79**:70, 1912.
6. Berry, J.: Brit. M. J. **2**:643 (Oct. 22) 1921.

Today three different modes of rupture of the intestine by blunt force are recognized. Moty,[7] in 1890, was the first to introduce this classification. He says: (1) The intestine may be crushed; (2) the intestine may be torn, and (3) the intestine may burst because of pressure within its lumen.

1. CRUSHING OR CONTUSION OF THE INTESTINE

Contusion is caused by a violent compression of the intestine between the anterior abdominal wall, which is pushed in by the force, and an opposing bony structure, such as the vertebral column or the pelvis. The force is usually directed perpendicular to the anterior abdominal wall and is necessarily considerable in amount, whether it is generalized or local trauma. The coil of intestine is either empty or contains only air, and in many cases it shows a fairly accurate impression of the contusing surface. Thus, in an accident in which the patient has been run over, there may be a complete annular contusion of the intestine about the width of the wheel. A characteristic lesion is sometimes seen in very violent local trauma, such as the kick of a horse. The coil of intestine may show two perforations on its anterior and posterior walls at the same level and in direct line with the applied force, so that the manner in which the injury was produced is scarcely doubtful. These lesions are almost always surrounded by a marked extravasation of blood in the intestinal wall, and sometimes they are accompanied by contusions of the anterior abdominal wall and the posterior retroperitoneal tissues at the level of the intestinal injury. Perforation of the intestine may occur at the time of the violence or may be secondary to an ulcerative necrosis following a loss of vitality in the contused area.[8]

The cases reported below are illustrative of perforation of the intestine by contusion.

REPORT OF CASES

CASE 1.—A white man, aged 28 years, was run over by an automobile truck, and died in a few minutes.

Necropsy (Eight hours later): The body, that of a strongly built man, showed no signs of external injury except a few abrasions on the anterior abdominal wall. The abdomen was filled with a half gallon of fluid blood, the result of huge tears of the mesenteries of the small intestine, sigmoid and the greater omentum and a rupture of the liver substance. In addition, the jejunum in the region of the mesenteric tear showed an annual contusion (Fig. 1). This case illustrates a true crushing injury of the intestine, in which the jejunum was compressed between the wheel of the truck and the vertebral column, while traction on the intestine in the direction of its cross axis produced the mesenteric tear. Death was due to the abdominal hemorrhage, while the jejunal lesion was merely a by-product of the generalized violence.

---

7. Moty, Rev. de chir. **10**:878, 1890.
8. Lexter: Berl. klin. Wchnschr. **48-49**:1233, 1901.

Case 2.—A white man, aged 38 years, was in one of the hospitals for two weeks with symptoms of delirium tremens following the excessive use of alcohol. He was then transferred to another hospital where his struggles became so violent that he was placed under restraint. Among other things, a broad strap was buckled over his abdomen. Shortly after this, he complained of severe abdominal pain and died several hours later. The abdominal pain and the other sypmtoms that he exhibited were attributed to his nervous condition, and no operation was attempted.

Fig. 1 (Case 1).—Contusion of small intestine and tearing of mesentery.

Necropsy: The body was that of a thin, poorly nourished man, showing no signs of external injury. Section revealed a peritoneum full of fecal material and gas, a necrotic peritonitis and a gaseous, gangrenous phlegmon of the retroperitoneal tissues in the right lumbar fossa. There were two longitudinal tears, 3 inches in length, in the peritoneal reflexions on either side of the ascending colon through which infective material evidently reached the abdomen. The cause of the infection and of the right lumbar cellulitis was a large triangular perforation of the anterior wall of the duodenum, 1¼ inches in diameter, and situated directly over the vertebral column, at a distance of 2 inches from the duodenojejunal junction. On the posterior wall of the duodenum was a partial perforation, directly behind the lesion on the anterior wall, and of almost the same size and shape. The only difference was that the mucous membrane and muscle alone were involved on the posterior wall, and

the external connective tissue layer was intact. Surrounding these injuries the intestinal wall was extensively bruised (Fig. 2). The manner in which the injuries were produced is not known certainly, but from the anatomic peculiarities and the history, it is reasonable to suppose that the restraining strap compressed the intestine against the vertebral column during the violent struggling.

Case 3.—A white woman, aged 48 years, fell against the edge of a table, Sept. 11, 1922, striking her abdomen. She complained of abdominal pain at the time; but the injury was not thought to be serious until alarming symptoms of abdominal distress developed, September 14. She was sent to a hospital and

Fig. 2 (Case 2).—Crushing injury of duodenum with complete perforation of anterior wall and partial perforation of posterior wall.

operated on the same day. A large amount of pus and fecal material was found in the abdominal cavity, and a small perforation of the ileum was located and sutured. She died several hours after the operation, of general peritonitis.

Necropsy: The body was that of a rather obese middle-aged woman, with a flabby anterior abdominal wall. There was an extravasation of blood, covering an area 1½ inches in diameter, in the subperitoneal tissue just above the umbilicus. The perforation was located in the middle of the ileum and sutured. When the stitches were removed it appeared to be a small hole, ovoid in shape, three-eighths by one-fourth inch, lying crosswise in the intestine. It was located opposite the insertion of the mesentery, and the intestine around the perforation was extensively bruised (Fig. 3). The lesion was almost certainly a contusion; but it is impossible to say whether the perforation occurred at the time of the injury or was a secondary erosion following a subsequent loss of vitality in the injured intestinal wall.

2. TEARING OF THE INTESTINE

The intestine and its mesentery may be torn in those cases in which traction is made on the intestine, in some way, during the course of the violence. If the pull is exerted in the cross axis of the intestine and against the root of the mesentery, the mesentery will be torn first and the intestine may or may not suffer. Figure 1 is a good illustration

Fig. 3 (Case 3).—Contusion of ileum with perforation.

of this lesion. However, if the traction pulls on the intestine in the direction of its long axis, then the bowel itself will tear at the start, and the mesentery may be involved only when the tear is complete. It is evident that the kind of force that exerts traction must be a reasonably violent one, and that it must act on the abdomen at a tan-

gent. It must be capable of compressing the abdominal wall enough to secure a purchase on the intestinal coil, and its further action must exert a strong pull on the intestine. A highway accident in which the automobile wheel grinds the trunk is a splendid example of this variety of generalized violence, while the violent kick of a horse which strikes the abdomen obliquely illustrates tangential local trauma.

Tearing is most likely to occur at points where the intestine is naturally fixed, such as the duodenojejunal junction or the ileocolic junction, or where it is unnaturally fixed, as by adhesions. The reason for this is fairly obvious. Most tears are inflicted by direct violence, but a few cases have been described in which the cause was indirect violence; that is, the force was not applied directly to the intestine itself. A person may fall from a height, landing heavily on his feet or buttocks, with the trunk in an upright position, in such a way that the sudden stop causes the small intestine, by its very weight, to jerk violently against the duodenojejunal junction, and so cause tearing at this point.[9]

In the following cases, the intestine was torn by direct violence.

Case 4.—A white man, aged 39, while crossing a street was struck by a street car. The exact modus operandi of the accident could not be learned. He was immediately taken to the hospital in an ambulance, after the ambulance surgeon had given him a dose of morphin. Examination when the patient entered the ward revealed a few bruises and cuts on the left side of the face and a compound fracture of the left tibia and fibula. No abdominal signs and symptoms were present at that time, and his condition seemed to be fairly good on the whole. Seventeen hours later, he was decidedly worse. Upper abdominal pain and rigidity, shallow rapid respirations and profuse sweating had developed. The extremities were cold. A laparotomy was then performed, which disclosed the abdominal cavity full of intestinal contents, and a transverse tear of the jejunum. As the patient's condition was poor, a quick jejunostomy was performed by stitching the torn portion of the intestine to the edges of a surgical stab wound of the upper abdomen. He died a few hours later, thirty hours after the accident.

Necropsy: The body was that of a well developed man in whom the different injuries and operations already described were visible externally. In the abdomen there was an almost complete tear of the jejunum, placed 18 inches from the duodeno-jejunal junction and involving about three fourths of the circumference of the intestine. There was much contusion surrounding the edges of this wound. Neither the mesentery nor any other abdominal organ showed signs of being injured. Death was due to the generalized suppurative peritonitis which followed the leakage of intestinal contents (Fig. 4).

Case 5.—A white man, aged 57, was run over by a motor truck in the street. He entered the hospital unconscious and very evidently alcoholic. He regained consciousness about seven hours afterward, but had no recollection of the circumstances of the casualty. His condition at that time did not appear to be especially serious, so operation was not considered. He died about two hours later.

---

9. John, K.: Viertelsjahrschr. f. gericht. Med. **61-62**:276, 1921.

Necropsy: The body was that of a middle-aged man, short and slight of frame. There were a few lacerations about the face. The ribs on the left side from the third to the ninth were fractured, and the apex of the lower lobe of the left lung was slightly torn, seemingly a lesion of no great importance. The abdominal wall showed no signs of injury, but the abdominal cavity contained more than a quart of dark red fluid blood. The hemorrhage was due to a number

Fig. 4 (Case 4).—Partial tear of jejunum.

of intestinal and mesenteric injuries: a 4 inch hole in the middle of the greater omentum; a partial tear across the duodenum, 3 inches from the jejunum, and finally a complete tear of the jejunum, 3 feet from its upper end. The latter was transverse, involving not only the intestine but also its mesentery, into which it extended for a distance of 3 inches. There was considerable contusion in the adjacent tissues. The circular muscle of the torn ends of the

intestine were markedly contracted and gripped the mucous membrane so tightly that there was no leakage of intestinal contents into the abdominal cavity (Fig. 5).

Case 6.—A white man, aged 29, was struck by a motor truck. He was taken to a hospital, where he apparently showed signs that justified a laparotomy. This was performed soon after admission and a tear in the jejunum was sutured. He died, however, of peritonitis several hours afterward.

Necropsy: The body was that of a strongly built man, with numerous abrasions over the shoulders and hips, a simple fracture of the left tibia and fibula and a contusion on the anterior abdominal wall. The jejunum had been torn across, 1½ feet from the duodenum, and had been resected. There was quite a

Fig. 5 (Case 5).—Complete tear of jejunum, with tear of mesentery.

large contusion in the mesentery, just below this tear in the intestine. None of the abdominal viscera were injured. Death was due to a generalized suppurative peritonitis.

3. EXPLOSIVE OR BURSTING RUPTURES OF THE INTESTINE DUE TO A SUDDEN RISE OF PRESSURE IN THE LUMEN OF THE INTESTINE

The mechanism of a bursting rupture of the intestine is not so well understood as is the production of the lesions resulting from crushing and tearing, and so, much has been written about how the intestine can burst and how often it actually does burst.

All agree that the pressure inside the lumen of the intestine must increase beyond the limit of elasticity of the intestinal wall before the

bursting can occur, but there is much disagreement as to the manner in which this increase in intestinal pressure can be produced. The older writers, Bonetus and Morgagni, beyond noting the fact that an intestine filled with fluid is more liable to rupture than one that is empty or that merely contains air, offered no explanation of the phenomenon. Moty [7] was practically the first to suggest a plausible modus operandi.

He asserts that the violence in some way compresses a coil of intestine against the posterior abdominal wall so that its contents cannot escape, and consequently makes a rise of the intra-intestinal pressure, in that particular segment, inevitable. Explosion will occur at the moment, the bursting force inside the coil overcoming the resistance of the intestinal wall. Sauerbruch [10] also endorses this view, and elaborates upon it, describing several ways in which the violence can imprison the contents of a coil and cause it to explode.

As Haim [11] pointed out, the theory of Moty and Sauerbruch will explain the course of events in all instances in which the violence directly compresses the intestine, but it fails to satisfy in those cases caused by indirect violence or muscular action, where direct action on the intestine is obviously impossible.

An example of explosion by indirect violence is seen when a person falls on his abdomen on a flat surface. Rupture by muscular action occurs when a man strains in lifting a heavy object, such as a barrel.[12] In both types of casualty, according to Haim,[11] the abdominal cavity is suddenly contracted, which necessarily causes a general rise of intra-intestinal pressure in an intestine distended with fluid. One or many explosions are liable to occur at the weak points of the intestinal wall, especially in or near hernial sacs, which are quite vulnerable because the sac coverings offer inefficient resistance to the sudden rise of internal pressure. Haim's theory depends on the assumption that the only air or fluid containing space in the normal abdomen is inside the hollow viscera, and that adjacent peritoneal layers are so closely approximated that there is no appreciable space present under normal conditions.

This theory of Haim is probably the correct one and is certainly more logical than that of Bunge,[13] who asserts that an air space is present outside the intestine and that the rise of intra-abdominal pressure occurs here. According to him, bursting of the intestine will take place only at weak places in the abdominal wall, most notably at the different hernial openings, at the moment when the increased abdominal pressure attempts to force the intestine through such lacunae. Bunge's theory is

10. Sauerbruch: Mitt. a. d. Grenzgeb. d. Med. u. Chir. **12**: 1903.
11. Haim, E.: Arch. f. klin. Chir. **93**:685, 1910.
12. Grasmann, M.: Deutsch. Ztschr. f. Chir. **91**:41, 1908.
13. Bunge: Beitr. z. klin. Chir. **47**:771, 1905.

not taken very seriously at the present time because it is vague and is based on an erroneous conception of intra-abdominal conditions.

Haim also mentions another mechanism of explosive rupture which he calls "bursting by contre-coup." He describes a man, aged 47, who was kicked by a horse. At operation two ruptures of the ileum some distance apart were found. One of the lesions was attributed to the direct action of the hoof, while the other was considered to be due to force transmitted to the column of fluid inside the intestine, so that the intestinal wall at the other end of the column received enough of the transmitted pressure to burst under the strain. The theory is ingenious but difficult either to prove or to disprove.

Other forms of explosive ruptures have been described which are rather uncommon and which will only be mentioned. Bursting of the large intestine in new-born infants has been found in rare instances and has been attributed to violent expulsive uterine contractions acting on an intestine full of meconium.[14] Occasionally, as the result of a practical joke, the sigmoid and large intestine in men have been ruptured as a result of the introduction of compressed air into the anal aperture with a compressed air hose.[15] It is probable that this occurs more often than has been reported.

Bursting ruptures of the intestine generally present a fairly characteristic lesion. According to Schwarz,[16] the injury starts as a transverse fissure on the side of the intestine opposite the mesenteric insertion. The explosive force tears the weak longitudinal muscle across and merely separates adjacent strands of the stronger circular layer. Later, by muscular contraction of the longitudinal layer, the transverse fissure is converted into an ovoid longitudinal hole through which shreds of mucous membrane project into the peritoneal cavity. Contusion of the intestinal wall is much less pronounced than in cases of crushing and tearing, and the force required to burst the intestine need not be a particularly violent one, especially when the wall is diseased or the seat of an ulcerative process, such as typhoid or tuberculosis.

Cases of traumatic explosive rupture of the intestine are reported below.

Case 7.—A man, aged 50, April 5, was struck in the left groin by a brick. The next day he entered a hospital, acutely ill, with deep abdominal distress. His condition was so bad that he was not operated on, and he died on April 8.

Necropsy: A broad contusion in the left groin and an incomplete, indirect inguinal hernial sac just under the contusion were revealed, occupying the canal but not penetrating the scrotum. The sac was empty. There was a purulent

14. Von Sury: Viertelsjahrschr. f. Gericht. Mer. **3**:91, 1912.

15. Buchbinder, J. R.: Pneumatic Rupture of the Intestine, J. A. M. A. **76**: 518 (Feb. 19) 1921.

16. Schwarz, A.: Deutsch. Ztschr. f. Chir. **95**:101, 1908.

plastic peritonitis, matting the coils of small intestine. The abdominal cavity contained about a quart and a half of green foul-smelling fluid. In the jejunum, 3½ feet from the duodenal junction, were two longitudinal ovoid holes, from 3 to 4 inches apart. They measured one-half by one-fourth inch and three-eights by one-fourth inch, respectively. One lay behind the other, and both were situated away from the mesenteric attachment. There was slight contusion around the edges of these perforations. In the intestine near this area were small transverse tears of the mucous membrane, about one-eighth inch in length. These lesions had all the characteristics of bursting ruptures (Fig. 6).

Case 8.—A girl, aged 6½ years, fell six stories out of a window. At the hospital it was noted that there were contusions of both thighs, anteriorly, and a fractured lower condyle of the right humerus. Symptoms apparently pointed to an abdominal condition, so a laparotomy was performed. Two perforations of the ileum were found and sutured. She died eighteen hours after the accident.

Fig. 6 (Case 7).—Explosive ruptures of the jejunum.

Necropsy: It was found that death had been due to a general suppurative peritonitis resulting from two perforations in the middle of the ileum, about 1½ feet apart. The mesentery was not involved. There were probably multiple bursting ruptures due to a fall flat on the abdomen.

Case 9.—A boy, aged 2 years, fell two stories down a fire escape and was taken to a hospital in an unconscious condition. For some reason he was not operated on until the next day, twenty hours after the injury. The abdominal cavity was full of a foul-smelling bloody fluid; but the source could not be located. He died an hour and a half after the operation.

Necropsy: Foul-smelling dark fluid blood was revealed in the peritoneal cavity and a gaseous phlegmonous cellulitis of the right lumbar region which had broken through the peritoneum in the region of the cecum. The origin of this process was a hole, three-eighths inch in diameter, in the most dependent portion of the duodenum, just to the right of the vertebral column. Its edges were

contused and ragged. No other injury was present, and there was no contusion of the anterior abdominal wall. The injury was probably a bursting rupture; but the mechanism of its production is not entirely clear.

Case 10.—A man, aged 40, entered a lodging house one night about 10 o'clock. At the time, the clerk at the desk noticed nothing peculiar about either his appearance or his behavior. He was found dead in bed the next morning, and a necropsy was performed to determine the cause of his death.

Necropsy: The body was that of a rather poorly developed, medium-sized man, with a distended tympanitic abdomen and a large direct inguinal hernia in the left scrotum, which was empty at the time of the postmortem. There was no sign of contusion on the abdominal wall or in the scrotum. The intestines were large, distended with an immense quantity of gas and fluid and were matted together by big masses of purulent fibrin. Two feet of the lower ileum was bound in a mass and lay near the hernial opening. Here the intestinal wall was swollen, edematous and friable as if its circulation had been damaged. In this coil, about 3 feet from the ileocecal valve, was a circular perforation, situated opposite the mesenteric attachment. Its edges were sharp and showed a thin rim of ecchymosis (Fig. 7). This perforation had been well walled off by adhesions, so that there was no gross leakage of intestinal contents. There was no sign of an ulcerative process in the intestine, which, aside from the



Fig. 7 (Case 10).—Bursting rupture of the ileum.

points already mentioned, was normal. No other injury could be found elsewhere in the body.

The lesion was doubtless a bursting rupture, probably produced by such a slight force that it could be scarcely classified as trauma. What that force was or how long the peritonitis had been present is unknown; but it is a justifiable assumption that the hernial sac played an important part in producing the perforation. This case resembles some of those described by Grasmann.[12]

Case 11.—A man, aged 50, was known to have been drinking to excess for some days prior to his death. The day before he died he complained to his landlady of feeling very ill. He was found dead in bed the following morning.

Necropsy: There was no evidence of injury to the abdominal parietes: but the lower 2 feet of the ileum was contained in a direct hernial sac on the right side, which was intact and easily reduced. There was, however, an ovoid perforation of the middle of the small intestine situated opposite the mesenteric attachment and showing a slight ecchymosis about its edges. The intestine was not ulcerated and was natural, aside from the marked generalized purulent peritonitis which was derived from the perforation (Fig. 8).

This case is like Case 10, so that the same remarks will apply to both.

Case 12.—A Chinaman, aged 38, who had been an inmate of a hospital for the insane for sometime, suffered from restlessness and delusions. In other respects, he was not especially ill and was not violent enough to be placed under restraint. One morning, however, on getting out of bed, he suddenly fell over dead.

Necropsy: The body was that of a slender, emaciated man, with a general suppurative peritonitis and a perforation in the ileum, situated 5 feet from the ileocolic junction. The hole was longitudinal, measuring 1½ by three-eighths inch. It was situated opposite the mesenteric attachment. The edges were slightly contused. Three quarters of an inch to one side was a contusion in the submucous layer of the intestine, of exactly the same size and shape as the perforation. The intestine was normal otherwise. There was also a small contusion in the abdominal wall around the umbilicus. No other injury was present, nor was there a hernial sac.

Fig. 8 (Case 11).——Bursting rupture of the small intestine.

The lesion was evidently traumatic, but the nature of the violence could not be ascertained, nor was it known just when it happened. The case is interesting in that the peritonitis must have existed for some time before death. The injury to the intestine is possibly an explosive one, though there is a possibility that it was the result of a contusion.

COMMENT

These twelve cases are among those that came to necropsy in the routine work of the medical examiner's office of New York. They were all fatal and the number is too small to permit the deduction of any statistical conclusions. They present, however, certain facts, worthy of emphasis, regarding the anatomic and clinical peculiarities of intestinal injuries caused by blunt force.

Above all, they show that the intestine may be crushed, torn or burst by pressure from within, and that in many instances the mechanism of the violence may be recognized both from the clinical history and from the anatomic findings at operation or necropsy. In other cases, however, the result cannot be read so plainly, and conclusions cannot be drawn with the same degree of certainty. It is impossible very often to determine the exact nature of the casualty; that is, just how the force was applied and what the condition of the intestine was at the time. For this reason, the assertions in the literature to the effect that crushing injuries are most common and that bursting injuries are exceedingly rare are unnecessarily dogmatic and even misleading. Beyond doubt, all three types of trauma do occur—crushing, tearing and bursting—but it is difficult to determine with certainty their relative frequency.

In any event, the manner in which the lesion was produced is, in many instances, a matter of only theoretical interest to the surgeon. The chief consideration is that a very violent trauma or a very slight one may perforate the intestine, a fact that must have an important effect in directing the subsequent clinical course of the patient.

The twelve cases of the series reported herewith show a wide variation in the medical history. The patient in Case 1 died almost immediately from abdominal hemorrhage.

In Cases 4 and 5, the patients gave indications of having been subjected to extreme violence, but because they did not present abdominal symptoms at the beginning the intestinal injury was not diagnosed in Case 5 at all, and it was not recognized in Case 4 until too late. It is probable that the alcohol and morphin in Cases 4 and 5 had a pronounced analgesic effect which obscured the signs of peritoneal irritation and thus rendered the diagnosis difficult.

In Cases 3 and 7 the patients had received only moderate local violence and were not driven to seek medical aid until the peritonitis had become well established. The primary symptoms immediately following the casualty were evidently too slight to arouse alarm.

Cases 2, 10, 11 and 12 are significant in that the patients had evidently sustained an injury to the intestine of which they themselves were not aware. Another patient (Case 11) had been drinking heavily, and the alcohol no doubt kept the signs of peritonitis in the background. In Cases 2 and 12 the patients were mentally unsound, and even though they were under clinical observation their injuries were not recognized. All this shows that sudden death may occur from an unsuspected infection in the abdominal cavity and that the term "walking peritonitis" has just as real a meaning as "walking pneumonia" or "walking typhoid."

Case 9 is interesting in that although the boy was operated on the intestinal lesion was not discovered. This was explained by the fact that

the injury was located in the duodenum, and so, therefore, it was well hidden in the retroperitoneal tissues. Berry [6] mentions similar instances.

Of the entire number, two patients (Cases 6 and 8) were operated on soon after the injury, but the damage done was too great to permit of recovery.

In our series, death from intra-abdominal hemorrhage occurred whenever associated mesenteric and visceral injuries were present. The majority of patients died of peritonitis, which is usual. In two instances, Cases 2 and 9, in which the duodenum was perforated, the infection was a retroperitoneal cellulitis. Hertle [4] mentions similar infections caused by traumatic ruptures of the duodenum and cecum.

It is thus apparent that the treatment of these injuries is very unsatisfactory. The mortality is high. Almost all patients not operated on die, and even those that are operated on are not the best of risks. Berry cites only twenty-six recoveries in 114 operations in London hospitals and Tschistosserdoff only eight in forty-seven. The longer the operation is delayed after the injury, the less the chance of recovery, so that prompt recognition of the condition is very important. It has already been noted that a very slight blunt force is sufficient to cause an intestinal injury and that various circumstances may arise which will delay the appearance of the characteristic clinical signs. In all casualties, therefore, in which there is a possibility that violence has been sustained by the abdominal parietes, the presence of a ruptured intestine should be suspected from the very start and the case treated accordingly.

It is the opinion of the staff of the first surgical division, Bellevue Hospital, that an exploratory laparotomy should be performed in every case of blunt trauma in which it is not possible to exclude the existence of an injury to the hollow abdominal viscera (personal communication of Dr. R. S. Hooker). The only deterrent to an operation under these circumstances would be the fact that the patient is so nearly moribund or in such shock that the operation in itself would be fatal. Certainly, absence of the signs of abdominal distress, shortly after the injury, would in no way contraindicate surgical interference, for, as has been seen, such lack does not guarantee the absence of a dangerous abdominal lesion. Of course, this policy of early operation would not be successful in every instance, but its advantages outweigh any possible disadvantage. Most of all, it would give a fighting chance to those patients with injuries of the intestine which do not make their presence felt at the start and which are often amenable to surgical intervention in the early stages, but which surely would lead to death if the operation is delayed.

A STUDY OF THE VIABILITY OF BONE AFTER REMOVAL FROM THE BODY*

S. L. HAAS, M.D.

SAN FRANCISCO

As a primary working principle, it is necessary to have a definite conception of the difference between death of the organism and death of its component parts. The life of the higher animals is dependent on an intact respiratory, circulatory and central nervous system, and, in consequence of the permanent destruction of one of these systems, there necessarily results the death of the individual. The various organs and tissues of the body are more or less dependent on the successful functioning of these systems for an adequate supply of nourishment, and, as soon as there is a disturbance in their working, with a diminution of the essential elements, there is a beginning degeneration of the organ or atrophy of the tissue. They are, however, able to withstand, for a limited period, the complete severance of their nutritive sources so that the ultimate death or degeneration of the organs and tissues of the body does not immediately follow the death of the organism, because the various cells are able to subsist for a limited period on such nutritive substances as they already contain or by which they are surrounded. There are various secondary factors that exert an influence on the degenerative processes; such as the sensitiveness of the individual cells, the amount of the stored products, and the cell's ability to utilize them, the liability to invasion by destructive bacteria and the subjectiveness to autolytic digestive processes.

Closely allied to this ability of the organs and tissues of the body to survive after the death of the individual is their ability to withstand death after removal from the organism. On account of this property of survival of tissues after excision from the host, it is possible to transplant them from one part of the body to another or to a different individual.

It has been shown, particularly by Carrel,[1] that by placing tissues in various fluids at different temperatures the death point can be postponed. Thus, between — 1 C. and — 2 C., the cadaveric disintegration is practically inhibited, and Carrel has successfully transplanted sections of arteries after the elapse of twenty-four days from the time of their removal. Furthermore, he has transplanted other tissues, such as dog's cartilage and periosteum, which had been kept in cold storage from

---

* From the Surgical Pathological Laboratory of Stanford University School of Medicine.

1. Carrel, Alexis: The Preservation of Tissues and Its Applications in Surgery, J. A. M. A. **59**:523 (Aug. 17) 1912.

twenty-four to twenty-eight hours into dogs and found that the cartilage remained alive and that the periosteum produced bone. Unfortunately, the details and the microscopic changes of these important observations are not given in the article.

In addition to the preservation of tissue in this condition of latent life, Carrel has been able to preserve tissues in a condition of active life outside the organism, by utilizing the method devised by Harrison.[2] Carrel preserved fragments of hypophysis and periosteum extirpated from dogs in normal plasma at a temperature of 38 C. He found that, after a few days, fragments of hypophysis were living and that continuous or tubular layers of epithelial-like cells had grown from the edges through the culture medium. Around small pieces of periosteum which were cultivated in hanging drops, a new tissue had developed; but the growth stopped at the end of ten days. Transplants of the periosteum that were preserved in active life were made after one, two and three days. The periosteal flaps were removed from the plasma, washed in Ringer's solution, and afterward placed under the skin of the chest of a dog. Control pieces that had been preserved in Ringer's solution were also transplanted, and, after the lapse of a month, it was found that more bone was produced by the flaps preserved in plasma than by the controls.

Recently, Ebeling[3] has reported the cultivation of a strain of fibroblast obtained from the heart of a chick embryo, Jan. 11, 1912, for a period of ten years, and representing the one thousand eight hundred and sixtieth generation of these connective tissue cells. This has been made possible by the use of an improved culture medium of embryonic tissue juices, chemically altered to conform to a definite ionic concentration. In view of this long propagation of cells, he ventures the opinion that, under proper nutritive conditions, certain cells are practically immortal.

The recent work of Lewis and McCoy[4] on the survival of various tissues after death of the organism offers another means of determining the death point of cells. Their criteria for life are the presence within the cell of certain granules and vacuoles that have an affinity for 0.5 per cent. solution of neutral red and a homogenous nucleus without the trace of a nuclear membrane. When the cell dies, there is a loss of color from the granules and vacuoles, a diffuse pink staining of the cytoplasm and nucleus, and a sharp distinct nuclear membrane and change in texture of the cytoplasm and nucleus. They discuss the

---

2. Harrison, R. G.: Observations on the Living Developing Nerve Fibres, Proc. Soc. Exper. Biol. and Med. **4**:140, 1907.

3. Ebeling, A. H.: A Ten Year Old Strain of Fibroblasts, J. Exper. Med. **35**:755 (June) 1922.

4. Lewis, W. H., and McCoy, C. C.: The Survival of Cells After the Death of the Organism, Bull. Johns Hopkins Hosp. **33**:284 (Aug.) 1922.

factors influencing the death of different cells of the body at varying periods after death as due to difference in chemical and physical constitution of the cells, in the rate of metabolism, in the amount of oxygen, in the various salts and foodstuffs used and in the chemical constitution of the waste products. Their results show that there is a longer survival period at low temperatures than at high temperatures and in tissues remote from the effects of intestinal bacteria. Each cell acts differently according to its environment, and when the animal dies, the environment is changed and the period of survival depends on how each cell is naturally fitted to live there. Thus, it was found that cartilage cells survived for a long period, up to two hundred and forty hours, and it is known that cartilage is rather far removed from the capillaries and would not respond so quickly to the cutting off of the blood supply as cells that have a higher rate of metabolism. On the other hand, brain cells were found to survive but one hour, and skeletal muscle, which developed no granules, died almost as soon as removed from the body.

Dobrowolskaja [5] took small pieces of bone from mice, kittens and rabbits, placed them in a hemogenous plasma and then incubated them in hanging drops of distilled water. He used compact bone, periosteum and cancellous bone, and described the outgrowth of tissue elements from the original material. He says that the embryonic tissue on the slides reveals cell proliferation without tissue formation. His drawings show an outgrowth of structureless dendritic masses that bear no resemblance to osseous tissue.

Fisher [6] reports the first successful cultivation of a pure strain of cartilage cells in vitro. The original tissue was obtained from the sclera of the posterior hemisphere of the bulbus oculi of the chick embryo, which has a pars cartilaginea sclerae. He obtained an increase in growth and reproduction of the cellular structure of the primary cartilage.

In view of the investigations just considered it does not seem unreasonable to expect that a tissue such as bone would possess latent and active life properties after removal from the body. Bone, unlike any other tissue of the body, is composed of a firm inorganic mineral base and ossein, in which are interspersed the active living bone corpuscles and haversian system of cells and blood vessels, and it is invested both externally and internally with active osteoblastic cellular elements which are capable of forming bone. Because of this peculiar complex structure, it is difficult to devise a satisfactory means of determining the survival of its cells. A consideration of the methods already mentioned

---

5. Dobrowolskaja, N. A.: On the Regeneration of Bone and Its Relation to the Cultivation of Bone Tissue, Brit. J. Surg. **4**:332 (Oct.) 1916.

6. Fisher, Albert: A Pure Stain of Cartilage Cells in Vitro, J. Exper. Med. **36**:379 (Oct.) 1922.

to determine which is the most suitable for this study may be taken up under the three following headings: (1) the study of cellular changes; (2) the cultivation on artificial mediums after exposure to see whether there is any power of growth; (3) transplantation of the tissue after exposure and investigation at a later period to determine whether there are signs of proliferation.

1. *Study of Cellular Changes.*—The microscopic study of the ordinary nuclear appearances is not exact because it is impossible to determine from the structure of the nucleus whether the cell is alive or dead. The method used by Lewis and McCoy is more definite; but it is unsatisfactory because of the difficulty of making spreads of a hard tissue like bone.

2. *Cultivation of Tissue on Artificial Mediums.*—This method may be suitable for a simple tissue, but is not applicable for one of such firm and complex structure as bone. The mere outgrowths of structureless processes as obtained by Dobrowolskaja without the reduplication of tissue, bearing at least some resemblance to bone, could not be accepted as proof of retained vitality of the osteoblastic elements that had been exposed after removal from the organism.

3. *The Transplantation of Tissue.*—In order to be certain that the cells of bone have survived, one must be able to demonstrate an active and definite reproduction of osseous tissue after such exposure. In the study of bone after the usual method of transplantation, it is fairly easy to recognize definite regenerative changes; but, in case a period had elapsed before transplantation, the vitality of the cells may be so reduced that such responses may be lacking. However, even should such proliferative changes be demonstrable, they may not be accepted by those investigators that maintain that they are not indicative of inherent life of transplanted bone. In a previous article, I [7] showed that there is the same tendency toward healing of a fracture in a transplanted bone as there is toward healing of a similar lesion in a bone in its normal position. It was, therefore, decided to utilize this physiologic response of the healing of a fracture in a bone transplant as a test of the activity of osteogenetic cells after removal from the body. Accordingly, after the bone was removed from the animal and fractured, a certain time was allowed to elapse before its transplantation to another location in the same animal. If then there should be any tendency to healing or signs of proliferation at the site of such a fracture, it is believed that this growth could be considered as absolute proof of the survival of the osteoblastic cells of the exposed bone. With this object in view, the following twenty experiments were performed on ten dogs.

---

7. Haas, S. L.: Spontaneous Healing Inherent in Transplanted Bone, J. Bone and Joint Surg. **4**:209 (April) 1922.

METHOD

Under ether anesthesia and with aseptic technic, two entire metacarpal bones were removed from the animal's foot. One bone, after being fractured in the center, was placed in a sterile bottle and kept at room temperature, while the other bone, after being broken, was placed in a bottle of physiologic sodium chlorid solution and kept at a temperature of 39 C. At the end of a certain period, the fragments were united with catgut, and the two different sets of bones were buried in the muscles on opposite sides of the back of the same animal. No attempt was made at this time to determine the best method for the prolongation of cell life of bone, which, in accordance with the investigations on other tissues, would be at lower temperatures and in a medium of embryonic tissue extracts; but an effort was made to determine the vitality of the cells after exposure to such conditions as exist in the operating room.

1. EXPOSURE TO AIR

EXPERIMENT 1.—From Dog 35, a grown animal, the fourth metacarpal bone was removed, fractured at the center, and the fragments placed in a sterile bottle at room temperature for two and one-half hours. The bones were then tied together with catgut and transplanted to the muscles on the right side of the back. The animal was killed at the end of forty-four days.

Gross Findings.—There was no evidence of union between the two fragments. There were a few osseous spicules about the ends.

Microscopic Findings.—There was a small osseous outgrowth on one of the segments, that stained fairly well, and, in general, had the appearance of new bone. The remainder of the bone was made up of stainless nuclei and was undergoing degeneration.

EXPERIMENT 2.—From Dog 25, a grown animal, the third left metacarpal bone was removed, fractured at the center and placed in a sterile bottle for three and one-half hours. The fragments were then tied together and transplanted to the muscles on the right side of the back. The animal was killed at the end of fifty-eight days.

Gross Findings.—There was no evidence of union between the fragments, which had undergone considerable absorption.

Microscopic Findings.—There were definite signs of proliferation about the fractured ends. It appeared that an attempt at bridging the gap between the two ends was being made. The remainder of the bone showed well stained nuclei about the periosteal and endosteal surfaces, as well as about the haversian canals, just as in certain stages after the usual transplantation of bone.

EXPERIMENT 3.—From Dog 23, a young animal, the fourth right metacarpal bone was removed, fractured at the center, and the two segments placed in a sterile bottle for five hours. The fragments were then bound together with catgut and buried in the muscles on the right side of the back. The animal died at the end of six days. There was infection present.

Gross Findings.—The bones healed in position, but it was too early for any signs of union.

Experiment 4.—From Dog 27, a full grown animal, the fourth right metacarpal bone was removed, fractured at the center and placed in a sterile bottle for six hours. The fragments were then bound together and transplanted to the muscles on the right side of the back. The animal died at the end of four days.

Gross Findings.—There was good healing of the wound, and the bones showed no abnormal changes.

Microscopic Findings.—The bone appeared dead. The nuclei stained poorly and appeared degenerated.

Experiment 5.—From Dog 29 the third right metacarpal bone was removed, fractured at the center and placed in a sterile bottle. At the end of six hours, the bones were tied together with catgut and placed in the muscles on the left side of the spine in the same animal. The dog developed convulsions on the fourteenth day and had to be killed.

Gross Findings.—There was good alinement of the fragments but no evidence of union.

Microscopic Findings.—There was no evidence of proliferation about the end or tendency to callus formation. There was a very limited proliferation along the cortex, but no signs about the endosteum. The nuclei of the cortex were degenerated.

Experiment 6.—From Dog 24, a full grown animal, the third right metacarpal bone was removed and fractured in the center, and the two fragments bound together with catgut, after which the bone was placed in a sterile bottle for seven hours. The bone was then transplanted to the muscles on the left side of the back. The animal was killed after sixty-one days.

Gross Findings.—There was no sign of union. The fragments had undergone some absorption. The roentgenogram revealed an entire absence of callus at the ends.

Microscopic Findings.—There was no evidence of callus nor signs of proliferation about the ends. Some of the nuclei along the outer surface of the cortex appeared normal.

Experiment 7.—From Dog 28, an old animal; the fourth right metacarpal bone was removed, and, after being fractured, was placed in a sterile bottle for nineteen hours. The segments were then bound together with catgut and placed in the muscles of the back on the right side of the spine. The animal died on the tenth day.

Gross Findings.—The bone was surrounded by hemorrhagic, partially necrotic material. There was no sign of union.

Microscopic Findings.—There was no evidence of proliferation about the ends. The bone appeared degenerated except toward the articular surfaces, where the nuclei took the normal stain.

Experiment 8.—From Dog 31, an old animal, the fourth metacarpal bone was removed from the right foot, and, after being fractured in the center, it was placed in a sterile bottle for nineteen hours. The fragments were then bound together with catgut and transplanted to the muscles on the left side of the back. The animal was killed at the end of fifty-three days.

Gross Findings.—The fragments were in good apposition, and there was weak union between the bones. The roentgenogram (Fig. 1) showed the frag-

ments together, but one could not determine definitely whether there was union. On close study, there appeared to be some proliferation from the ends. There was considerable absorption of the bone.

Microscopic Findings.—There was considerable new osseous tissue at the site of the fracture. A complete osseous bridge between the fragments could not be demonstrated on section; but a study of a number of slides indicated that it did take place. This new bone was composed of well-stained nuclei, while the adjoining old bone was, for the greater part, made up of stainless degenerated nuclei (Fig. 2). There was a layer of new bone on the endosteal and periosteal surface of the cortex.

Experiment 9.—From Dog 26, a young and growing animal, the fourth right metacarpal bone was removed, fractured and placed in a sterile bottle for

Fig. 1 (Exper. 8).—Appearance of the metacarpal bone at the end of fifty-one days, showing evidence of new bone formation, which was verified on microscopic study of a section through the site of fracture. The bone had previously been kept in air for nineteen hours.

twenty-one hours. The fragments were united and placed in the muscles on the right side of the back. The animal died of infection on the second day.

Gross Findings.—The bone showed no change.

Microscopic Findings.—The nuclei were practically all stainless. There were no signs of activity of the osseous cells.

Experiment 10.—From Dog 30, a full grown animal, the fourth right metacarpal bone was removed, fractured at the center and placed in a sterile bottle for twenty-four hours. The fragments were then bound together with catgut and transplanted to the muscles on the right side of the back. The animal was killed at the end of fifty-nine days.

Gross Findings.—There was no evidence of union. The fragments appeared to be dead, and there was no evidence of proliferation.

Microscopic Findings.—The nuclei of the bone were stainless. The ends of the bone were blunt and showed no signs of an attempt at callus formation. The general appearance was one of absorption and degeneration. The extreme inactivity was unlike that of any of the other experiments of similar duration.

II. IN PHYSIOLOGIC SODIUM CHLORID SOLUTION

Experiment 11.—From Dog 35 the third right metacarpal bone was removed, fractured in the center, and the fragments placed in a bottle containing physiologic sodium chlorid solution at a temperature of 39 C. At the end of two and a half hours, the fragments were tied together with catgut and transplanted to the muscles on the left side of the back in the same animal, from which they were removed. The animal was killed at the end of forty-four days.

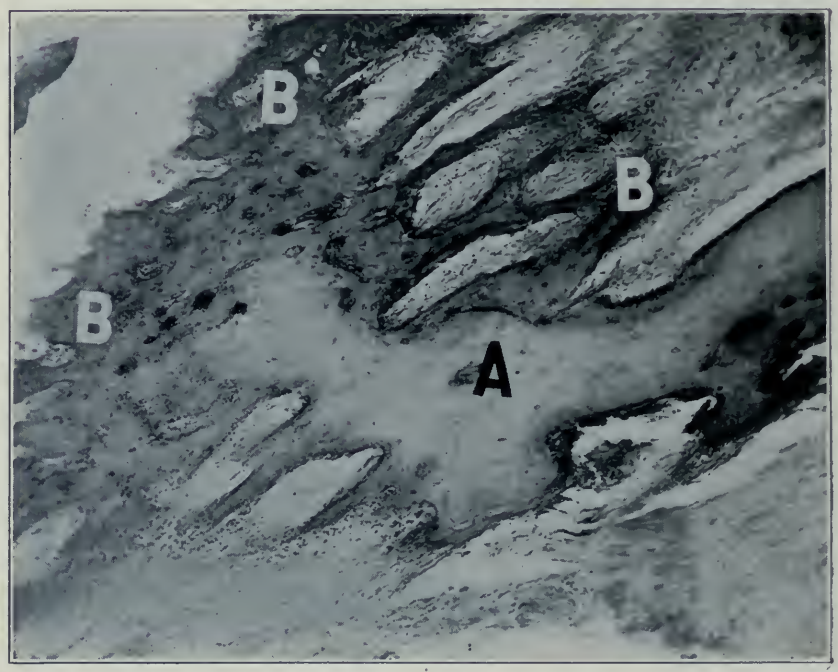

Fig. 2 (Exper. 18).—Callus at site of fracture of a bone that was fractured and allowed to remain in physiologic sodium chlorid solution for nineteen hours before being transplanted to the muscles of the back of the same animal. A similar picture was found at the site of fracture in Experiment 8, in which the bones were placed in a sterile bottle for nineteen hours before transplantation. This new bone was formed by the cells that had survived the period of exposure, and the response was exactly like that which would occur in the healing of a fracture under normal conditions: *A,* degenerated old bone; *B,* new osteoid tissue.

Gross Findings.—There was no evidence of union between the two fragments. The ends of the bone were rather smooth and showed no outgrowths at any place.

Microscopic Findings.—There was a fairly normal, thin layer of bone near the end of the fragment and along the surfaces that were approximated to the other segment. The remainder of the bone contained stainless nuclei and appeared to be dead. The inherent tendency and functional influence for union seemed to exert some regenerative force, even though union had not been completed.

Experiment 12.—From Dog 25 the fourth left metacarpal bone was removed, fractured in the middle and placed in physiologic sodium chlorid solution for three and a half hours. The pieces were then sutured together and placed in the muscles on the right side of the back of the same dog, where they were allowed to remain fifty-eight days.

Gross Findings.—The fragments were in good alinement. There was marked atrophy of the bone. A few nodules were present at the site of fracture.

Microscopic Findings.—There was no evidence of callus or new bone at the site of fracture. There was some well-stained bone about the periosteal surface, endosteal surface and the haversian canals.

Experiment 13.—From Dog 23 the third right metacarpal bone was removed, fractured, and placed in physiologic sodium chlorid solution for five hours. It was then placed in the muscles on the left side of the back. The animal died at the end of six days.

Gross Findings.—The bones were in apposition, but were not adherent to the surrounding tissues. The period of time was too short for osseous changes.

Experiment 14.—From Dog 27 the third right metacarpal, after being fractured, was placed in physiologic sodium chlorid solution for six hours, and then transplanted to the muscles on the left side of the back, and left there for four days.

Gross Findings.—There was good healing of the wound, but no signs of union.

Microscopic Findings.—There was no evidence of early callus. The cortical bone was composed of stainable nuclei, and, at places along the periosteal surfaces, the osteoblast appeared to be proliferating.

Experiment 15.—From Dog 29 the fourth right metacarpal bone was removed, fractured at the center, and then placed in physiologic sodium chlorid solution at 39 C. The bone was removed at the end of six hours; the fragments were tied together with catgut and then transplanted to the muscles on the right side of the spine, where they were left for fourteen days.

Gross Findings.—The ends of the fragments were in apposition, but there was no sign of union.

Microscopic Findings.—It was surprising that there was an entire lack of any proliferative changes in the region of the fracture. It was possible that the infection that was present had some influence. Aside from the staining of some of the nuclei on the surface of the bone, there was an entire absence of living cells.

Experiment 16.—From Dog 24 the fourth right metacarpal bone was removed, fractured in the center and, after being tied together with catgut, was placed in physiologic sodium chlorid solution for seven hours. It was then removed and transplanted to the muscles of the right side of the back of the same animal. The animal was killed at the end of sixty-one days.

Gross Findings.—There was a definite union between the two fragments. The bone was smaller than at the time of operation. The roentgenogram showed the bones in perfect alinement. The osteoid callus appeared as a faint shadow, mostly of the endosteal type.

Microscopic Findings.—There was a definite osseous connection between the two fragments. This callus was composed of nuclei of fairly normal shape and of normal staining properties (Figs. 3 and 4). The original cortex on either side of the connecting bridge had lost its nuclear stain and was undergoing absorption. It appeared that the new bone was more resistant to absorption than the original bone, which was possibly due to its structure or to the fact that it was functioning as a connecting band.

Experiment 17.—From Dog 28 the third right metacarpal bone was removed, fractured and placed in physiologic sodium chlorid solution for nineteen hours.



Fig. 3 (Exper. 16).—Appearance of a section of the metacarpal bone, showing the survival of the osteoblastic cells after exposure of seven hours in physiologic sodium chlorid solution and their ability to produce callus after transplantation to muscle for a period of sixty-one days: *B-B,* site of union, showing the well stained normal nuclei; *A-A,* original bone on either side, showing that the nuclei of the old bone fail to stain; objective, ⅔; ocular, 2 inches.

The fragments were then bound together with catgut and transplanted to the muscles on the left side of the back. The animal died in ten days.

Gross Findings.—There were no signs of union.

Microscopic Findings.—There were no signs of proliferation about the ends of the fractured bone. There was some periosteal proliferation; but the greater part of the bone was made up of stainless nuclei.

Experiment 18.—From Dog 31-18 the third right metacarpal bone was removed and fractured at the center, and the fragments were placed in a bottle of

physiologic sodium chlorid solution for nineteen hours at 39 C. The fragments were then tied together with catgut and placed in the muscles on the right side of the back and left for fifty-three days.

Gross Findings.—The fragments had become displaced, and there was no evidence of union. The bone had undergone considerable absorption.

Microscopic Findings.—There was a marked outgrowth of new bone from the ends of the fragment, which was similar to that which occurred in Experiment 8 (Fig. 2). This new bone was just like the callus that is formed at the site of a fracture in its normal position. The greater part of the original bone adjoining this new bone was dead, as shown by the stainless nuclei. In this experiment, even though there was a nonunion, there was the definite tendency toward the formation of callus, and an effort was made to bridge the gap.

Fig. 4 (Exper. 16).—Higher magnification of area within the square indicated in Figure 3, showing the normal osseous structure of the uniting callus. It cannot be determined whether the osteoblastic cells are forming bone or absorbing it on the surface. Probably the latter process is predominant at this time. The nuclei of the bone away from the site of union are stainless; objective, ⅔; ocular, 2 inches.

Experiment 19.—Dog 26 was operated on, the third left metacarpal bone being fractured, placed in physiologic sodium chlorid solution for nineteen hours and then transplanted to the muscles of the left side of the back and left for two days.

Gross Findings.—The wound was infected.

Microscopic Findings.—The nuclei were practically all stainless.

Experiment 20.—From Dog 30 the third right metacarpal bone was removed, fractured in the center and placed in a bottle of physiologic sodium chlorid solution at 39 C. for twenty-four hours. The fragments were then tied together with catgut and placed in the muscles of the left side of the back of the same animal, remaining for fifty-nine days.

Gross Findings.—The bones were in good alinement. There was absolutely no evidence of union. There was practically no connection between the bones and the surrounding muscle, such as usually takes place in this type of experiment; but they had acted just as do foreign bodies.

Microscopic Findings.—The bone contained stainless nuclei throughout and appeared dead. The ends of the fractured segments were blunt and irregular. There was no sign of proliferation at any place. The periosteum appeared to have been loosened from the bone which lay within, just like a sequestrum. It was difficult to explain the entire failure of activity in this experiment, when, in other experiments that were performed in exactly the same manner, definite signs of growth took place from the bones, and, in one instance, there was union of the fragments.

SUMMARY

In ten of the twenty experiments, the period of observation was less than fifteen days, owing to the death of the animal, making these experiments unsatisfactory so far as drawing conclusions as to the ultimate results is concerned. The entire loss of nuclear staining is not unlike that which takes place in the early stages after bone transplantation. The high mortality of 50 per cent. as compared with the mortality of 10 per cent. for the usual transplantation experiments leads one to believe that there was something associated with the character of the experiment that was responsible for the bad results. Naturally, there is a greater chance for infection when the bone is allowed to remain outside the body for a considerable period before transplantation. Furthermore, it is possible, that, in the presence of at least partially degenerated bone, the virulence of the bacteria is increased. It might be that the changed proteid of the exposed bone exerted a toxic action after it was replaced in the animal.

The accompanying tables give in brief the findings in the five experiments in which the bone was placed in a sterile bottle.

In Experiment 8, a weak union occurred in a fractured bone that remained in a sterile bottle for nineteen hours before being transplanted into the muscles of the back of the same animal. As there was no contact with any bone, this uniting callus must have been formed by the surviving cells of the exposed bone. It is an interesting fact that the nuclei of the callus retain their staining properties, while those of the adjoining bone are stainless. This persistence of the life of these cells might be due to the fact that the cells at the site of the fracture are functioning in forming the union, while those beyond are inactive, thereby undergoing a more rapid degeneration.

In Experiments 1 and 2, although there was no union, a small amount of new bone had formed about the ends as if there had been an attempt to form a connection.

In Experiment 6, there was practically no sign of proliferation, while in Experiment 10, the bone was dead.

The formation of callus under such conditions as existed in these experiments is considered an exacting test of the living condition of the cells of exposed bone. Callus has been demonstrated not only in two experiments; but, in another, a union has taken place after nineteen hours, which leaves no doubt as to the vitality of the cells of bone that has been exposed to air for nineteen hours.

TABLE 1.—*Exposure of Bone to the Air*

Number of Experiment	Number of Animal	Duration of Exposure, Hours	Duration of Experiment, Days	Result
1	35	2½	44	Slight outgrowth of new bone at end of fragment
2	25	3½	58	New bone at the ends of fragments; normal staining bone about periosteum and endosteum
6	24	7	61	Some nuclei on outer surface are stainable
8	31	19	53	Weak union between the fragments; normal osteoid callus
10	30	24	59	Bone dead

TABLE 2.—*Exposure of Bone to Physiologic Sodium Chlorid Solution*

Number of Experiment	Number of Animal	Duration of Exposure, Hours	Duration of Experiment, Days	Result
11	35	2½	44	Live appearing bone near approximated surfaces of the fragments; no union
12	25	3½	58	No union; well stained bone on periosteal and endosteal surfaces
16	24	7	61	Firm union
18	31	19	53	Nonunion; considerable new osteoid callus about the ends
20	30	24	59	Bone dead

Table 2 gives the findings in brief of the five experiments in which the bone was placed in physiologic sodium chlorid solution at a temperature of 39 C.

In Experiment 16, a firm union was formed in a bone that was fractured and kept in physiologic sodium chlorid solution for seven hours before being transplanted to the muscles of the back. In Experiment 18, in which the bone was kept in physiologic sodium chlorid solution for nineteen hours, a considerable amount of callus was formed about the ends of the bone. This callus was similar to the osteoid callus that forms about the site of a fracture in its normal position and under normal conditions. In Experiments 11 and 12,

there was histologic evidence of live bone, although no callus was formed at the fracture line. In Experiment 20, the bone appeared dead.

These results add further evidence to substantiate the fact that the cells of bone will live after the removal of the bone from the host. The cells not only live but are capable of forming callus, even after being kept nineteen hours in physiologic sodium chlorid solution.

Collectively, in the two groups, there were two experiments in which a union occurred, three in which callus was formed about the fractured ends, and two in which there were signs of living bone on histologic examination. There did not seem to be any superiority in the use of physiologic sodium chlorid solution at 39 C. over those bones that were placed in a sterile bottle at room temperature. The longest period at which signs of living bone were demonstrated was nineteen hours for both methods. Undoubtedly, the preservation in cold storage would be more efficient in prolonging the survival period of the cells.

It is difficult to explain the disparity in the results, especially as to the small amount of callus in the case of the bones that were exposed for a short time. A larger series in which attention is directed to the age of the animal, condition of the animal, the method of holding the fragments in apposition, food and variation in physiologic processes may help to solve this problem.

CONCLUSIONS

1. The osteoblastic cells of bone will survive an exposure period of nineteen hours in air at room temperature.

2. There is sufficient active retained vitality in the exposed cells to form callus, and, in some instances, union of a fractured bone after its transplantation into a muscle of the same animal, independent of any other source of osseous elements.

3. The demonstration of the survival of the cells of bone after removal from the host adds uncontroverted evidence to prove that the osteoblastic cells of a bone graft play an independent active rôle in the processes of regeneration.

DESMOID TUMORS: A REPORT OF THIRTY-ONE CASES *

RALPH W. NICHOLS, M.D.
Fellow in Surgery, Mayo Foundation
ROCHESTER, MINN.

Mueller,[1] in 1838, first suggested the term "desmoid tumor," but it was not accepted generally until Sänger[2] published four papers (1880 to 1885) describing tumors arising from the round and the broad ligaments, the periosteum of the pelvic bones and from the abdominal walls. Ledderhose,[3] in 1890, collected from the literature 100 cases of such tumors in the abdominal walls. Pfeiffer,[4] in 1904, published a comprehensive review of the subject and reported forty cases from his own clinic and 260 from the literature. These with Ledderhose's 100 cases made a total of 400. Pfeiffer limited the use of the term "desmoid" to fibromas arising in the musculo-aponeurotic structures of the abdominal walls, and this interpretation has been generally accepted.

Powers,[5] in 1905, reported three cases of his own and abstracted the work of Pfeiffer in detail. Stone,[6] in 1908, reported a case of his own, also five cases from Johns Hopkins Hospital and seven from the literature. Balfour,[7] in 1916, reported two cases from the Mayo Clinic

---

* From the Section on Surgical Pathology.

1. Mueller: Ueber den feineren Bau und die Formen der krankhaften Geschwülste, Berlin, 1838.

2. Sänger, M.: Ueber Primäre desmoide Geschwülste der Ligamenta lata, Arch. f. Gynäk. **16**:258-285, 1880; Weitere Beiträge zur Lehre von den primären desmoiden Geschwülsten der Gebämutterbänder, besonders der Ligamenta rotunda, ibid. **21**:279-308, 1883; Ueber desmoide Geschwülste der Bauchwand und deren Operation mit Resection des Peritoneum parietale, ibid. **24**: 1-37, 1884; Zwei weitere Fälle von desmoiden Geschwülsten der Bauchwand, Zentralbl. f. Gynäk. **9**:321, 1885.

3. Ledderhose, G.: Desmoide Geschwülste der Bauchdecken, Deutsch. Chir. **45**:52-77, 1890.

4. Pfeiffer, C.: Die Desmoide der Bauchdecken und ihre Prognose, Beitr. z. klin. Chir. **44**:334-401, 1904.

5. Powers, C. A.: Fibroid Growths of the Abdominal Wall, J. A. M. A. **45**:676-680 (Sept. 2) 1905.

6. Stone, H. B.: Desmoid Tumors of the Abdominal Wall, Ann. Surg. **48**: 175-185, 1908.

7. Balfour, D. C.: Desmoid Tumors: Report of Two Cases in Which the Tumor Occurred in Operative Scars, Railway Surg. J. **22**:434-436, 1916.

occurring in postoperative scars. Levy,[8] in 1919, prepared an unpublished thesis on the subject at Yale, in which he reviewed the literature extensively and reported two cases seen in his service at the New Haven Hospital.

From 1906 to 1922 thirty-one cases of tumors, classified pathologically as desmoids, were observed at the Mayo Clinic. Specimens from these tumors, with one exception, have been examined, and photographs of the gross specimens, photomicrographs and abstracts of case histories are herewith presented.

The twenty-five tumors occurring in the muscles of the abdominal walls conform to the classification of Pfeiffer. The remaining six have

Fig. 1 (Case 1).—Specimen from the upper third of the right rectus muscle.

been very carefully studied. They present similar clinical histories, and the clinical and pathologic findings are such that one feels perfectly justified in classifying them as desmoids.

Nineteen of the thirty-one patients (61 per cent.) were females; and of these, thirteen (68 per cent.) had been pregnant, and twelve (68 per cent.) were under 35 years of age. Ten of the twelve male patients (83 per cent.) were more than 35 years of age. In four of the cases the tumor was found in postoperative scars. In four other cases abdominal operations had been performed, but the tumors were not associated with the scars. Tumor was noticed before operation in one. Since the tumors were found in the scar only four times in approximately 100,000 abdominal operations, their occurrence may be considered as a coincidence.

8. Levy: Desmoids of the Abdominal Wall, unpublished thesis for degree of Doctor of Medicine, Yale University, 1919.



Fig. 2 (Case 1).—Photomicrograph of specimen shown in Figure 1; × 100.

Fig. 3 (Case 2).—Specimen from the upper half of the right rectus muscle.

Desmoid tumors are usually symptomless except for occasional twinges of pain. They were most often discovered in the course of routine examination, although in certain cases the tumor itself led the patient to consult a physician. Growth was usually very slow. None attained great size, but tumors weighing 20 pounds have been reported.

DIAGNOSIS

Tumors in the abdominal walls were often diagnosed as intra-abdominal: appendiceal abscess, retroperitoneal sarcoma or tumors of the cecum, gallbladder, liver, pancreas, spleen or kidney. If the abdominal walls were relaxed, as in multiparae, the tumor, if in the wall, could usually be palpated. Otherwise, especially if the tumor



Fig. 4 (Case 2).—Photomicrograph of specimen shown in Figure 3; × 100.

involved the peritoneum, its exact location could be determined only at operation. In the six cases in which the tumors originated in muscles other than the abdominal, they likewise were diagnosed with difficulty. Five were diagnosed as sarcomas, and the sixth as carcinoma of the breast. One patient, a single woman, aged 33 years, had a tumor in the right thigh just above the politeal space in which calcareous deposits were seen in the roentgenograms. Grossly, the specimen removed at operation appeared to be a calcareous degenerating desmoid. Careful study of microscopic sections, however, proved it to be a calcareous degenerating angio-endothelioma.

Pathologically, desmoid tumors have been classified under various names, for example, fibroma, fibromyoma, myxofibroma, keloid and so forth. The differentiation of desmoid tumors and sarcomas is

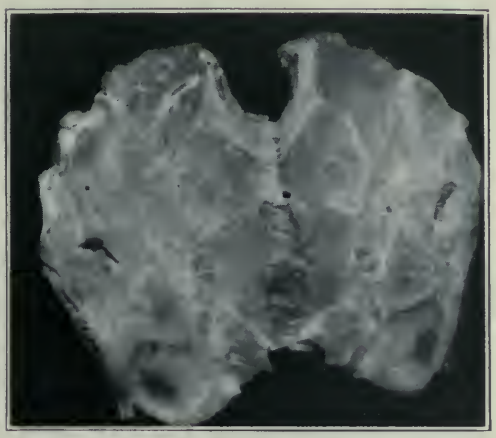

Fig. 5 (Case 3).—Specimen from the upper half of the right rectus muscle.

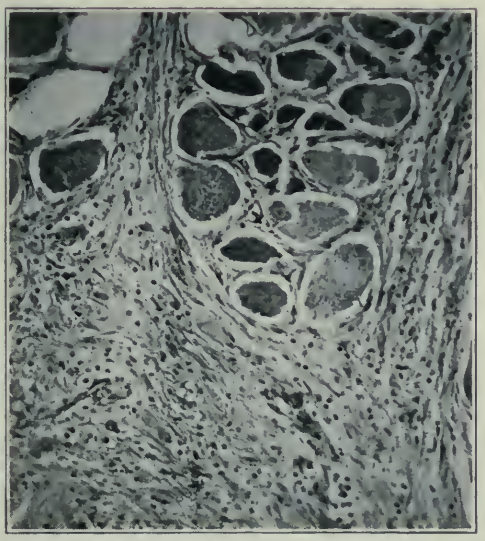

Fig. 6 (Case 3).—Photomicrograph of specimen shown in Figure 5; $\times$ 100.

difficult. Many of the so-called cell-rich desmoids contain young, actively proliferating, connective tissue cells closely resembling sarcoma cells. The recurrence of benign desmoids and the fact that desmoids may become sarcomatous complicate the clinical diagnosis.

Complete excision of the tumor resulted in permanent cure, with one exception. Four patients operated on elsewhere came to the clinic with recurrences, and were apparently cured following operation and radium treatment. In three instances the tumor was not completely excised, and the patients are known to have recurrences. Radium was used postoperatively in most instances, but the benefit derived cannot

Fig. 7 (Case 4).—Specimen from the lower half of the right rectus muscle.

be accurately estimated. Radium and roentgen-ray treatment retard growth and often markedly reduce the size of a tumor. Complete and early excision of the tumor promises most satisfactory results.

According to location the tumors may be classified thus: rectus muscles, nineteen cases; internal and external oblique and transversalis, six cases; muscles of the left thigh, one case; right gluteus maximus, one case; soleus in the right popliteal space, one case; left abductor longus, one case; right pectoralis major, one case, and left serratus magnus, one case.

REPORT OF CASES

Case 1.—Mrs. D. C. D., aged 28, during pregnancy about two years before admission had noticed a slowly growing, painless lump in the right upper abdomen. There was no history of injury. The local physician diagnosed the

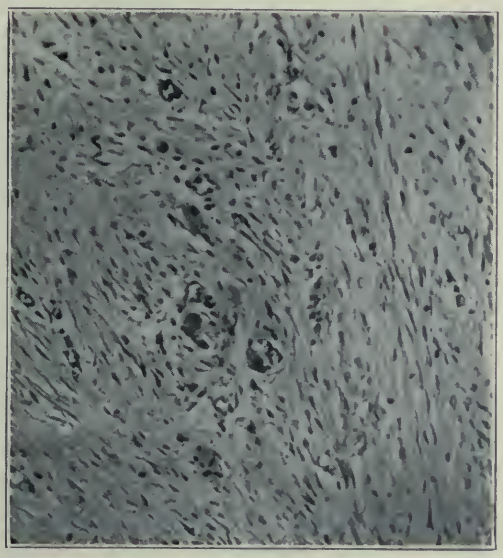

Fig. 8 (Case 4).—Photomicrograph of specimen shown in Figure 7; × 100.

Fig. 9 (Case 5).—Specimen from the right rectus muscle.

condition as "fatty tumor." Examination revealed a hard, movable, painless tumor, apparently in the right rectus muscle. At operation 15 cm. of the upper right rectus muscle was excised. A plastic closure was made, using internal oblique and imbricating fascia (Figs. 1 and 2).

Case 2.—Mrs. J. W., aged 27, had one child, aged 4 years. She first noted a lump in the right upper abdomen when the child was born. Since then it had not changed in size. Two months before admission she had a chill followed by fever and probably slight jaundice. A local physician diagnosed the condition as tumor of the gallbladder. The general examination, including a roentgen-ray examination of the stomach, was negative except for a mass, apparently intra-abdominal, in the right upper quadrant in the region of the gallbladder. A diagnosis was made of right epigastric tumor. At operation a tumor was found lying crosswise in the right rectus muscle, just below the

Fig. 10 (Case 5).—Photomicrograph of specimen shown in Figure 9; × 200.

ninth rib, and extending to the umbilicus. The entire upper half of the rectus muscle was excised with the aponeurosis and peritoneum. The gallbladder was normal (Figs. 3 and 4).

Case 3.—G. A. B., man, aged 53, had first noticed a tumor in the right upper quadrant of the abdomen three weeks prior to admission. Examination revealed the tumor to be soft, possibly cystic, and it was thought to be intra-abdominal. General examination, including roentgenograms of the spine, chest colon, kidneys, ureters and bladder, was negative. Cystoscopic examination was negative. At operation the tumor was found to be in the outer border of the right rectus muscle. It was removed and a sinus was found leading to the inner surface of the chest wall. This was packed with iodoform gauze and a rubber drain inserted. Fifteen months later the patient's general condition was good, but the old sinus continued to open and discharge periodically (Figs. 5 and 6).

Case 4.—Dr. F. S. M., aged 46, had undergone a right inguinal herniotomy in 1914. In 1917 examination at the clinic revealed multiple polyposis of the colon, which failed to respond to medical treatment, and in February, 1919,



Fig. 11 (Case 6).—Specimen from the right pectoralis major muscle.



Fig. 12 (Case 6).—Photomicrograph of specimen shown in Figure 11; × 100.

a Brown operation was performed through the incision in the right rectus muscle. In May, 1920, the patient returned with a tumor in the upper angle of the incision of the right rectus muscle. General examination was negative. At operation the tumor was found intimately attached to the posterior sheath of the right rectus muscle and peritoneum. It was completely excised, and plastic closure of the wound made. In November, 1920, the patient returned with two other tumors in the right lower quadrant of the abdomen, one 2 cm. and the other 6 cm. in diameter. Treatment with radium and roentgen ray was given (Figs. 7 and 8).

Case 5.—Mrs. S. A., aged 37, with five children, had noticed a tumor for two years in the right side of the abdomen; it had grown to about three times the size first noted. Examination revealed a fixed, firm, nodular tumor thought to be intra-abdominal; otherwise, examination was negative. At operation the tumor was found in the right rectus muscle and involved the peritoneum, a piece of which, 7.5 cm. long, was incised with the tumor. Exploration of the gallbladder, stomach and duodenum was negative. The appendix was removed (Figs. 9 and 10).

Case 6.—Mrs. A. E. D., aged 36, had a history of polydipsia, polyphagia and polyuria of one year's duration. A local physician had found sugar in the urine three months before. The patient had improved on careful diet. Examination revealed only a trace of sugar in the urine. The roentgenogram of the chest was negative. In the left lower quadrant of the right breast was a hard fixed mass attached to the skin and to the chest wall, and there were palpable glands in the axilla. A diagnosis of carcinoma of the right breast was made. A radical amputation of the right breast was performed. A tumor was noted in the inner lower quadrant over the fourth intercostal space, penetrating the muscle and involving the skin. Pathologic examination revealed that the tumor in the pectoralis major muscle, 5 by 4 by 2 cm., was purely desmoid in character. The glands in the axilla were inflammatory (Figs. 11 and 12).

SUMMARY

1. Desmoids are rare, symptomless, slowly growing benign tumors arising most commonly in the musculo-aponeurotic structures of the abdominal walls but also of other muscles.

2. Clinical diagnosis is difficult, and careful pathologic study of gross and microscopic specimens is essential.

3. Complete and early excision is the treatment of choice. Radium and roentgen rays are at least excellent palliative measures in inoperable cases.

ARCHIVES OF SURGERY

VOL. 7 SEPTEMBER, 1923 No. 2

EXTENSIVE HEMORRHAGIC EXTRAVASATION FROM THE VENOUS SYSTEM OF GALEN, WITH A CLINICAL SYNDROME

A REPORT OF THREE FATAL CASES WITH TWO NECROPSIES

CHARLES BAGLEY, JR., M.D.
BALTIMORE

Improvements in surgery directed toward the relief of traumatic brain lesions, developed since the practice of asepsis, have greatly reduced immediate mortality and have made the subsequent course of the case less prone to complications.

The group first benefited comprised patients with compound fracture of the skull, a condition now so amenable to treatment that very satisfactory results may be expected. Further advance was made when another large group was defined in whom the visible skull injury was not of such great importance, but the presence of signs and symptoms of compression was stressed. The favorable effect of decompression has come to be so well understood that the surgeon is glad when serious cases fall into this group.

There remains a large group of traumatic cases for which the surgeon has nothing to offer and in which the mortality is so great that, in a classification of cerebral lesions, it might be included under the head of "Cases fatal within the first twenty-four hours." Some would find a place there because of extensive destruction of cerebral tissue (cases not likely ever to yield to treatment); others, with little of such destruction apparent, the initial symptoms indicating a slight injury, nevertheless progress rapidly to a fatal issue. Although one is now often forced to stand by with a feeling of ineptitude, conscious that the outcome can only be unhappy, it is from this class of cases that the surgeon must draw material in his efforts to improve the outlook of traumatic cerebral lesions.

Our present inert position in the treatment of injuries of this class is in a large measure due to lack of knowledge of their mechanism. Many are regarded as fracture of the base; others are ascribed to medullary disturbance, compression, edema or anemia. Cases of severe cerebral symptoms without demonstrable fracture of the vault are often included in the group of fracture of the base without direct evidence of such fracture, and the term "medullary disturbance" is much over-

worked. By seeking a new classification of these physiologically upset cerebral cases based upon structural findings, advancement in diagnosis may be made.

In this paper, attention is invited to three cases in which the signs and symptoms were alike and in which the brain lesions were the same in the two cases in which necropsy was performed. A case not included in the following report because of the rather poor opportunity for study came under my notice in March, 1915, when I examined a man injured in an automobile accident and noted a train of symptoms similar to those seen later in the three cases here reported. The patient was in a hospital somewhat distant from Baltimore. I saw him only twice, and there was no necropsy. The symptoms were unlike those usually found in traumatic lesions, and the treatment directed toward relief was unavailing, so that my interest was especially aroused. An opportunity to study these symptoms was had in the following cases.

REPORT OF CASES

CASE 1.—*First impression: simple concussion. Subsequent course: hyperpyrexia, rapid pulse and respiratory rate; muscular rigidity with increased deep reflexes; bloody cerbrospinal fluid. Exploration, revealing low intracranial pressure; death from pneumonia ten days after accident; no necropsy.*

History.—M. L., aged 30, a married woman, brought to Sheppard and Enoch Pratt Hospital, a psychiatric institution, in Baltimore County, March 16, 1921, in the afternoon, had been thrown from a horse, striking her head in the fall. The exact nature of the accident could not be determined as it first became known when her riding companion saw the riderless horse dash by, and looking back saw the patient lying in the road on the concrete pavement. She was unconscious when picked up.

Physical Examination.—The patient was unconscious but was restless when moved, and made aimless movements. Over the right frontal region within the hairline was an abrasion, and a swelling extended back 10 cm. within the hairline. A large bruise was noted over the hip on the right side. The pupils were equal and there was no exophthalmos. Breathing at times was shallow, but there was no cyanosis.

When I saw her at 6 p. m., in consultation with Dr. J. M. T. Finney, she had not been aroused since the accident. At intervals, stertorous breathing was suggested. Snoring with inspiration and blowing with expiration were observed.

She moved the left arm freely but showed little activity of the right. When handled, the left arm offered little resistance; while the right arm offered great resistance—it was definitely spastic. The left leg moved more freely than the right.

Tests of the cranial nerves revealed: second nerves: right disk distinctly seen, veins full and slightly tortuous, appearance of left disk about the same as right; third, fourth and sixth: no nystagmus, right pupil dilated and fixed, diameter about 5 mm., left pupil reacted normally to light; fifth, no response to pin-prick; seventh, face symmetrical, impossible to bring about involuntary movements; eighth, unable to test, no blood in canals; tenth, pulse had ranged from 60 to 80 (at 6 p. m., it was 66), systolic blood pressure was 100, patient had vomited four times; first, ninth, eleventh and twelfth, not tested.

All deep reflexes of the upper extremities were very active. The Achilles tendon reflex was active and equal, and ankle clonus was suggested on both sides. The Babinski sign was pronounced on both sides.

At 10:15 p. m., the patient was more easily aroused and at one time used the left hand in a normal manner to rub the left eye. Restlessness had increased. She had moved the right arm and leg a little. The right arm was much less spastic. The right leg was spastic, but moved very little. There were jerking movements of the left arm and leg.

The right pupil was unchanged, the left was less active. The right disk showed very slight edema, but the vessels were not overfilled. The left disk was normal in appearance. Coarse jerking movements of the jaw were observed at times. Breathing was good. The pulse was irregular but averaged about 100. The systolic blood pressure was 105. The patient had been absorbing fluid by rectum. She voided involuntarily.

The fact that the right pupil was fixed and the right leg was spastic and almost motionless, with quivering of muscles, the unconscious state, the low blood pressure and the irregularity of pulse were unfavorable; but the fact that the disks showed little or no edema, the absence of a slow pulse and the lack of respiratory disturbance were considered favorable.

March 17: During the night, there had been a sharp rise of temperature to 104. The pulse rate had increased to 160 and respiration to 40 a minute. At 10:30 p. m., a slight right facial weakness was noted.

March 18: The right pupil was fixed and the left had become more active. The ophthalmic veins were full and tortuous, and a mild degree of edema of the disk was present. The facial weakness had not increased during the night. The right lower extremity was not spastic at the knee. The Babinski sign was more marked on the right but was present on the left.

Roentgen-Ray Examination.—Diploic vessel markings were numerous and the meningeal grooves were deep and their distribution was unusual. In the coronal suture, there was a line which suggested a saddle linear fracture, but the shadow was too indefinite to justify the diagnosis of skull fracture. At operation no fracture was found.

At 2 p. m., the patient was transferred from Sheppard and Enoch Pratt Hospital to the Hospital for the Women of Maryland, in Baltimore. She was completely unconscious, but occasionally moved the right arm, which was strongly contracted at the elbow and slightly so at the shoulder and at the wrist. The arm could be passively extended, and, when the patient was stimulated, became strongly flexed. The right leg was definitely spastic, although less so than twenty-four hours before, and was not markedly contracted. The left leg moved restlessly.

The right pupil, which was dilated to 6 mm., was fixed and did not respond to light either directly or indirectly. The left contracted normally and reacted both directly and consensually to light. The eyes were convergent. Slight papillary edema was present, perhaps a little more on the left than on the right.

Right facial weakness had been present for twenty-four hours. When stimulated, the muscles of the left side of the face contracted. The pulse rate was 110; the temperature, 102, and respiration, 28.

Reflexes: The corneal reflex was obtained from the right side. The response to this was a strong tetanic contraction of the whole left side of the face. The right side did not move. The jaw jerk was active. The deep reflexes of both upper extremities were exaggerated. Abdominal reflexes were

present on both sides. The knee kicks were exaggerated on both sides, much more so on the right. A sustained ankle clonus was observed on the right side and a suggestion of ankle clonus on the left. Plantar stimulation on the right gave a typical, slow dorsal flexion of the great toe. On the left, there was also a dorsal flexion, but this was less constant.

March 19: From 2 p. m. until midnight, March 18, the pulse had varied, ranging from 100 to 128, and the respiratory rate was gradually increasing.

Decompression was advised because of attacks of cardiorespiratory difficulty; the definite disturbance of the musculature of the right side of the body, and the slight edema of the disk. It was not believed that there was a great amount of pressure, but it was hoped that something could be accomplished by drainage of the bloody cerebrospinal fluid.

Operation (2 a. m.).— A left subtemporal decompression was performed, a rather small bony opening being made. The dura was slightly tense, and when it was incised, there was a free flow of bloody cerebrospinal fluid under slightly increased tension. After the escape of the fluid, the cerebral tension was less than normal. The brain was easily compressed with the spatula so there was a space of several centimeters between the cortex and the dura. The pia and arachnoid were opaque and hyperemic.

A spatula passed toward the tip of the temporal lobe disclosed very bloody cerebrospinal fluid.

Course and Outcome.—The patient returned from the operating room in a satisfactory condition; but about two hours later the pulse and respiratory rate increased and the general condition was less favorable.

After the attack which commenced about 8 a. m., there was gradual improvement until about 12 o'clock, when a pronounced disturbance occurred, lasting about an hour. The attack was recognized in its beginning and an effort was made through manipulation of the jaw and stimulation to prevent increased cyanosis and rapid rate of pulse and respiration. This, however, was unsuccessful, and the condition was grave.

Following the cardiorespiratory disturbance between 12 and 1 o'clock, the condition seemed less favorable than after the previous attacks. At 5:10 p. m. the patient was placed on the table in the cerebellar position. This reduced the respiratory difficulty, and within ten minutes the rate dropped 10 per minute.

March 20: The patient was kept in the cerebellar position. The condition at this time was improved. Since 10 o'clock the night before, the pulse had not been above 127, and respiration was below 40.

The neurologic condition was practically the same, except that the contraction of the right arm was less and the ankle clonus on the right side was less sustained.

The close of the first twenty-four hours in the cerebellar position at 5:10 p. m. found the patient in a satisfactory condition. Cyanosis, very marked twenty-four hours earlier, had practically disappeared.

March 21: The condition was less favorable. Respirations were usually between 35 and 40 and very noisy. A lumbar puncture revealed slightly bloody spinal fluid.

The puncture was made without changing from the cerebellar position, and the first few drops of the fluid flowed gently, with no evidence of pressure; after which it was necessary to aspirate the fluid. The condition improved soon after the puncture, although it could not be said that improvement was due to the puncture.

March 22: There had been a very noticeable improvement in pulse and respiratory rate, and there was some evidence of consciousness. The patient had moved the left arm freely and the right occasionally; the right leg very little, but the left frequently. Purposeful movements of the right arm were made, such as grasping a hand, turning a screw on the table and fastening a safety pin, objects with which her reaching hand came in contact.

During the day, the pulse rate and blood pressure had been steadily improving; the respiratory rate was between 35 and 40. Twitching of the left lower and perhaps some of the left upper extremity had increased. There was less motion of the right upper and very little of the right lower extremity. Complete absence of palate reflex on both sides was responsible for a good deal of difficulty in breathing. Because of the respiratory rate and the fact that a lumbar puncture had seemed of value thirty-six hours before, another puncture was made. Even the first fluid was not blood stained, but was a very light straw color. With a view to maintaining the position of the head without continuing the patient on the cerebellar table, a crinoline cast was applied.

At 5:30 p. m., the patient was placed in the dorsal position on the bed and later turned on the right side; which seemed to embarrass respiration.

March 23: There was no improvement after the lumbar puncture. Through the night, respiration had been labored and quick, and in the morning, the crinoline cast was cut off, with some relief of symptoms.

March 24: In the morning, the patient was improved. She responded when called, made an effort to talk and, at one time, opened the left eye. The temperature was running a rather steady course and the pulse and respiratory rates were lower. There had been practically no movement of the right arm or leg, but twitching of the entire left side, including the face and tongue, was observed.

In the afternoon, there had been a rather peculiar drop of pulse to 72, although the character seemed good. Respiration was labored and very shallow. Feeding through a stomach tube was satisfactory. The right arm and leg remained motionless, but some twitching of the left side was present. At 5:30, the patient was placed on the right side and an effort made to avoid flexion of the cervical region.

March 25: During the night, she suffered respiratory embarrassment, and at 6 a. m., she was placed in the dorsal position, with some relief of symptoms.

The condition for the day was unsatisfactory. Respirations were shallower; cyanosis gradually increased, and the temperature range was higher. Physical signs indicated beginning pneumonia at the bases of both lungs.

March 26: The patient was greatly bothered by mucus, which was removed at frequent intervals by means of a suction pump, this alone seeming to make breathing possible. She occasionally groaned during the aspiration, but there was practically no indication of return to consciousness. The right pupil remained dilated. There was an almost complete flaccid paralysis of the muscles of the right upper and lower extremities. Occasional movements of the left arm and hand were noted, and she moved the left foot when the sole was stimulated, until late in the day, when there was no response. The deep reflexes of the left arm were very sluggish. Achilles tendon reflex was sluggish on the left and absent on the right. Biceps, triceps and radioperiosteal reflexes were more active on the right than on the left. Evidence was seen of increasing pneumonia at the bases of the lungs posteriorly. Death occurred at midnight.

Summary of Clinical Course.—A severe blow, by which the right frontal region, the right elbow and the right thigh were bruised, resulted in immediate unconsciousness and absence of motion in all extremities. On the way to the hospital, perhaps twenty minutes after the accident, the patient showed some little motion of the left arm and leg, but none of the right.

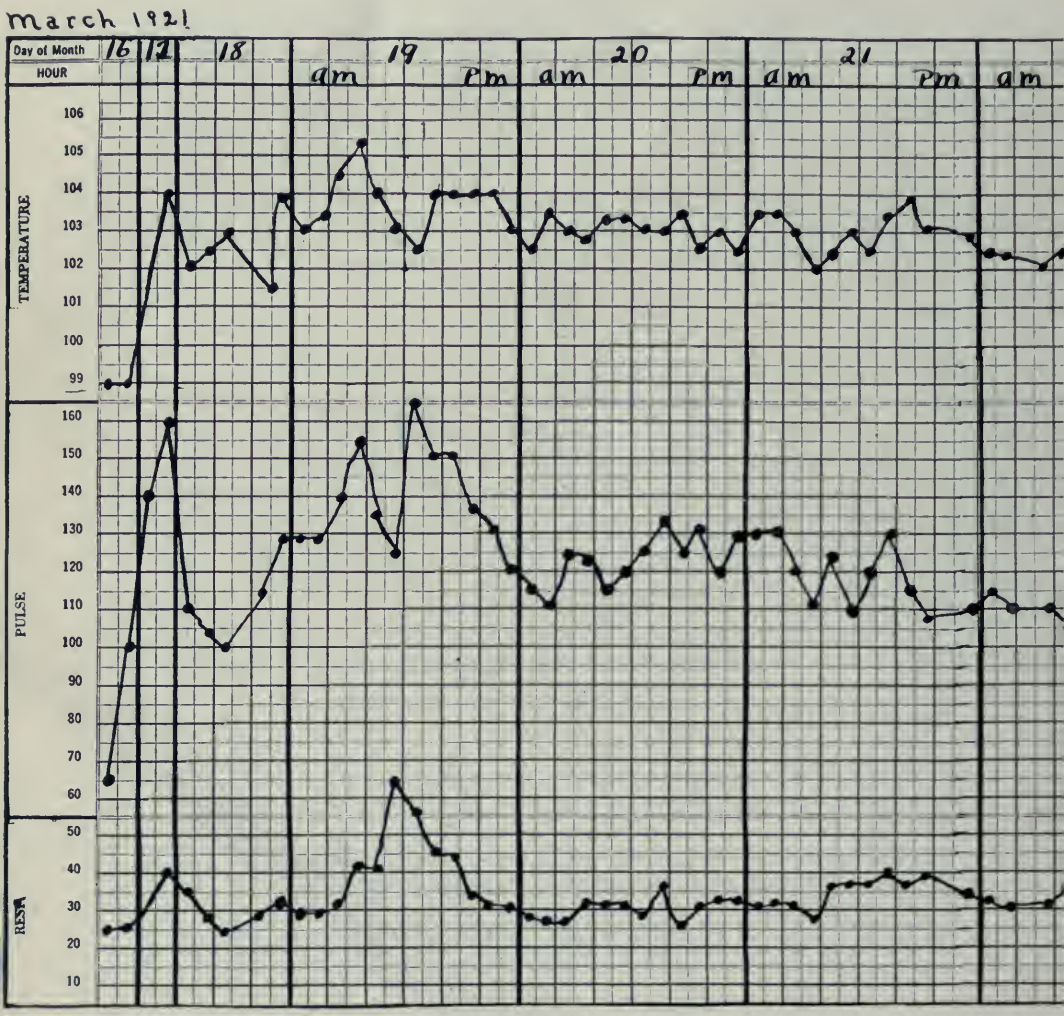

Fig. 1 (Case 1).—Clinical chart.

Two hours after the injury, there were spasticity of the right arm and leg, restlessness, perhaps irritation of the left arm and leg, exaggeration of the deep reflexes on both sides, including a suggestive ankle clonus, a Babinski sign on both sides, dilatation and fixation of the right pupil and much blood in the cerebrospinal fluid. Consciousness was lost but the corneal reflexes were present. The patient did not seem to be in deep coma.

During the first few hours, the pulse was slow, registering as low as 64. Between 11:30 and 12 o'clock, there was a sharp rise to 140, and later to 160. There was also a sharp rise of temperature and of the respiratory rate.

Twenty-four hours after the accident, the right arm and leg were still spastic. Forty-eight hours after, the condition was unimproved.

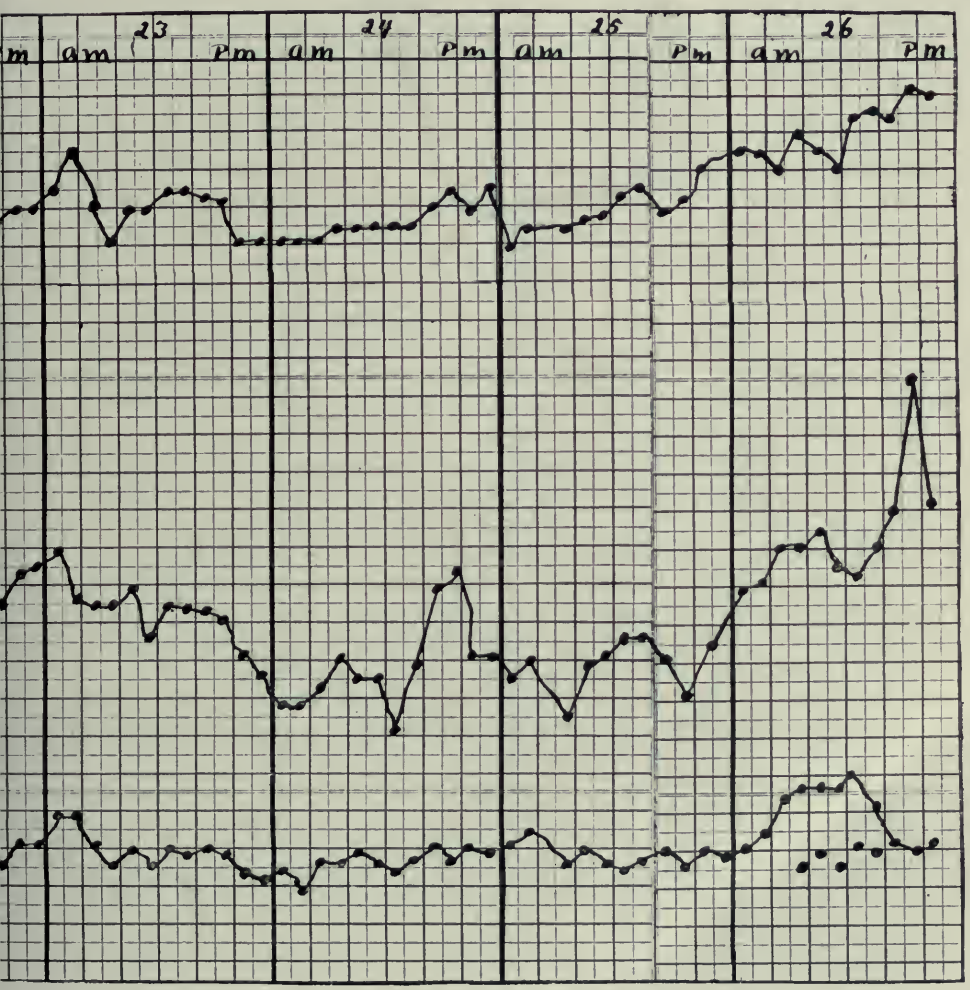

Fig. 1 (Case 1).—Clinical chart.

After sixty hours, evidence of cardiorespiratory disturbance was observed. A left subtemporal decompression was performed. There was an excess of cerebrospinal fluid under slightly increased tension, but the brain bulk seemed less than normal. The cardiorespiratory disturbance continued.

Practically no change in the state of consciousness occurred until about 170 hours after the injury, when the patient attempted to answer simple ques-

tions. This lasted for twelve hours, when there was profound coma. The muscle condition, marked by spasticity and lack of motion on the right side, continued, and the left side became less active, but did not seem completely paralyzed. Twitching of the muscles of the entire left side, including the face and tongue, seemed to increase when the patient was in the right lateral position. The cerebrospinal fluid, very bloody in the beginning, contained only a few blood cells six days after the accident, and was not under pressure.

Because of marked cardiorespiratory, thermoregulatory disturbance and bilateral motor pathway involvement, a lesion, in all probability a hemorrhage, was believed to involve the medulla. Whether the hemorrhage was intramedullary or extramedullary could not be said with certainty, but continuation of signs and symptoms after drainage of all bloody cerebrospinal fluid argued against an extramedullary hemorrhage.

In addition to motor pathway involvement, the paralysis of the right third and seventh nerves also indicated medullary disturbance. This placed the lesion rather high, and it could not be properly alined with the paralysis of the right side, so that if the lesion was intramedullary, it was not single.[1]

On the day this patient died, initial examination of a patient (Case 2) admitted to another hospital, led us to believe that the lesion to be dealt with in this case was the same as that described in Case 1.

Case 2.—*First impression: concussion. Subsequent course: hyperpyrexia, rapid pulse and respiratory rate; muscular rigidity with increased deep reflexes. Ventricular puncture revealing low intracranial pressure and bloody cerebrospinal fluid; death sixty hours after injury; necropsy.*

History.—A. S., aged 8 years, a well-nourished and well-developed lad, was seen by me in consultation with Dr. A. B. Lennan at the Hebrew Hospital to which he was admitted at 10:30 p. m., March 26, 1921, about ten hours after being struck by an automobile.

The patient's father and two sisters were living and well. His mother died of acute nephritis. He had had measles and whooping cough, but his general health was good.

Examination.—The boy was unconscious, as he had been since the moment of the accident, and vomited frequently. He was restless and sometimes groaned as he lay rigid in bed, and the arms were held firmly against the trunk. Rigidity was greater on the left side and was much increased by manipulation.

The right fundus presented a sharp outline, with the pigment showing. The vessels were full but within normal limits. It was impossible to see the left disk because of lack of cooperation. The pupils were equal and were small, but not pin-point size, and they reacted well to light. The face was symmetrical. There was no bleeding from the ears, nor was there evidence

1. The summing up of the clinical course and our final opinion in this case in which necropsy was not obtained are of interest when contrasted with the actual lesions in Cases 2 and 3.

of scalp injury. An irregularity of the skull, probably developmental, was observed in the right parietofrontal region. The temperature was 102 F.; pulse, 120; blood pressure, 116.

Deep reflexes on the left were not markedly increased. There was dorsal flexion of both great toes. The knee jerks were active on both sides. The Achilles tendon reflex was not increased, and there was no ankle clonus. On stimulation, the Babinski reflex was marked.

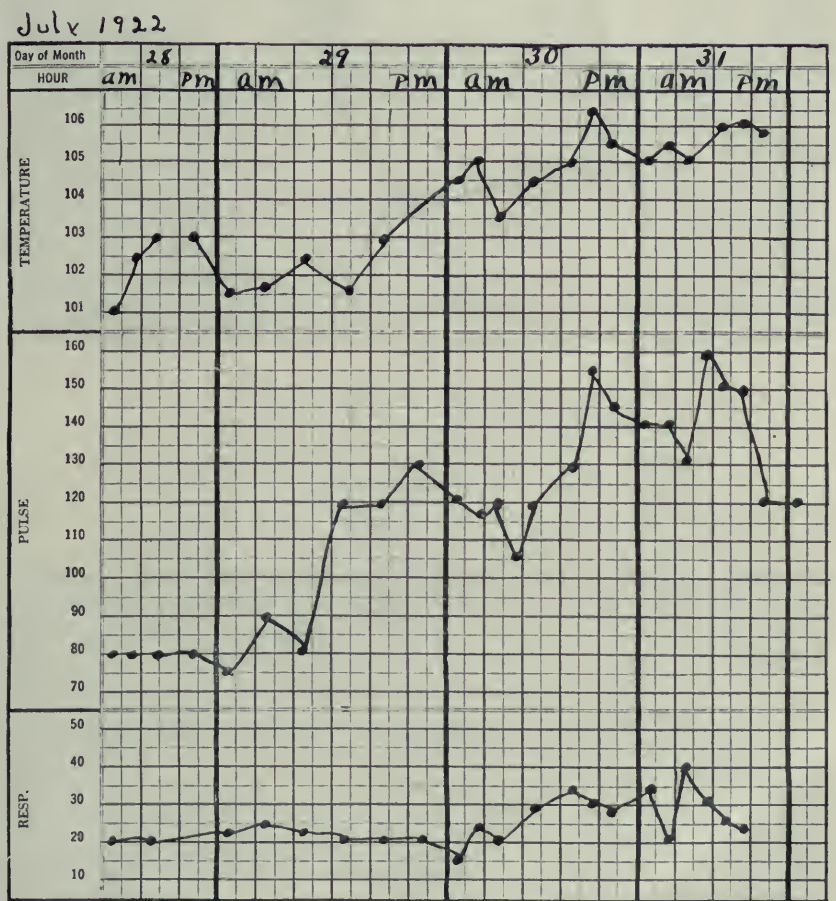

Fig. 2 (Case 2).—Clinical chart.

March 27: The pupils were 1.5 mm. in diameter, were equal and did not react to light. While being examined, the patient rolled his eyes in all directions, but generally with lack of parallelism.

Jaw jerks and reflex contractions over the occipitofrontalis and muscles of the face were not obtained. Masseter reflexes were absent. The tongue was not drawn to either side. The patient was incapable of voluntary movements of the muscles of the extremities, trunk or face. Handling produced contraction of the muscles of the trunk; spasms of the extensors of the arms and legs;

Fig. 3 (Case 2).—The frontal section, showing hemorrhage in the gyrus cinguli, corpus callosum and septum lucidum.

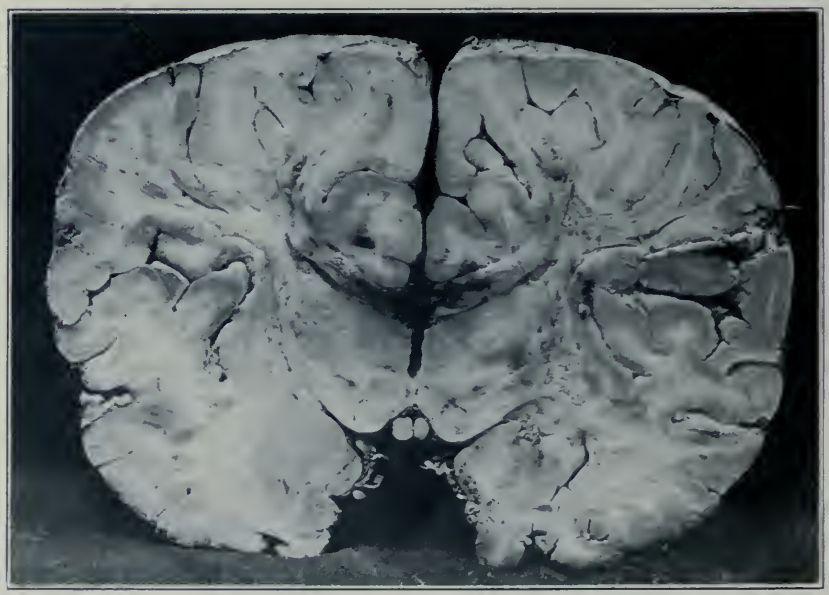

Fig. 4 (Case 2).—A more posterior section than that presented in Figure 3, showing greater extravasation in the same structures.

Fig. 5 (Case 2).—Hemorrhages as noted in Figures 3 and 4, and in the thalamus of both sides.

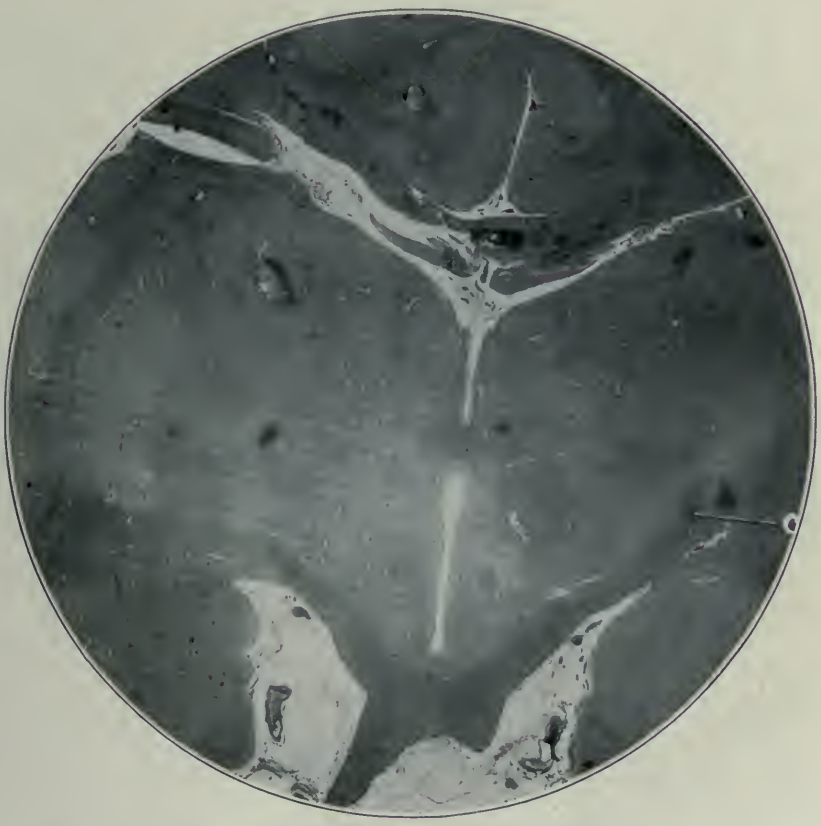

Fig. 6 (Case 2).—Higher magnification of the section presented in Figure 5, showing distortion of the corpus callosum and fornix, and dilatation and hemorrhagic extravasation of the veins of the thalamus. The extravasation in the internal capsule fibers on the right at *c* is especially to be noted. A higher magnification of this is seen in Figure 7.

flexion of the thumb on the palm; flexion of all the fingers over the thumb, and retraction and rotation of the head to the right. Roentgen-ray examination revealed no fracture of the skull.

Treatment and Course.—Having so recently had the experience described in Case 1, I was at a loss to advise treatment in this case. It was evident that the usual decompression operation was not indicated, but I aspirated the lateral ventricles and found that they contained a small amount of bloody

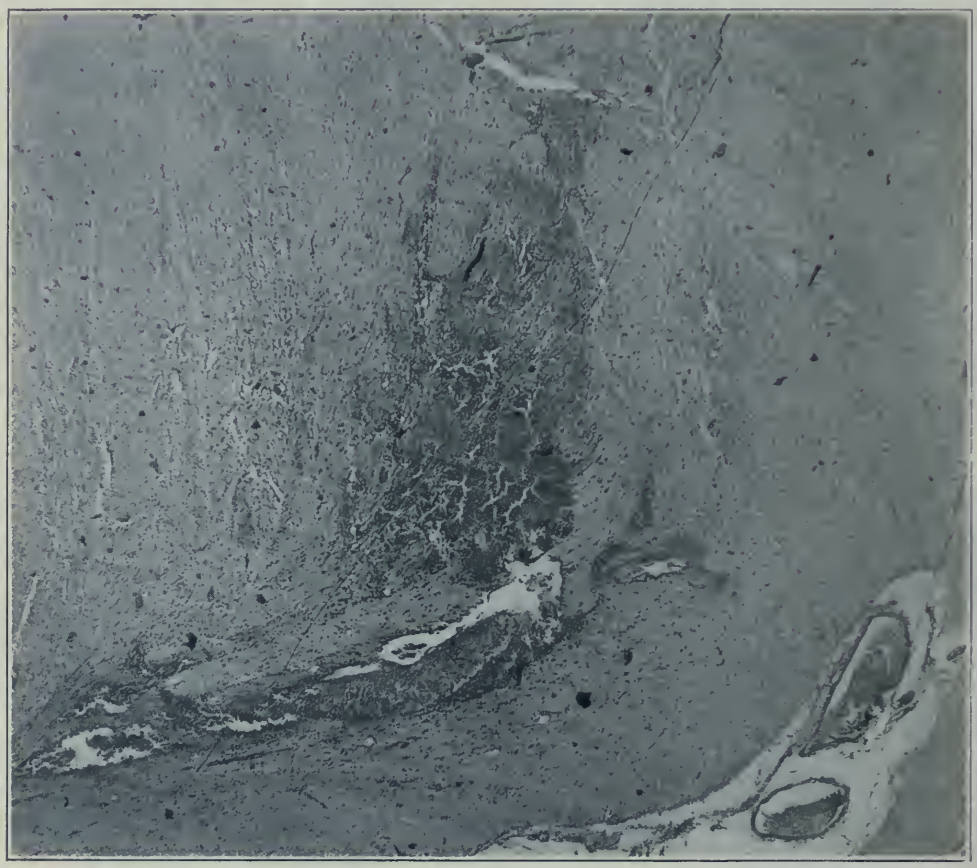

Fig. 7 (Case 2).—Magnification of area *c*, in Figure 6, showing extravasation in the internal capsule fibers.

cerebrospinal fluid. During this procedure, I was struck, as in the former case, by the low degree of intracranial tension.

March 28: The patient was unconscious all day, with a temperature ranging around 105 F. He was placed on a special table in the cerebellar position. His pharynx was cleaned out by the suction apparatus whenever indicated. The condition slowly became worse. The neurologic state was much the same as on the day before. The temperature rose to 107 F., and the pulse rate and respiratory rate were high. Sponge baths were given every hour, but the

temperature did not respond. At 7 p. m., respirations were very shallow, at 10:00 p. m. becoming of the Cheyne-Stokes type. At 12:35 a. m., March 29, death occurred, sixty hours after the accident.

Necropsy Findings.—The brain was removed, and the external appearance was not abnormal except for slight blood staining of the pia at the base. No fracture in any part of the skull was found. The brain was immersed in 10 per cent. formaldehyd, and sectioned after several days. Extensive hemorrhagic extravasation of the corpus callosum was most striking, though smaller hemorrhages were found in the gyrus cinguli and thalamus.

CASE 3.—*Compound comminuted fracture right elbow; shock and cerebral concussion; operation; repair and drainage of elbow joint and treatment for shock; cerebral disturbance greater on third day; hyperpyrexia, a rapid pulse and respiratory rate; lumbar puncture revealing bloody cerebrospinal fluid under low pressure; cyanosis and later bronchopneumonia; increased deep reflexes. Death four days after injury; necropsy.*

History.—W. W., a foreman in a meat packing house, was brought to St. Agnes Hospital, Baltimore, at 10 a. m., July 28, 1922, in an unconscious condition immediately after a fall two stories down an elevator shaft.

Examination.—The patient was unconscious and markedly shocked. No fracture of the skull was made out. The right shoulder was badly swollen, and there was a compound comminuted fracture of the right elbow. The left pupil was larger than the right. The temperature was 101.5 F.

The patient was assigned to the surgical service of Dr. George Stewart. Because of severe shock, the injuries were treated temporarily. The elbow was treated by the application of dressings and by placing a number of tubes for irrigation by Dakin's method.

July 29: In the morning, the patient was still unconscious. The temperature had ranged from 101 to 102.2 F. The pulse rate was between 75 and 85 per minute. Respiration had not been elevated above normal.

Roentgen-ray examination revealed a compound comminuted fracture of the right elbow joint, and the lines were suggestive of fracture of the right shoulder and of the skull.

Spinal fluid test revealed no organisms; cell count, 20; globulin, slightly positive.

Treatment and Course.—A more thorough dressing was made; devitalized tissue was removed, and the cavity was washed with surgical solution of chlorinated soda (Dakin's solution). Tetanus antitoxin was given.

In the evening, the patient was very restless and his condition was unimproved. At 8 p. m., the pulse rate had increased to 120.

July 30: The temperature range had become higher and the pulse rate had gone above 120. A lumbar puncture revealed slightly bloody cerebrospinal fluid under low pressure. There was a leukocytosis of 18,400.

July 31: A neurologic consultation was requested. The patient was entirely unconscious. There was slight cyanosis of the lips. The skin was moist but rather cold. The pupils were contracted but were equal in size. Slight edema of the fundi was observed. The veins were overfilled and tortuous. The cranial nerves were negative. There was no paralysis of muscles, but an increase of muscle tone with exaggeration of the deep reflexes was present.

This increase was more evident when an effort was made to turn the patient in bed. A second lumbar puncture revealed slightly yellow cerebrospinal fluid under about normal pressure.

The very early elevation of temperature suggested that this was of cerebral origin. Later, however, the patient seemed septic and it was believed that the temperature and leukocytosis were due to something outside the head—in all probability the fracture of the right elbow.

August 1: The respiratory rate, pulse rate and temperature had increased. The patient died about 4 a. m.

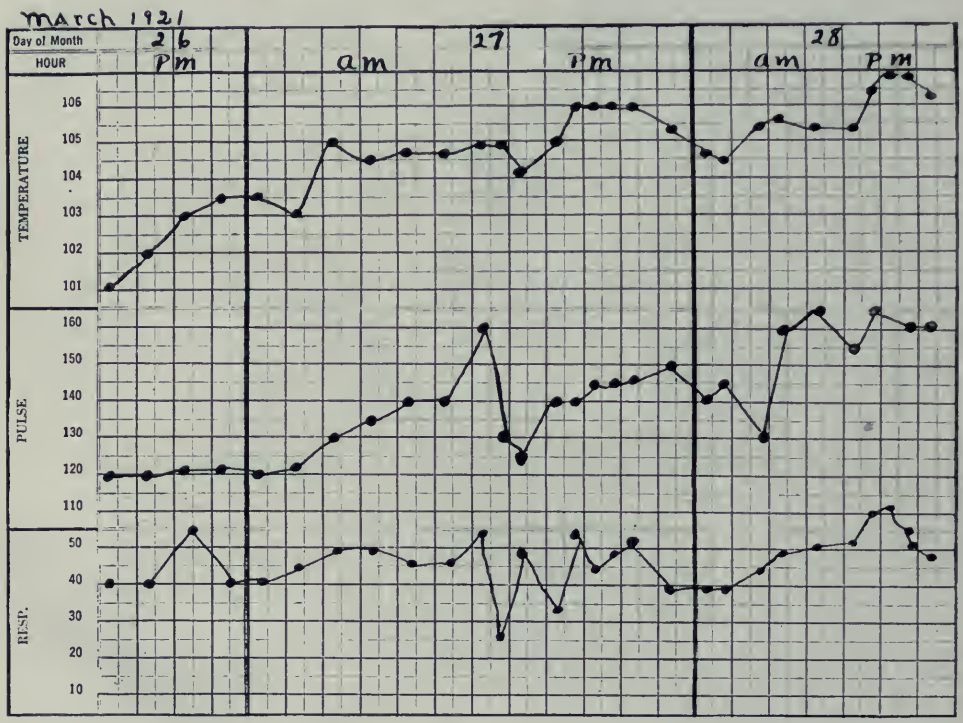

Fig. 8 (Case 3).—Clinical chart.

Necropsy Findings.—The brain was removed in the usual manner, and a small amount of blood staining was found over the cortex. There was no flattening of the convolutions or other evidence of increase of intracranial pressure.

A compound comminuted fracture of the elbow joint with evidence of infection was revealed. No fracture in any part of the skull was found. Small patches of bronchopneumonia were found in the lower lobes of both lungs.

The lesions in the brains in Cases 2 and 3 were strikingly alike, consisting of hemorrhagic extravasations varying in size from small microscopic lesions to large venous infarcts resulting in extensive softening.

Fig. 9 (Case 3).—A frontal section through the rostrum corpus callosum, with extravasation chiefly in the lateral portion of the structure.

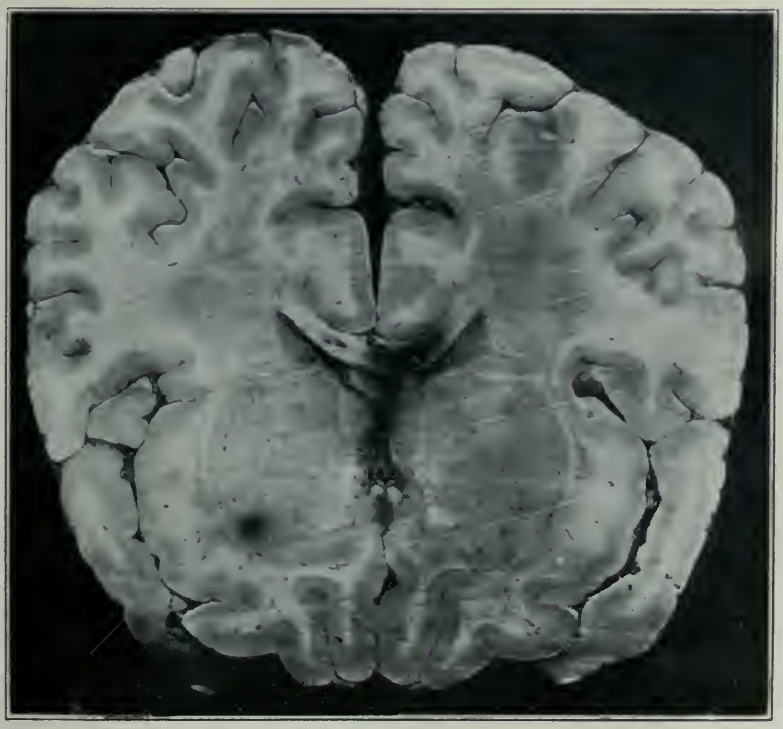

Fig. 10 (Case 3).—Extravasation of the corpus callosum extending into the ventricle. In addition to these hemorrhages, there are numerous small extravasations throughout the lenticular and caudate nuclei, visible microscopically.

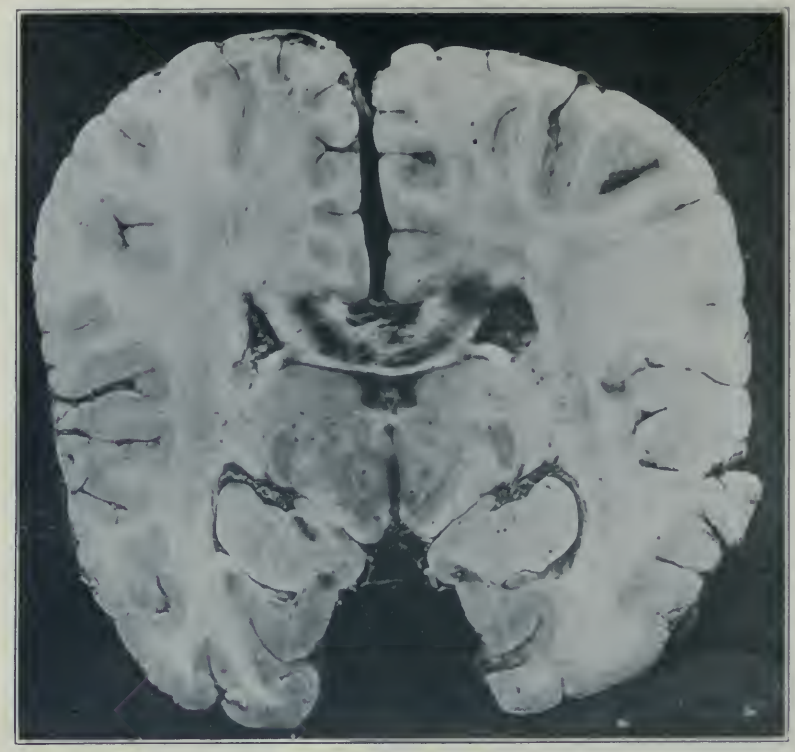

Fig. 11 (Case 3).—A frontal section showing extensive extravasation in the splenium corpus callosum and small hemorrhage in the cornu ammonis.

Fig. 12 (Case 3).—Extravasation of blood in the tapetum fibers of the right hemisphere.

Fig. 13 (Case 3).—Frontal section through the septum lucidum, showing dilatation of the veins of this structure.

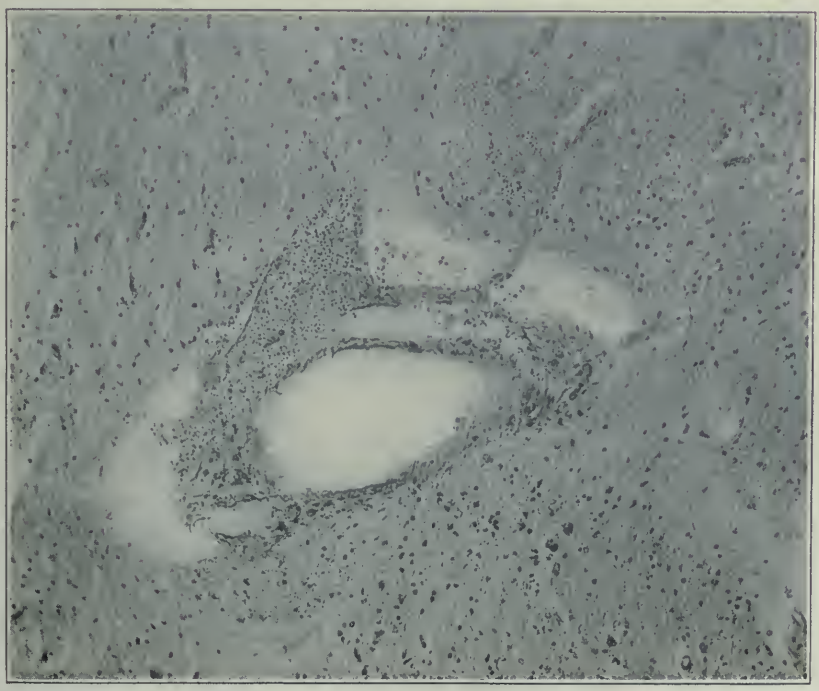

Fig. 14 (Case 3).—Photomicrograph of a vein of the thalamus which is distended and broken so that there is extravasation of blood in the neighborhood and softening of the nervous tissue; × 125.

Fig. 15 (Case 3).—Photomicrograph of area of extravasation. Throughout the tissue drained by the vein of Galen, numerous areas of this type were found.

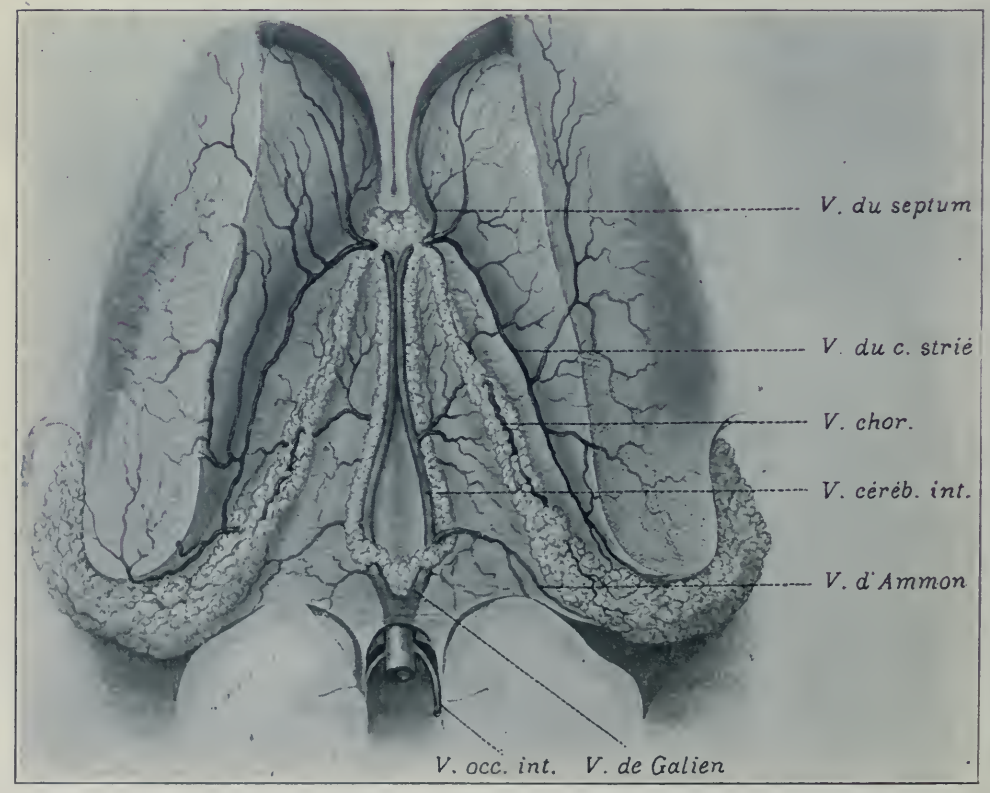

Fig. 16.—Internal tributaries of the venous system of Galen (redrawn from Poirier and Charpy).

In studying the sections, one was struck by the fact that the lesions were limited to certain structures, the remaining parts of the brain having entirely escaped. This limitation suggested to Dr. Meyer that the cause was to be found in some circulatory disorder of the brain,

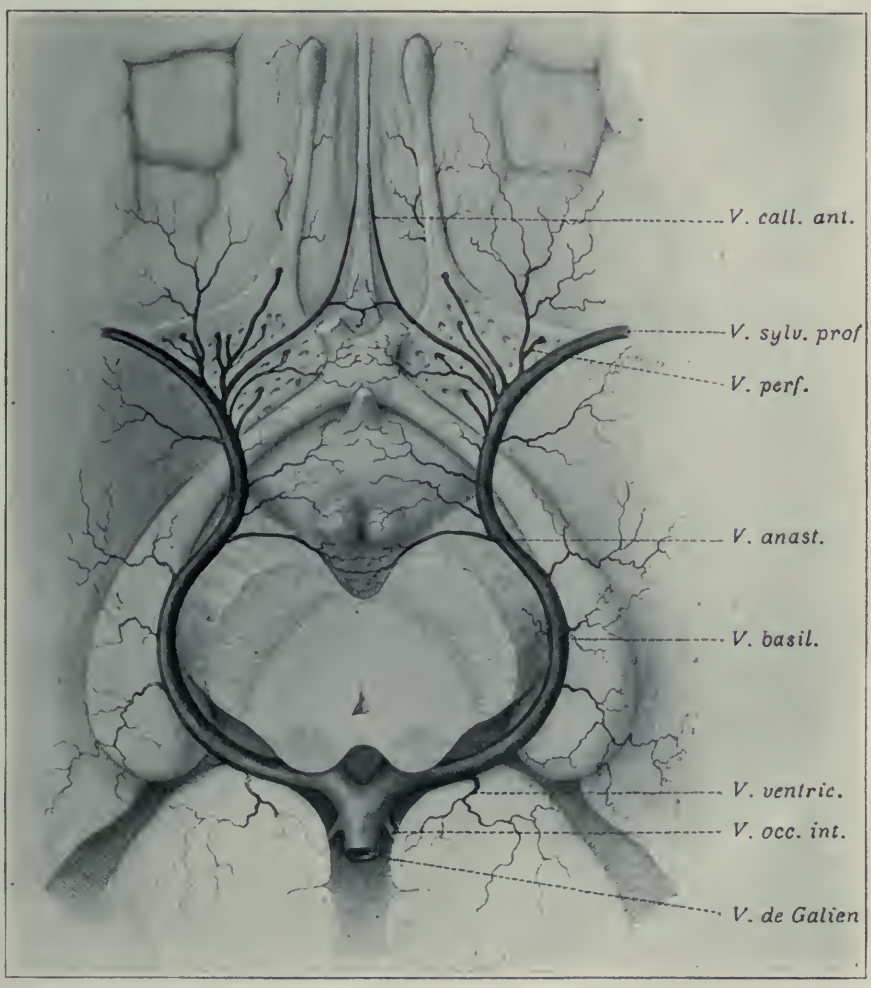

Fig. 17.—Basal tributaries of the venous system of Galen (redrawn from Poirier and Charpy).

and further examination showed the lesions to be limited to the area drained by the vein of Galen and its tributaries. All of the tributaries of the vein are not involved in each case. In Case 2, there was extensive infarction in the gyrus cinguli, but the extreme anterior and posterior extremities of the corpus callosum were free from extravasation; while

the reverse was true in Case 3. The lesion was, therefore, evidently not a complete thrombosis of the vein of Galen, but rather a partial obstruction resulting in stasis of a greater or less degree in the various tributaries.

The accompanying figures, from the work of Poirier and Charpy,[2] show the distribution of the tributaries of the vein of Galen, an area exactly corresponding to that involved in these cases.[3]

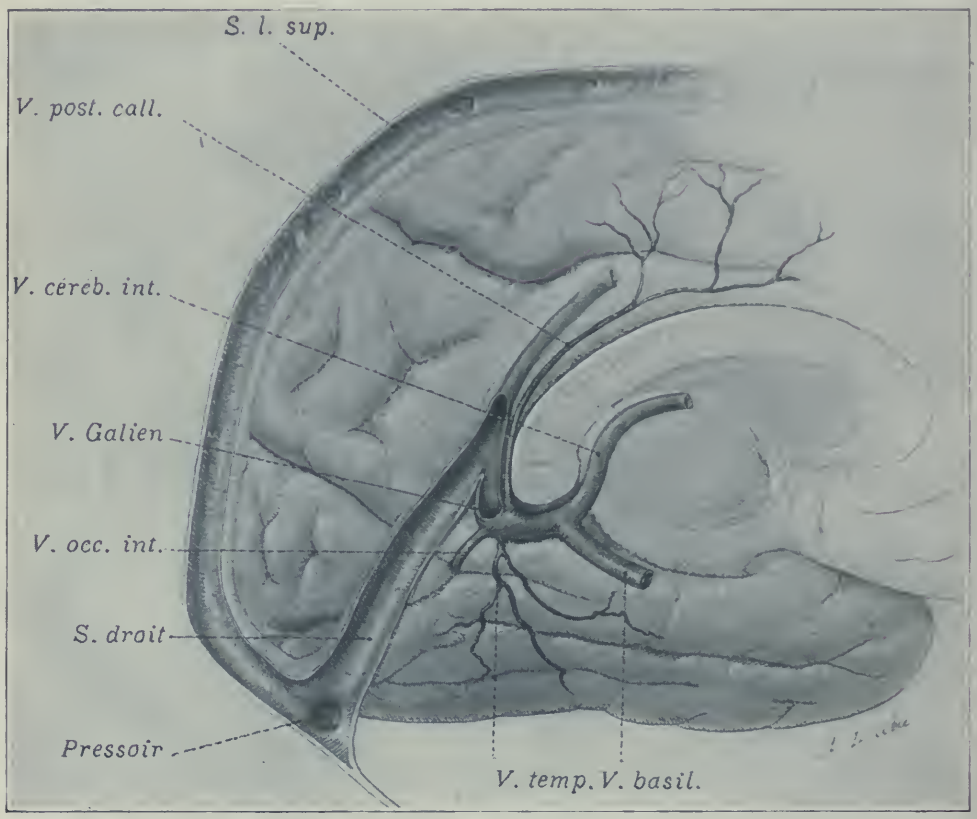

Fig. 18.—Mesial surface tributaries of the venous system of Galen (redrawn from Poirier and Charpy).

2. Poirier, P., and Charpy, A.: Traite d'anatomie Humaine, Paris **3,** 1901.

3. In the splendid paper of Eardley Holland (The Causation of Foetal Death, London, 1922) distortion and rupture of the vein of Galen at a point where the straight sinus is formed is put down as one of the results of trauma in the new-born. Holland found the vein of Galen ruptured twice in a series of eighty-one cases, but he believes that hemorrhages from some of the tributaries is a much more frequent accident.

SUMMARY

The clinical course was identical in the three cases. An early sharp rise of temperature, amounting to nearly 3 degrees a few minutes after the accident in Case 2 and to 5.5 degrees ten hours after in Case 1, marked the beginning of a hyperpyrexia that continued throughout the course and gradually increased to from 106 to 107 F. in all cases at the time of death. The respiratory and pulse rates were greatly elevated in all cases. In Case 2, the pulse rate was 120 and the respirations 56 a few hours after the accident, and the pulse rate was 160 before the end of twenty-four hours after coming under observation, after which it ranged between 125 and 170. The respiration rate during the entire course ranged between 26 and 62 per minute.

In all cases, muscle power was affected to a greater or less degree, and increase of deep reflexes was present. Disturbance was chiefly of the spastic type, with predominance of loss of power on one side in Case 1. The pupillary reactions were disturbed and there was blood in the cerebrospinal fluid in all cases. In Case 1, a small opening was made in the temporal region and the intracranial tension was found to be less than normal; indeed the brain seemed to be almost shriveled and was very easily compressed by the spatula.

In Case 2 the ventricle was aspirated through a burr opening over the occipital pole. In this case, there was a space of at least 1 cm. between the dura and the cortex of the brain showing lack of a normal degree of intracranial pressure.

The pathologic findings in the two cases that came to necropsy justify the conclusion that the symptom complex was based upon a definite morbid state. The morbid anatomy was so definitely limited to the structures anatomically related to the vein of Galen and its tributaries that it is believed such a syndrome can be accounted for in the lesions described. Some of the signs, for example, disturbance of muscles, spasticity, weakness and increase of deep reflexes, are fully accounted for by the pathologic findings; while others, hyperpyrexia, unconsciousness, and low intracranial pressure, could, perhaps, better be attributed to lesions of this part of the brain than to those of any other.

RESECTION OF THE PROXIMAL COLON FOR MALIGNANCY *

FRED W. RANKIN, M.D.
Professor of Surgery, University of Louisville
LOUISVILLE, KY.

AND

ALBERT J. SCHOLL, M.D.
Resident Surgeon, St. Mary's Hospital
ROCHESTER, MINN.

Both physiologically and anatomically, the right half of the colon lends itself admirably to direct surgical procedures with very little general disturbance to the patient. Developmentally, the right half of the colon differs from the left, and certain anatomic relations render its mobilization comparatively simple; its sacrifice not incompatible with comfortable existence, and its removal less likely to be followed by unpleasant complications and malignant recurrences. In fetal life, the entire colon begins low in the left side of the abdomen close to the middle line, and then rises progressively, rotating around the superior mesenteric artery as an axis until it reaches the attachment of the splenocolic ligament, which is derived from the omentum, under the diaphragm in the left splenic fossa. After the third month of fetal life, the right colon pushes forward across the abdomen, and the cecum descends to its final station in the right flank. During this act of rotation, the mesentery elongates to such an extent that, in its final position, the ilocecal coil is freely movable, and possessed of a large but constant blood supply and a scanty lymphatic drainage.

This completion of mobilization of the cecal angle and the scanty lymphatic supply make the technical resection comparatively simple, and also influence the prognosis favorably. Removal of the colon around to the juncture of the hepatic flexure with the proximal half of the transverse colon causes little, if any, impairment from a physiologic standpoint. The right half of the colon is recognized to be the portion of the organ in which absorption takes place; the left half is utilized more as a reservoir in which many of the fluid elements of the ingesta are extracted, or by reverse peristalsis are returned to the cecum and hepatic flexure. It has been noted, in cases in which the right half of the colon was removed and the continuity of the bowel restored by any one of the various methods applicable to such cases, that a dilatation of

* From the Division of Surgery, Mayo Clinic.

from 30 to 40 cm. of the ileum takes place. This dilatation suggests that the distal segment of the small bowel may assume the functions of the colon when the latter is removed. Its embryologic development from the middle gut is identical with that of the large bowel up to the juncture of the right half with the transverse colon.

LYMPHATIC INVOLVEMENT

Because of its scanty lymphatic drainage, cancer of the right half of the large bowel metastasizes slowly, and hence the prognosis is favorable. C. H. Mayo [1] has pointed out that these lymphatics may be considered as connected with only the outer surface of the colon; and he further attributed their relatively small number to the less septic content of this part of the colon, which caused Nature to eliminate them in part. For this reason, extensive operations involving the removal of parts of adjacent organs to which the cancer of the colon is attached are often advisable, and are attended with gratifying results. Because the growth remains local so long, death rarely results directly from it, but is due to perforation and peritonitis or obstruction. Butlin [2] has shown that, in 55 per cent. of patients with cancer of the colon, the disease is still local at death. Consequently, one gages the extensiveness of the lesion and its prognosis by the involvement of the lymph glands. In the right half of the colon, these lymphatics follow a well-organized system which is a part of the ileocolic system, the lymphatics of which accompany the ileocolic artery from its origin and run along its branches to their termination. The various groups of these glands are named according to the vessel which they accompany.

Craig,[3] in reviewing the cases of cancer of the right colon at the Mayo Clinic which had been subjected to radical extirpation, studied 100 pathologic specimens, and 1,033 associated lymphatic glands. He tabulated the material in three groups: (1) cases in which there was no glandular involvement; (2) cases in which there was glandular involvement, and (3) cases of colloid cancers which were further subdivided into (*a*) those with glandular involvement, and (*b*) those without glandular involvement. He found that there was metastatic involvement of the original chain of glands in 32 per cent. of cases. Involved lymphatic glands were often found which were apparently normal in consistency, yet were palpable and visible to the naked eye. The size of the lesion and the size and number of the invaded lymphatic

---

1. Mayo, C. H.: A Consideration of Cancer of the Large Bowel, Long Island M. J. **11**:129-131, 1917.

2. Butlin, H. T.: On the Operative Surgery of Malignant Disease, Ed. 2, Philadelphia, P. Blakiston's Son and Company **12,** 1900.

3. Craig, W. McK.: Personal communication to authors.

glands proved to be no criterion of the presence or absence of metastasis. Certain glands which simulated cellular infiltration and lymphedema often proved to be inflammatory; others were too small to be palpated at the time of operation, and yet were found to be the site of metastasis. In the cases presenting glandular involvement, there were also numerous glands which could be distinguished only by microscopic study. At times, in cases of low malignancy, clinically, without metastasis, the local glands were larger and more numerous than in the cases of higher malignancy with metastatic involvement. Cases in which a larger number of glands were involved usually proved to be highly malignant clinically. Craig believes that predominance of invasion of the posterior ileocolic lymphatic glands should prove valuable in making diagnoses in the operating room, for 64 per cent. of the glands which showed metastatic involvement from malignancy involving the right side came from the ileocolic group. It is quite evident from this study that the only index to prognosis is a thorough study of the involvement of the lymphatic glands, and since Nature has protected the right half of the colon by giving to it a scanty lymphatic drainage, it seems reasonable to expect a high percentage of cures in this type of malignancy.

PATHOLOGY

The majority of tumors on the right half of the colon are adenocarcinoma, arising from the intestinal mucosa in the cecum. As a rule, they are large and irregular, and are covered with stubby protuberances; or they may be ulcerated, with flat necrotic surfaces. The most common type often becomes large, and is highly cellular, composed almost entirely of glandular tissue. A histologic study of this type of tumor reveals great masses of irregularly grouped glands. The cells are irregular in size and shape, and contain large, deeply staining nuclei. Occasionally, the glandular cells are arranged in a manner similar to that of the highly cellular papillary growths which at times occur in the ovary and the thyroid. In some tumors, there is predominance of fibrous tissue, and when this occurs, the growth is usually flat and rarely undergoes extensive ulceration, but has a tendency to cause obstruction by contraction of the intestinal lumen.

In the fibrous type of growth there is generally only a small number of glandular cells, which are frequently arranged in one or two rows, separated by bands of fibrous tissue. Either the glandular or the fibrous type may completely encircle the intestine. Colloid cancers may occur in the right half of the colon, generally arising in the cecum. They may become large, and generally do not ulcerate so readily as the more cellular adenocarcinoma. Grossly, the colloid cancers are soft and gelatinous; histologically, they are composed of a thinly cellular,

collagenous substance, supported by a framework of fibrous connective tissue. The colloid growths were found by Hayes[4] to occur in 16 per cent. of cancers of the large bowel, and a study of their clinical symptoms, as well as the local pathologic condition, revealed that they were divided into two types, those with short duration of symptoms and mildly malignant, and those with a long duration of symptoms and highly malignant. Hayes found a high percentage of local involvement of the lymphatic glands in colloid cancers, and made the clinical notation that, once a malignant condition of this type had developed metastases, as it frequently does early, its control is extremely difficult.

GENERAL COMMENT

Approximately, 30 per cent. of cancers of the large bowel originate in the right segment. Mummery[5] collected 1,006 cases, in 388 of which the cancers were found to be located proximal to the juncture of the hepatic flexure with the transverse colon. Ewing[6] notes eighty-eight growths of the right side in 297 cases collected by Körte,[7] Petermann[8] and Anschutz.[9] In 1,273 cases of cancer of the large bowel, including the rectum, treated surgically at the Mayo Clinic, in which radical removal was carried out, 150 operations were for cancer in the right half of the colon; 102, in the cecum; thirty, in the ascending colon; fifteen, in the hepatic flexure, and three at the juncture of the hepatic flexure with the transverse colon.

With the possible exception of cancer of the body of the uterus, no site offers a more favorable prognosis following radical extirpation. In 1916, W. J. Mayo[10] reported 419 resections of the large bowel, with an average mortality of 14.5 per cent. Eighty-four of these cancers involved the left half of the colon, including the splenic flexure, but not the rectum; and the mortality was 17 per cent. Resection of the right colon was followed by a mortality of 12.5 per cent. This difference of 5.5 per cent. in the mortality rate he attributed to the less septic character of the liquid contents of the right colon as

---

4. Hayes, J. M.: The Involvement of the Lymph Glands in Carcinoma of the Large Intestine, Minnesota Med. **4**:653-663 (Nov.) 1921.

5. Mummery, J. P.: Diseases of the Colon and Their Surgical Treatment (Founded on the Jacksonian Essay for 1909), New York, William Wood & Co. **6**, 1910.

6. Ewing, James: Neoplastic Diseases; A Treatise on Tumors, Ed. 2, Philadelphia, W. B. Saunders Company, 1922.

7. Körte, quoted by Ewing, James: Footnote 6.

8. Petermann, quoted by Ewing, James: Footnote 6.

9. Anschutz, quoted by Ewing, James: Footnote 6.

10. Mayo, W. J.: Radical Operations for the Cure of Cancer of the Second Half of the Large Intestine, Not Including the Rectum, J. A. M. A. **67**:1279-1284 (Oct. 28) 1916.

compared with the solid contents of the left. He emphasized the fact that the attempt to increase the operability in cases of cancer had resulted in a higher mortality, because of the fact that patients with more extensive disease, who were therefore poorer surgical risks, were subjected to a more radical operation.

SYMPTOMS AND DIAGNOSIS

Beside being susceptible to invasion by cancer, the right colon is commonly the site of pathologic changes which result from two major infections: hyperplastic tuberculosis and actinomycosis. The striking similarity of clinical symptoms presented by the three diseases in the early stages sometimes makes accurate differentiation difficult. The association of weakness and loss of weight and strength; secondary anemia without apparent loss of blood, and a generally painless tumor in the right lower abdomen is common to all. Cancer progresses more rapidly, and, as a rule, with a more steadily increasing anemia, than the two other diseases, and its recognition by means of roentgenograms is generally more accurate in the early stages. The presence of the tumor in many cases has antedated by weeks or months the appearance of other symptoms distressing enough to compel the patient to seek relief. A complete physical examination, with roentgenograms of the colon, aids in making an accurate diagnosis. One of the earliest cases diagnosed in the Mayo Clinic was that of a physician who accidentally noticed a mass in his right side. The diagnosis was evident from the roentgenograms, and the operation was performed within a week of the discovery of the mass. The malignant nature of the tumor was demonstrated, and a resection was carried out. The patient recovered uneventfully, and is well after two years.

Actinomycosis often is not recognized until a sinus has formed and the "sulphur bodies" of the disease are demonstrated microscopically. A temperature curve and an increased leukocyte count, due to secondary infection, aid in the differentiation. A carefully taken history, with accurate roentgenologic study, generally outlines the underlying pathologic conditions. Brogden,[11] who recently reviewed the histories of fourteen cases of actinomycosis, obtained accurate data concerning ten. Six of the patients are dead, having lived, on an average, three years after the onset of the disease. One patient is apparently well after four years, with no evidence of recurrence.

Patients with hypertrophic tuberculosis often have associated pulmonary tuberculosis, and, on this account, an increase in temperature. The anemia is generally not so marked in the earlier stages of the dis-

11. Brogden, J. C.: Actinomycosis of the Gastro-Intestinal Tract: A Study of Fourteen Cases, J. Lab. & Clin. Med. **8**:180-189 (Dec.) 1922.

ease. Roentgenograms are the final means of accurate diagnosis (Figs. 1 and 2). In malignant conditions, a filling defect may be made out, and there is generally obstruction of some degree to the opaque meal or enema. Carman [12] asserts that it is not unusual for the inflow of the enema to be markedly or even completely obstructed; while the passage of a bismuth meal is apparently retarded only slightly, and the patient does not complain of constipation. The persistent filling defect is pro-

Fig. 1.—Filling defect of the cecum, caused by an extensive fungating carcinoma.

duced either by the projection of the growth into the intestine, or by fibrous contraction of the involved area of bowel (Figs. 3 and 4). Pain is an infrequent and untrustworthy symptom, varying in type from that associated with chronic obstruction to that of a dull, aching, annoying type. Obstruction is not always present, because the lesion is generally at the cecal junction with the ascending arm of the colon, and

12. Carman, R. D.: The Roentgen Diagnosis of Diseases of the Alimentary Canal, Ed. 2, Philadelphia, W. B. Saunders Company.

on its posterior wall; and is consequently remote enough from the ileocecal valve not to interfere with the proper emptying of the contents of the small bowel. In a fresh specimen, the location can be made out more easily and accurately than in one which has been subjected to preservatives for any length of time. In the latter, it is necessary to make multiple sections for microscopic study to determine the exact extent of the disease toward the ileocecal valve. Such sections have sometimes demonstrated an extension to the head of the colon and

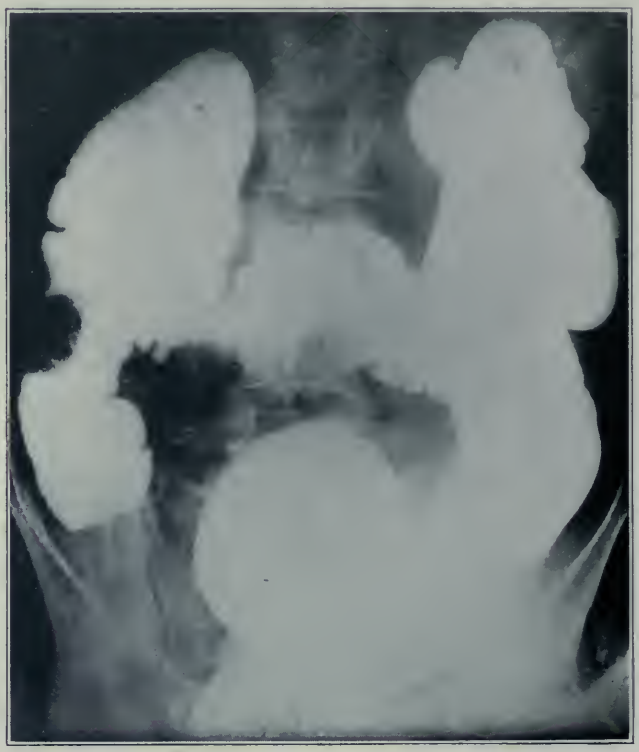

Fig. 2.—Constriction of the ascending colon, caused by an annular type of carcinoma.

ileum, but it is usually a direct extension along the mucous membrane and is not the site of the original lesion. Patients are occasionally able to feel the peristaltic waves go over the abdomen to the growth and then abruptly stop.

Blood in the stool is an inconstant symptom. There may be, and generally is, more or less disturbance of the bowel, sometimes a feeling as of failure to empty the bowel being manifested. The remote location of the growth and the fluidity of the content of the right half of the large bowel which, because of its very nature, does not irritate

or wound the mucous membrane as much as would the hardened feces of the left side, may explain the absence of bleeding in such a large percentage of cases. It has long been recognized clinically that the associated anemia, in which the hemoglobin is often as low as from 20 to 30 per cent., is not a contraindication to operation, as it generally is in other malignant cases. Such a reduction of hemoglobin, in a case of gastric cancer, for instance, almost invariably means either metastasis

Fig. 3.—Filling defect of the ascending colon, caused by flat, fibrous type of carcinoma.

to some other vital organ, or a growth which is inoperable because of its local attachment. Even in the event that the malignant process has not extended beyond its original site in the stomach, resection is a most formidable procedure attended with a high mortality rate, even in the hands of a skilful and experienced surgeon. This does not obtain in the case of the right colon, as has already been pointed out. It is questionable whether it is necessary routinely to institute measures for replacing the lost blood in the anemic cases. Generally, we have not

felt that transfusion of blood before operation is essential. This marked reduction in the blood, usually accompanied by a visible loss, and oftener than not unattended by demonstrable occult blood in the stool, has not as yet been satisfactorily explained.

Koons, at the Mayo Clinic, has recently reviewed the cases of malignancy of the proximal colon with special reference to anemia, and has brought out certain interesting facts. He found that the average hemo-

Fig. 4.—Filling defects produced by double lesion, hepatic flexure and transverse colon.

globin reading in cases of operation for cancer of the cecum and colon in the year 1921 was 61 per cent. Many of the readings, however, were below 30 per cent. The anemia, as a rule, was in direct proportion to the size of the growth. Ulceration, which is often found in the very large tumors, seemed to have relatively little bearing on the anemia. He mentioned a fact already known, that cancer of the distal colon did not produce nearly so marked an anemia as did a similar growth in the proximal half, despite the fact that ulceration and metastasis occurred earlier from the distal side. After reviewing the literature and experi-

mental work of many investigators on obstruction of the large bowel, he concluded that toxemia was produced which impaired the absorptive function of the mucous membrane of the bowel and resulted in severe secondary anemia.

OPERATIVE PROCEDURE

The method of operating on a malignant growth in the right colon easily divides itself into two stages: (1) exploration and mobilization, and (2) restoration of the continuity of the lumen of the bowel after removal of the primary growth and its lymphatics. The three types of restoration of the continuity of the bowel, namely, lateral anastomosis, end-to-end anastomosis and end-to-side anastomosis, have been popu-

TABLE 1.—*Summary of Results in Cases of Carcinoma of the Right Side of the Intestine*

Patients operated on at the Mayo Clinic (1910-1921).....	150	
Complete postoperative data on.....	133	
Patients living	57	(42.8 per cent.)
Deaths	76	(57.2 per cent.)
Patients living more than three years after operation....	62	(47 per cent.)
Postoperative period of life		57 patients living
From 10 to 15 years.....		13
From 5 to 10 years.....		30
4 years		6
3 years		7
From 1 year to 2 years.....		11
		76 deaths
1 month		23
From 2 to 12 months.....		32
From 1 year to 2 years.....		14
From 3 to 15 years.....		7

larized by various surgeons. Within recent years, the side-to-side anastomosis has lost its popularity and has been replaced by either restoration of continuity in the long axis of the bowel by end-to-end anastomosis of the bowel or by end-to-side anastomosis with a button for intestinal anastomosis, as advocated by C. H. Mayo.

A small percentage of the patients operated on at the Mayo Clinic had been examined elsewhere; and because of local attachment, the incision was closed without radical removal being attempted. Many of these patients, after a second exploration, were operated on radically if no metastasis was found, although the attachment to the abdominal wall made removal of a large segment of muscle and fascia necessary. It was necessary in one instance to remove the kidney, which had become pyonephrotic following the ligation of the ureter; but it was evident that the infection in the organ was present prior to the operation. Occasionally, in growths on the left side, it has been found necessary to perform a complete hysterectomy, removing the uterus

TABLE 2.—*Mortality and Results According to Type of Operation*

Postoperative period of life. Lateral anastomosis (50 cases)	
	Patients living
From 10 to 13 years	13
9 years	2
6 years	2
	17 (34 per cent.)
	Deaths
1 month	9
From 2 to 12 months	11
From 1 year to 2 years	3
From 2 to 3 years	5
From 3 to 4 years	3
From 5 to 6 years	1
15 years	1
	33 (66 per cent.)
End-to-end anastomosis (21 cases)	Patients living
From 4 to 9 years	7
3 years	2
2 years	1
	10 (48 per cent.)
	Deaths
1 month	4
From 2 to 12 months	6
2 years	1
	11 (52 per cent.)
End-to-side anastomosis with button (15 cases)	Patients living
6 years	2
5 years	2
2 years	1
	5 (33 per cent.)
	Deaths
1 month	2
From 2 to 12 months	5
From 2 to 3 years	2
4 years	1
	10 (67 per cent.)
End-to-end anastomosis (47 cases)	Patients living
From 4 to 9 years	11
3 years	4
2 years	8
1 year	2
	25 (54 per cent.)
	Deaths
1 month	8
From 2 to 12 months	10
From 1 year to 2 years	3
From 3 to 4 years	1
	22 (46 per cent.)

and adnexa with the malignant growth; but in resecting growths on the right side, this has not been imperative. The sacrifice of a large amount of muscle on the abdominal wall in radical operations, while followed in some instances by ventral hernia, is rarely attended by recurrence, even though the attachment has been of long standing. Occasionally, loops of small bowel have been so attached to the original growth as to necessitate double resection. Obviously, this increases the operative risk, but since this attachment is generally the result of an inflammation, and is not neoplastic, its presence does not necessarily contraindicate removal. Because of the tendency of the malignant growth to metastasize slowly, and because cachectic persons with a malignant growth in this location stand a formidable operation well in spite of loss of strength, it seems advisable to resect, even though a clinical picture is presented which in cancer elsewhere would almost preclude operative procedure. However, the cardinal rule that extensive attachment to vital structures, metastasis to the liver and marked obstruction are definite contraindications to resection must be considered before such a formidable procedure as extirpation of any segment of the colon is undertaken. The obstruction in the right colon is generally less marked than in any other portion of the large bowel, only 25 per cent. of the growths being annular and obstructing. The obstruction in this type of cancer is due possibly to the presence of scar tissue rather than to direct extension of the cancer around the bowel. W. J. Mayo, many years ago, called attention to the fact that the greater number of these malignant growths begin on the posterior wall of the bowel, that is, at its mesenteric border.

Mobilization.—This procedure, in the three types of operation, is identical. It is imperative that the operator should have an ample incision, so that he may not be handicapped by lack of exposure. The too common "digging operation" without adequate exposure results in involvement of the glands, spreads cancer cells over the raw surfaces, and often is followed by hemorrhages and peritonitis. The abdomen obviously should be carefully explored before radical extirpation is attempted. The liver is first carefully felt, and any nodules of a cancerous nature immediately rule out a radical resection. The presence of palpable lymph glands does not necessarily contraindicate removal. It has been shown so often that enlarged lymph glands are inflammatory, and that, other things being equal, the presence of enlarged glands should not contraindicate radical operation.

After removal of the growth and its neighboring lymphatics has been decided on, mobilization is most easily accomplished by first freeing two points, one at the head of the colon, and the other at that point in the transverse colon at which the anastomosis to the small bowel is to

be made. This affords two points of suspension which, with traction, bring the area to be removed into the field of operation as the other operative steps are taken. The outer leaf of the peritoneum which attaches the colon to the right parietal wall, and which does not contain blood vessels, is incised along the entire length of the cecum and ascending colon. The attachment at the head of the colon is freed, and a dissection downward along the muscles of the posterior abdominal wall is begun (Fig. 5). After the lateral leaf of peritoneum is severed, the dissection may easily be made with dry gauze, by wiping, toward the piece of bowel to be removed, the fatty tissues and their lymphatics which are to be included in the extirpation. Commonly at this juncture, in the male, the operator exposes the spermatic vessels and the vas deferens. These may or may not be saved. The right ureter sometimes comes into view, but it is rarely involved. It should be remembered that the ureter is rolled inward and upward with the peritoneum, and it may be included in the dissection unless it is carefully watched. Ligation or resection of the ureter is not usually attended by unpleasant consequences. As the dissection is carried upward toward the transverse colon, it should be borne in mind that the retroperitoneal duodenum is easily injured in its second portion. The blood supply of the right half of the colon is constant, and is generally located at the point of juncture of the right and distal half of the colon where the resection is to be made. The blood supply of the ileum is rich, and there is no difficulty from lack of blood supply in resecting a portion of the distal small bowel. It is advisable generally to remove from 20 to 30 cm. of the small bowel. The mobilization being completed thus far, and points of resection determined, the bowel is cut across with a cautery between the clamps and the cut ends are sterilized. It is advantageous now to cover as much as possible of the raw surface which has been left by the resection, and to suture the rent in the mesentery so as to prevent obstruction by loops of small bowel going through and becoming strangulated. The mesentery is sutured with fine catgut, the outer leaf of the peritoneum being employed to cover the posterior raw surface.

Lateral Anastomosis.—This is accomplished by inverting the two ends of the bowel with a purse-string suture, and making an anastomosis between a point on the superior longitudinal band of the colon and a similar point on the ileum opposite its mesenteric quarter. The operation may be carried out by suture, or by means of a button for intestinal anastomosis, as the surgeon prefers. This method has the disadvantage of leaving a blind pouch in each end of the severed bowel where feces

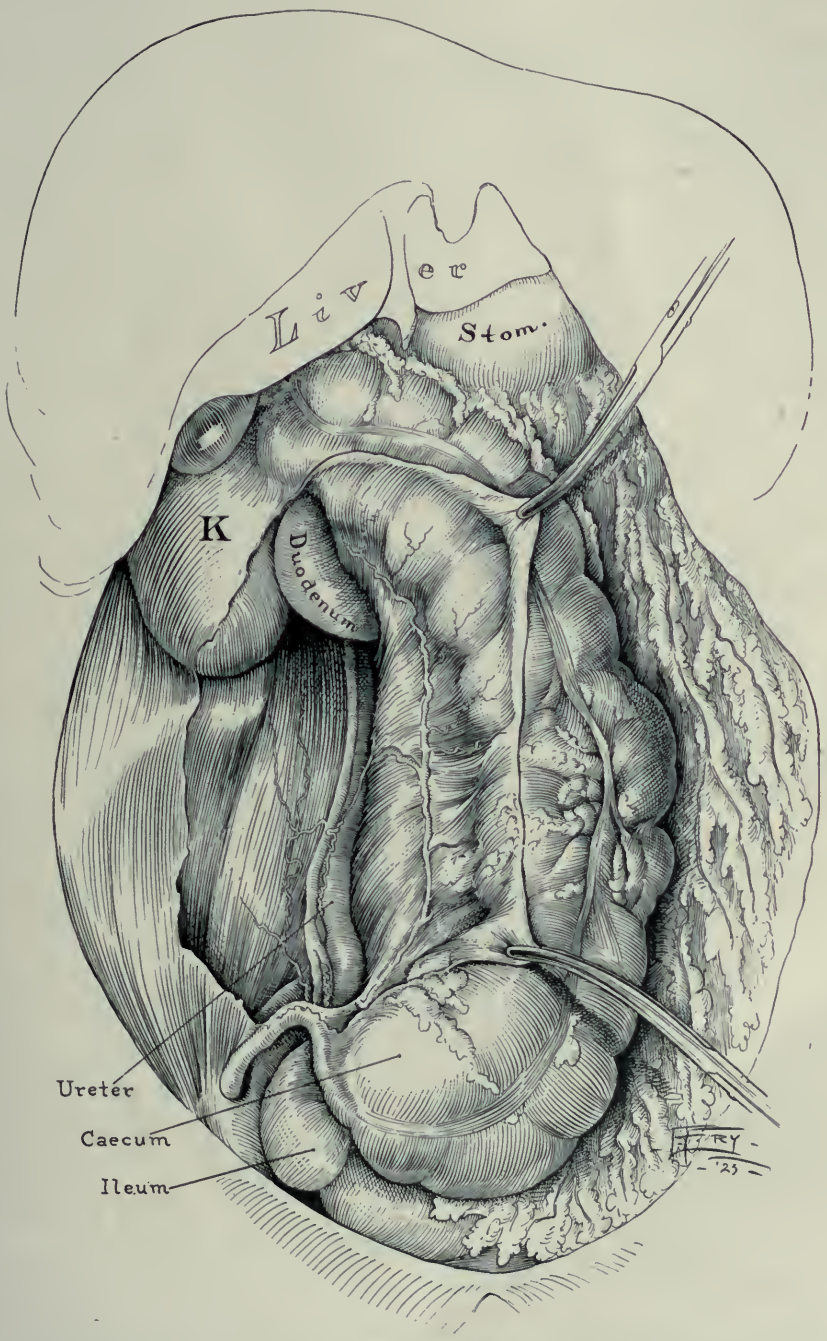

Fig. 5.—Division of parietal peritoneum with mobilization of cecum and ascending colon.

may collect. Horsley [13] has reported a case in which a dog died as a result of a small bone's becoming lodged in the blind end of the bowel. In lateral anastomosis, the longitudinal fibers of the bowel are split instead of being cut across, as in end-to-end anastomosis, and instead of propelling the ingesta through the opening, tend to contract it. Thus,

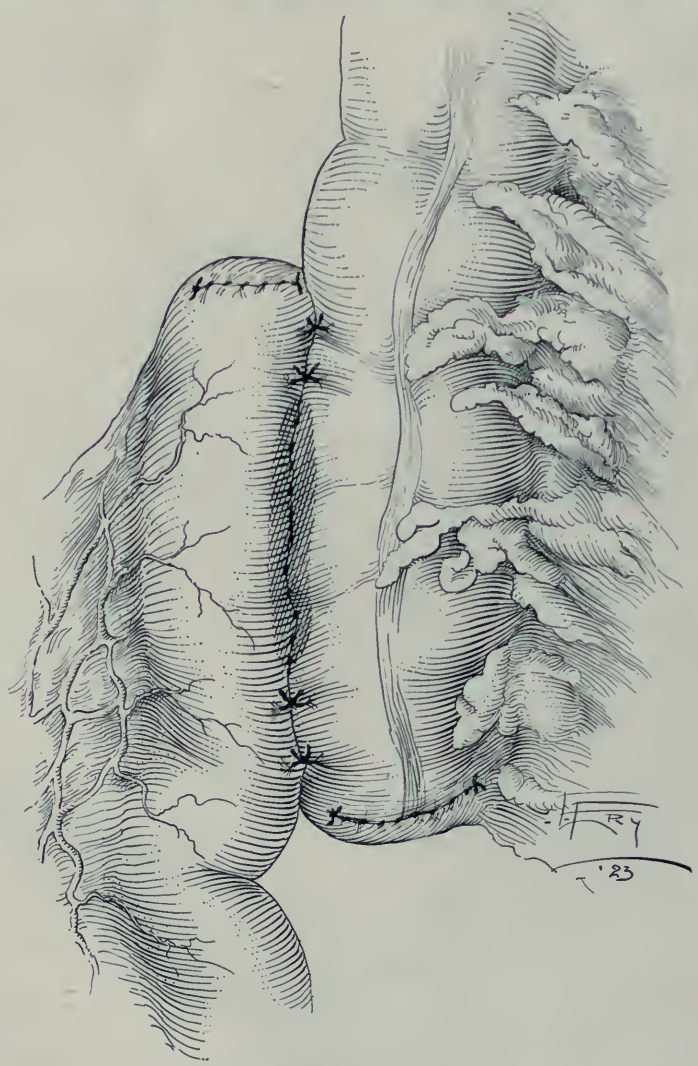

Fig. 6.—Lateral anastomosis of ileum to colon.

there is always present a certain amount of obstruction, which can only be overcome by the column of feces being forced through the anastomosis (Fig. 6).

13. Horsley, J. S.: Resection of the Cecum and Ascending Colon, Ann. Surg. **69**:25-30 (Jan.) 1919.

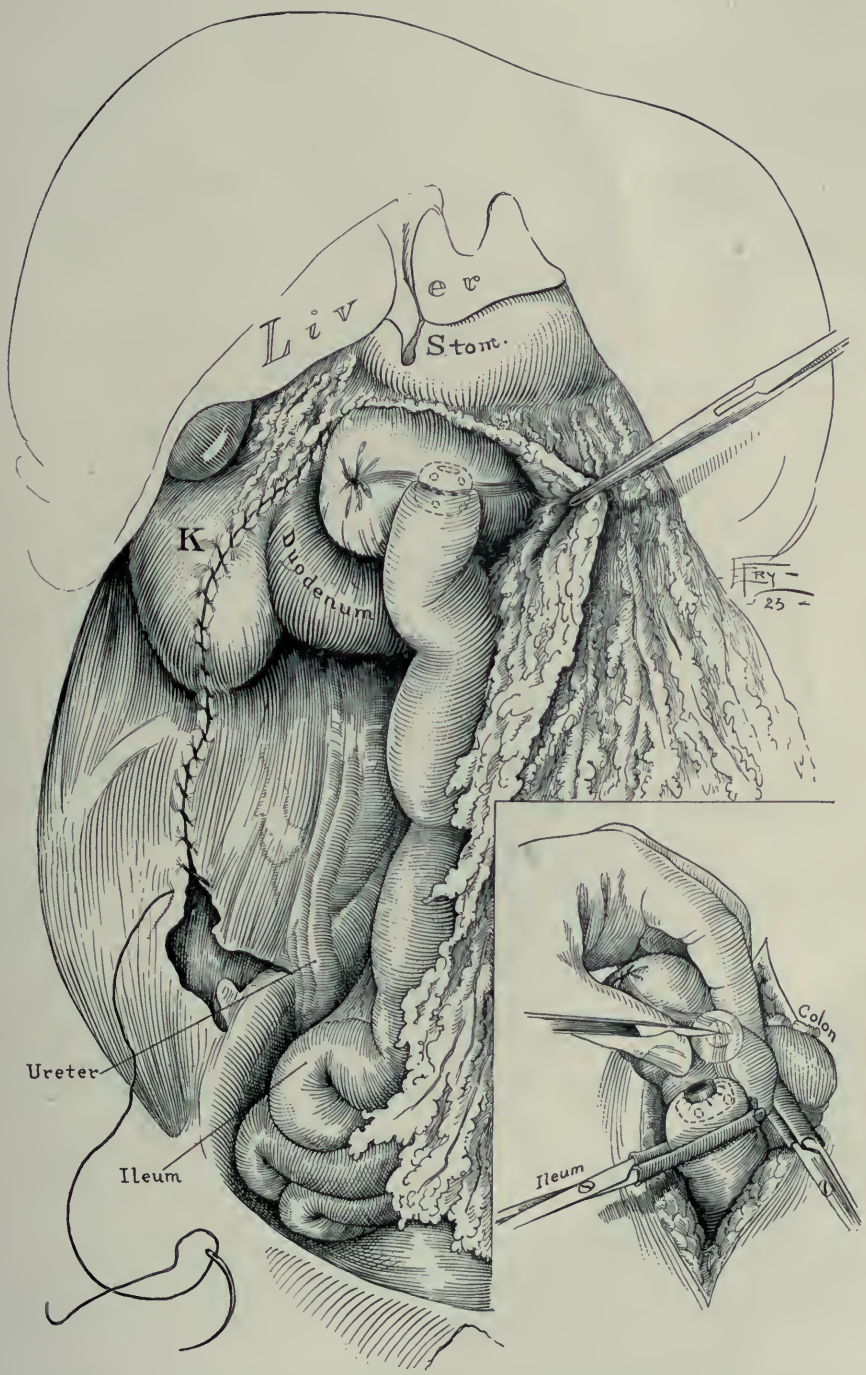

Fig. 7.—C. H. Mayo's method of end-to-side ileocolostomy. Insert: Method of approximating the two portions of button for intestinal anastomosis.

End-to-Side Anastomosis (C. H. Mayo's method).—After mobilization is completed, the mesentery of the small bowel is sutured to the mesentery of the colon so as to bring the cut end of the ileum easily to a point about 10 or 12 cm. above the cut end of the distal colon. The heavy half of a button for intestinal anastomosis, held in the fingers of an assistant at a point chosen for the anastomosis, is placed in the end of the colon. The light half of the button is placed

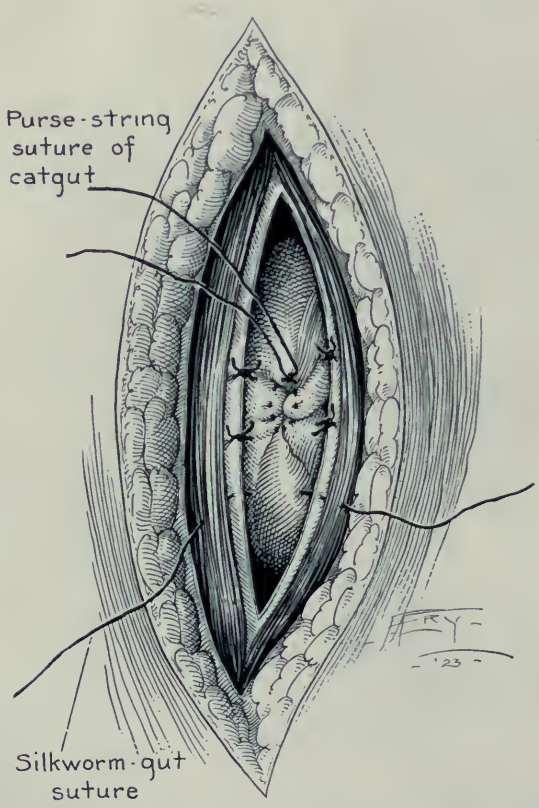

Fig. 8.—Colon attached to peritoneal edge, with catgut guide sutures left protruding from incision.

in the cut end of the ileum and held in place by a purse-string suture. A small opening is now made into the colon opposite a point where the button is held. The nose of the button is pushed through and fastened to its fellow, thus completing the anastomosis (Fig. 7). Whether or not a second layer of suture is placed over the site of anastomosis is optional. The cut end of the colon is now brought into the wound and sutured to the peritoneum. The catgut purse-string suture is allowed to protrude from the wound, so that it may be used as a guide in case it is deemed advisable to open the colon on account of gas dis-

tention (Figs. 8 and 9). The wound is closed except for a small opening down to the end of the colon, in which a wick of gauze is placed. In case of gas distention unrelieved by the rectal tube, it is a simple matter to follow with a small pointed forceps the track made by the gauze and the purse-string suture of the catgut, making an opening in the end of the colon to release the pressure.

This method has many advantages and the end-results have been the most satisfactory. It has the double advantage that it may be

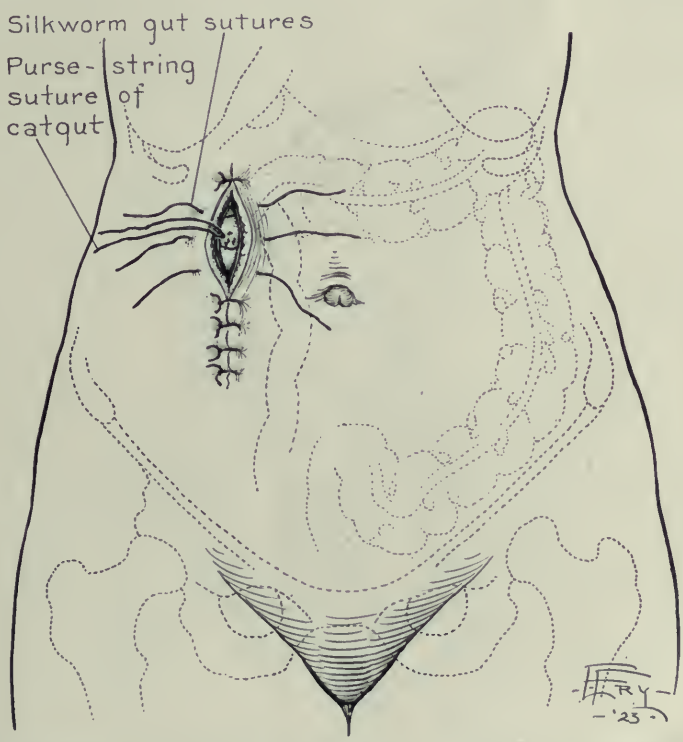

Fig. 9.—Method of attaching cut end of colon to upper angle of incision.

carried out either by suture or by a button for intestinal anastomosis, and at the same time the proximal end of the large bowel is brought up under the skin, where it may be easily punctured in case a safety valve for gas distention is necessary after operation.

End-to-End Anastomosis.—Mobilization being completed, as in the other operations, the two ends of the bowel are joined by direct suture, the mucous membrane first being approximated, and then the muscular and serous coats. Should the cut end of the ileum be found markedly disproportionate to the cut end of the distal colon, it may be made to approximate the proper circumference by splitting back through all

its coats opposite the mesenteric border, as suggested by C. H. Mayo (Fig. 10). This gives two openings of equal size which are exactly approximated. We have found that a continuous suture of chromic catgut makes an accurate closure, and prevents hemorrhage or leakage. The fingers of the operator are held in the opening as an obturator, preventing tight closure which might otherwise take place. A second continuous suture of chromic catgut closes the musculoserous coats and completes the operation. A third layer of silk may or may not be used to insure safety, but it has been our experience that, because of

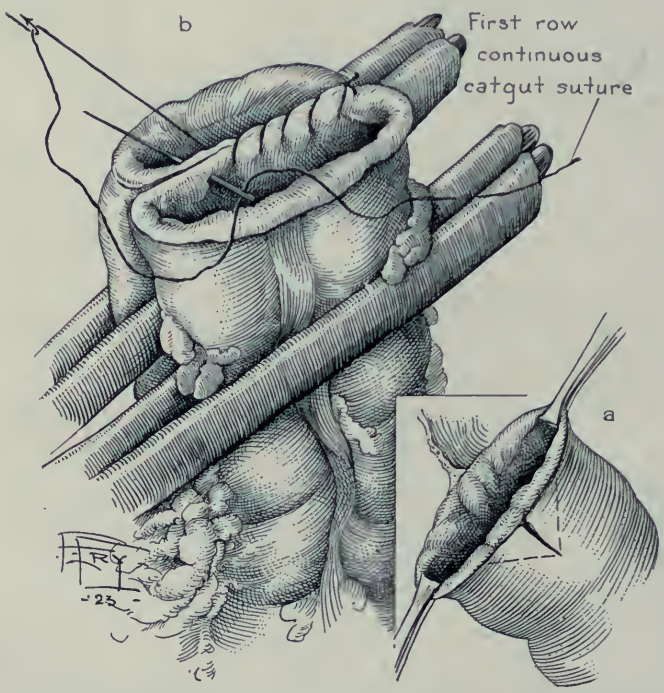

Fig. 10.—End-to-end anastomosis. Insert: Method of enlarging lumen of ileum so that it approximates the opening in the colon.

the slow healing in cases of malignancy, it is a wise precaution. No harm results from anastomosing the intestinal tract with silk, such as results from anastomosing the stomach and small bowel with this material.

This anastomosis is not, as was formerly believed, followed by stricture, because the various coats of the bowel can be approximated singly and accurately, and the two lumina can be made proportionately the same by enlarging the lumen of the small bowel, after the method of C. H. Mayo. The suturing is more easily and rapidly done, and in our series of cases we have had no leakage at what was formerly con-

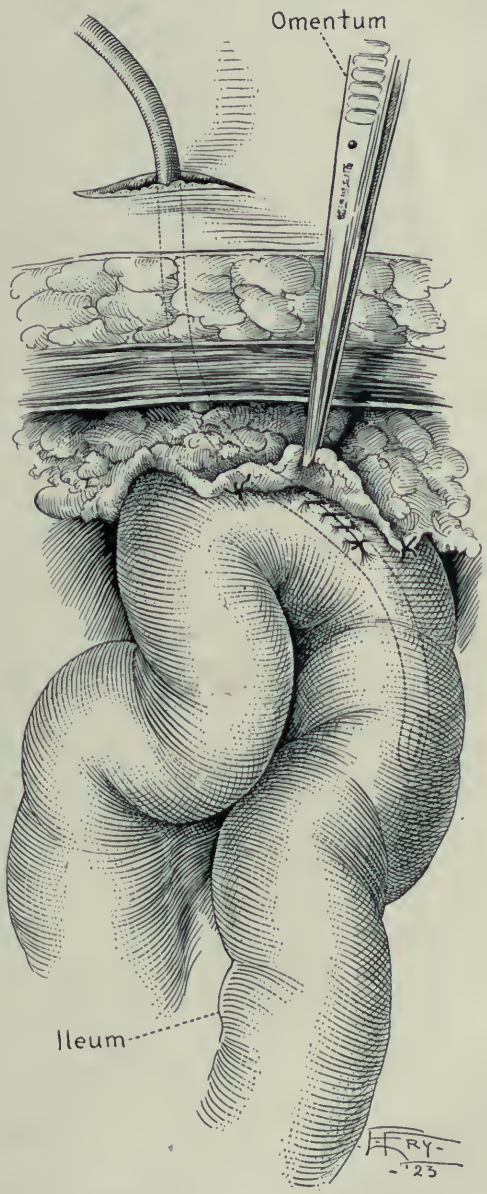

Fig. 11.—Ileostomy: The catheter is inserted opposite the mesentery, and is not opened unless there is need to relieve gas distention.

sidered the weak spot at the mesenteric border. Horsley has pointed out that leakage here is generally due to an infection in the cut surfaces of the mesentery.

In any of these anastomoses, lateral, axial or side-to-end, the omentum may be utilized by spreading it over the line of anastomosis. It is a valuable aid in preventing leakage and spread of contamination.

Following resection of the bowel, we have found it extremely advantageous to perform an ileostomy about 30 or 35 cm. above the site of anastomosis. This is done by a modification of the Witzel method. A small opening is made in the bowel opposite its mesenteric border, with a knife or Paquelin cautery, as advocated by Long. A No. 10 F catheter may be inserted, and a purse-string suture closes the opening around it. A layer of sutures buries it in the wall of the intestine for from 2.5 to 5 cm. (Fig. 11). The catheter remains closed until there is necessity to relieve gas distention. Death may result from general peritonitis due to leakage at the suture line, and gas pressure in the bowel is a potent factor in producing leakage several days after operation. It is often impossible to remove this pressure by enema, and we have found that an enterostomy, which may be quickly performed and adds little if any danger to the operation, is a most desirable maneuver in these cases. In only about one of four cases is it necessary to open the tube and release the gas, but when this is indicated, the effect is so marked as to make its adoption as a routine warranted. Fistula from the enterostomy does not occur if a very small tube is employed, with the Witzel technic. Generally, the tube drops out of its own accord, about the fifteenth day. We have always used fine silk to make this enterostomy.

POSTOPERATIVE TREATMENT

The postoperative treatment of these cases is most important. The rule that nothing shall be given by mouth or by rectum until the fifth day has proved highly satisfactory. It is unwise to employ proctoclysis because it not only places more stress on the line of anastomosis, but stimulates peristalsis markedly, as is easily seen in the Brown operation for colitis. Reverse peristalsis soon ejects the injected liquid from the open ileum. The increase of peristalsis in the peritoneal cavity obviously has the effect of spreading organisms. There is little difference, so far as increased peristalsis is concerned, in administration of fluids by mouth or by rectum. The body fluids should be obtained by hypodermoclysis of physiologic sodium chlorid solution, sterile water, or a 3 per cent. solution of glucose. Morphin in frequent and adequate doses should be given, not only to allay pain, but also to inhibit peristalsis. By rigid adherence to these postoperative principles, fewer

complications will arise, and cases which are long drawn out may terminate more favorably.

SUMMARY

The right half of the colon is readily mobilized, permitting good surgical exposure. This half of the colon is not essential to the life of the patient and its removal is not often followed by serious complications. Malignant tumors in the cecum and ascending colon metastasize late; consequently, the results of extirpation of the growth are good. If the cancer is in the right side of the colon, the best results are obtained by removing the right half of the colon and a portion of the ileum, following this procedure with an ileocolic anastomosis. The right bowel is mobilized by freeing two points, one at the cecum, the other on the transverse colon where the resection is to be performed. The peritoneal attachment of the right colon to the right abdominal wall is then divided, and the colon is drawn toward the middle line. The colon and the ileum are then resected between clamps.

There are several common methods of restoration of the continuity of the lumen of the bowel after removal of the primary growth. Lateral anastomosis may be carried out, either by suture or by use of a button for intestinal anastomosis. This method has the disadvantage that blind pouches are left in which feces may collect. In the end-to-side anastomosis, a button for intestinal anastomosis may also be used. The heavy portion of the button is placed in the end of the colon. In the end-to-end anastomosis, the two ends of the bowel are joined by direct suture, the mucous membrane and the serous coats being approximated with separate sutures. Following resection of the bowel, an ileostomy is made about 30 cm. above the anastomosis. This is not opened unless an emergency arises.

AN UNUSUAL ALTERATION IN THE NATURAL HISTORY OF A GIANT CELL TUMOR OF BONE *

W. S. STONE, M.D. AND JAMES EWING, M.D.
NEW YORK

It is the object of this communication to review the history of our knowledge of the giant cell tumor of bone, emphasizing its invariable failure to produce metastases; and to record a case in which this rule was broken in the case of a tumor which completely altered its original structural character and proved fatal, with pulmonary metastases, apparently as the result of repeated insults from attempted surgical removal, irradiation and infection.

Between 1840 and 1860, medullary tumors of bone received much attention from European surgeons and pathologists, and this interest culminated in 1860 in the appearance of an elaborate monograph by Nelaton,[1] in which nearly all that we now know about benign medullary tumors was clearly presented.

Before that time, medullary tumors were variously described and designated and vaguely interpreted. Ambrose Pare [2] recognized benign tumors of the maxillae which were curable by repeated excision. Under the term spina ventosa, the older authors included various neoplastic overgrowths of bone, and Beclard [3] (1827) described one variety which was medullary, vascular and not "cancerous." Warren [4] of Boston (1837) described benign and malignant forms of the vascular erectile tumors of the maxillae, as well as benign central tumors of femur and the tibia. Lebert [5] appears to have first recognized the giant cells in certain medullary tumors; which, however, he did not at first separate from malignant sarcoma of bone. The yellowish deposits in some of these tumors he described as xanthosis. In 1850, Robin [6] pointed out the existence of characteristic benign tumors of bone in which there were large numbers of giant cells, myeloplacques, of a type which he had (1849) identified in normal bone marrow. These cells are not the

---

* From the Memorial Hospital.

1. Nelaton: Tumeurs benignes des os, Paris, 1860.
2. Pare: Cited by Nelaton (Footnote 7).
3. Beclard: Elements d'anatomie générale, 1827, p. 167; cited by Nelaton (Footnote 7).
4. Warren: Surgical Observations on Tumors, Boston, 1837.
5. Lebert: Physiologie pathologique **2**:121, 1845.
6. Robin: Soc. de Biol. 1849-1850.

ordinary giant megakaryocytes of marrow tissue with mutilobed nuclei, but multinuclear giant cells found along the inner surface of the shafts of growing bones.

In England, Paget,[7] referring mainly to Lebert's [8] work, applied the term myeloid tumors to the growths containing giant cells, and showed that they were generally benign. This assertion excited a lively discussion among English surgeons, and from 1853 to 1860, they published a series of case reports which generally confirmed the view that the myeloid tumors, while recurring locally, generally failed to yield metastases; but they also recorded several cases which showed to their satisfaction that myeloid tumors occasionally proved fatal from pulmonary metastases. It will be shown, however, that they did not distinguish between the true giant cell tumor and the malignant, highly vascular, osteogenic sarcoma which often contains giant cells.

Nelaton's contribution [9] is so comprehensive and so full of accurate detail that it is worthy of careful attention at the present time. He emphasized the proliferation of giant cells, myeloplacques, as the essential factor in the process. He insisted that the giant cells must predominate in the tissue and not be present merely in small numbers, since such cells were occasionally seen in other tumors. The term myeloid he rejected as failing to designate accurately the histogenesis of the tumor. He recognized several anatomic varieties, depending on location, conformation, structure, and stage of evolution of the tumor: (1) typical, reddish brown tumors resembling muscle tissue or old blood clot, and solid or cystic; (2) fibrous forms; (3) yellowish tumors infiltrated with fatty material (xanthoma), and (4) very vascular tumors yielding pulsation or bruit and covering the majority of erectile or aneurysmal tumors of bone. The tumors were either medullary or periosteal in location. The age of incidence was mainly between 15 and 25 years. Without the aid of the microscope, diagnosis was usually impossible, especially with the fibrous and fatty varieties.

Regarding prognosis, Nelaton was quite specific. Every tumor composed essentially of giant cells should be regarded as benign. Even when the giant cells were mingled with cells infiltrated by, or associated with, fibrous tissue or cartilage, the tumor carried the same prognosis. A tumor in which the giant cells still predominated but were associated with a very notable proportion of spindle fibroblasts still had a chance of proving benign, especially in young, healthy subjects, but in such cases the histologic diagnosis was less absolute. It would doubtless vary with the relative prominence of the different cells, the age of the

7. Paget: Surg. Pathol., 1853.
8. Lebert: Arch. gén. de méd., 1853.
9. Nelaton: Gaz. d. Hôp., 1863, p. 25.

subject and various clinical considerations. Further observations were necessary to determine whether, with the advancing age of the patients, these tumors, ordinarily benign, might not reveal a malignant character a little more often.

Giant cell tumors had almost no tendency to remain stationary or to regress spontaneously. Simple extirpation was not to be relied on, since the tumor would generally recur if any fragment was left. Cauterization by zinc chlorid was recommended. Resection of the bone or amputation was often required. Nelaton discussed at much length the aneurysmal tumors of bone and concluded that the majority of them were vascular forms of the giant cell tumor. He denied the existence of true aneurysm of bone and, while he was evidently aware of the existence of malignant types of highly vascular tumors, he did not succeed in distinguishing them clearly from the benign forms. It is doubtful that anyone has even yet succeeded in this task.

In 1879, Gross described in detail the features of the giant cell sarcoma, analyzing seventy cases from various sources and emphasizing their benign character. However, after referring to the reports of the English surgeons, he concluded that these tumors occasionally produced metastases, and he thought that this fact was observed only with those tumors which showed multiple points of ossification.

Since that time, the benign character of the giant cell central or myeloid tumors of bone has been generally recognized, and the contrast with the malignant osteogenic sarcomas has been rather widely emphasized. Yet it has always been felt that the recognition of the benign tumors is often difficult or impossible, owing to the great variations in their gross and structural features, and, probably on this account, no consistent effort has been made in recent years to demonstrate that these benign tumors might occasionally produce metastases. The evidence on which this malignant property may be attributed to the giant cell tumors is found almost entirely in the older literature. It seems desirable, therefore, to review this literature in order to determine to what extent it is trustworthy.

Virchow [10] is often quoted, and correctly, as asserting the malignant behavior of certain myeloid sarcomas. Yet a careful study of his text fails to reveal any case in which a typical giant cell tumor produced metastases. Thus, he dismisses Gerlach's [11] case, which had been held to prove the malignancy of myeloid sarcoma, by finding it to be a true periosteal sarcoma. In Hutchinson's [12] case, a large tumor developed in four years in the upper end of the humerus of a man of 33

10. Virchow: Geschwulste **2**:332, 1864.
11. Gerlach: Ztschr. f. rat. Med. **6**:377, 1847.
12. Hutchinson: Tr. London Path. Soc. **8**:346, 1857.

years. This tumor was resected with the acromion and coracoid process. The axillary nodes were greatly enlarged, but proved to be inflammatory. A recurrence in the arm developed in a few weeks, and the patient died after five months, with pulmonary metastases. The original tumor was described as myeloid and fibroblastic, but many typical giant cells were present. In the lungs, the tumors were very cellular and Paget regarded them as cancer. Virchow states that the giant cells contained from one to three nuclei, which would indicate that the original tumor was a true osteogenic sarcoma. No illustrations accompany Hutchinson's report. Virchow acknowledges doubt as to the nature of the tumor. He also quotes as doubtful the case of Forster,[13] a large tumor of the fibula in a boy of 18 years, which produced rapid metastases in lungs and spine. In the sections of all the tumors, Wilks found bone tissue, and he concluded that the tumor was a mixture of osteosarcoma and myeloid sarcoma. He regarded as more convincing Henry's[14] case, a large tumor of the humerus which recurred after excision and gave multiple metastases in the lungs. Both the original tumor and the metastases showed much bone production, and it seems highly probable that the giant cells, with from three to fourteen nuclei, represented secondary changes in an osteogenic sarcoma. The case of Cock and Wilks [15] he accepts. Here a tumor of the upper end of the fibula in a man of 32 years led to amputation above the knee. Two years later, there was a recurrence in the stump of typical myeloid character, and a few days later the patient died, with bulky pulmonary metastases, the total duration being two years and seven months. No microscopic details were given, yet in the original report of this case we find that in one of the recurrent tumors there was central ossification. This feature is hardly compatible with what is known of the giant cell tumor.

It is to be noted that Virchow does not refer to any cases of his own in which typical giant cell tumors of the type described by Nelaton produced metastases. His conclusions were based on reports in the literature of the time, when it is apparent that a lively controversy had arisen over the assertions of Nelaton and Robin. We have looked up all these reports, except that of Gerlach (1847), which is inaccessible, and have received the same impression of doubt regarding their nature which Virchow acknowledges.

The more recent German literature is also credited with containing records of metastasizing giant cell tumors. Thus Escher, reporting on a series of bone sarcomas, refers to a giant cell tumor which recurred

13. Forster: Tr. London Path. Soc. **8**:389, 1857.
14. Henry: Tr. London Path. Soc. **9**:367, 1858.
15. Cock and Wilks: Med. Times & Gaz. **70**, 1859.

repeatedly over a period of seven years without metastases, but states that metastases of giant cell tumors have been observed by Krause and König.

Referring to Krause's contribution, we find that he records some remarkable cases of local recurrence which were cured by amputation, but he passes the responsibility for confirmation of metastasizing giant cell tumors to Oberst.

In Oberst's case, there was a rapidly growing, very vascular, cystic tumor of the lower end of the femur in a man, 21 years of age, which recurred promptly after excision and produced many large hemorrhagic metastases in the lungs. The peripheral portions of the metastatic tumors were well ossified. This case is evidently one of malignant bone aneurysm, or telangiectatic osteogenic sarcoma, in which the typical foreign body giant cells formed about blood masses. The original growth was extremely cellular, and the bone production in the pulmonary tumors proves the osteogenic character of the growth. Oberst himself regarded the case as a malignant bone aneurysm, and he felt that it belonged in a class intermediate between the benign giant cell tumor and the malignant forms of central sarcoma.

In König's Lehrbuch d. Chirurgie, 1881, the author refers to the oft quoted cases of Wilks and Oberst, but gives no detailed reports of his own.

Eve[16] quotes Kausch[17] as having observed a case of myeloid sarcoma which produced general metastases. On investigation, we find that this was a large tumor of the upper end of the humerus which involved 16 cm. of the shaft. No reference whatever was made to the histologic structure. The disease proved fatal within a year, with general metastases. The involvement of a large section of the shaft and the rapid course with fatal outcome are inconsistent with the diagnosis of giant cell tumor; while positive evidence of a giant cell tumor is entirely missing from the report.

Gross states unreservedly that certain myeloid sarcomas are malignant, and he supports this conclusion by referring to five cases in the literature, four of them also quoted by Virchow, and one reported by L. A. Stimson. He does not refer to any cases of his own observation.

Referring to Stimson's report, we find that the author described a large, rapidly growing tumor of the femur as a central osteosarcoma, in which areas of ossification were abundant, but large myeloid cells were present, especially about points of ossification. The metastatic tumors presented the same structure, but bone formation was even more prominent. It is clear that this tumor belongs in the group of

16. Eve: Proc. Roy. Soc., 1912.

17. Kausch: Beitr. z. klin. clin. chir. **68**:694, 1910.

osteogenic sarcoma and that the giant cells represented a secondary change in structure of a highly malignant tumor.

Gross made the significant observation that central bone sarcomas were very prone to be malignant if they were of the ossifying type, all the cases which he quotes, except Wilk's, being of this sort. Yet he found three cases of central ossifying sarcoma in which recovery followed operation (Bristowe,[18] Paget,[19] Nelaton[9]). Today, all these tumors would be classed as malignant osteogenic sarcoma, and excluded from the recognized class of benign giant cell tumor.

From a study of the earlier literature we must conclude that it does not contain any satisfactory record of a typical central giant cell tumor which produced metastases. The case of Wilks is a possible exception, but is too briefly reported to be convincing as to its exact nature. The considerable number of supposed metastasizing giant cell tumors reported about 1857-1859 seems to represent a popular effort to disprove the correctness of Nelaton's claims. Such reports apparently ceased abruptly after a short time. The older authors, it seems, did not carefully distinguish between central osteogenic sarcomas with active ossification and large blood sinuses, telangiectatic osteogenic sarcoma, and the characteristic benign giant cell tumor described by Nelaton.

In a general discussion of bone sarcoma by the Surgical Section of the Royal Society, 1912, Maybury[20] refers to two cases of myeloid sarcoma which proved fatal, with pulmonary metastases. The first case was that of a girl, aged 16 years, in whom a large tumor appeared at the lower end of the femur shortly after an injury. It did not pulsate and there was no egg-shell crackling. On incision, the tumor seemed to be composed chiefly of blood, but from curetted material, the diagnosis of myeloid sarcoma was made, and the leg was amputated. Nine months later, the patient died, with many pulmonary metastases. In the rather faint reproduction of the structure of the original tumor, there are many rather small giant cells which appear to us far from typical of the benign giant cell tumor; while many quite small giant cells and many more hyperchromatic polyhedral cells appear in the field. The pathologist Gough reported the tumor as a mixed cell sarcoma, most of the cells being spindle, but some irregular, round and giant, forms being found. Since reaching this conclusion, we find that Stewart,[21] after examining the sections in this case, pronounced the growth a malignant osteogenic sarcoma.

---

18. Bristowe: Tr. London Path. Soc. **7**:351, 1856.
19. Paget: Surgical Pathol. Ed. 3, 1870, p. 547.
20. Maybury: Proc. Roy. Soc., Surg. Sect. **6**:91 (Nov.) 1912.
21. Stewart: Lancet 2:1236, 1914.

In the second case, the neoplasm, which appeared in the os innominatum of a man of 46 years, proved fatal, with pulmonary metastases in the short period of eight months. Here again, the published photograph of the tumors shows giant cells of many sizes and types, mostly small, lying among many large hyperchromatic polyhedral tumor cells.

Without access to the sections, it is perhaps an impertinence to question the diagnosis in these cases, but it may at least be said that the data available in the publications do not permit the acceptance of these cases as genuine giant cell tumors of the type described by Nelaton and Robin. Moreover, the clinical histories of both these cases are so widely divergent from the usual story as to raise a grave doubt from this point alone as to their identity with the giant cell growths. Both were fatal within less than a year. This rapid course, as well as the occurrence of certain giant cells in the malignant telangiectatic osteogenic sarcoma, suggests that both these cases were of the latter type. Throughout this whole discussion, it does not appear that any of the contributors fully recognized the existence of this important type of malignant central sarcoma. The chairman expressed doubt that they had been correctly interpreted.

We have, therefore, been unable to find in the literature any authentic case in which the published record proves satisfactorily that a true giant cell tumor produced metastases. The instances in which metastases are supposed to have occurred, while widely quoted, are few in number. It appears that the authors have generally failed to recognize two ready sources of error in the recognition of giant cell tumors: 1. Very vascular osteogenic sarcomas producing bone may resemble in gross appearance the vascular giant cell tumors. 2. Typical foreign body giant cells of the epulis type may form about blood masses and detritus, and from other secondary processes, in many cases of malignant osteogenic sarcoma. As frequently stated, the diagnosis of benign giant cell tumor may not be based on the presence of giant cells alone, but must consider more particularly the type of the supporting tumor tissue.

The further conclusion that benign giant cell tumors have never produced metastases is by no means permitted by this search of the literature. It seems extremely probable that among the great number of these tumors subjected to repeated curettages some would yield cell emboli that would lodge in the lungs and continue to grow. Under these circumstances and in view of the fact that these tumors exhibit variable and sometimes considerable powers of growth, it is quite remarkable that metastases have not been clearly proved. That metastases have not been found emphasizes the rigidity of the laws often governing the growth of tumors, and serves to establish with

peculiar force the belief that these tumors are essentially benign to the extent that cell groups loosened from them are not viable.

In America, the facts established regarding giant cell tumors seem to have been largely disregarded for many years, and apparently most of these tumors were subjected to operation, until Bloodgood,[22] in 1910, called attention to the benign character of the disease. He recommended curettage with cauterization of the cavity; and he recorded eighteen cases successfully treated in this manner, contrasting the lesion briefly with malignant bone aneurysm, of which he cited three cases. In 1912, he recommended the use of the term giant cell tumor instead of giant cell sarcoma, observing that surgeons recognized only one form of sarcoma and that malignant, requiring radical surgical treatment. In 1919, he reported forty-seven cases of giant cell tumors without recurrence. The sole defect in Bloodgood's contributions seems to have been the failure to support his contentions by reference to the older literature, in which the same questions had been discussed thoroughly.

Barrie,[23] in a series of contributions, stressed the benign nature of the disease, emphasizing that the process was not a true neoplasm but a form of hemorrhagic osteomyelitis. While this interpretation may apply to the milder chronic processes, it certainly cannot be accepted in the more aggressive and destructive cases which are unquestionably neoplastic. An interesting feature of the more active giant cell tumors is their local aggressiveness, which sometimes supports the clinical impression of malignancy. Breaking through the capsule, they may travel along the intermuscular or fascial planes, but apparently never invade the muscle tissue; and they may fungate along the tract of incision made for diagnosis.

Bristowe found invasion of the veins of deltoid muscle by pulpy tissue of the same structure as the original tumor. When this patient died several years later from phthisis, no metastases were found. Virchow described a giant cell tumor which passed from the head of the fibula to the head of the tibia, by erosion of the latter. Langenbeck saw a tumor which passed from the lower end of the ulna to the lower end of the humerus.

Joint cavities are occasionally invaded by undermining of the cartilages, which allows collapse and rupture into the joint. Brodie saw the synovial fringes of the knee covered with tumor tissue. All these complications, however, belong to the most aggressive type of the disease, and are distinctly rare.

The advanced stages of giant cell tumors whose growth is undisturbed are seldom or never seen at the present time, since all these

22. Bloodgood, J. C.: Ann. Surg. **52**:145, 1910; **56**:210, 1912; **69**:345, 1919.
23. Barrie, G.: Ann. Surg. **71**:581 (May) 1920.

cases are interrupted by amputation or excision; but the older literature contains reports which show that, when allowed to progress to their natural termination, many of these tumors reach very large dimensions, and prove fatal from hemorrhage or infection, but without metastases.

Oberst refers to several such cases in which the tumors reached enormous size and proved fatal from hemorrhage, but necropsy failed to reveal any metastases. In three cases that he observed, two involving the upper end of the humerus and one the lower end of the femur, the patients died from exhaustion and marasmus, but failed to show any signs of metastases. Yet in the absence of roentgenograms of the lungs, these cases can hardly stand as demonstrative.

From Volkmann's clinic, he reports two cases of very extensive giant cell tumors of the humerus, requiring resection of the shoulder and the excavation of large masses of tumor tissue from the surrounding muscle, and yet the patients recovered and remained well for years.

Kraus also refers to a case in which a tumor of the femur reached very large dimensions and eventually gave rise to a fatal hemorrhage. In another case, the tumor recurred six times, but was finally controlled by excision.

The uninterrupted natural history of the more aggressive forms of giant cell tumors seems to terminate in death from hemorrhage and sepsis. Krause reports several cases of giant cell tumors of large size and long standing, in which the patients, refusing operation, eventually died from hemorrhage and sepsis. In a case reported by Brown, the patient died of erysipelas ten years after the appearance of the tumor (cited by Gross). Escher states that the giant cell tumor is essentially benign but that great danger arises when it becomes infected. He reports one case in which there was repeated recurrence over a period of seven years, but no metastases.

Nevertheless, spontaneous cure has been observed in a considerable number of cases, only a few of which seem to have appeared in the literature.

Recently, Jungling,[24] in discussing the effects of irradiation, warned against attributing all of the good results to the treatment. He refers to an observation of a central giant cell tumor of the head of the fibula in a woman of 27 years, which although it had destroyed the head of the bone, completely subsided after one year, the woman being well after four years.

Spontaneous cure probably occurred in Coley's Case 36,[25] a tumor of the femur, in which the patient refused amputation after diagnostic incision and was well four years later.

---

24. Jungling: Strahlentherapie **12**:192, 1921.
25. Coley: Ann. Surg. **45**:349, 1907.

The transformation of multiple giant cell tumors into bone cysts, recorded by Martland, represents a form of spontaneous cure.

Multiple giant cell tumors occurring in many bones of the body, and as a rule running a very slow course, have been described by Bloodgood, Barrie, Martland, Elmslie and others.

REPORT OF CASE

History.—J. N., aged 19 years, a chauffeur, admitted June 29, 1919, to Memorial Hospital, noticed swelling, tenderness and pain, for which he could assign no cause, below the outer side of right knee joint in February, 1919. As the pain and swelling persisted, he entered St. Luke's Hospital, where a tumor in the head of the tibia was removed, with curettage. The tumor area was very vascular and appeared to consist of a cystic cavity filled partly with soft reddish tumor tissue and surrounded on the outer side by a thin wall of bony tissue, which was partly removed. Section of this tissue revealed a typical giant cell tumor of epulis type. The patient was then referred to Memorial Hospital for irradiation.

Examination.—On admission, the right tibia was found to be the seat of a large cavity involving the greater part of the head of the bone. The inner surface was covered with clean looking granulation tissue, from which there was a serosanguinous discharge.

July 5: Roentgen-ray examination revealed a clean cut excavation of the head of the tibia, without periosteal involvement. The chest was negative (Fig. 4).

July 16: Forty-seven millicuries of radium emanation, in glass tubes wrapped in rubber and gauze, was placed in the cavity for forty-eight hours. A plaster cast was applied.

December 11: Roentgen-ray examination revealed some new bone formation, no widening of cavity and no further destruction of bone.

May 29, 1920: The patient returned, complaining of pain in the leg. The sinus was filled with soft tissue, resembling granulation tissue, and there is considerable redness of the skin about the sinus.

Operations.—June 4: The sinus was curetted, following which there was a sharp inflammatory reaction extending down to the ankle.

June 12: There were signs of typical osteomyelitis of the tibia, with a rise in temperature, due to the septic condition. There was an abundant purulent discharge.

June 30: Amputation was performed through the lower end of the femur, the wound being completely healed by July 28. The patient was allowed to go home.

After the patient left the hospital, his health steadily declined. Feb. 6, 1921, roentgen-ray examination of the lungs disclosed numerous rounded tumor masses scattered through both lungs. March 13, death ensued.

After the tumor had been subjected to surgical treatment, it would have been better if this treatment had been continued, with repeated curettages and amputation, if necessary. The great majority of these patients, with tumors of this histologic structure, escape infection and recover after several curettages.

The use of unfiltered radium in the tumor cavity was ill advised. It has seldom been followed, in our experience, with any good results. It was undertaken against our better judgment, but seemed preferable to a refusal to accept and treat the case referred by a colleague. It is our belief that the best treatment of the case would have been external irradiation without incision of the tumor.

In the period of several months which followed irradiation, infection became established in the tumor cavity. This infection and the failure

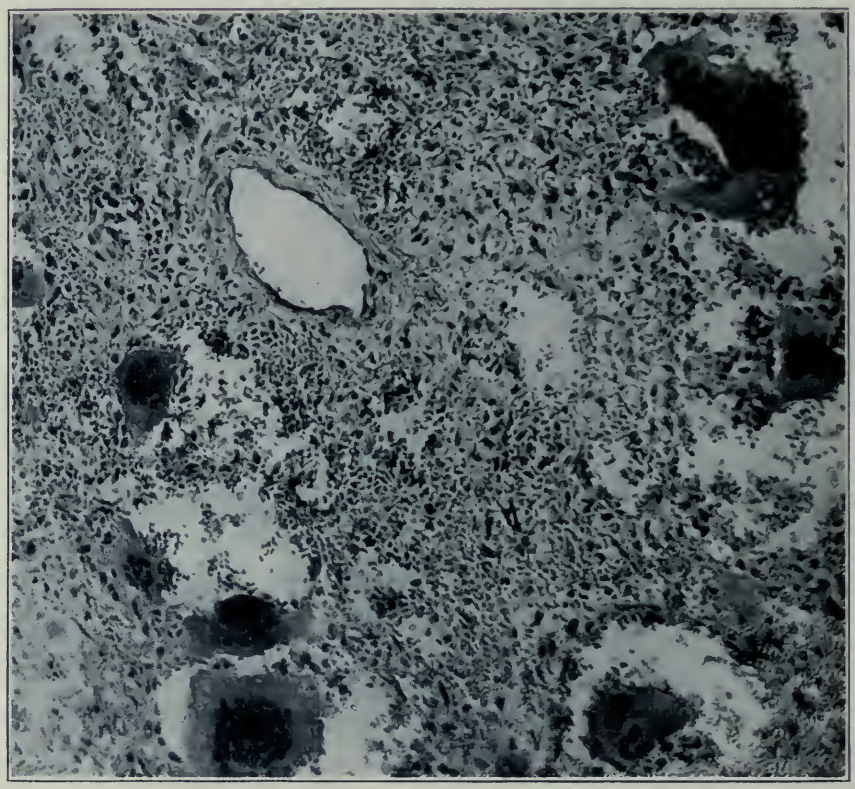

Fig. 1.—Structure of original tumor.

of the cavity to close was probably due to the effects of irradiation, which causes a chronic osteitis and often superficial bone necrosis, and thus offers a field favorable to infection.

The infection flared up as a result of the second curettage, and acute osteomyelitis and cellulitis developed.

In each of the two recurrent tumors, the growth became more progressive and more anaplastic and malignant. It is our belief that, during the second curettage or thereafter, tumor cell emboli of malignant character occurred and led to pulmonary metastases.

The case was referred for irradiation because Dr. F. C. Wood, pathologist of St. Luke's Hospital, believed that the tumor might possess malignant properties. His original report read: "Giant cell tumor. Osteogenic"; and amputation was recommended. This opinion was influenced by the presence of foci of forming bone trabeculae in the capsule of the tumor. The question is raised, therefore, as to the significance of traces of bone formation in the capsules of giant cell

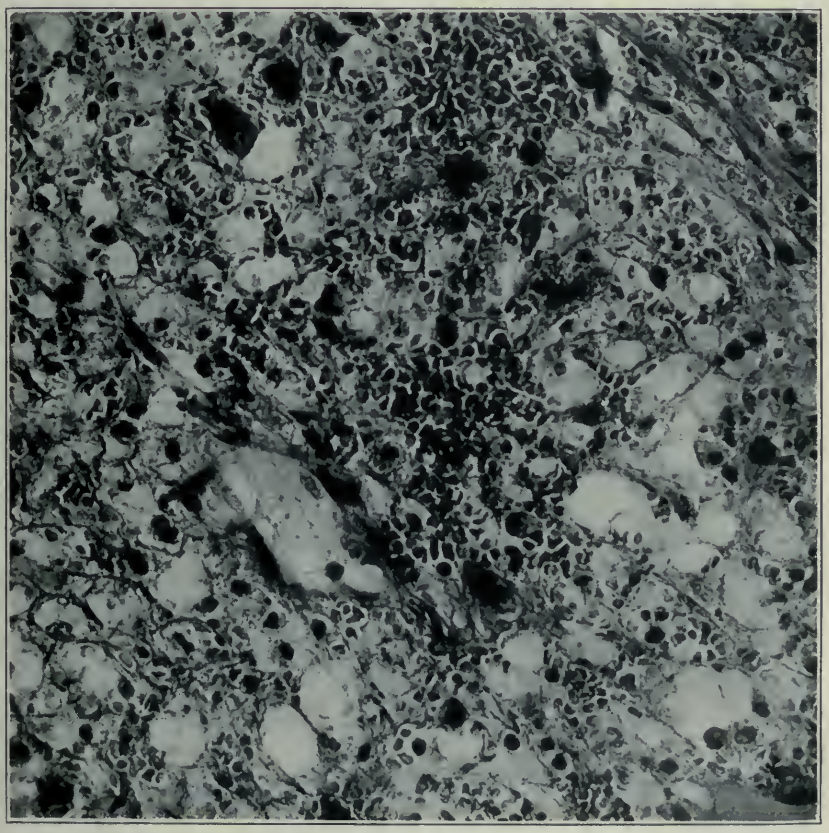

Fig. 2.—Structure of first recurrent tumor.

tumors, and on this point further experience seems desirable. It is our belief that such foci may usually be found in the capsules of giant cell tumors in cases attended by recovery. On account of the presence of such foci, and because of the occurrence of very cellular areas of spindle cells in certain giant cell tumors, many pathologists, we among them, feel compelled to recognize various grades of malignancy in the group of giant cell tumors; which does not, however, justify including them in the class of malignant osteogenic sarcoma.

The Structure of the Original Tumor.—The sections, kindly given us by the pathologic department of St. Luke's Hospital, show a structure which is typical of the benign giant cell tumor. It includes the bony capsule and the layer of tumor tissue surrounding the cystic cavity. The tissue contains abundant giant cells of large size, with five to twenty nuclei. These cells form rather compact masses along the edge of the tumor, and many lie deeper in the tumor mass. The accompanying spindle cells are scanty; their nuclei are not hyperchromatic; mitotic figures are missing, and the intercellular substance is fibrous. A few

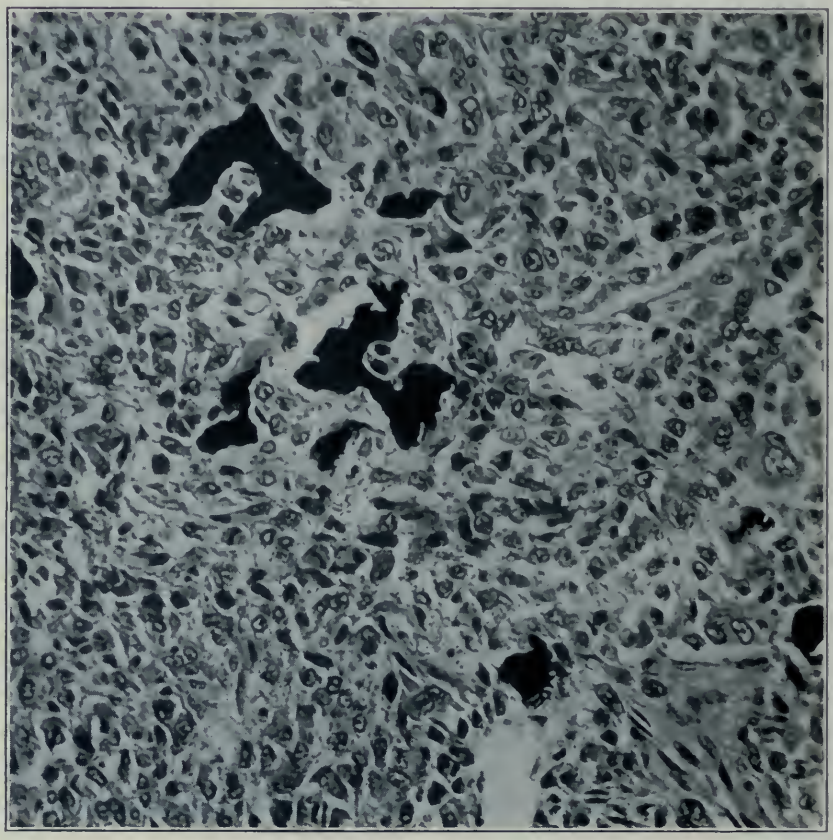

Fig. 3.—Structure of tumor in amputated leg, from which metastases probably developed. The black fragments are dissolving bone.

bone trabecula are found in the capsule, and these are surrounded by a moderate number of osteoblasts of normal type. There are no cell groups of atypical form or hyperchromatic nuclei; which might suggest malignant qualities. The sections have been submitted to several pathologists, all of whom have pronounced the growth a typical benign giant cell tumor (Fig. 1).

Structure of the Recurrent Tumors.—Twice during the treatment at Memorial Hospital, sections were made of the recurrent tumors curetted from the head of the tibia. On both occasions, the tissue was altered by exudative

inflammation, with edema, hydropic swelling of the cells and infiltration by polymorphonuclear leukocytes. In this material, the structure was markedly different. Giant cells were missing, and the tumor was composed of short spindle and of polyhedral cells which were markedly hydropic. Scanty mitotic figures were found, but the nuclei were not very hyperchromatic (Fig. 2). On these sections, a positive diagnosis was withheld, the sections of the original tumor not being at hand, and a guarded prognosis was given. It was felt that the tumor was not a simple giant cell process, but that it belonged to the group of relatively malignant central tumors that recur persistently and eventually

Fig. 4.—Roentgenogram taken of leg, on admission of patient to Memorial Hospital, showing central location, preservation of bony capsule and absence of periosteal involvement.

require amputation. It is now evident that the tumor structure had changed considerably in the first recurrence, and had acquired some malignant features, while losing the giant cells.

The Amputated Limb.—This presented a solid, opaque tumor mass occupying nearly all the epiphysis and about 4 cm. of the diaphysis, the lower border ending abruptly. Tumor tissue fungated through the original line of incision and slightly along the main sinus to the skin. Several suppurating tracts burrowed among the calf muscles. There was no subperiosteal growth, the tumor

being entirely medullary. The central portions were necrotic, and were partly excavated (Fig. 5). Sections of the tumor now showed solid sheets of large but rather short spindle cells, with very hyperchromatic nuclei and numerous mitoses. The intercellular material was scanty or absent and no giant cells could be found. The appearance was that of a definitely malignant spindle cell sarcoma, but the structure differed from that of malignant osteogenic sarcomas (Fig. 3).

Fig. 5.—Cross-section of amputated leg, showing tumor occupying epiphysis and portion of diaphysis, with sharply demarcated lower edge, without periosteal involvement.

Comparing the sections in the light of the clinical history, the conclusion seems imperative that, through successive recurrences and through the effects of inflammation, the tumor acquired increased powers of growth and changed its structure, with the elimination of giant cells.

It is unfortunate that, owing to the fact that there was no necropsy, the structure of the pulmonary tumors could not be determined. Their presence was clearly demonstrated by the clinical symptoms and the roentgenograms (Fig. 6).

Fig. 6.—Roentgenogram of lungs, showing multiple spherical tumor metastases.

SUMMARY

The record of the case presented is of interest from several aspects. The transformation of the structure of a benign giant cell tumor, while evidently very rare and not previously recorded in this disease, finds a parallel in similar transformations that have occurred in many other tumors, benign and malignant, after surgical and other forms of trauma.

The development of metastases in this case proves no exception to the rule that the benign giant cell tumor never produces metastases. Here, the metastasizing tumor was not a giant cell tumor, but a malignant growth that developed out of a giant cell growth, as the result of various insults, in which curettage and imperfect irradiation probably played the chief part.

Our search of the literature seems to show that there is no satisfactory record of metastasis of a giant cell tumor in its original form. That such metastases have not been recorded among the great number of these tumors that have been subjected to repeated curettages seems to us a matter of surprise.

The occurrence of metastases in this case seems to stand as a somewhat hazardous feature of the usual surgical treatment of the benign giant cell tumor and as evidence in favor of the treatment by external radiation.

The unfortunate outcome in this case suggests that the surgical plan of treatment, if adopted in these cases, should be adhered to, and that it is unwise to attempt to combine surgical methods with postoperative radiation by means of radium inserted in the tumor cavity.

BRAIN ABSCESS

WITH ESPECIAL REFERENCE TO ABSCESS OF THE FRONTAL LOBE *

HARRY HYLAND KERR, M.D., C.M.

WASHINGTON, D. C.

Abscess of the brain is a localized suppurative encephalitis of the cerebral or cerebellar tissues. It may be single or multiple, and any of the pus producing organisms may be the exciting cause. The condition is always secondary to suppuration elsewhere. While it most commonly follows infection of the ear or sinuses, it may arise from chronic infection elsewhere in the body. When an abscess is secondary to an acute condition, the primary infection is always in the immediate neighborhood. Brain abscess may follow traumatism of the head, as perforating fracture of the skull, or gunshot injuries. The traumatic type will not be considered in this communication.

The condition is usually seen in adults, but may occur at any age. According to Holt, brain abscess is rare in very young children. Suppuration in the ear or mastoid is by far the most common cause of abscess of the temporosphenoidal or cerebellar lobes. Frontal lobe abscess usually arises from infection of the frontal or ethmoid sinuses.

Although the discussion following includes brain abscess in general, because of certain difficulties that are encountered in the diagnosis of frontal lobe abscess particular attention is devoted to involvement of this area. It is generally conceded that abscess of the frontal lobe is relatively rare. In his recent book, "Brain Abscess," Eagleton gives an exhaustive review of the published cases, with bibliography. He found that not more than 150 cases of what he called adjacent frontal lobe abscess (abscess by direct infection) have been reported, while more than 900 cases of adjacent abscess of the middle cerebral fossa were found by him in the literature. Of these 150 cases, he analyzed 118.

We have analyzed 113 of these cases, and find that 44 per cent., or nearly half of them, were not recognized until necropsy. It is evident that there is need of careful study of all cases in the hope of improving the diagnosis of frontal lobe abscess. This study includes six cases observed by me.

Again, we find that we have an extremely high mortality, 75 per cent. As the mortality is much higher among patients operated on late, that is, in the terminal stage, the need of earlier diagnosis so that the condition may be attacked during the latent or more hopeful period is emphasized.

---

* Read at a meeting of the Southern Surgical Society, at Memphis, Dec. 14, 1922.

PATHOLOGY

On the invasion of the brain tissue with micro-organisms, a localized encephalitis is produced. The infection may reach the cranial contents by direct extension, as from an infected middle ear (adjacent abscess of Eagleton's classification), or by septic emboli from a distant chronic process (metastatic abscess). Direct invasion may occur through a phlebitis of the tributary veins of the thrombosed blood sinus or by osteomyelitis, localized meningitis and encephalitis. At the onset, the process is what used to be called "acute softening of the brain." The condition may progress with rapidly advancing symptoms, ending in death. On the other hand, when the local encephalitis has completely broken down, a pyogenic membrane may be produced which encapsulates the pus for a longer or shorter time (encapsulated abscess). In this way, a quiescent stage is produced, lasting over many months or even years. Eventually, however, one of two things occurs: The abscess ruptures, or a secondary encephalitic process starts, progressing rapidly to a fatal issue. Rupture of a brain abscess may occur when the presence of an abscess is not suspected, the resulting condition suggesting a vascular lesion. For anatomic reasons and because it is a so-called "silent area," the frontal lobe is peculiarly susceptible to this condition, as is illustrated in the following cases.

Case 1.—A. G., woman, aged 23, first seen, Dec. 8, 1921, in consultation with Drs. Hough and Burns, had suffered from headache for the last two years, more severe during the last three months. Three weeks before consultation, she had fainted in her office and since than had not returned to work. She spent some days in bed, on others she was up and around. Two days before consultation, she went, by street car, to have a roentgen-ray examination of the head made, at the suggestion of Dr. Gill. Involvement of the left frontal sinus and antrum was found. December 7, the patient had a convulsion in the morning, a second at noon and a third at night. A spinal puncture was made by Dr. Hough about midnight, from 20 to 25 c.c. of bloody fluid being withdrawn very slowly and intermittently. This was followed immediately by unconsciousness and apnea. Artificial respiration was started, and was continued until 4 a. m., when I first saw the patient.

The left ventricle was tapped from above, and a few cubic centimeters of bloody fluid spurted out under great pressure. The right ventricle was negative. With artificial respiration continued, the patient was transferred to Garfield Hospital, in an ambulance, where a left subtemporal decompression was performed under local anesthesia. The brain was found under great pressure, white and nonpulsating, and there was no bleeding from the cortical vessels. A right subtemporal decompression was immediately performed, with similar findings. Following the last operation, the cortical vessels bled freely and the brain became pinker. An intratracheal tube was introduced and attached to a positive pressure motor, and the air driven in at a pressure of about 10 to 15 mm. of mercury. Cyanosis and impaired heart action came on gradually, so that rhythmic pressure had to be applied over the chest in addition. Spontaneous respiration was never established. Cardiac action grew gradually weaker until death occurred, at 11:30 p. m., twenty-three and one-half hours later.

Necropsy revealed a small abscess, about the size of a walnut, under the anterior horn of the right ventricle, the abscess having ruptured, with hemorrhage into the ventricle. Both the lateral ventricles, especially the right, and the third and fourth ventricles were found filled with a recently formed clot. Some small scattered clots were found in the subarachnoid space around the base. The tip of the cerebellum on the right side showed a rimlike depression, as if it had herniated into the foramen magnum.

SYMPTOMS

The symptoms of brain abscess are general and focal. The general symptoms are those of an infection plus increased intracranial pressure. The chief complaint is headache. There may be vomiting, convulsions or stupor. Temperature in the latent stage may be normal or subnormal; when increased, it varies in degree according to the acuteness of the condition. Leukocytosis, usually of low grade, is common, but this also is occasionally lacking in the latent stage. As the process destroys the brain tissue rather than displaces it, pressure symptoms are usually inconspicuous.

Cerebellar Abscess.—When the cerebellum, the second most frequent site of abscess of otitic origin, is involved, one finds nystagmus, adiadokokinesis, a positive Romberg and a positive Bárány sign and respiratory difficulties.

Cerebral Abscess.—When the process occurs in the temporosphenoidal lobe, secondary to otitic infection, the following symptom-complex is seen: Abscess in the right temporosphenoidal lobe, in right-handed individuals, produces transient weakness of the lower left side of the face, diminished left abdominal and cremasteric reflexes, increased left deep reflexes and a left Babinski reflex. Abscess in the left temporosphenoidal lobe in right-handed individuals gives rise to the foregoing phenomena, plus sensory aphasia, difficulty in naming objects seen and recognized and word forgetfulness. A careful mapping of the visual fields shows the existence of an incomplete hemianopsia.

When the motor area is involved, jacksonian convulsions, followed by paresis or paralysis, point to the focus.

In occipital lobe lesions, subjective or objective eye symptoms appear. When the frontal lobe, the so-called "silent area," is affected, focal symptoms may be entirely lacking. Diagnosis of an abscess in this region is most difficult because there are no characteristic focal signs of frontal lobe involvement for the chronic cases and the signs in the acute cases differ very slightly from those of the causative, neighborhood lesion.

In the cases reviewed by Eagleton, clinical evidence of intellectual and psychic disturbances were generally found wanting. Change of disposition and poor memory, according to this author, may be present, although they have been but infrequently observed. Mental dulness,

stupor and coma may occur. Mental dulness and stupor were noted in four of my six cases. Headache was almost a constant symptom. Of the six cases, in one (Case 3) no record was made of this symptom. The patient was admitted for cerebral hernia following gunshot wound of the head. The hernia was caused by the pressure produced from a frontal lobe abscess. The decompression associated with the hernia explained the absence of headache. It was a pronounced feature of the five other cases. Convulsions occurred in three. There was evidence of increased intracranial pressure on fundus examination in all the cases. In four, there was a frank choked disk. This is contrary to the views expressed by Eagleton, who states that "in frontal lobe abscess, papilledema is rarely present.

The accompanying table gives the chief symptoms noted in the six cases.

DIAGNOSIS

In the early and acute stage, the diagnosis must rest on the evidence of intracranial involvement from a neighborhood infection and the elimination of other possible localization. Certain objective signs may be of great importance. Indeed, the localization of the lesion may rest entirely on these signs. In Case 2, Macewen's sign of altered percussion note and tenderness were the only positive signs of a right frontal lobe abscess.

Case 2.—A. K., boy, aged 15 years, referred to Drs. Campbell and Hough, Dec. 11, 1921, at 5 years had an acute otitis media on the left side, followed by persistent foul discharge. About two years before admission, there was some disturbance of the left eye, for the relief of which a submucous resection of the nasal septum was performed. Two months later, cerebrospinal rhinorrhea developed. This persisted unchanged for twenty months. Two months before admission, the rhinorrhea suddenly ceased, and pneumococcus meningitis developed. The patient recovered, following repeated spinal puncture. Two weeks before I saw him, headache and vomiting began. On examination, he showed slight elevation of temperature, and a leukocytosis of 16,000. Choked disk was developing. Neurologic examination was absolutely negative. Percussion, however, brought tenderness over the right frontal region, with a decided change in the percussion note. Roentgen-ray examination revealed nothing except increased intracranial pressure. The question of internal hydrocephalus following meningitis was considered, but the local tenderness and changed percussion note pointed to a right frontal brain abscess. Craniotomy in this region was performed. Several ounces of greenish pus (pure culture pneumococcus Type IV) was evacuated from an abscess about 3 cm. deep in the right frontal lobe. Drainage was maintained for six months and was followed by complete recovery.

With the history of chronic infection, especially of the middle ear or head sinuses, and of headache, choked disk, mild temperature and leukocytosis, plus the focal symptoms outlined above, the diagnosis of

Summary of Cases—Frontal Lobe Abscess

Case	Patient	Age, Years	Source	Organism	Length of Time Between Onset of Causative Lesion and First Symptom of Abscess	Time Between First Symptom and First Consultation	Symptoms	Complications	Operation	Outcome
1	A. G.	23	Probably infected frontal sinus and antrum	Unknown	Unknown	Over 2 years (chronic)	Convulsions, headaches, fainting spells, apnea following lumbar puncture	Rupture of abscess into ventricle	Subtemporal decompression, bilateral	Died 24 hours later; necropsy
2	A. K.	16	Cerebrospinal rhinorrhea	Pneumococcus	1½ years	16 days (acute)	Macewen's sign (right front), frontal headache, beginning choked disk, leukocytosis, vomiting, slight temperature, stupor	None	Craniotomy; drainage for 6 months	Well
3	W. M.	29	Gunshot wound of frontal lobe	Staphylococcus	Unknown (weeks)	2 years (chronic)	Cerebral hernia, convulsions, choked disk, vomiting, slight rise in temperature, fast pulse, paresis on left side, no headache	Cerebral hernia	Craniotomy; drainage for 2 months	Well
4	F. B. D.	17	Ethmoiditis	Staphylococcus, streptococcus	15 days	5½ months (chronic)	Convulsions, frontal headache, choked disk, leukocytosis, slight rise in temperature, mental dulness, diplopia, Macewen's sign (right front)	Surgical shock	Right frontal osteoplastic flap	Died several hours after operation; necropsy
5	M. S.	10	Infected naso-pharynx	Unknown	Days	4 months (acute)	Headache, choked disk, projectile vomiting, slight rise in temperature, leukocytosis	.....	Craniotomy during terminal encephalitis	Died 24 hours later; no necropsy
6	W. D.	28(?)	Frontal sinusitis and osteomyelitis of frontal bone	Streptococcus	7 months	Days (acute)	Leukocytosis, fever, headache, hemiplegia (right side), convulsions, aphasia, drowsiness	Extradural abscess, unrecognized	Exploratory craniotomy and drainage	Died 7 days after operation; necropsy

brain abscess, with the possible exception of abscess of the frontal lobe, can be made sufficiently early for surgical intervention to give a fair chance of recovery.

Because of the more or less complete absence of focal symptoms, abscess of the frontal lobe is likely to be overlooked until too late for surgical interference to save the life of the patient. The presence of infection of the frontal sinuses of the ethmoid, or orbit, should place one on guard with respect to the possibility of abscess of the frontal lobe. Persistent frontal headache in the presence of such infection, with good drainage, points directly to involvement of the frontal lobe. The other symptoms enumerated, together with a suggestive history, leave little doubt as to the diagnosis. In view of the small size of the area concerned in frontal lobe abscess and the consequent possibility of rupture before the abscess has attained sufficient size to give rise to the symptoms which would otherwise be manifest, suspected cases should be studied closely and operation performed before rupture occurs.

DIFFERENTIAL DIAGNOSIS

Brain abscess must be differentiated from generalized encephalitis, meningitis and sinus thrombosis. Lumbar puncture carefully performed is an aid in the differentiation. A high cell count, especially of leukocytes, points to meningitis. A slight increase in cells, especially lymphocytes, points to encephalitis. Percussion of the skull may elicit a higher-pitched note and tenderness, an aid to the diagnosis and localization.

TREATMENT

The treatment of brain abscess is surgical. When pus is located, incision and drainage must be made. The surgical principles are the same as for pus elsewhere in the body, but the means of evacuation and the after-treatment are very different.

Exploratory Craniotomy.—The diagnosis of brain abscess depends on a preponderance of either the general or the focal symptoms. If the focal symptoms are only suggestive or even wanting, an exploratory craniotomy may be indicated. Exploration should be made with the brain needle. A small trephine craniotomy under local anesthesia exposes the dura and permits the insertion of an exploratory needle in several directions to a depth of 6 or 7 cm. A blunt hollow needle made with a stylet and with several openings on the side should be used. As the pus may be under slight pressure, the needle should be inserted slowly and allowed to remain long enough in each suspected area to allow a possible thick pus to find its way out. In chronic abscess it will be necessary to force the needle through the pyogenic membrane. With the use of more than one brain needle, the exact location of the abscess can be determined.

If the abscess is in the neighborhood of a local bony infection, such as mastoiditis or frontal osteomyelitis, the question of exploration through the infected area or through a sterile field is to be decided. Each method presents its disadvantages. Exploration through an infected field may carry organisms into a sterile subarachnoid space, thus initiating a fatal meningitis. On the other hand, when there is a positive finding beyond a sterile region, infection may be carried from the abscess into a sterile subarachnoid space, with the resultant meningitis, though this is less likely.

The otologist is rather prone to explore through the infected wound. As a rule, the infection has reached the brain by direct extension; the underlying meninges have been agglutinated, and there is little danger of spreading the infection. A subdural abscess may even be encountered, which, of course, is best attacked by this approach.

In exploring through a sterile field, the increased intracranial pressure will have temporarily obliterated the meningeal spaces. A few hours packing outside the dura will produce adhesions sufficient to allow subsequent drainage without danger. This is illustrated by the following case.

Case 3.—W. M., man, aged 29, referred by Dr. Fritz Reuter, May 15, 1921, was suffering with cerebral hernia following a gunshot wound received two years previously. From the history and neurologic examination, it was believed that an abscess was present in the neighborhood. An exploration through a sterile field located pus at a depth of 4 cm. The brain needle was withdrawn and the extradural space packed with gauze. On removal of the packing in twenty-four hours, occlusion of the underlying meningeal spaces had occurred, allowing a free opening for drainage. Prompt recovery ensued, with a spontaneous cure of the cerebral hernia.

Local anesthesia is to be preferred.

In my opinion, an osteoplastic flap should very seldom be used to attack a brain abscess.

It is contrary to good surgical judgment to open widely the region most susceptible to infection—the subarachnoid space—to drain an abscess. If it cannot be reached through its own avenue of invasion, already occluded by a plastic meningitis, a more accessible route should be provided. Packing may be placed outside the unopened dura over as large an area as may be desired and left for twenty-four hours or more. This will produce sufficient intradural reaction to set up aseptic occluding adhesions and prevent the inception of an acute meningitis when the abscess is drained at a subsequent sitting.

When the abscess is located with the brain needle, either at the primary operation, through the already occluded meninges, or at a secondary operation, the needle should never be withdrawn until ample

drainage is established. A grooved director or similar instrument should be passed along the needle and the track gradually enlarged until a tube of sufficient caliber can be inserted.

In the chronic abscess with a firm membrane, it is wise not to allow the cavity to empty itself through the searching needle, for fear of collapse and the difficulty of again finding the lesion. I have never used the encephaloscope and feel that the additional trauma in its use is unnecessary.

With the increased pressure there is a tendency for a decompression through the craniotomy opening and extrusion of the drain. The type of drain used varies with different operators. Gauze packing, glass tubes, rubber tissue and rubber tubes all have their advocates. Tubes made of wire mesh were used in the British Army and have found favor in this country.

Two points must be emphasized: (1) Prevention of extrusion of the tubes in the presence of pressure and (2) prolonged drainage.

I have devised a tube which I have used for the last year with gratifying success. It is an ordinary rubber drainage tube with a rubber cuff fixed about 3 cm. from the end. The tube is split down to this cuff, and to each half a tape is sewed. When the tube is in place, the tapes are tied around the head and effectually prevent extrusion.

Once the drain is properly placed, it should not be disturbed. If withdrawn to be cleaned, there may be difficulty in replacing it, as its pathway may disappear within a few minutes in the soft cerebral tissue. The drain may be kept open by applying a dressing soaked in glycerin, or a small rubber catheter may be inserted through the drain daily and aspiration practiced. Irrigation is not indicated and is fraught with danger, but the instillation of dichloramin-T after aspiration helps, I believe, to overcome the infection.

No matter what form of drain is used, it should not be disturbed until all symptoms have completely disappeared, and then only to shorten it very carefully. For this reason, rubber tubing is advantageous. The danger of pocket formation at the bottom of the sinus and recurrence of the abscess are obviated if the tube is not cut off more than a length equal to its diameter. I would urge that drainage be maintained for too long rather than for too short a time. There is no *vis a tergo* of muscular action and movement which helps to squeeze empty a pus pocket in other soft tissues in the body; and we must rely entirely on the healing process to cure an abscess of the brain.

The accompanying table summarizes the six cases of frontal lobe abscess in which I have operated to date, including the three briefly recorded above.

CONCLUSIONS

1. Brain abscess in general is difficult of diagnosis and especially difficult of treatment.

2. Abscess of the frontal lobe of the brain has been recognized before death in only about one half of the reported cases.

3. The high mortality indicates the need of a more careful study of such cases.

4. Persistent headache, with sustained leukocytosis, and especially the presence of retinal changes indicative of pressure, in cases of drained frontal sinusitis or ethmoiditis, indicate exploration.

5. Exploration by the two-stage operation through a sterile field may be indicated.

6. Direct drainage with a minimum trauma should be established and should not be disturbed until all symptoms have subsided.

7. It is of paramount importance to drain a brain abscess for too long rather than too short a time.

THE TRANSFUSING OF UNMODIFIED BLOOD*

OSBORNE A. BRINES

Director of Laboratory, St. Mary's Hospital; Pathologic Chemist, Jefferson Clinic

DETROIT

This paper is presented after a study of 400 blood transfusions which I have given in the last two years. In the first 150, the citrate method was employed, and in the remainder, the direct method of giving whole blood. A comparison of the two methods is attempted and recent valuable contributions to the literature have been reviewed for the consideration of variations in technic and the explanation of phenomena relative to blood transfusions. The brief discussion of indications and results is an expression of various truths which cannot but be realized in a general way by the one performing the transfusions.

HISTORY

If we could consider in detail the history of blood transfusions we would be deeply impressed by the extremely interesting sequence of events which have led to present day achievements. At first, there were short periods of success, followed by long intermissions when the procedure was considered hazardous. Perhaps no work has been more successful and has produced more valuable results, or has led to greater disappointment, because the expectations have been so high and the imagination so fertile. Even though the technic was crude, early workers obtained some startling results and consequently they entertained earnest hopes of restoring health to all sick, and youth to the aged and infirm. For a while, transfusion assumed the aspect of a cureall, and false theories prevailed. Reference is commonly made to the first transfusion as being given to Pope Innocent VIII by a Jewish doctor in 1492,[1] blood from three small boys being employed. The result was fatal to all the donors, and the patient's life was not saved. That this was truly a transfusion has been disputed and probably justly so, because it seemes strange that one should have been thought of at that time, 124 years before the theory of the circulation of the blood was proposed by Harvey. Some believe that transfusions reported at this early date were nothing more, perhaps, than the giving of blood as a beverage.

---

* From the Jefferson Clinic.

1. Pemberton, J. deJ.: Blood Transfusion, Collected Papers, Mayo Clinic **10**:508, 1918.

Up to 1901, the methods of transfusing had been numerous but crude, and considerable difficulty had been encountered. Many serious and fatal reactions were produced and not more than 50 per cent. of the transfusions performed up to this date were successful. In France, at one time, transfusions were prohibited by law. Two factors were outstanding: first, the tendency of the blood to clot rapidly, and second, the hemolysis produced because of the incompatibility of bloods.

In 1901, the greatest stride in the history of blood transfusion was made when Landsteiner, followed by Moss [2] and Jansky, discovered the existence of isohemagglutinins and divided people into groups according to the agglutination reaction of their blood. Serologic perfection was followed by the surgical period in which Murphy,[3] and later Crile [4] and others, revolutionized blood vessel surgery.

METHODS

The evolution of blood transfusions has proceeded toward the attainment of high degrees of efficacy, rapidity and security. Different procedures have been followed which can be grouped under two headings: (1) the modified blood, and (2) the unmodified or whole blood methods. The former can also be called the indirect method because the collecting of the blood is usually a separate procedure from the giving, or it can be called the citrated method because sodium citrate is universally used to prevent clotting. It seems strange that sodium sulphate has not been used for this purpose, as it is a more efficient anticoagulant and can be administered in much larger doses than sodium citrate.

Citrate Method.—Since Lewisohn's [5] work in 1914, the citrate method has been essentially the method of choice; its application has been attended by phenomenal success, and it has been widely accepted and extensively used, so today the most valuable data we have on the clinical value of blood transfusions have been collected from those performed by this method. But, unfortunately, the coagulation of the blood cannot be retarded without alteration of some of its chemical and biologic properties.

---

2. Moss, W. L.: Studies on Iso-Agglutinins and Isohemolysins, Bull. Johns Hopkins Hosp. **21**:63-70, 1910; A Simple Method for the Indirect Transfusion of Blood, Am. J. M. Sc. **147**:698, 1914.

3. Murphy, J. B.: Resection of Arteries and Veins Injured in Continuity End to End Suture—Experimental and Clinical Research, Med. Rec. **51**:73-88, 1897.

4. Crile, G. W.: The Technique of Direct Transfusing of Blood, Ann. Surg. **46**:329, 1907.

5. Lewisohn, R.: Blood Transfusion by the Citrate Method, Surg., Gynec. & Obst. **21**:37, 1915; Med. Rec. **87**:141, 1915.

Sodium citrate has been observed experimentally to affect blood in several ways:[6]

1. It destroys the blood platelets, which apparently play an important rôle in the coagulation of the blood. The citrate method, then, would not be indicated when blood is desired for its hemostatic effect.

2. Added to whole blood in amounts necessary to prevent coagulation, it develops anticomplementary properties in the plasma, which can be demonstrated by an attempted Wassermann test. If, however, the same proportion of sodium citrate is added to the serum or plasma, and a Wassermann test is performed, noticeable anticomplementary properties cannot be demonstrated. This signifies that the salt in question must alter the blood cells, liberating in some way anticomplementary substances. Sodium citrate also destroys complement directly and reduces the phagocytic and opsonic powers of the blood. These facts would naturally argue against the use of the citrate method in the general infections when a resistance action is sought.

3. Sodium citrate increases the friability of the erythrocytes, a result not to be desired in the treatment of the anemias, especially those of the pernicious type.

4. The employment of sodium citrate in cases of severe hemorrhage produces undesirable results. Further reference will be made to this later.

In spite of the shortcomings of the citrate method, it is indeed valuable, and it is fundamentally simple. Most men can easily be trained in its use and acquire skill in the technic. The indirect method should never be discarded; but to those desirous of employing this method, it is suggested that the technic so often followed, namely, citration of the blood by allowing it to run into a graduate into which the citrate solution has been previously placed, stirring the while with a glass rod, should be abandoned in favor of one of several superior methods. Such a technic is crude because the prevention of coagulation is not effective; asepsis is not even presumed, and the blood cells are mechanically injured. For the citration and the giving of citrated blood, I would recommend that a simple but efficient apparatus be used, such as the one represented in Figure 1, which provides for the citration of the blood as it leaves the needle, prevents needless exposure to the air and eliminates the necessity of pouring the blood from one container to another. The withdrawal of blood by this method is simple and rapid. This apparatus, or one similar to it, can easily be made by utilizing a Potain aspirator.

---

6. Unger, L. J.: Precautions Necessary in Selection of Donors for Transfusion, J. A. M. A. **76**:9 (Jan. 1) 1921.

The unmodified or whole blood methods can be subdivided into two groups—the indirect and the direct. In the former, the principle differs from the citrate method in that, instead of a salt being added to the blood to act as an anticoagulant, clotting is prevented by allowing the blood to flow through and into an apparatus coated with a layer of paraffin or a mixture of paraffin and other substances such as stearin and petrolatum. This method was developed by Kimpton and

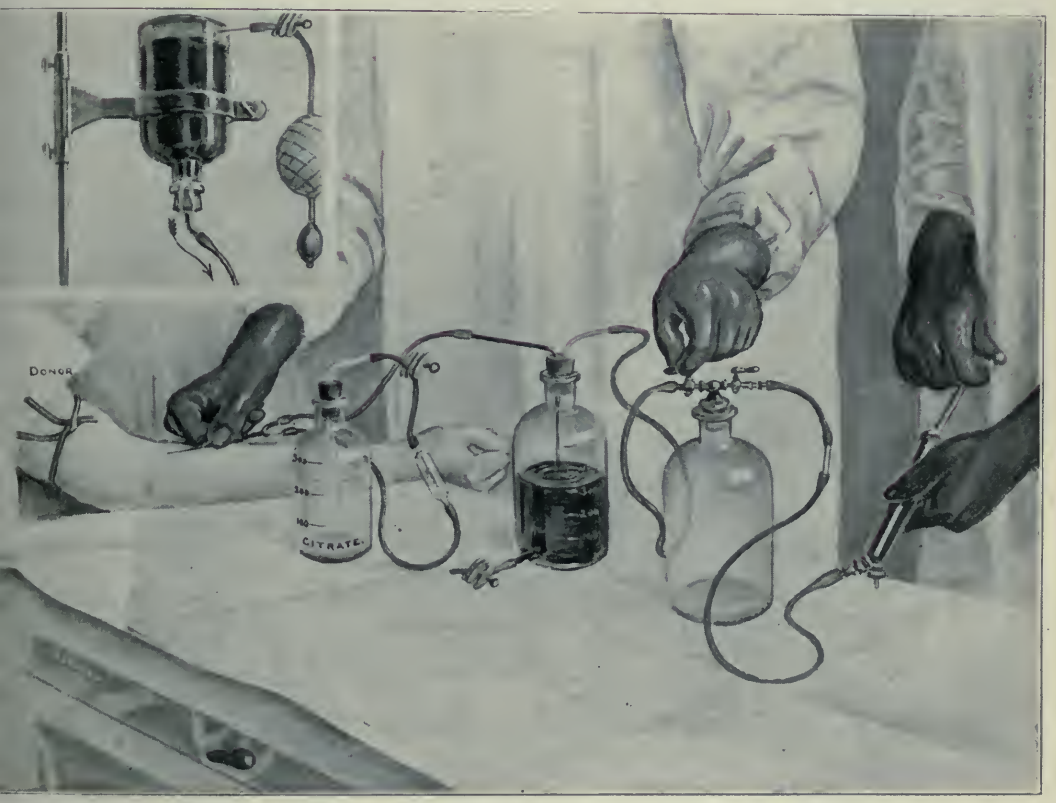

Fig. 1.—Apparatus for indirect method.

Brown [7] and is extensively used by Crile.[8] A high degree of skill is necessary completely to coat the tubes used, and the slightest flaw in the coating leads to an unsuccessful transfusion. In addition to the perfect familiarity with the technic which is required, an unwarranted measure of surgery is necessary, it being customary to make an incision,

7. Kimpton, A. R., and Brown, J. H.: A New and Simple Method of Transfusion, J. A. M. A. **61**:117, 1913.

8. Crile, G. W., et al.: The Thyroid Gland, Ed. 2, Philadelphia, W. B. Saunders & Company, 1922.

using local anesthesia, incising, and finally ligating, both ends of the veins of both donor and recipient, and thus unnecessarily increasing the liability of infection and subjecting the blood vessels to great injury.

Whole Blood Method.—The earliest technic of transfusing, that used before the compatibility of bloods was even considered, consisted in connecting by cannulas an artery of the donor and a vein of the recipient. This method has been recently reported as that followed at St. Elizabeth's Hospital at Richmond, Va.[9] The cannula method may be criticized on the ground that there is no way of accurately estimating the amount of blood passing from the donor to the patient. It is important to give known quantities of blood, and to discourage a knowledge of the quantity given is unscientific.

The greatest impetus to the development of methods of certainty in transfusing has been lent by the introduction of the multiple-way stopcock and the manufacture of syringes of a good quality, allowing the handling of known quantities of blood without danger of introducing large volumes of air. The practice of entering the vessels with needles instead of using the scalpel has removed much of the danger of infection and injury to both the donor and the recipient. When blood vessel surgery was resorted to, the number of times an individual could give or receive blood was limited. By the needle method, one donor frequently employed by this clinic has served for more than fifty transfusions in the last year and a half without any apparent alteration in the condition of his veins.

Of a large number of instruments which have been introduced embodying these improvements, none were entirely successful until Unger[10] devised an instrument consisting of a four-way stopcock providing for a flow of a small amount of saline through that part of the apparatus not in use. For example, when the blood syringe is being filled from the donor's vein, a small amount of saline (about 2 c.c.) is gently forced through the rubber tubing and needle leading into the patient's vein, thus preventing stagnation and consequent clotting of the blood in this part of the apparatus. While the blood syringe is being emptied into the patient's vein, the saline runs through the opposite side of the apparatus, i. e., toward the donor. This is the most important point in Unger's method, and distinguishes it as a successful procedure from the large number which are similar but unsuccessful. It is to be noted that neither the saline nor any other substance is mixed with the blood in the apparatus. The Unger apparatus is represented in Figure 2.

9. Horsley, J. S.; Vaughan, W. T., and Dodson, A. I.: Direct Transfusion of Blood, Arch. Surg. **5**:301-313 (Sept.) 1922.

10. Unger, L. J.: A New Method of Syringe Transfusion, J. A. M. A. **64**: 582-584 (Feb. 13) 1915; **69**:2159-2165 (Dec. 29) 1917.

TECHNIC

Before a transfusion it is, of course, necessary to consider the compatibility of the bloods with which we are dealing. The grouping of blood is dependent on the existence in the plasma of isohemagglutinins, of which there are two, A and B, providing for four possibilities: the presence of both, either or neither; or four groups. Furthermore, the cells of an individual are, naturally, immune to agglutination by the agglutinins of his own plasma. The determination of the agglutinins which will not agglutinate an individual's cells establishes his group.

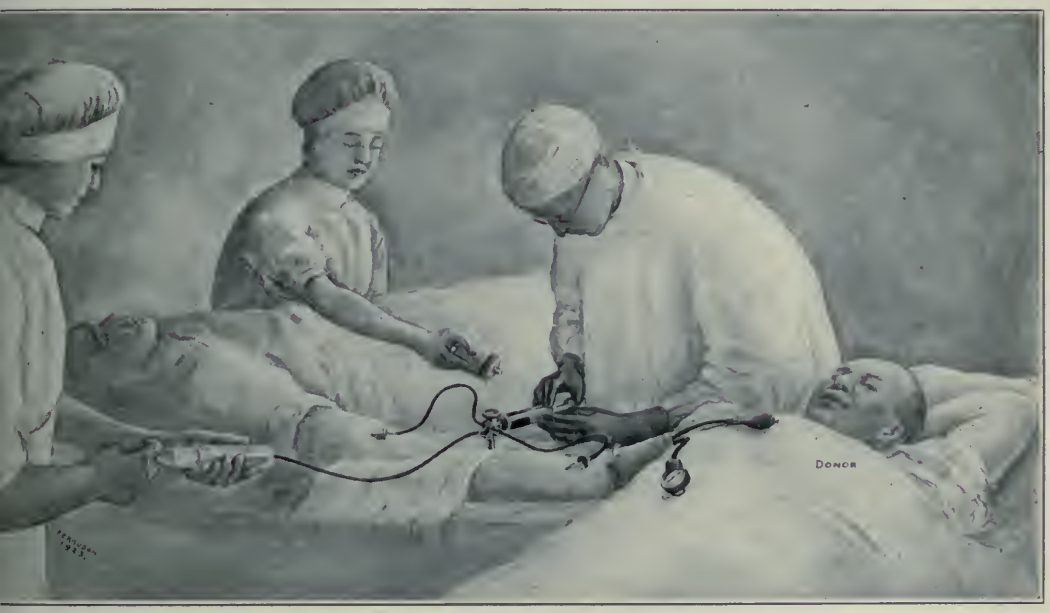

Fig. 2.—Operation of Unger method.

The question of the possible agglutinating of bloods is important because, as Landsteiner discovered about twenty years ago, agglutination always precedes hemolysis. We are principally, if not solely, interested in the behavior of the patient's serum, or rather plasma, toward the donor's corpuscles, because these are the only cells which may possibly be agglutinated in any ordinary transfusion. Even though the donor's serum is capable of causing agglutination when mixed in equal or almost equal quantities with the recipient's blood, it is so diluted by the patient's blood during the transfusion that its titer is then too low to produce clumping of cells. This fact enables us to use Group IV as a universal source of blood because the donor's cells, accustomed to the presence of both isohemagglutinins, are not agglutinated by the plasma of the recipient of any group. There are

those who disagree with this statement. Crile believes that 5 per cent. of Group IV individuals cannot be used as universal donors. But in this series of transfusions, fully 85 per cent. were performed with Group IV donors, irrespective of the type of the patient, without the slightest manifestation of any reason for not so doing. One Group II patient received thirty-seven transfusions for pernicious anemia with Group II and Group IV donors being used alternately, and no preference could be detected. Work done at the Mayo Clinic [11] has shown that, in their cases of pernicious anemia of Groups I, II and III, the patients were benefited to a greater extent by the blood of Group IV than by that from donors of their own group. So we have come to regard the typing of the patient largely as a matter of form, and we have chosen a donor of the patient's type only when it has been more convenient to do so, which is not often the case. We prefer professional or semiprofessional donors for the reason that they can be more carefully studied by the laboratory, and we are especially concerned with having a large list of available Group IV donors.

At St. Mary's Hospital, where most of our transfusion work has been done, it has been found advisable, before all serious operations, to group as many of the friends and relatives of the patient as possible before the operation, a first step in the preparation of a possible transfusion. The usual procedure is to group the patient first and then find a donor to match. We generally reverse this by first grouping the donors. If a Group IV donor is found we may stop there. If not, we then group the patient in order to find out whether or not the blood of the patient will match that of the available donors other than Group IV.

Theoretically, there are two possible instances when donors should not be chosen universally from Group IV: 1. When the agglutinating titer of the donor's plasma is greatly above normal, so that after diluting with the recipient's blood the potency would still be sufficiently high to cause agglutination. There may or may not be such individuals. I have never observed such a condition. 2. When such a large amount of blood is transferred from the donor to the patient that the concentration of the donor's plasma in the patient's circulation is still sufficiently high to cause agglutination. If less than about 800 c.c. was transfused, I do not believe that such a possibility would be worth considering, but if more than this amount were to be given from a Group IV donor to a patient of Groups II or III, it might be well to proceed with care. I have never encountered such a result, but the thing seems possible.

---

11. Ashby, W.: Transfused Blood; Periodicity in Eliminative Activity Shown by Organism, J. Exper. Med. **34**:127 (Aug.) 1921; Transfused Blood; Blood Destruction in Pernicious Anemia, ibid. **34**:147 (Aug.) 1921.

Blood groups are inherited and are not changed during life. We have repeatedly attempted to change the type of an individual by giving him a large number of transfusions of blood of a different group, containing agglutinins which his plasma does not possess, hoping to cause an accumulation of the foreign antibodies; but the attempts were unsuccessful.

In grouping an individual, one drop of blood is taken from the finger or lobe of the ear and mixed with 1 c.c. of physiologic sodium chlorid solution—not sodium citrate solution. One drop of this cell suspension is mixed thoroughly with one drop of each of the agglutinative serums to be used, separately, on an ordinary microscopic slide, according to the method of Vincent.[12] It should be examined both macroscopically and microscopically. I cannot agree with Ottenberg [13] that the microscope should not be used to note the presence or absence of agglutination. Agglutination cannot always be readily detected grossly, and use of the microscope is certainly not objectionable, because anyone should be able to detect pseudo-agglutination or rouleaux formation. An agglutinative serum is simply the blood serum of an individual of a known group. Three of these are used in our laboratory: one known to be Group II; one, Group III, and one, Group IV.

In this way, the action of the two isohemagglutinins on the cells is observed separately and together. For this test, I find it preferable to mix the agglutinative serums with the cells thus diluted rather than with a small amount of whole blood from the point of puncture; for it affords an opportunity to repeat the test or to make similar tests subsequently without obtaining more blood and, still more important, it guards against the use of a cell suspension which is too dense. Culpepper [14] has called attention to the value of filing the slides on which the test has been performed and thus establishing a permanent record of the test. He has also shown how agglutinating serums can be preserved by such disinfectants as tricresol. In addition to the indirect test just described, a direct matching should also be employed. This consists of testing a drop of the recipient's serum with a drop of the proposed donor's cell suspension. This is a valuable check because there seem to be occasional exhibitions of slight incompatibility of the

---

12. Vincent, Beth: A Rapid Macroscopic Agglutination Test for Blood Groups, and Its Value in Testing Donors for Transfusion, J. A. M. A. **70**:1219 (April 27) 1918.

13. Ottenberg, Reuben: Medicolegal Application of Human Blood Grouping; Sources of Error in Blood Group Tests, and Criteria of Reliability in Investigation on Heredity of Blood Groups, J. A. M. A. **79**:2137 (Dec. 23) 1922.

14. Culpepper, W. L., and Ableson, M.: Bloods Typed Using Moss's Grouping, J. Lab. & Clin. Med. **6**:226 (Feb.) 1921.

blood of two individuals of the same group, and for explanation of this phenomenon we find reference to major and minor, or chief and paragroups or subgroups. This condition probably does not exist as commonly as we are sometimes led to believe, but we should be prepared to detect such a phase when it does occur.

The grouping of blood requires the simplest of technic, yet many errors are made, with dangerous or decidedly undesirable results. Every precaution should be exercised. Fresh typing serums should be obtained, often because the older ones become deteriorated, and new serums should be tested before using to insure their being of the right group and of sufficient strength. The failure to detect weaknesses in the agglutinating serums is probably the greatest source of error, outside of gross carelessness. We employ a Group IV known serum to detect a sudden deterioration of Groups II and III test serums, which are usually employed alone. This has proved a valuable control. The use of desiccated and redissolved serum is dangerous. Ten minutes should be allowed for agglutination to take place; a greater length of time is undesirable. Every one should know the group of his blood and that of each member of his family. An emergency might easily arise when this information would be very valuable.

The direct blood transfusions here described have been performed by the Unger method, slightly modified, as shown in Figures 2 and 3. The patient and donor are placed side by side, with the heads in the same or opposite directions and the arms bared. Lack of space and facilities often alters this arrangement. Unger has drawn attention to the greater ease with which blood can be drawn from the donor if the needle is inserted toward the hand. This is often true, but it is considerably more difficult to insert the needle away from than toward the heart. Tourniquets are placed on the arms of both donor and recipient. The skin is disinfected by the usual antiseptics and aseptic precautions are observed. Any conspicuous vein may be used, but probably the median basilic or median cephalic are most frequently used.

Procain (2 per cent.) is injected intradermally at the site of puncture. Inserting the needles is the most difficult part of the procedure. The needles should be sharpened before each transfusion. It is desirable to have a number of needles of assorted sizes, ranging from 15 to 12 gage, and a size is chosen which seems to be consistent with the size and accessibility of the vein to be entered. No attempt should be made to pierce the skin and enter the vein at the same time; the needle should be placed under the skin first and then inserted into the vein as a separate operation. The needle must be placed squarely within the lumen and not through or crosswise of the vein. If, when the

vein is entered, the blood only drops from the needle and does not spurt out in a forceful stream, the attempt to enter the vein properly has been unsuccessful, and should be repeated at another point.

We have found it advisable to discard the hollow stylets which are fitted into the needles. Only a very small amount of blood is lost in inserting the bare needles, and this can be allowed to fall on a piece of gauze. A needle of the proper size is selected and placed in position in the vein of the patient's arm, first, because it is with the patient that the greatest difficulty is usually encountered. The tourniquet is removed and saline is allowed to flow into this vein while the other needle is being placed in the donor's vein. As a rule, a larger needle is used for the donor than for the patient. In place of a tourniquet on the donor's arm, a Tycos blood pressure apparatus may be advantageously used and inflated to about 70 pounds. It is allowed to remain in place during the transfusion and the pressure varied to provide the best flow of blood. More saline may be used than Unger recommends, or about 100 to 750 c.c. of blood transfused. This may be administered by means of a 100 cubic centimeter all glass syringe (Fig. 2) or by gravity (Fig. 3). This saline is not mixed with the blood, but is allowed to flow through the temporarily unused side of the apparatus to prevent stagnation of blood. Saline is the only substance other than blood that enters the blood vessels.

The plungers of the 20 cubic centimeter blood syringes are lubricated with sterile glycerine, and a fine stream of ether is allowed to play on the blood syringe during the transfusion. Both of these precautions are for the purpose of reducing the liability of the plunger to "stick," and to enable one to use the same syringe throughout the whole transfusion. The ether accomplishes this effect by cooling the blood immediately adjacent to the wall of the syringe and thus prolonging the coagulation period, but it does not noticeably lower the temperature of all the blood injected. It does, however, prevent the formation of a thin film of clotted blood between the plunger and the wall of the syringe.

Stiff walled rubber tubing should be used, and excessive suction or pressure should be avoided. New rubber tubing is used for each transfusion. A count of the number of syringefuls given is made by the person spraying the ether. At the end of the transfusion, the needles are removed and a sterile piece of gauze is placed and held firmly at the site of puncture. The time occupied by the actual transfusion is usually about ten minutes. In 200 consecutive cases, we have found it necessary to make an incision to expose the vein in only one instance, and this patient was pulseless. Even with veins difficult to enter, it has been found possible to perform every other transfusion within



Fig. 3.—Author's modification of Unger apparatus.

sufficient time. In case of extreme difficulty, when time is an important element, the vein may be exposed under local anesthesia, but the necessity of using the scalpel routinely has been eliminated.

In some instances we have used two and three donors in a single transfusion. It is then only necessary to remove the needle from the first donor's vein; flush the intake side of the apparatus with saline; substitute a new needle for the next donor, and proceed as before, allowing saline to flow into the patient's vein during the extremely short time required to change donors. Donors are required to lie quietly for about a half hour following the transfusion, and are urged to remain in the hospital for an additional three or four hours.

INDICATIONS

Blood transfusion makes operations possible for the seriously ill, the severely anemic, the jaundiced, the starved, the diabetic, the septic, the toxic and persons suffering from hemorrhage and shock. The indications for transfusion in surgical cases are numerous, and in medical cases they should be equally so, because there we have the so-called primary and secondary anemias, the infections, tuberculosis and hemorrhage.

Transfusion corrects disturbed circulatory balance; provides increased oxygen transportation to the tissues; increases, to a greater extent than do lactates, calcium salts or any other substances, the coagulability of the blood, and tides the patient over a critical period, until his blood-forming centers can take up their burden or he acquires the proper resistance. It combats infection by increasing the general resistance and by the bactericidal action of whole blood. It restores the bulk of the blood, but more especially the red corpuscles; and it is important to note that young erythrocytes are better oxygen carriers than old ones.

There are frequent instances when insufficient quantities of blood have been transfused; for instance, in a severe acute hemorrhage in which the patient has lost 2 or 3 liters of blood, it seems inadequate to give a pint. It would be better to use two or three donors and give 1,000, 1,500 c.c. or even 2,000 c.c., because the object is to restore most of the blood lost, in the shortest time possible, thereby eliminating the factors of shock and acapnia,[15] and replacing as completely and as quickly as possible the red blood cells, which carry oxygen to the tissues, remembering that hemorrhage is a form of asphyxia. By employment of a large amount of blood at once, the necessity of a second transfusion may be eliminated. This is desirable

15. Henderson, Yandell; Haggard, H. W., and Coburn, R. C.: Acapnia Theory. J. A. M. A. **77**:424 (Aug. 6) 1921.

because the incidence of reactions is greater in a second or in subsequent transfusions. At any rate, if a second transfusion is later found to be necessary, the patient will have received enough blood during the first transfusion to enable him to withstand a reaction well should one occur following a second or third.

RESULTS

Little need be said concerning the results; they speak for themselves. One needs but to witness the gratifying changes in many of those seriously ill following transfusion—the transformation of an almost lifeless patient into a bright, cheerful convalescent.

But, then, we must not lose sight of the possibility of a reaction—an important consideration, but by no means a necessary or a desirable sequence as some have believed. Reactions are usually characterized by all or some of the following symptoms, in somewhat the order given: slight headache; malaise; urticaria; slight fever; chills; nausea and vomiting; appreciable hemolysis; hemoglobinuria; difficulty in respiration; pain in the occipital and lumbar regions, and sometimes acute shock. The term "reaction" has been so vague and so loosely applied that it has been standardized by Drinker and Brittingham [16] as meaning the appearance of some of the above mentioned symptoms, accompanied by a rise in temperature of 2.5 degrees (F). It is a rare thing that such a rise in temperature following a transfusion is not accompanied by some of these symptoms.

Reactions are produced by:

1. Incompatibility of bloods. This is seen now only as a result of an error by the laboratory in the preliminary test.

2. Slight incompatibility of bloods, due to the supposed presence of paragroups, subgroups or minor groups.

3. The effect of sodium citrate.

4. Sensitization to foreign serums, such as horse, antistreptococcic, antidiphtheric and antitetanic, and the various vaccines, in the case of a first transfusion.

5. It has been observed by Levine and Segall [17] that a transfusion should never be performed within twenty-four hours after ether anesthesia, as the ether is thought to produce incompatibility of otherwise compatible bloods. I have not had the opportunity to observe this type of reaction, following postoperative transfusions, because at this

16. Drinker, C. K., and Brittingham, H. H.: The Cause of Reactions in Transfusions of Whole Blood, Arch. Int. Med. **23**:133 (Feb.) 1919.

17. Levine, E. C., and Segall, H. N.: Post-Transfusion Reactions, Surg., Gynec. & Obst. **35**:313 (Sept.) 1922.

hospital, anociassociation [18] has been generally the method of choice in major surgery, and no contraindications so far as the anesthetic is concerned have been noted.

In comparing the two main methods of blood transfusion, citrated and whole blood, the superiority of the latter method is striking. I have attempted to point out several ways in which the weight of evidence favors the giving of whole blood. And again in the phenomenon of reaction, the greatest difference is perhaps observed. Disregarding extreme statistics and considering only the more conservative figures, one finds reports of reactions following the citrate method ranging from 25 to 50 per cent., while those following whole blood transfusions are given as from 2 to 10 per cent. In our work, the incidence of reactions was reduced from 37 to 4 per cent. by changing from the citrate to the whole blood method; and, furthermore, the reactions following the latter method were very mild in comparison to those of the former.

The deleterious effect following employment of sodium citrate is undoubtably due to two things: (1) the action of the salt, principally on the red blood cells and to some extent on the protective bodies in the plasma, and (2) the fact that the hydrogen-ion concentration of the citrate solution may not correspond to that of the blood. Mellon [19] and his co-workers have called attention to the wide variation in the hydrogen-ion concentration of solutions prepared from different specimens of sodium citrate, and have shown, in addition, that the reaction of many solutions, and even of distilled water, changes on aging. A technician in Mellon's laboratory, after witnessing a severe reaction following a citrate transfusion, allowed herself to be given a transfusion of her own blood mixed with an unused portion of the citrate solution from the previous transfusion, and a similar reaction occurred. It was later found that this citrate solution possessed a hydrogen-ion concentration of approximately p_H 12.

Yandell Henderson,[20] in his interesting work, has shown the comparative effects of administration of several solutions intravenously, following extreme hemorrhage. He established a standard hemorrhage in dogs by bleeding the animals systematically until the blood pressure was 28 mm.; a state in which the dog was about as apt to live as

---

18. Blain, A. W.: Nitrous Oxide-Oxygen Anesthesia in Major Surgery, J. Michigan M. Soc. **21**:456 (Nov.) 1922.

19. Mellon, R. R.; Slagle, E. A., and Acre, S. F.: Practical Application of "Buffers" in Regulation of Hydrogen Ion Concentration in Intravenous Solutions, J. A. M. A. **78**:1026-1029 (April 8) 1922.

20. Henderson, Yandell, and Haggard, H. W.: Hemorespiratory Functions; Respiration and Blood Alkali During Carbon Monoxid Asphyxia, J. Biol. Chem. **47**:421 (July) 1921.

it was to die. He then administered sodium citrate solution, and the dogs died in every instance. He gave saline intravenously, but, following a temporary improvement, the mortality was increased; and, following injection of acacia solution,[21] much the same result was observed. After the administration of compatible whole blood, the animals recovered in every instance.

SUMMARY AND CONCLUSIONS

1. A greater degree of care and accuracy should be exercised in choosing donors.

2. Group IV donors may be used universally.

3. Sodium citrate is harmful, chemically, biologically and physically, in blood transfusions, and some fatalities have followed its use.

4. Reactions are fewer and milder following the whole blood method than following the citrate method.

5. One by one, most workers are deviating from the citrate method and turning to the whole blood method.

6. While the citrate method should not be abandoned, the whole blood method should, whenever possible, be substituted for it; however, there is never a time when citrated blood is as good as whole blood.

7. The Unger method seems to be the most simple and most generally successful for the giving of blood directly.

8. This method insures promptness, as no time need be consumed by preliminary details or arrangements.

9. It is most desirable that transfusions be performed in the operating room, yet the procedure may be successfully carried out in a private room or ward, or even at the patient's home, with comparative ease, though there might be slight inconveniences arise.

10. With the proper listing of professional or semiprofessional donors, it should be easily possible to perform a direct transfusion in any part of a large city on a notice of one hour.

2201 Jefferson Avenue East.

---

21. Bayliss, W. M.: Acacia for Transfusion, J. A. M. A. **67**:1885-1887 (June 17) 1922.

EMPYEMA NECESSITATIS AND SOME ALLIED CONDITIONS *

FREDERICK J. TEES, B.A., M.D.
MONTREAL

An exercise in anatomy which may be undertaken with profit is provided by a consideration of the influence exerted by the more resistant tissues of the body in controlling the spread of pus.

A recognition of the importance of this influence is no doubt responsible for the time-honored emphasis placed on certain structures, such as the deep cervical and the pelvic fascia, which have long been a source of mystification in the dissecting room. The importance of these structures almost warrants the care that is devoted to their demonstration, for a knowledge of the possible directions in which pus is likely to travel and to "point," in the neck, in the pelvis and elsewhere throughout the body is of more than speculative interest.

The recent occurrence of some unusual cases of purulent pleurisy prompted a consideration of the possible consequences when a purulent effusion in the pleural cavity is for one reason or another allowed to follow its own course. With improved methods of diagnosis and the closer cooperation existent between the physician and the surgeon, such sequelae are becoming less and less familiar; but when the condition is not recognized, or when operative measures are unduly delayed, provided death does not ensue from toxemia, septicemia or exhaustion, any of the following events are among the possibilities.

In a limited number of cases, recovery seems to occur. A small effusion may become absorbed or encapsulated. Cases of natural cure are occasionally found in the necropsy room, when the pus has become inspissated, and calcification has supervened.

The pus may perforate the parietal pleura at one or more points (empyema necessitatis); at times, through an intercostal space, eventually ulcerating through the skin and discharging spontaneously; at other times, producing denudation of the periosteum or perichondrium of ribs or costal cartilages before making its appearance at the surface. Sometimes, the pus may burrow for some distance in the muscles or soft tissues before rupture occurs.

Perforations occur most frequently in the parasternal line where the chest wall is thinnest. Here, the intercostal spaces lack the support of the external intercostal muscles, which extend only to the junction of the ribs and costal cartilages, and corresponding gaps are left between the digitations of the deeply placed triangularis sterni.

---

* From the Montreal General Hospital.

The subjoined case is illustrative.

Case 1.—A girl, aged 17, admitted to the Montreal General Hospital, March 27, 1923, on the service of Dr. Hutchison, gave a rather indefinite history, dating back to March, 1922, when she apparently had a pleuropneumonia on the left side, followed by an unrecognized empyema. She had been bed-ridden since the onset of the illness. After about six weeks, an abscess appeared over the second interspace just to the right of the sternum. The abscess was opened by her physician and has been discharging ever since (Fig. 1).

Fig. 1 (Case 1).—Appearance of chest of patient, showing sinus in the second right interspace, through which an empyema drained spontaneously.

She was brought to the hospital on account of loss of weight and strength. Dr. H. A. Lafleur reported that she had a chronic pyopneumothorax of the right side, a diagnosis which was confirmed by the roentgen-ray findings. There was no evidence of tuberculosis. In this case, a purulent effusion of long standing had found its way through a weak spot in the chest wall.

Another relatively common site is the fifth interspace, outside the area supported by the pectoralis major; but the pointing may occur in any part of the chest wall. Following is another example of an empyema which pointed in the upper anterior region:

Case 2.—A girl, aged 7, admitted to the Montreal General Hospital, Sept. 15, 1922, three months previously had had a pleural effusion on the left side; and, despite a holiday in the country, convalescence had been slow. During the three weeks preceding admission, she had gained in weight, and had no cough or elevation of temperature, but the dulness at the left base had persisted.

On admission, examination by Dr. A. H. Gordon revealed: temperature, 99 F.; pulse, 100; respiration, 20. The patient was rather poorly nourished

Fig. 2 (Case 1).—Appearance of chest one year after onset of an empyema which ruptured spontaneously through second right interspace (Fig. 1).

and rather pale. The finger nails were bluish. Both tonsils were quite enlarged. The glands were not swollen. Examination of the chest revealed a distinct fulness on the left side, with bulging of the intercostal spaces, and a localized swelling opposite the third rib just inside the nipple line. This area, which was about 2 inches (5 cm.) in diameter, was not painful. It was slightly elastic but with no definite fluctuation. The other signs were those of a massive effusion in the left chest with displacement of the heart to the right and slight scoliosis in the dorsal region, with convexity to the right.

A roentgenogram of the chest showed a fairly dense homogeneous shadow occupying the lower two thirds of the left chest, obscuring the diaphragm, with

displacement of the cardiac shadow to the right; and bulging of the left chest wall and dorsal scoliosis with convexity to the right. The right lung field showed increased radiability to the roentgen ray.

On aspiration, some greenish yellow, rather thin pus was obtained. The direct smear showed pus cells and cellular débris. No growth was obtained from the culture.

A resection of the ninth rib was undertaken, and a great quantity of thin greenish pus was liberated. The palpating finger could feel neither lung nor pericardium.

Within a few days, the swelling in the upper front part of the chest, no doubt a commencing empyema necessitatis, completely and permanently disappeared, and subsequent progress was uninterrupted.

Many cases of empyema, apparently cured, have an unfortunate way of lighting up again. The length of the latent period and the manner of recurrence make the following case worthy of mention.

Case 3.—A man, aged 28, waiter, admitted to the Montreal General Hospital, March 13, 1923, on the service of Dr. Bazin, had, in 1918, a lobar pneumonia on the right side, followed by empyema, for which he underwent an operation in Winnipeg. The wound ceased to discharge after about two months and had since remained dry.

Feb. 25, 1922, the present illness began, with chills, fever and profuse night sweats. There was no cough. After remaining three days in bed, the patient called a physician, who found no elevation of temperature and advised him to get up. He remained in the house, however, on account of a tight feeling in the chest, as he expressed it, and a soreness in the old scar. March 8, he applied at the hospital outdoor department, where examination revealed a visible swelling near the site of the old drainage wound, which, the patient stated, was gradually increasing in size. The swelling could be obliterated by pressure, but returned when the pressure was removed.

On admission, the temperature was 101 F.; pulse, 100; respiration, 22. There were signs of fluid in the right side of the chest. In the ninth interspace, behind the posterior axillary line, there was a fluctuating swelling about 6.0 cm. in diameter. Further examination revealed a complete transposition of the viscera, which had at first confused the clinical picture. Roentgentograms confirmed the clinical findings, and showed two round, dense shadows, each about 1.5 cm. in diameter in the area occupied by the fluid. The chest was aspirated, and 400 c.c. of pus withdrawn, which on culture gave *Staphylococcus aureus.*

March 15, operation was undertaken by Dr. F. B. Gurd. An incision was made over the rib, behind the old incision. The abscess in the chest wall was opened. This was found to communicate through the site of the former rib resection with the pleural cavity, from which another 400 c.c. of foul smelling, purulent material was liberated, in which was about 4 drams of material resembling Beck's paste. Following irrigation with surgical solution of chlorinated soda (Dakin's solution), the discharge appeared to clear up readily, and the wound healed in about one month after operation, when the patient left the hospital and was admitted to the outdoor department. About the end of May, he began to complain of pain in the chest, and examination revealed a reaccumulation of fluid. A section of the rib above the old thoracotomy wound was removed, and a cavity containing about 1,500 c.c. of

blood-stained, foul-smelling purulent material was drained. Discharge from the wound ceased after a period of one month, and the patient has apparently made a complete recovery.

Sir William Osler was wont to preface the earlier editions of his "Principles and Practice of Medicine" with the familiar aphorism of the Father of Medicine that "Experience is fallacious and judgment difficult." Perhaps it has been omitted in later editions because, in the practice of medicine, we are in little danger of overlooking the fact. The truth of the aphorism is illustrated in the following case report.

Case 4.—A boy, aged 10, admitted to the Montreal General Hospital, Sept. 3, 1922, complaining of weakness, tiredness and nosebleed, gave a history of double pneumonia in 1920. He subsequently developed empyema on the right side, for which he was treated in the Children's Memorial Hospital, Montreal, rib resection being performed, March 1, 1920. He was discharged as well, April 10, and had remained well up to the onset of the present illness.

About two weeks before admission, while in the country, he began to feel abnormally tired. Aug. 24, 1922, he had nosebleed. There was no headache but he complained of pain in the back, and the tired feeling persisted. August 31, his family physician diagnosed the condition as typhoid fever and put him to bed. He was sent to the hospital, September 3.

On admission, the temperature was 102.6 F.; pulse, 120; respiration, 32. The patient was bright, well-developed and well-nourished. He rested comfortably, either lying on his back or sitting up. The pupils were equal, and reacted to light and in accommodation. The ears and nose were negative. The throat was clear, with evidence of an old tonsillectomy. The edges of the tongue were clean and pink, the remainder was slightly coated. There were two decayed teeth in the lower jaw. The glands were negative. There was an old thoracotomy scar on the right side of the chest, posteriorly. The right shoulder was lower than the left, and expansion on the right was poor, the whole right side of the chest being flatter than the left. There was dulness on percussion on the right side in front, from the fourth rib in the anterior axillary line to the base, where it blended with the liver dulness. Dulness extended posteriorly from the eighth spine downward. The left side of the chest was clear. Fremitus was diminished over the dull area, and here numerous fine and medium crepitations were audible, more so after coughing. The sounds on the left were clear, and there were no râles. The pulse was of good volume, regular and dicrotic. There was relative cardiac dulness, at the third rib above, and from the midsternal line 7.5 cm. to the left. The blood pressure was 108 systolic, 46 diastolic. The sounds were fairly clear, and there were no murmurs. The abdomen was flat and moved freely. There was no tenderness. The spleen and liver were not palpable. There was frequency of urination. The urine had a specific gravity of 1.021 and gave an alkaline reaction. Otherwise, it was negative.

A Widal test was negative. In the absence of a definite diagnosis, the case was treated as typhoid.

September 4: The spleen was palpable, and there were no rose spots. The general condition was very good. The temperature had dropped to 99.8 F. The pulse was 120, of good volume, and regular. The tongue showed dorsal coating, with clean tip and edge. Respirations numbered 30. The white blood

cell count was 20,400. The leukocytosis raised the question of a pneumonic infection, and with this was associated the physical signs at the base of the right side of the chest. It was noted, however, that though there were dulness and crepitations over the site of the old empyema, the diminished vocal fremitus over the same region confirmed the view that these conditions were of old standing. The spleen was definitely palpable. There were no rose spots, but the patient's placidity and absence of dyspnea pointed rather to an enteric than to a pneumonic infection. The Widal test was definitely negative. A blood culture gave no growth after thirty-six hours' incubation.

September 8: Roentgen-ray examination of the chest revealed an old resection of the eighth rib posteriorly, and firm bony union had occurred. The inner half of the right side of the diaphragm was flattened, but there was no indication of the presence of the free fluid. The right lower third showed grayish hilum shadows enlarged and blurred, particularly to the right. The left lung showed increased radiability. The heart was small and in a vertical position.

September 11: The signs in chest were unchanged. The abdomen was negative except for a palpable spleen. The patient was bright and happy, and clear mentally. The temperature had ranged from 101 to 103 F. on each of the past four days. The white blood cell count was 16,500. The Widal test was still negative. Diagnosis remained obscure.

September 12: Early in the morning, the nurse discovered that the old empyema wound was reddened. On palpation, it was extremely tender and the center was soft. There is no fluctuation round it.

September 13: Redness was increasing at the site of the old thoracotomy wound, and there was fluctuation. The patient was transferred to the surgical ward (service of Dr. J. Alex Hutchison), for incision and the drainage.

At operation, the abscess was explored and was found to lead to a regenerated rib at the site of the old resection. The outer surface was irregular and denuded of periosteum. In the center of the rib was a small perforation, 0.5 by 0.3 cm., through which thick greenish pus was welling. The rib was resected, and a large empyema cavity was entered. The various pockets were swabbed out and the cavity was drained. The condition of the patient improved immediately; and he returned to his home on the fortieth day after operation, apparently well, and having gained greatly in weight.

Sometimes, the pus perforates through the visceral pleura and escapes into the bronchial tubes, leading to suffocation unless expectorated. Even in such cases, recovery is possible. This eventuality was recognized by Hippocrates,[1] who wrote: "Those in whom a pleurisy ends in suppuration may be cured if they bring up the matter within forty days from the rupture of the pleura."

It is interesting to recall, as Fowler and Godlee point out, that before the days of paracentesis, both external rupture and perforation of the lung were regarded as of favorable import, and cases are recorded in which even rapid recovery followed the escape of pus.

Cases of rupture into the pericardium, mediastinum, and esophagus have been reported.

---

1. Hippocrates: Aphorisms V, 15.

Perforation of the diaphragm with abscess formation in the peritoneal cavity (subphrenic) occasionally occurs. Archibald, in 1906, citing reviews of 447 cases of subphrenic abscess collected by Maydl, Grueneisen and Perutz, attributed but eighteen cases to intrathoracic infections, including a case of his own. The spread of the infection in this type of case was ascribed (following Kuettner) to lymphatic intercommunication, or (following Burkhardt) to passage of the organisms through the tissues by active growth. In some cases, the burrowing probably does not occur until the diaphragm is actually destroyed at one or more spots. Fagge and Pye-Smith refer to a case occurring in 1865 in Guy's Hospital, in which, in a man dying of empyema, tapped eleven days previously, a small hole was found in the fleshy substance of the diaphragm, beneath which was a large circular abscess, not yet opened into the peritoneal cavity.

Perforation of the diaphragm with rupture into the stomach has been reported; likewise, rupture into the intestines.

Osler cites as "very remarkable" those cases in which "the pus passes down the spine and along the psoas into the iliac fossa, simulating a psoas or lumbar abscess."

Fagge and Pye-Smith record one such case in which pointing occurred in the loin:

A boy, nine years old, was once in Guy's Hospital for pleurisy. Afterwards, he came back with a pulsating swelling in the left lumbar region which proved to be an abscess, and was opened. Two months later the boy died of tubercular meningitis and an autopsy showed that the left lung was still contracted, and that a sinuous channel, six inches long, extended down from the pleural space behind the diaphragm to the external opening.

Now while it is conceivable that, following Osler's description, pus from an empyema might pass down the spine and along the psoas into the iliac fossa (a complication well recognized in tuberculosis of the spine), it would seem impossible to follow the description of a lumbar abscess as being formed in this way. Such descriptions are found in many textbooks, serving to show how a minor inaccuracy may become firmly established. What undoubtedly happens when the abscess appears in the loin is that the pus has burrowed behind the external arcuate ligament of the diaphragm to invade the quadratus lumborum muscle, the sheath of which is quite distinct from that of the psoas.

A case of this kind which occurred in my practice will be described, as it seems to clear up the confusion which exists on this point.

Case 5.—Private T., aged 25, was undergoing treatment at Granville Canadian Special Hospital, Buxton, England, for an old shrapnel wound in the left leg. Oct. 28, 1918, when the influenza epidemic was at its height, he developed the disease, with chest complications. November 15, examination revealed dulness, with absence of breath sounds on the left side of the chest,

posteriorly, below the eighth rib. A coarse friction rub was heard along the lower margins of the lung. Many moist râles were present at both bases. A diagnosis was made of fluid at the left base, with extensive bronchitis in both lungs. Aspiration was undertaken, with negative result.

November 21, as his condition was not improving, he was examined by the consulting physician, with the following findings: In the left lumbar region and extending up over the ribs on the same side was a diffuse indefinite swelling, extremely tender but giving no fluctuation. The left rectus was not splinted, but further back the abdominal muscles were very rigid. No definite abdominal tumor was felt. Over the left side of the chest at the base was slight dulness, and here the breathing was loud and tubular, with medium crepitations. The

Fig. 3 (Case 5).—Back of patient, showing the scar in the left loin through which drainage was established, in a basal empyema, the abscess pointing into the substance of the quadratus lumborum muscle.

urine, which at the onset was negative save for some turbidity due to urates, at this time had a specific gravity of 1.030. It was turbid with urates, and had a faint trace of albumin. Microscopically, there were occasional pus cells, red blood cells, calcium oxalate crystals and ammonium urates. Roentgenograms were taken, but yielded no information of value.

Two days later, the tenderness in the left loin was more marked, and the patient appeared to be in a very septic condition. The white cell count was 18,000.

The lung picture was little changed. A perinephritic abscess was suspected, and he was transferred to the surgical division.

At operation, under ether anesthesia, an incision was made through very boggy, edematous tissue in the left loin, obliquely downward and outward from the last rib toward the crest of the ilium (Fig. 3). This led into an abscess cavity with necrotic walls. On being traced upward, it was found to communicate with a larger cavity, above the diaphragm and below the base of the left lung, the opening into the pleura lying between the external arcuate ligament (lateral lumbocostal arch) of the diaphragm and the twelfth rib. The arch could be clearly determined, springing medially from the transverse

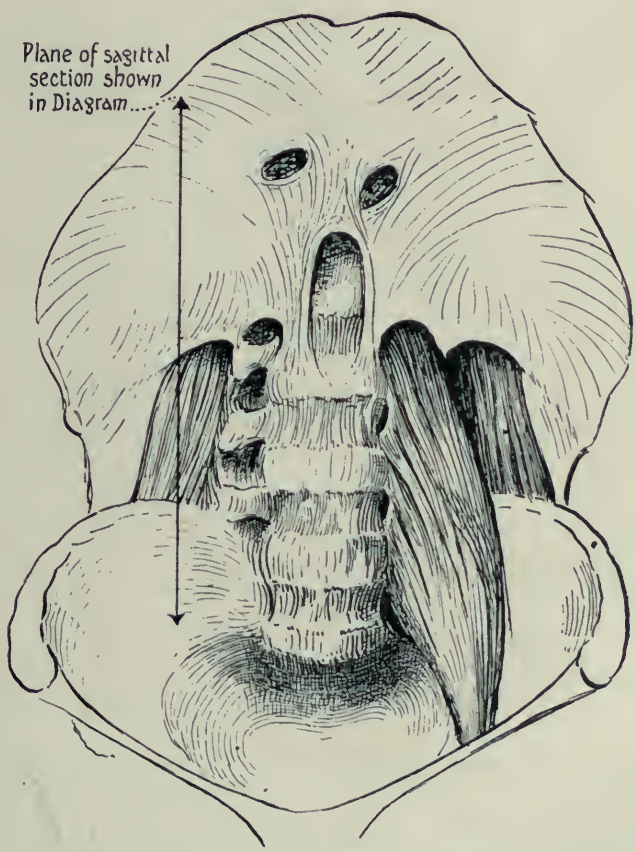

Fig. 4.—Posterior abdominal wall, showing the origin of the diaphragm from the arcuate ligaments. The arrow intersects the external arcuate ligament and the quadratus lumborum muscle.

process of the first lumbar vertebra and extending to the twelfth rib, leaving no doubt as to its identity.

A large quantity of pus was evacuated from the pleural cavity through the lumbar incision. The cavity was gently cleansed out with dry swabs, and lightly packed. A culture showed the presence of staphylococci. The packing was removed on the third day following operation, and lightly replaced.

It was proposed, for the purpose of record, to inject the cavity with opaque solution for roentgen-ray examination, but by the time the patient seemed well enough to stand the requisite moving and manipulation, the sinus had all but healed.

Recovery was uninterrupted. The wound healed completely within three weeks, and the patient was quite well at the time of his return to Canada, two months later. Subsequent roentgen-ray examination revealed a practically normal diaphragm.

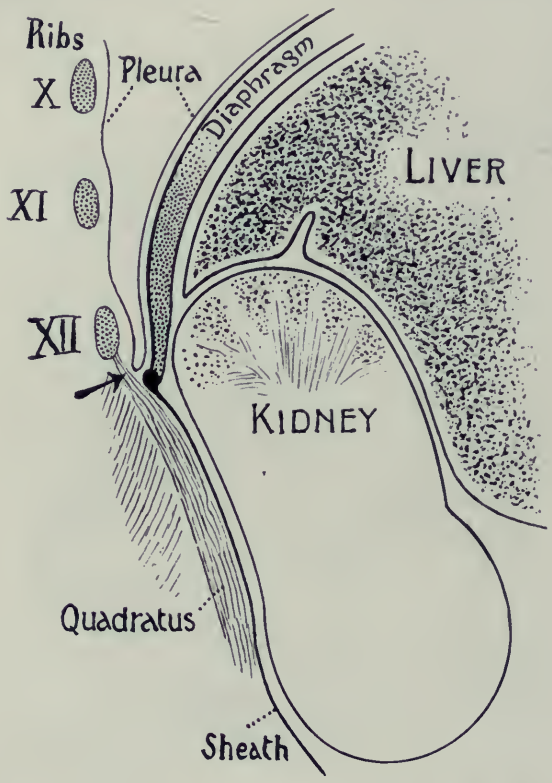

Fig. 5.—Sagittal section in the plane of the arrow in Figure 2. The upper border of the sheath of the quadratus forms the external arcuate ligament, from which the diaphragm arises. The small arrow indicates the area where the pleura and the unprotected quadratus are in direct apposition, and where the pus from an empyema burrowed into the loin (Case 5).

A series of dissections undertaken in connection with the foregoing case, together with an examination of cross sections, have aided in making clear the chain of events. Figures 4 and 5, prepared by Prof. J. C. Simpson, well illustrate the result of our study on the anatomic relations. The external arcuate ligament which serves as part of the origin of the diaphragm is simply the thickened superior border of the fascia covering the quadratus lumborum muscle anteriorly; but the

muscle continues up behind the ligament, to become attached to the last rib. At this point, the muscle is in immediate proximity with the pleural recess.

The only reasonable explanation of the sequence of events in the case cited is that a basal empyema extended downward, between the last rib and the arch, into the substance of the quadratus lumborum, and the pus, having traversed the substance of this muscle, pointed in the loin.

SUMMARY

In this paper, there have been described and illustrated some of the sequelae possible when a purulent pleural effusion has been allowed to take its own course. In the first case, an unrecognized empyema found its way through a weak spot in the upper anterior chest wall. In the second, a massive empyema, commencing to point in a corresponding region, subsided after adequate drainage of the chest was established. In the third case, a fluctuating swelling in the chest wall arose from an old underlying empyema which had remained latent for four years. In the fourth case, with the history of a purulent effusion two and a half years previously, apparently cured, the diagnosis was established on the appearance of a superficial abscess at the site of the former rib resection. In connection with the last case, that of a basal empyema pointing in the loin, a detailed description is given of the anatomic relations which render this possible.

105 Crescent Street.

INTRA-ABDOMINAL HERNIAS *

NAT H. COPENHAVER, M.D.
Fellow in Surgery, Mayo Foundation
ROCHESTER, MINN.

The development of acute symptoms of intestinal obstruction is usually the first warning of the existence of intra-abdominal hernias. Extensive or prolonged operation is contraindicated, and the saving of time is important. A better understanding of the location and differentiation of the various types will enable the surgeon to make a more rapid, intelligent and systematic exploration.

In my study of the development of the gastro-intestinal tract and abdominal fossae I have used Moynihan's monograph. It is essential that one should be familiar with the development of the gastro-intestinal tract, abdominal fossae and the diaphragm in order fully to understand intra-abdominal hernias.

LOCATION AND ORIGIN OF THE ABDOMINAL FOSSAE

The abdominal fossae may be divided into three groups: those formed around the duodenum, around the cecum and around the sigmoid.

Waldeyer,[1] in 1868, published an excellent work describing the anatomy of the retroperitoneal fossae. Various theories have been advanced with regard to the formation of the various fossae. Treitz [2] gave the first explanation concerning the duodenal fossae, attributing their existence to the embryonic movement of the intestinal canal, and their folds to the dragging of the intestine in the displacement of the viscera to the right. This is known as the "traction theory." Waldeyer asserted that the folds were formed by the inferior mesenteric vein, made more prominent by the development of the left kidney. Moynihan,[3] however, accepts the "fusion theory," that the folds are formed by fusion between the original left, or later anterior, surface of the ascending portion of the duodenum and the right, or anterior, surface of the descending mesocolic folds.

---

* Abridgement of thesis submitted to the Faculty of the Graduate School of the University of Minnesota in partial fulfilment of the requirements for the degree of Master of Science in Surgery, October, 1922.

1. Waldeyer, H.: Hernia retroperitonealis, nebst Bemerkungen zur Anatomie des Peritoneums, Breslau, F. W. Jungfer, 1868.

2. Treitz, W.: Hernia retroperitonealis: Ein Beitrag zur Geschichte innerer Hernien, Prague, F. A. Credner, 1857.

3. Moynihan, B. G. A.: On Retroperitoneal Hernia, in: The Anatomy and Surgery of the Peritoneal Fossae, London, Baillière, Tindall and Cox, **8,** 1899.

Paraduodenal Fossae. — Moynihan describes nine paraduodenal fossae, four of which are infrequently observed and considered unimportant. The five commonly seen are: the superior duodenal fossa, the inferior duodenal fossa (that of Treitz), the paraduodenal fossa (that of Landzert), the mesentericoparietal fossa (that of Waldeyer), and the mesocolic fossa. The inferior duodenal fossa occurs most often and the superior next. Moynihan found that the inferior occurred in from 70 to 75 per cent. and the superior in from 40 to 50 per cent. of the cases examined.

Pericecal Fossae.—Lockwood and Rolleston [4] describe the fossae around the cecum as the ileocolic fossae, the ileocecal fossae and the subcecal fossae. Moynihan describes four as the ileocolic fossa, the accessory ileocolic fossa, the ileo-appendiceal fossa and the retrocolic fossa. The ileo-appendiceal and the retrocolic fossae correspond to the ileocecal and the subcecal fossae of Lockwood and Rolleston, respectively.

Intersigmoidal Fossa.—Only one, the intersigmoidal fossa, is found in the sigmoid region. The orifice of the fossa points downward and the fundus upward. The iliac artery lies behind, and the sigmoid artery lies above and to the right. The fossa is found most often in infants. Treves [5] found that it occurred in 84 per cent., and Moynihan in 70 per cent., of the bodies examined.

PARADUODENAL HERNIAS

Paraduodenal hernias may be divided into two main groups: right duodenal and left duodenal. The left duodenal hernia has been commonly described as the duodenal hernia, the term "right duodenal hernia" being employed to indicate that form of hernia in which the sac extends toward the right side of the abdomen. Left duodenal hernias are more frequent.

Moynihan has shown that the right duodenal hernia originates usually in the mesentericoparietal fossa, while the left originates in almost every case in the paraduodenal fossa. Since the majority of paraduodenal hernias occur in either the fossa of Waldeyer or the fossa of Landzert, only these will be described.

The paraduodenal fossa is situated on the left, and some distance from the ascending portion of the duodenum. It is formed by the raising of a fold of the peritoneum by the mesenteric vein. This fold

---

4. Lockwood, C. B., and Rolleston, H. D.: On the Fossae Round the Cecum, and the Position of the Vermiform Appendix, with Special Reference to Retroperitoneal Hernia, J. Anat. & Physiol. **26**:130-148, 1891-1892.

5. Treves, F.: Lectures on the Anatomy of the Intestinal Canal and Peritoneum in Man, Brit. M. J. **1**:470-474, 527-530, 580-583, 1885.

has been described as "the mesentery" of the vein. The opening points down and to the right. The pouch is directed upward and slightly to the left. Some confusion has arisen as to the exact limits of this fossa, owing to the fact that it not infrequently exists in conjunction with other fossae.

Moynihan's location of the mesentericoparietal fossa and his description are as follows: "The most usual position of this fossa is in the first part of the mesojejunum immediately behind the superior mesenteric artery. The orifice of the fossa looks to the left; its blind extremity to the right and downward. In front it is bounded by the superior mesenteric artery and behind by the lumbar vertebrae. The peritoneum of the left leaf of the mesentery lines the fossa. That of the right covers the blind end and is then continued directly into the posterior parietal peritoneum." This fossa is comparatively rare. Desjardins [6] examined 100 bodies and found it in only one.

Moynihan reported sixty-five cases of paraduodenal hernia. Short [7] collected seventeen cases from the literature in 1914, one of which had previously been reported by Moynihan. Desjardins, in 1917, reported a case and collected four more from the literature, making a total of eighty-six cases. Since then fifteen cases have been collected. Five paraduodenal hernias have been observed at the Mayo Clinic, four at operation and one at necropsy. In none of the cases were the symptoms suggestive of internal hernia, and consequently a clinical diagnosis was not made. Neither was an accurate anatomic classification made by the surgeon of the cases found at operation.

REPORT OF A TYPICAL CASE OF PARADUODENAL HERNIAS

Case 1 (reported by Desjardins).—Mr. E. D., aged 56, came to the clinic complaining of shortness of breath and abdominal distention.

Physical examination revealed multiple, fine nodular masses in the upper abdomen, an enlarged palpable spleen and a large quantity of fluid in the left pleural cavity. A supraclavicular lymph gland removed for microscopic examination showed lymphosarcoma, and four days after the patient's arrival at the clinic he died. At necropsy it was found that a large uniformly rounded mass, measuring 20 by 17 cm., filled the center of the abdominal cavity and was surrounded by the large bowel. The hernial sac contained all the small intestines except the terminal 12.5 cm. of the ileum and descended to within 5 cm. of the symphysis pubis. The opening of the sac was found above and behind the lower pole of the mass and to the right of the middle line. The orifice pointed downward and to the right. The sac contained both the inferior mesenteric vein and the left colic artery. The inferior mesenteric vein passed

6. Desjardins, A. U.: Left Paraduodenal Hernia, Ann. Surg. **67**:195-201 (Feb.) 1918.

7. Short, A. R.: A Case of Retroperitoneal Hernia Cured by Operation, with Report on the Literature of the Subject, Brit. J. S. **3**:48-54, 1916.

beneath the posterior parietal peritoneum across the back of the hernial sac. It then crossed downward and inward to the right margin of the hernial orifice, forming the outer boundary of the neck of the sac. The left colic artery ran toward the left side, coursing downward in the space between the sac and the descending colon. It then entered the left side of the anterior margin of the hernial orifice and passed through it upward and to the right. This was an example of hernia into the fossa of Landzert and should be classified as a left paraduodenal hernia (Fig. 1).

PERICECAL HERNIAS

Pericecal hernias are not so common as hernias occurring around the duodenum. Only one case has been observed at the Mayo Clinic. Operation was performed in a case of a posterior pericecal hernia with transposition of the cecum. The anatomic relations were somewhat distorted because of the transposition, but the hernia was believed to have originated in the retrocolic fossa and to have pushed its way to the right and upward between the two layers of mesentery. This fossa, as described by Moynihan, lies posterior to the cecum and extends upward toward the kidney as a part of a peritoneal tube bounded by two peritoneal folds, an outer or upper, and a lower or inner.

REPORT OF CASE OF PERICECAL HERNIA

Case 2.—Mr. G. W., aged 25, came to the clinic because he had had a "sore stomach" for seven months and distress from gas. The pain was usually more severe in the middle of the afternoon, being relieved somewhat by food, from one to three hours after meals, or by taking an effervescent acetanilid mixture.

Physical examination revealed a spot of extreme tenderness in the epigastric region. Urinalysis was negative. The hemoglobin was 49 per cent.; erythrocytes numbered 3,890,000, and leukocytes, 6,000. A test meal revealed a total acidity of 56, and free hydrochloric acid 38. Roentgenograms of stomach and chest were negative. Transposition of the colon was apparent on roentgen-ray examination; but the clinical diagnosis was indeterminate.

When the abdomen was opened at operation, transposition of the cecum was revealed. The greater part of the mesentery of the cecum, with the blood vessels of the cecum and the ascending colon, came from a point to the left of the mesenteric attachment of the small intestine. The outer leaf of the peritoneum of the mesentery of the cecum remained in its normal position. The hernia included practically all of the small intestine, being expressed through an opening, 4 cm. in diameter, directly beneath the ileocecal valve into the root of the mesentery of the cecum. The outer leaf of peritoneum of the mesentery of the cecum and ascending colon was incised throughout its length, thus destroying the hernial sac. Numerous adhesions were found around the cecum. On account of the mobility of the cecum, a side-to-side anastomosis was made between the terminal ileum and the transverse colon.

Convalescence was uneventful until the ninth day, when signs of acute obstruction developed. A second exploration revealed a loop of small bowel strangulated by adhesions. The bowel was quite cyanotic. The adhesions were freed, and an enterostomy was performed; but the patient died the following day (Fig. 2).

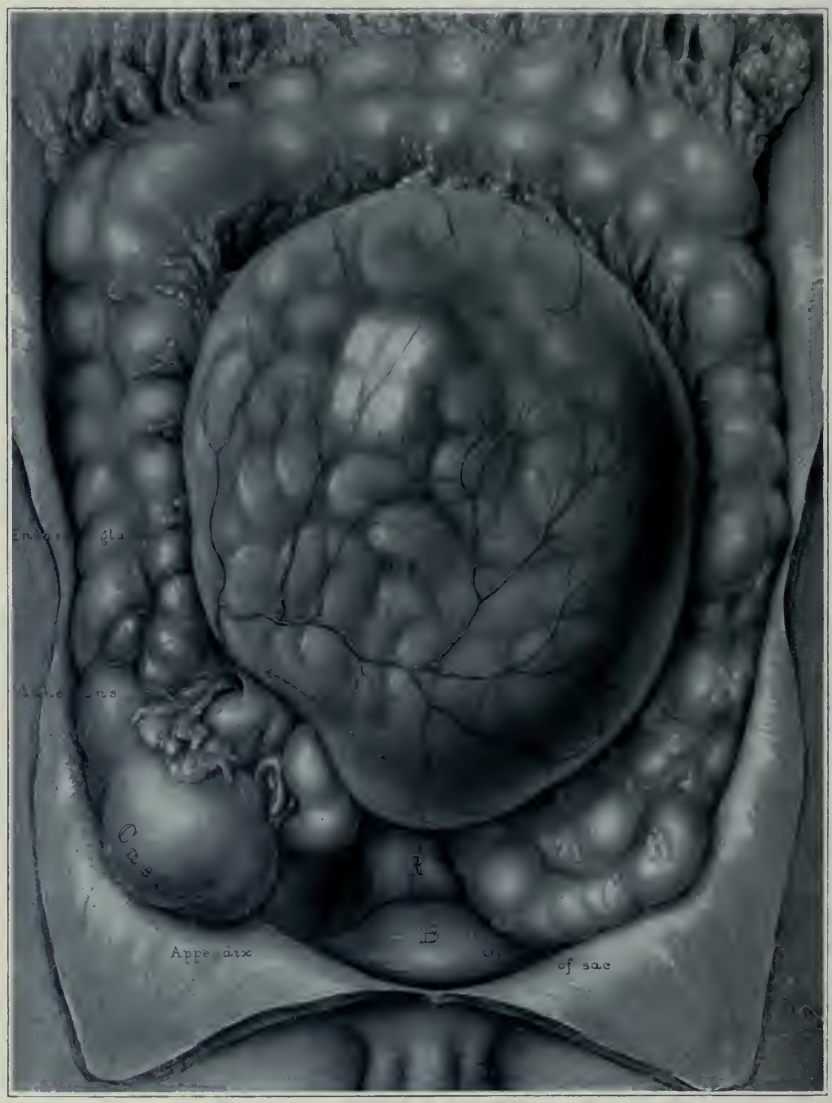

Fig. 1 (Case 1).—Paraduodenal hernia. The sac contained the entire small bowel, except the terminal 12.5 cm. The opening of the sac lay behind the lower pole of the mass and to the right of the middle line. The orifice pointed to the right and downward.

INTERSIGMOIDAL HERNIAS

Moynihan reported only two cases which he considered authentic intersigmoidal hernias. Since then isolated cases have been reported. Coley [8] reported a third case in 1909. Krall [9] and Machol [10] reported two cases in 1911, and Krall reported a unique case in which a part

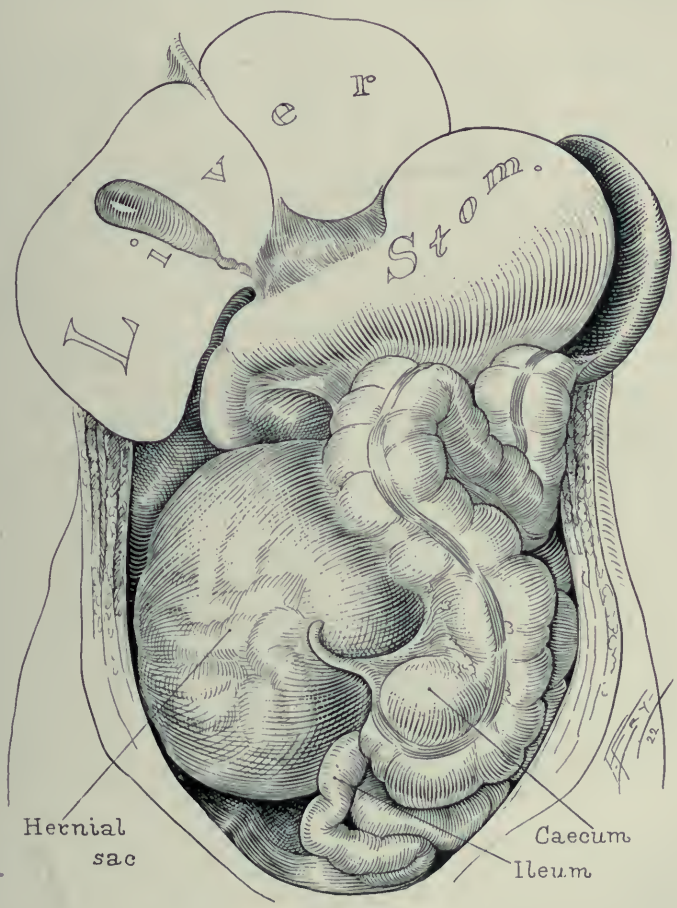

Fig. 2 (Case 2).—Pericecal hernia with transposition of the cecum. The sac contained practically all of the small intestine which had entered through an opening beneath the ileocecal valve into the root of the mesentery of the cecum, extending upward and to the right.

8. Coley, W. B.: Strangulated Retroperitoneal Hernia of the Intersigmoid Fossa, Tr. Am. Surg. Assn. **27**:445-456, 1909.

9. Krall: Ein Beitrag zur Kenntnis der Hernia intersigmoidea, Deutsch. Ztschr. f. Chir. **110**:303-306, 1911.

10. Machol: Beitrag zur Kenntnis der Hernia intersigmoidea, Beitr. z. klin. Chir. **76**:209-216, 1911.

of the sigmoid itself was folded into a loop and caught in the fossa. Murphy,[11] Black,[12] and Nuzum and Nuzum [13] have each reported a case, bringing the total up to eight cases. Taylor,[14] in 1918, reported a case which he called a hernia into the mesosigmoid fossa. From his description of the hernia and its location it would appear that the case also was a true intersigmoidal hernia. There is no record in the Mayo Clinic that such a hernia has been observed.

HERNIAS THROUGH THE FORAMEN OF WINSLOW

Twenty-three cases of hernia through the foramen of Winslow have been recorded. Moynihan reported eight cases. Corry,[15] in 1917, reported one and collected nineteen, and since then three other cases have been reported. The rarity of such hernias may be explained by the small opening and the barrier formed by the transverse colon to the passage of the small intestine toward the foramen. In the early years of life the foramen is more clearly defined, but in later years it is not uncommon to find adhesions between the anterior and the posterior borders of the opening. The foramen is bounded by the inferior vena cava behind, the duodenum and hepatic vessels below, the caudate lobe of the liver above, and the hepatic artery in front, the portal vein and common bile duct being contained in the lesser omentum. The opening is circular, and is 2 by 3 cm. in diameter.

Merkel [16] believes that either an abnormally long mesentery or a retardation of the normal process of fixation of the colon must exist if portions of the intestine are present in the lesser peritoneal cavity. From the twelve cases reported by Moynihan it would appear that a gross congenital abnormality must exist to permit the occurrence of such hernias. In the twelve cases four types of abnormality were observed: (1) a common mesentery for the whole intestine, (2) absence of the secondary fusion of the ascending colon to the posterior abdominal wall, (3) abnormally large size of the foramen, and (4)

---

11. Murphy, J. B.: Ileus: Varieties; Symptoms; Management; Illustrative Cases, Surg. Clin. of John B. Murphy **3**:617-653, 1914.

12. Black, J. C.: Intersigmoid Retroperitoneal Hernia. Surg., Gynec. & Obst. **31**:527, 1915.

13. Nuzum, F., and Nuzum, J.: Two Unusual Internal Hernias—One Intersigmoid, the Other Into the Paraduodenal Pouch of Landzert, Tr. Chicago Path. Soc. **9**:191-207, 1913-1915.

14. Taylor, G.: A Successful Case of Hernia Into the Mesosigmoid Fossa. Lancet **1**:873 (June 22) 1918.

15. Corry, M.: Notes on a Case of Hernia (with Obstruction) Into the Lesser Sac of the Peritoneum, Indian M. Gaz. **52**:130 (April) 1917.

16. Merkel, quoted by Piersol, G. A.: Human Anatomy; Including Structure and Development and Practical Considerations, Philadelphia, J. B. Lippincott Company.

abnormal length of the mesentery with undue mobility of the intestine. The one case observed in the Mayo Clinic and reported here is of the fourth type. In the absence of one of the abnormalities, Moynihan says, the occurrence of a hernia may be considered a physical impossibility.

REPORT OF A CASE OF HERNIA THROUGH THE FORAMEN OF WINSLOW

Case 3.—Mrs. B., aged 56, had an attack of acute right epigastric pain, nausea and vomiting seventy-two hours before coming to the clinic. The pain was severe enough to require morphin. Enemas were given with unsatisfactory results.

On examination the abdomen was found to be markedly distended. There was no evidence of peristalsis, but tenderness was detected over the gall-bladder area. A diagnosis of acute intestinal obstruction was made and an enterostomy performed, a catheter being placed in the first loop of distended small bowel that appeared. A cystlike mass could be felt in the upper right posterior part of the abdomen. The possibility of internal hernia was considered, but, owing to the critical condition of the patient, exploration was not continued. The patient improved, but because of continued obstruction, the abdomen was again explored the following day. The cecum and ascending colon, which had a long free mesentery, had passed through the foramen of Winslow into the lesser peritoneal cavity, had ruptured through the anterior leaf of the lesser omentum, and were hanging down in front of the stomach. The loop was dark in color and distended to four or five times the normal size. A needle was inserted and gas withdrawn; it was then possible to reduce the hernia. A catheter was inserted at the point where the needle entered. The color of the bowel improved as soon as the hernia was reduced.

In the first twelve hours there was very free drainage from the catheter (1,400 c.c.). Then there was a sudden cessation of the drainage, the abdomen became distended, and the patient grew worse and died.

Necropsy revealed that the free mobility of the cecum had allowed it to become twisted on itself. A definite volvulus of the cecum and distal portion of the ileum was the cause of the sudden stoppage of the drainage, and the terminal factor in causing the patient's death (Fig. 3).

DIAPHRAGMATIC HERNIA

There are two types of diaphragmatic hernia, congenital and acquired. Congenital hernias occur usually through the posterior left part of the diaphragm. Most authorities give the ratio of 8 to 1. Of the 635 cases tabulated by Eppinger,[17] 580 were on the left and fifty-eight on the right, a ratio of 10.5 to 1.

Anatomically, the left side is weaker than the right because of the openings of the aorta, inferior vena cava and esophagus. The part played by the liver as a shield, to protect any defect and to distribute

17. Eppinger, H.: Allgemeine und spezielle Pathologie des Zwerchfells, Hölder, Vienna und Leipzig, 1911.

equally pressure exerted from below, is important in preventing hernias on the right.

Giffin,[18] in 1912, reported a single case and collected 650 cases from the literature. During the World War numerous traumatic hernias occurred following wounds of the diaphragm. Bryan,[19] in 1921, reviewed injuries of the diaphragm, sustained during the war, together with surgical treatment. He divides injuries of the diaphragm into: (1) injuries without an external wound, caused by some external

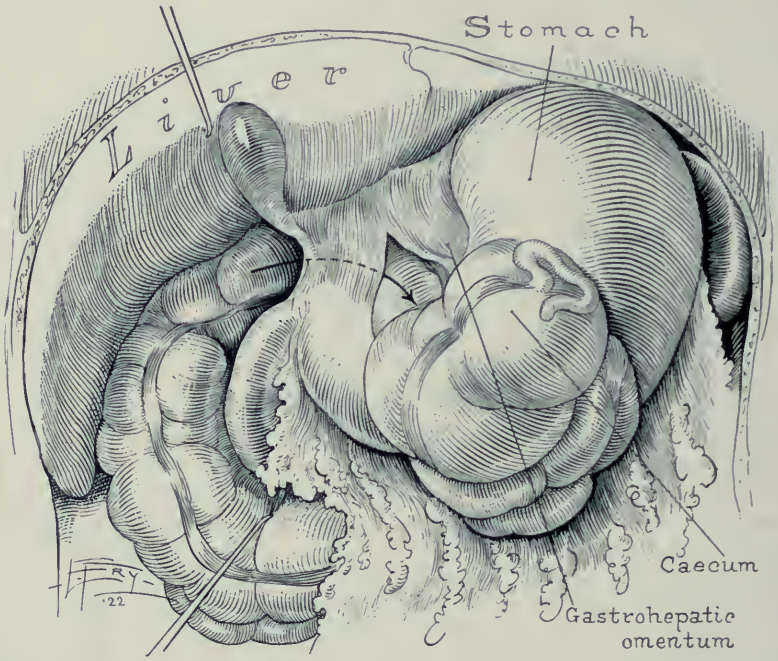

Fig. 3 (Case 3).—Hernia of the terminal ileum, cecum and ascending colon through the foramen of Winslow into the lesser peritoneal cavity and out through the gastrohepatic omentum.

violence of a crushing nature, and (2) penetrating abdominothoracic wounds involving the diaphragm. He reports fifty cases of his own, all of which came to operation. Twenty-six of his patients were evacuated to the base hospitals, and twenty-four died in clearing stations. The symptoms in acute cases of diaphragmatic hernia are

18. Giffin, H. Z.: The Diagnosis of Diaphragmatic Hernia, Ann. Surg. **55**: 388-397, 1912.

19. Bryan, C. W. G.: Injuries of the Diaphragm: with Special Reference to Abdominothoracic Wounds, Brit. J. Surg. **9**:117-147 (July) 1921; Lancet **2**: 1-8 (July 2) 1921.

dyspnea, and severe upper abdominal and left thoracic pain. Symptoms of intestinal obstruction are often found. In chronic cases, whether congenital or traumatic in origin, the symptoms are much less striking. Such cases simulate elevation of the diaphragm in which attacks of abdominal pain, dyspnea and vomiting may occur, though less severe than with diaphragmatic hernias. Giffin points out the difficulty of differentiating traumatic diaphragmatic hernia because of indirect injury and elevation of the diaphragm. The roentgenogram is of great value in differentiating these conditions. Balfour [20] mentions three important roentgenologic indications of hernia: (1) destruction of the definite dome shape which is characteristic of the normal line of the diaphragm, (2) the appearance of the lung tissue through the gas bubble in the left side of the chest and (3) the demonstration of bismuth in the colon above the level of the bow line in the chest.

REPORT OF CASES OF DIAPHRAGMATIC HERNIA

Case 4.—Dr. W. H. C., aged 57, had had an attack of gas and belching two years before. Three days later he felt weak and suddenly vomited about 3 quarts of dark bloody material. He collapsed and went to a hospital, where a diagnosis of perforated gastric ulcer was made. He improved, went back to work after two months and was free from pain for nine months, then gas and epigastric pain returned. A severe left upper abdominal colicky pain, lasting for several hours, was followed by vomiting of from 2 to 3 gallons of clear serum. For two weeks he vomited from two to four hours after eating.

Physical examination and urinalysis were practically negative. Analysis of the blood showed hemoglobin 23 per cent. and 8,000 leukocytes. The Wassermann reaction was negative. Total gastric acids were 20; free hydrochloric acid, 10. Roentgenograms of the stomach disclosed that the duodenum and pyloric end of the stomach were fixed high under the liver. The clinical diagnosis was indeterminate.

When the abdomen was opened the small intestine protruded through the high middle line incision. The stomach was lying very high and was drawn down with difficulty. There was no evidence of ulcer or cancer in either stomach or duodenum. The omentum and transverse colon which were lying high on the right side were pulled down, and it was found that these came out through a large opening in the diaphragm. The stomach, almost the entire transverse colon and the omentum were lying in the thoracic cavity at the beginning of the operation, and an opening in the diaphragm, about 11.25 or 12.5 cm. in diameter, was found. This opening began along the central posterior surface of the diaphragm and extended over toward the right side. After the intestine and omentum had been drawn out of the opening there was a tremendous sucking of air through the abdominal cavity into the thoracic cavity. The right and left lobes of the liver had been pushed downward and to the right; the spleen had been dragged toward the right and was lying in the middle line above the stomach and very close to the diaphragm. It was impossible to find

20. Balfour, D. C.: Nonstrangulated Diaphragmatic Hernia Due to Indirect Injury, Ann. Surg. **63**:78-82 (Jan.) 1916.

any definite right edge of the hernial opening. The opening was closed by suturing the inner edge of the hernial opening to the posterior sheath of the right rectus muscle. The peritoneum was freed from the posterior sheath of the rectus muscle along the right side of the upper portion of the abdominal incision, and the inner edge of the hernial opening was sutured to the posterior sheath of the rectus muscle with multiple interrupted chromic catgut sutures. The patient stood the operation well and made a good recovery.

Case 5.—Mr. T. F., aged 36, complained of pain in the stomach associated with vomiting and tarry stools. Two years before, two of his ribs had been broken by a fall. A thoracotomy was performed at that time, and considerable blood was removed from the left side of the chest. One year before an abdominal exploration had been made for gastric ulcer, but none was found. The appendix was removed, but symptoms continued unabated.

Physical examination was practically negative. The patient was 30 pounds underweight. Examination of the urine, of the blood and the blood Wassermann reaction were negative. Gastric analysis revealed a large, lax duodenum, but the roentgen-ray diagnosis was indeterminate. A clinical diagnosis of duodenal ulcer was made.

Exploration revealed chronic cholecystitis and pancreatitis, and cholecystostomy was performed. There was an opening in the left diaphragm about 3.75 cm. in diameter, and the omentum was firmly adherent to the ring. The stomach, duodenum, transverse colon and intestines were in the normal position. No attempt was made to close the opening. The patient recovered uneventfully.

Case 6.—R. T., a boy, aged 17, had a history of many attacks of epigastric pain, vomiting, constipation and dyspnea on exertion. These attacks had occurred since early childhood, at which time a dextrocardia was recognized. Severe attacks simulating appendicitis were noted later. Five months before, the patient had a sudden attack of severe epigastric and right hypochondriac pain, accompanied by shock, pain on breathing, tenderness over the appendix and a mass in the left upper abdomen. The appendix was removed. Three months later obstructive symptoms necessitated short-circuiting the colon around the mass in the region of the splenic flexure. The small bowel was found in the thorax. The patient improved markedly. After five weeks a return of abdominal pain, gas, peristaltic unrest, difficult bowel movements, distress with enemas and dyspnea on sudden change of position brought the patient to the clinic.

Exploration disclosed the stomach, spleen and splenic flexure of the colon lying in the left thoracic cavity. A perforation of the jejunum on the left chest wall and the descending colon was repaired. Remnants of inflammatory tissue together with the omentum were sutured in the lateral half of the thorax to form an artificial diaphragm. Enterostomy was performed nine days later for relief of obstructive symptoms. Ten days later the obstruction from a band over the ileum was relieved. The patient made a good recovery.

Of the eight diaphragmatic hernias found at operation, three of which are here reported, only one was in a female; five were congenital and three were traumatic; seven were on the left, and one on the right, the one on the right being of the congenital type.

INTRA-ABDOMINAL HERNIAS DUE TO TEARS IN THE MESENTERY, OMENTUM AND LIGAMENTS

Numerous isolated cases of hernias through an abdominal opening of the abdomen have been reported. They may occur anywhere in the abdominal cavity, appearing in some instances in obscure and unusual places. Downing [21] has reported a case in which the small bowel passed through a tear in the wall of the large bowel and presented as a tumor in the lumen of the rectum. Fagge [22] has reported two cases of strangulated hernias into pouches extending into the broad ligaments of the uterus. Like diaphragmatic hernias they are usually caused by injury and may follow accidents of a crushing nature, an abdominal wound, or, as pointed out by W. J. Mayo,[23] may be caused by persistent severe straining in vomiting. They are rather common clinically and are, for the most part, readily amenable to surgical treatment.

Hernias into the lesser peritoneal cavity through a tear in the lesser omentum, gastrocolic omentum, the great omentum, or the transverse mesocolon have received considerable attention by various authors. Moynihan has reported four such cases; Mayo reported two cases in 1909, and Short one case in 1915, with thirteen collected from the literature. Pringle [24] has more recently reported four cases. Hernias often occur through a slit in the mesentery of the large and small bowel, or the great omentum.

REPORT OF A CASE OF INTRA-ABDOMINAL HERNIA

Case 7.—Mr. E. F., aged 48, had been taken with cramps in the lower abdomen while eating his breakfast the day before and had begun to vomit. The cramps and frequent vomiting persisted. Morphin was required for relief of the pain. Six weeks before, the patient had had mild abdominal pain for two or three days following heavy lifting.

There was marked tenderness over the lower abdomen with distinct spasm. The abdomen was slightly distended. Digital examination of the rectum was negative. A diagnosis of obstruction was made, and the patient was sent to the hospital for operation. Exploration disclosed a hernia of the small intestine through an opening in the omentum. The small bowel had become twisted on itself after passing through the opening. About 3 feet of the lower end of the jejunum was gangrenous and had to be resected. The opening in the omentum was closed. The patient suffered considerable shock following the operation and died on the fourth day, of peritonitis (Fig. 4).

---

21. Downing, A. T.: Hernia of the Small Bowel into the Rectum, Boston M. & S. J. **180**:586-588 (May 22) 1919.

22. Fagge, C. H.: Two Cases of Strangulated Retroperitoneal Hernia into Pouches in the Broad Ligament, Brit. J. Surg. **5**:694-696 (April) 1917-1918.

23. Mayo, W. J.: Mesocolic or Retrogastric Hernia, Collected Papers, Mayo Clinic, Philadelphia, W. B. Saunders Company, 1905-1909, pp. 337-341.

24. Pringle, J. H.: Hernia Across the Lesser Sack of the Peritoneum, Glasgow M. J. **91**:129-146 (March) 1919.

POSTOPERATIVE HERNIAS

Postoperative intra-abdominal hernias may be divided into two types: (1) those through an abdominal opening made during operation, and (2) those into pouches or openings formed by the intestinal canal

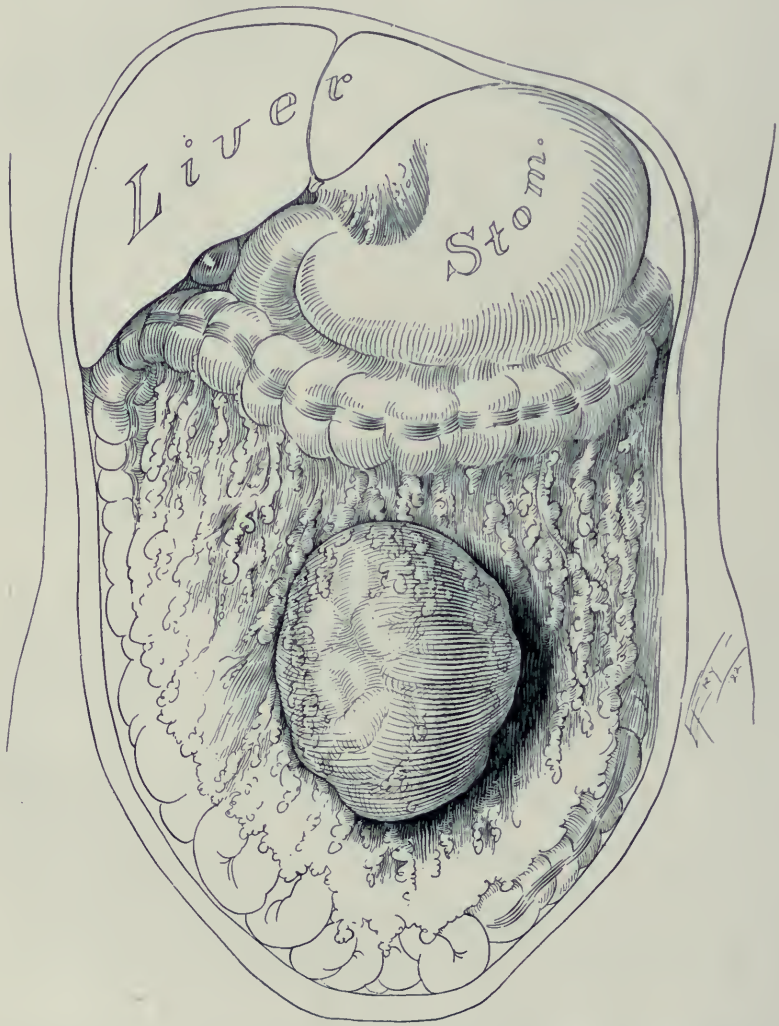

Fig. 4 (Case 7).—Hernia of the small intestine through the omentum from the posterior side.

itself, following an operation. The first type is not so important from a practical standpoint as the second. Formerly, the most common point of occurrence for the hernias in question was through the mesentery of the transverse mesocolon following posterior gastro-enterostomy.

Although the possibility of the small bowel passing through an opening in the transverse mesocolon had been pointed out before the posterior method of gastro-enterostomy was advocated, it was not until after several hernias had occurred that surgeons began closing the opening by suturing the mesocolon to either the stomach or the jejunum. Now that the posterior method of gastro-enterostomy has been standardized, such hernias are rare. Even with this important advance in technic, the danger of internal hernias following gastro-enterostomy is not entirely removed. C. H. Mayo and Magoun [25] collected ten cases from the literature in which the small intestine slipped behind the loop of jejunum which is formed by every anastomosis. Six of the cases followed posterior gastro-enterostomy, two anterior, and in two the type was not mentioned. The fact that the posterior method is used in a far greater number of cases than the anterior would explain the fact that more hernias have been reported following the posterior method. No cases of hernia folowing a Polya operation have been reported. Mayo and Magoun reported two other cases of hernia following gastro-enterostomy, one by the posterior and the other by the anterior method. They also report a unique case of hernia following a left rectus colostomy. In this case the entire small bowel had passed between the loop of sigmoid forming the colostomy and the left abdominal wall.

SUMMARY AND CONCLUSIONS

1. Intra-abdominal hernias are rare, but are important from a surgical standpoint.

2. The majority of internal abdominal hernias arise as a result of some defect in the embryologic development.

3. The symptoms are indefinite and are usually of intestinal obstruction, either acute or chronic, with periodic mild attacks. Differential diagnosis is impossible.

4. In all cases of intestinal obstruction a hernia should be considered.

5. The occurrence of abdominal hernias is confined to: (1) the duodenal area, (2) the cecal area, (3) the area of the foramen of Winslow and (4) the sigmoidal area.

6. Hernias in the duodenal area are the most common.

7. Two fossae around the duodenum are of practical importance, the paraduodenal fossae, formed by the raising of a fold of peritoneum by the mesenteric vein, and the mesentericoparietal fossa, formed in the first part of the mesojejunum just behind the superior mesenteric artery.

---

25. Mayo, C. H., and Magoun, J. A. H.: Postoperative Intra-Abdominal Hernia, Arch. Surg. **4**:324-333 (March) 1922.

8. Hernias through the foramen of Winslow depend on four congenital anomalies: (1) a common mesentery for the whole intestine, (2) absence of the secondary fusion of the ascending colon to the posterior abdominal wall, (3) the abnormally large size of the foramen, and (4) the abnormal length of the mesentery with undue mobility of the intestine.

9. Intersigmoidal hernias are the rarest of all hernias; only nine cases have been reported.

10. Of the acquired internal hernias there are three types: (1) diaphragmatic hernias due to trauma, (2) hernias through tears in the abdominal viscera and (3) postoperative hernias.

11. Diaphragmatic hernias are the most common of the acquired type and should always be looked for following any accident of a crushing nature.

12. Left diaphragmatic hernias, both congenital and acquired, are more common than those on the right.

13. The diagnosis of diaphragmatic hernias is made possible by the roentgen ray. Differentiation, however, of a true hernia and elevation of the diaphragm is often difficult.

14. In operating on diaphragmatic hernias it is difficult to keep the abdominal viscera from being sucked back into the thorax while closure of the opening is being made.

15. Care must be taken not to injure the superior mesenteric artery and inferior vein in operating on duodenal hernias.

16. Considerable difficulty is encountered in the reduction of strangulated hernias into the lesser peritoneal cavity. The close proximity of important structures to the foramen of Winslow makes enlargement of the orifice extremely hazardous.

DEETHERIZATION BY MEANS OF CARBON DIOXID INHALATIONS

WITH SOME OBSERVATIONS ON PULMONARY VENTILATION AND ETHER TENSION DURING ANESTHESIA *

JAMES C. WHITE, M.D.
BOSTON

Until very recently, no satisfactory method had been devised for improving the condition of patients suffering after operation from the bad effects of ether anesthesia. The use of carbon dioxid for this purpose was proposed two years ago by Henderson and Haggard.[1] The physiologic principles which suggested this method are (1) that ether, being a volatile substance carried by the blood, will be eliminated chiefly through the lungs; (2) that the rate of its elimination must, therefore, vary directly with the volume of pulmonary ventilation. Carbon dioxid being the natural stimulus to the respiratory center, its addition in small quantities to the inspired air seemed to them the logical method of accomplishing this purpose.

The present research was undertaken in an effort to discover whether such a use of carbon dioxid in patients suffering from the effects of ether anesthesia could be of outstanding benefit, and whether it was capable of producing any harm. It was begun on the suggestion of Professor Henderson, and is essentially the application of extensive studies in the Laboratory of Applied Physiology at Yale, on the respiration, the blood gases and ether anesthesia, to a clinical problem. It may be regarded as a joint product of that laboratory and of the clinic of the Massachusetts General Hospital. Dr. Haggard has given frequent and cordial consultation with regard to his own closely related analytic and theoretical work on the absorption, distribution and elimination of ether, at New Haven. The present work was divided into two parts: 1. Clinical observations were made in order to study the length of time required to recover consciousness, the color, the blood pressure, the pulse rate and the subjective sensations of patients treated with carbon dioxid, as compared with untreated patients. 2. A laboratory study was undertaken in which quantitative analyses were made on the ether tensions in the venous pulmonary air and the minute

* From the Third Surgical Service and Medical Laboratory of the Massachusetts General Hospital, and aided in part by a gift from Dr. William Norton Bullard. The work was done in collaboration with Drs. J. H. Means and E. P. Richardson.

1. Haggard, H. W.; Coburn, R. C., and Henderson, Yandell: The Therapeutic Use of Carbon Dioxid After Anesthesia and Operation, J. A. M. A. **74**: 783-786 (March 20) 1920.

volume of respiration, to determine the exact rate of deetherization. In the course of these studies, information has been obtained on such related subjects as the anesthetic tension of ether and pulmonary ventilation during induction and maintenance of anesthesia, as well as during the recovery period. The use of carbon dioxid for purposes other than deetherization will also be mentioned.

METHODS

The apparatus used for carbon dioxid administration was that of Haggard and Henderson,[1] who have fully described it. In brief, it consists of a carbon dioxid tank, a needle valve, a safety valve and a face mask. The flow of carbon dioxid is regulated by the needle valve. The safety valve makes it impossible for the patient to get an undesirable amount. The mask is constructed in such a way that carbon dioxid is added to the inspired air, but the expired air wastes into the room. The apparatus as used at the Massachusetts General Hospital is shown in Figure 1. The only change from its prototype is the addition of a large carbon dioxid tank on a truck, for convenience, and a reducing valve, with which the tank is equipped.

CLINICAL STUDIES

Henderson and Haggard [1] published a brief record of seventeen patients deetherized by this method at the New York Post-Graduate Hospital. They reported the rapid production of hyperpnea, with an increase in the minute volume of respiration to from 30 to 70 liters a minute. Under this rapid and efficient pulmonary ventilation, their patients regained consciousness in from fifteen to twenty-five minutes. The blood pressure, which had fallen from 5 to 15 mm. below normal and which control observations had shown would continue to fall still farther, was rapidly restored to a normal level. Observations made on the blood alkali show an average fall of 10 per cent. by volume, with a complete return to normal after the administration of carbon dioxid. In addition to these objective findings, they noted that patients returned to the ward with color and circulation much improved; that the tendency to nausea and vomiting was much reduced, and that none developed gas pains.

The first series here reported is made up of thirty patients treated in the autumn of 1922. The second series of sixteen cases was studied during March and April, 1923. In the second series, a certain amount of clinical data was obtained similar to that in the first series. For convenience, therefore, all the clinical findings will be discussed together, and the laboratory material will be discussed separately, in a later section. All clinical data are given in Table 1,and all laboratory data in Table 2.

The first series covers the normal run of operation from skin graft to cerebellar tumor. After the pulse and respiratory count and the blood pressure had been taken, carbon dioxid administration was started as soon as the wound was closed. Respiration never failed to show an increase within the first minute. At the end of two to three minutes, it could be kept at any volume desired. A moderate rate of deep breathing was produced which, in itself, could in no way tire the

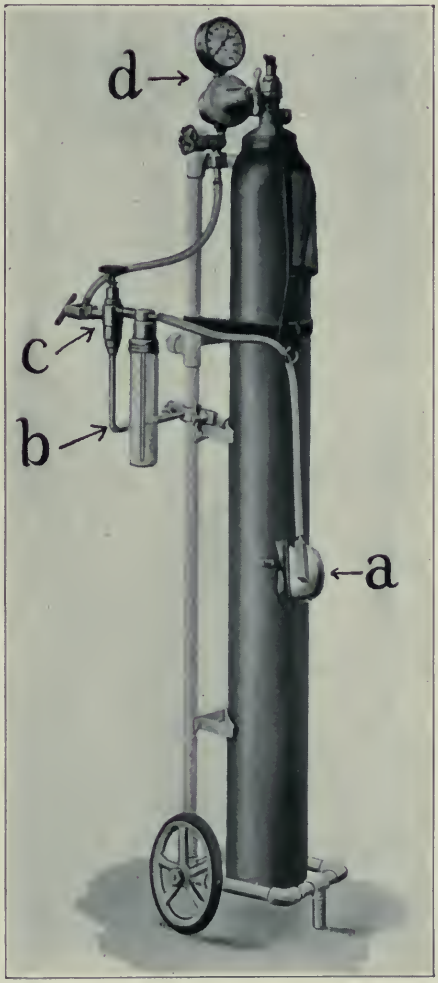

Fig. 1.—The Henderson Carbon Dioxid Apparatus as used at the Massachusetts General Hospital. The only changes from the original are that a large gas cylinder mounted on a truck is used for convenience, and a reducing valve is attached to the cylinder to reduce the high pressure: *a*, face mask; *b*, T tube dipping under a column of water which acts both as a safety valve and as a means of estimating the rate of flow; *c*, needle valve; *d*, reducing valve.

TABLE 1.—*Clinical Data*

Case	Sex*	Age	Operation	Duration of Ether Anesthesia		Condition After Anesthesia	Respiration		Pulse		Blood Pressure			Depth of Anesthesia Before Carbon Dioxid Administration	Time to Regain Consciousness, Min.	Nausea and Vomiting		Recovery
				Hr.	Min.		Average During Operation	Average with Carbon Dioxid	Average During Operation	Average with Carbon Dioxid	Normal	End of Operation	After Carbon Dioxid Administration			Before Return of Consciousness	After Return of Consciousness	
1	♀	18	Inguinal hernia	...	.30	Good	40	35	82	115	.....	.....	.....	Light	10	0	0	Uneventful
2	♂	14	Skin graft	1	..	Good	31	30	115	125	110/60	.....	130/70	Mod. deep	30	0	1	Three previous ether anesthesias with same special nurse; definitely better ether recovery
3	♂	50	None	...	12	Pale	32	30	100	108	140/80	140/80	160/80	Mod. deep	12	0	1	Operation not performed on account of skin infection
4	♂	45	Postgastro-enterostomy	1	20	Good	25	30	80	110	120/80	.....	125/80	Light	14	1	8	In very good condition
5	♀	38	Appendectomy	1	5	Slightly blue	40	36	104	130	128/95	105/90	135/100	Deep	20	2	0	Uneventful
6	♂	58	Carcinoma of penis	...	50	Good	30	25	105	90	125/80	105/70	130/70	Light	10	0	1	Uneventful
7	♂	45	Osteomyelitis of tibia	1	5	Pallid	29	25	90	110	125/60	115/65	125/71	Deep	17	0	0	Respiration very shallow and obstructed with mucus in beginning; great improvement with carbon dioxid; no ether discomfort on recovery
8	♀	53	Cystocele and rectocele	...	50	Slightly blue	35	35	90	108	135/80	.....	154/80	Light	10	0	0	Felt much better than after previous ether anesthesia
9	♂	20	Hernia in scar	1	50	Poor color	40	30	125	125	120/70	.....	125/70	Mod. deep	15	1	3	Resuscitated by carbon dioxid after overdose of ether
10	♂	46	Incarc. inguinal hernia	1	..	Good	33	36	125	135	120/80	110/80	125/80	Very light	3	0	0	Wide awake and not nauseated; on ward
11	♂	34	Clamp and cautery for hemorrhoids	1	3	Slightly blue	27	30	80	100	135/80	125/80	135/80	Deep	60	0	0	Carbon dioxid for 15 minutes, then beginning to move head; ether before at Mass. Gen. Hosp.; very nauseated and uncomfortable for two days; no complaints at this time
12	♀	41	Cholecystectomy	...	55	Poor color	35	32	120	120	115/70	100/70	120/70	Deep	60	0	0	Carbon dioxid for 15 minutes to improve color; woke up quite clear in head; on ward; at previous operation much troubled by nausea
13	♀	58	Ventral hernia	1	28	Fair	35	32	85	...	185/80	.....	.....	Very light	3	0	0	Commented on comfortable recovery after discomfort and nausea with previous ether anesthesia

14	♀	46	Hysterectomy	1	10	Good	45	32	110.	105	132/80	125/75	140/80	Deep	..	0	0	Carbon dioxid for 15 minutes.; then slept 1 hour and 40 minutes; on ward; died of sepsis
15	♂	21	Skin graft	1	15	Good	25	27	110	115	120/80	115/80	135/80	Light	14	1	0	Mueh more rapid recovery than after six previous ether anesthesias
16	♀	57	Careinoma of breast	1	35	Pale (shoek?)	28	31	120	120	140/85	110/85	130/85	Deep	50	2	0	Carbon dioxid for 20 minutes; shallow respirations, low blood pressure and poor color, all markedly improved; continued in good shape; on ward
17	♂	37	Inguinal hernia	1	40	Slightly blue	34	24	95	108	120/80	120/80	145/80	Deep	40	0	0	Mild bronchopneumonia on next day
18	♂	20	Appendeetomy	...	50	Good	25	35	100	114	.....	.....	.....	Light	13	0	0	Uneventful
19	♂	44	Inguinal hernia	1	30	Poor eolor	30	24	100	85	140/80	.....	130 80	Mod. deep	13	0	0	Hard to etherize; fat; slept for 2 hours; on ward
20	♀	50	Choleeystetomy	1	3	Very blue	48	45	110	120	140/85	130/80	145/80	Light	19	0	1	Very hard to relax; stopped breathing onee; mueh mueus; earbon dioxid caused rapid improvement; felt mueh better than after previous operation
21	♀	22	Suspension and repair of eervix	1	35	Good	35	35	88	95	120/85	125/80	135/80	Deep	24	1	0	Uneventful
22	♂	50	Perineal prostatetomy	1	..	Slightly blue	35	32	95	90	140/80	105/80	130/80	Light	7	0	0	No after-effeets of ether anesthesia; immediate return of appetite
23	♀	17	Appendeetomy	1	10	Good	40	40	100	110	125/80	.....	135/80	Light	10	2	0	No ether discomfort
24	♀	14	Pyelotomy	2	..	Good	36	36	100	120	125/70	110/.0	130/.0	Light	10	0	0	No ether discomfort
25	♀	25	Fistula in ano	...	58	Good	40	32	120	115	120/75	110/75	130/75	Mod. deep	17	0	0	No ether discomfort
26	♀	40	Careinoma in sear	...	41	Good	25	24	90	120	125/80	.....	130/80	Very light	5	0	1	Appetite returned for supper; after previous ether anesthesia, tasted the ether for 2 days
27	♂	17	Cerebellar tumor	1	50	Severe respiratory depression	18	20	130	120	120/70	95/70	108/70	Light	10	0	0	Respiration returned to normal and continued so after three hours; uneventful eonvaleseenee
28	♀	25	Cerebellar tumor	1	15	Marked respiratory depression; deep eyanosis	15	22	...	...	.....	.....	.....	Mod. deep	60	0	0	Carbon dioxid in deereasing amounts for three hours; if stopped completely respiration beeame very shallow and eolor dusky; uneventful eonvaleseenee
29	♀	23	Cerebellar tumor	3	..	Mueh hemorrhage; resp. depression on turning patient on back	30-60	40	120	140	123/90	110/70	120/78	Mod. deep	60	0	0	Color, respiration and general eondition mueh improved; eondition fair next morning, then Cheyne-Stokes respiration and death; necropsy: eyst size of hen's egg pressing on medulla

* In this column, ♀ indicates female; ♂, male

TABLE 1.—*Clinical Data (Continued)*

Case	Sex*	Age	Operation	Duration of Ether Anesthesia		Condition After Anesthesia	Respiration		Pulse		Blood Pressure			Depth of Anesthesia Before Carbon Dioxid Administration	Time to Regain Consciousness, Min.	Nausea and Vomiting		Recovery
				Hr.	Min.		Average During Operation	Average with Carbon Dioxid	Average During Operation	Average with Carbon Dioxid	Normal	End of Operation	After Carbon Dioxid Administration			Before Return of Consciousness	After Return of Consciousness	
30	♂	51	Left temporal decompression for fractured skull	1	..	Very insufficient respiration	6	15	...	...	.....	.....	.....	Mod. deep	15	0	0	Condition considered critical on account of respiratory depression until carbon dioxid was used; spontaneous normal respiration after 1 hour and 15 minutes
31	♂	48	Varicose veins	1	20	Good	30	25	90	...	.....	.....	.....	Mod. deep	18	1	2	Appetite for supper
32	♂	20	Appendectomy and varicose veins	1	30	Good	30	30	120	...	.....	.....	.....	Deep	37	1	0	After previous operation complained of ether effects for 2 days; no complaint this time
33	♂	30	Submaxillary tumor	...	40	Good	20	24	80	...	.....	.....	.....	Very light	5	0	0	Appetite for supper; no complaint of ether
34	♂	51	Cholecystostomy	1	35	Poor; mod. blue	..	..	...	...	.....	.....	.....	Mod. deep	25	0	0	Stopped breathing under ether; very blue through operation; fat and a bad risk; perfectly conscious on return to ward; no complaint of ether
35	♂	25	Osteotomy of tibia for osteomyelitis	...	30	Good	..	..	...	...	.....	.....	.....	Light	10	0	0	Several previous ether anesthesias with vomiting; talked in 20 minutes
36	♂	25	Tubere. gland of neck	...	40	Good	..	..	...	...	.....	.....	.....	Light	15	0	0	Three previous ether anesthesias with much vomiting; talked in 35 minutes; went home next day
37	♀	45	Hysterectomy	1	5	Good	..	..	...	...	.....	.....	.....	Light	7	1	0	No gastric discomfort; talked in 30 minutes
38	♀	50	Salpingectomy	1	9	Good	..	..	...	...	.....	.....	.....	Light	10	0	0	Several previous ether anesthesias with much nausea; no gastric discomfort this time
39	♀	40	Hysterectomy	1	..	Good	..	..	...	...	.....	.....	.....	Light	10	0	0	
40	♀	50	Hysterectomy	1	10	Very fat	..	..	...	...	.....	.....	.....	Very light	5	0	0	Good recovery after difficult fibroid operation
41	♂	35	Gastro-enterostomy	1	..	Breathing bad; poor color	..	.	...	...	.....	.....	.....	Mod. deep	10	1	...	Respiration and color improved at once; no gastric discomfort

patient. This is easily done by adjusting the apparatus to deliver an amount of carbon dioxid in the inspired air which stimulates the desired degree of increased ventilation in the average individual. It has been shown by Peabody [2] that the pulmonary ventilation of the average individual is nearly doubled when the carbon dioxid of the inspired air reaches 5 per cent., and is quadrupled, or more, when it reaches 6 per cent.

The simplest way to summarize these results is to consider the averages first, and then several of the most interesting cases separately. The mean duration of anesthesia was one hour and eight minutes. The average rate of respiration at the end of the anesthesia was 31 per minute, but it was very shallow. Carbon dioxid administration did not increase it; but one noted almost at once a change from the gasping movements, limited to from small excursions of the ribs to a full rise and fall of the chest assisted by the accessory muscles. The respiratory volume was very obviously increased, and it rarely took over five minutes for the common pallor of the skin and mucous membranes to be changed into a healthy pink, with complete filling of the superficial veins.

The pulse in these cases averaged 100 at the end of the anesthesia and rarely rose more than 10 points, showing clearly that there could be little strain on the heart associated with this artificial hypernea. The blood pressure had frequently fallen to 105 or 110 systolic, to rise at the end of fifteen minutes to normal, or slightly above it. In thirty-five cases in which carbon dioxid was administered uninterruptedly, the average time required for the patients to recover consciousness sufficiently to open their eyes in response to their names was fourteen minutes. If carbon dioxid was discontinued at this point, they would relapse again, probably either because of liberation into the blood of a surplus of ether in the tissues, or owing to the fact that, although during the carbon dioxid hyperpnea the tension of ether in the arterial blood was kept below anesthetic concentration, that in the venous blood was still sufficient to induce a return of unconsciousness, on reaching the brain, after the carbon dioxid hyperpnea had stopped. On the other hand, if the administration was continued from five to ten minutes beyond this point, the patients remained wide awake and were fully conscious on return to the ward. In two cases in which deep anesthesia was purposely maintained until carbon dioxid administration could be started, consciousness returned in twelve and seventeen minutes. In a control series of forty similar but untreated cases taken from the

2. Peabody, F. W.: Clinical Studies on the Respiration. I. The Effect of Carbon Dioxid in the Inspired Air on Patients with Cardiac Disease, Arch. Int. Med. **16**:846 (Nov.) 1915.

hospital records, the average time taken to recover consciousness was one hour and fifteen minutes.

Of forty-one patients, only eight complained of nausea or any vomiting after regaining consciousness; while out of a control series of fifty untreated ether patients, 88 per cent. of the women and 50 per cent. of the men complained of definite discomfort due to nausea and vomiting, which they attributed to the effects of the ether. Thus, it can be seen that this treatment shortened the average recovery rate from three to five times and very definitely reduced the incidence of nausea and vomiting. Ten of these patients of their own accord mentioned previous disagreeable experiences after ether anesthesia of similar duration and operations of equal severity, and commented on how much better they felt after this treatment. Of these, a patient with gallbladder disease and one with a ventral hernia, both elderly women, who had previously been nauseated for three days, recovered without a trace of gastric discomfort. With a single exception, every patient who had had previous ether anesthesia commented on how much better he felt on recovery after this treatment.

In another case (Case 9, Table 1), a young Italian being operated on for hernia was given an overdose of ether accidentally. Respiration had sunk to slight gasps and had remained so for several minutes, while a nasal tube and mouth gag were tried without effect. Meanwhile, the patient had become intensely cyanotic, with widely dilated pupils. Carbon dioxid administration was tried instead of artificial respiration. After the first shallow gasps, the rate and depth of breathing both began to increase, so that in three minutes all cyanosis had disappeared, and ether anesthesia was continued. All this was done without interrupting the progress of the operation.

Finally, there were four brain cases,[3] each placed on the danger list immediately after operation because of profound respiratory depression. The first was a glioma in a boy of 17 (Case 27, Table 1). The operation lasted one hour and fifty minutes, and removal of the growth was incomplete. Respiration continued normal through the operation, only to take a sudden drop as the patient was turned on his back on removal from the table. When he was first seen, two hours later, his respiratory rate had not exceeded six per minute. He was still deeply under the anesthesia; the respirations were shallow; the blood pressure was 95 systolic, 70 diastolic, and the general appearance was very poor. Administration of carbon dioxid brought the respiratory rate up to 24 in ten minutes, and awakened him fully in twenty minutes.

From then on, it required the smallest possible amount of carbon dioxid to keep the respirations at 15, and of good depth, though if the

3. For the opportunity to study these brain cases I am indebted to Dr. William J. Mixter.

gas was stopped altogether the breathing tended to relapse. In an hour and a half, the blood pressure rose to 108 systolic, 70 diastolic. At the end of three hours, normal respiration continued spontaneously, and he has made an uneventful recovery since. In this case, the cause of the respiratory depression seems to have been a direct pressure on the medulla, such as may occur in a lumbar puncture in brain tumor. The onset was sudden and took place when the patient was turned on his back. This would suggest that a depressed respiratory center which cannot respond to the normal amount of carbon dioxid in the blood can react to an increased concentration.

The second patient (Case 28, Table 1), was a woman of 25. Ether administration was stopped at the end of unsuccessful cerebellar exploration lasting one hour and fifteen minutes. While the patient was still lying face down, the breathing rate gradually slowed to 4 per minute and the inspiration became so shallow that all apparent respiratory exchange had ceased. She became intensely cyanotic. Carbon dioxid administration was started by the etherizing nurse, and the respiration rate rose to 22 almost immediately, with a return of a normal pink color. The patient recovered consciousness at the end of one hour, but had to be given intermittent and decreasing doses of carbon dioxid for three hours more, as, without it, cyanosis and respiratory failure gradually returned. At the end of this time, normal breathing continued of itself, and the patient has since made a satisfactory recovery.

The third patient (Case 29, Table 1) was a woman of 23 who, after a long continued cerebellar exploration, developed a profound respiratory depression immediately after being moved from the operating table. She also became intensely cyanotic but was completely relieved by administration of carbon dioxid given for one hour and fifteen minutes. Spontaneous respiration in this case was only temporarily restored. The patient died on the day following operation. Necropsy revealed a large cyst pressing on the medulla.

Lastly, in a case of fractured skull (Case 30, Table 1), causing slow and inadequate respiration, a left temporal decompression brought about no immediate improvement, and the patient was left in a very critical condition. His respiratory rate at the end of the operation was 6 per minute, and he was cyanotic and still deeply anesthetized. He was revived by administration of carbon dioxid, and it was found that his respiration could thus be absolutely controlled and held at any desired level. He came out of the anesthesia in twenty minutes, and after an hour and a half, normal respiration continued, unaided.

It should be emphasized that, in all four of these cases, the depression of respiration was so great that the operating surgeon doubted that the patient would ever return to consciousness.

TABLE 2.—*Laboratory Data*

Patient, Operation, and Anesthetic	Time	Stage	Ether Concentration in Gm. per Liter of Blood	Pulmonary Ventilation, Liters per Min.	Remarks
1. Mr. C. N., aged 27; repair of bilateral inguinal hernia; Mass. Gen. Hosp. cone method; morphin, ¼ grain; atropin, 1/120 grain	10:13	Induction	....	....	
	11:10	Middle op.	1.00	....	
	12:00	End ether	1.02	....	
	12:10	Recovery	0.79	....	
	12:20		0.64	....	Very shallow respiration
	1:00		0.55	....	Beginning to retch
2. Mrs. E. M., aged 46; cholecystectomy; Mass. Gen. Hosp. cone method; morphin, ⅙ grain; atropin, 1/120 grain	10:27	Ether started	....	....	
	11:00	Ether stopped	....	....	
	11:15	Recovery	0.95	....	Sewing up incision
	11:30		....	6.7	
	11:45		0.53	5.3	Shallow, rapid respiration
	12:00		0.51	4.0	Shallow, rapid respiration
	12:30		0.38	7.6	Opened eyes and vomited
3. Mr. C. C., aged 31; perforated gastric ulcer; postgrastro-enterostomy; morphin, ¼ grain; atpin, 1/200 grain; Mass. Gen. Hosp. cone method	10:30	Ether started	....	....	
	11:20	Ether stopped	....	....	
	11:35	Recovery	0.54	....	
	12:00		0.45	10.0	Normal resp., therefore fairly rapid elimination
	12:30		0.37	10.6	
	12:45		....	....	Opened eyes
	1:30		0.18	7.5	Cooperative but not well oriented
	2:45		0.16	....	Asleep
	3:00		0.155	....	Asleep
	4:00		0.145	....	Asleep
	5:30		0.10	....	Wide awake and clear mentally
4. Mrs. J. H., aged 50; varicose veins, both legs; Mass. Gen. Hosp. cone method; morphin, ⅛ grain; atropin, 1/120 grain	10:00	Ether started	....	....	Patient extremely fat
	10:10	Induction	....	16.0	
	10:20	Operation	....	9.5	
	11:00		....	7.9	
	11:45		....	8.3	
	12:00		....	7.9	
	12:30		1.00	6.1	
	12:35	Ether stopped	....	....	Ether
	12:37	Recovery	0.77	....	
	12:50		0.73	7.0	
	1:00		0.68	6.4	
	1:45		....	....	Conscious
	4:30		0.24	....	Still semistuporous
5. Mrs. M. B., aged 64; cholecystectomy; Mass. Gen. Hosp. cone method; morphin, ⅙ grain; atropin, 1/120 grain	10:26	Ether started	....	....	
	10:35	Operation	0.81	....	Skin incision
	10:50		0.91	....	Removing gallbladder
	11:10		0.86	....	Sewing up
	11:13	Ether stopped	....	....	
	11:30	Recovery	0.66	5.0	Shallow breathing
	12:13		....	....	Eyes open, answers question drowsily
	2:43		0.20	....	Eyes open, mind not yet clear
	24 hr.		0.008	....	Complains of ether
	48 hr.		Trace	....	No further perception of ether
6. Mr. F. P., aged 58; repair of bilateral recurrent inguinal hernia; Mass. Gen. Hosp. cone method; morphin, ¼ grain; atropin, 1/100 grain	11:17	Ether started	....	....	
	12:45	Operation	....	5.0	
	1:03		1.48	6.3	
	1:06	Ether stopped	....	....	
	1:10	Recovery	1.38	7.6	
	1:15		0.98	....	
	1:20		0.93	6.7	
	1:27		0.64	....	
	1:36		0.63	....	
	2:45		0.32	5.6	Conscious at 2:35
	24 hr.		0.006	....	Nauseated and tasting ether
7. Mr. W. L., aged 26; periarterial sympathectomy; Mass. Gen. Hosp. cone method; morphin, ¼ grain; atropin, 1/100 grain	9:48	Ether started	....	....	
	9:50	Induction	....	20.0	Hyperpnea
	10:00	Operation	....	12.0	Hyperpnea
	10:15		0.94	9.3	
	11:00		1.10	8.8	
	11:30	Ether stopped	1.40	....	
	11:36	Recovery	1.20	10.0	
	11:50		0.86	....	Marked resp. obstruction
	12:00		0.67	3.4	Cyanotic; blood pressure, 110/80
	12:30		0.62	4.0	
	1:30		....	....	Conscious
	2:30		0.25	4.9	Slightly cyanotic
	3:30		0.26	6.6	Very slow recovery probably due to depth of anesthesia and shallow breathing

TABLE 2.—*Laboratory Data (Continued)*

Patient, Operation, and Anesthetic	Time	Stage	Ether Concentration in Gm. per Liter of Blood	Pulmonary Ventilation, Liters per Min.	Remarks
8. Mr. A. F., aged 20; appendectomy and operation for varicose veins; Mass. Gen. Hosp. cone method; morphin, ¼ grain; atropin, 1/120 grain	10:15	Ether started	....	....	
	10:20	Induction	....	32.0	Marked hyperpnea
	10:25		....	18.5	Marked hyperpnea
	10:30		....	14.8	Marked hyperpnea
	10:45	Operation	0.73	13.5	Marked hyperpnea
	11:00		1.2	10.0	
	11:50	Ether stopped	1.0	4.6	
	12:02	Recovery	....	....	Carbon dioxid started
	12:05		0.81	32.0	Vomited; carbon dioxid off
	12:20		0.63	37.0	
	12:25		0.48	....	
	12:30		0.35	32.0	Conscious
9. Mr. H. K., aged 51; Exploration for carcinoma of pancreas; poor risk; Mass. Gen. Hosp. cone method; morphin, ¼ grain; atropin, 1/120 grain	10:15	Ether started	....	....	
	10:25	Induction	....	12.6	Slight hyperpnea; cyanotic
	10:30		....	10.0	Very cyanotic
	11:00	Operation	0.9	4.0	Stopped breathing for 30 min.; very cyanotic
	11:45	Ether off	....	....	Color improving slightly
	11:48	Recovery	0.85	3.5	
	11:55		0.71	....	Carbon dioxid started
	12:05		0.54	17.5	Color much improved
	12:10		....	....	Opened eyes
	12:30		0.26	34.0	
	12:33		....	....	Carbon dioxid off
	12:40		....	10.0	
	1:30		0.16	....	Perfectly clear mentally; no ether discomfort
10. Mr. M. K., aged 48; varicose veins of both legs; Mass. Gen. Hosp. cone method; morphin, ¼ grain; atropin, 1/120 grain	9:55	Ether started	....	....	
	10:25	Operation	0.73	....	
	10:35		0.89	....	
	10:48		0.86	....	
	11:00		0.98	....	
	11:15	Ether stopped	....	....	
	11:20	Recovery	0.83	5.05	
	11:30		....	....	Carbon dioxid started
	11:32		....	21.0	
	11:40		0.59	40.3	
	11:48		0.36	47.0	Conscious; vomited
11. Mr. C. T., aged 19; freeing adhesions and ceecopexy; Mass. Gen. Hosp. cone method; morphin, ¼ grain; atropin, 1/150 grain	10:40	Ether started	....	....	
	10:50	Induction	....	13.5	
	10:55		....	10.0	
	11:00	Operation	1.40	7.5	
	11:15		....	8.0	
	11:30		...	4.8	
	11:40	Ether stopped	....	....	
	11:48	Recovery	1.05	8.4	
	11:55		0.9	....	
	12:00		0.7	8.8	
	12:25		0.54	5.3	Vomiting
	1:10		0.37	....	Restless; unconscious
	3:00		0.31	6.0	Began carbon dioxid; very nervous, vomiting, many complaints
	3:05		0.18	32.8	Carbon dioxid
	3:15		0.145	23.2	Carbon dioxid; much clearer mentally
	3:25		0.155	23.2	Carbon dioxid stopped
	3:35		....	5.5	
	5:40		0.10	....	No further nausea; felt much better
12. Master J. C., aged 10; bone plate for fractured femur; drop method; morphin, 1/12 grain; atropin, 1/150 grain	12:00	Ether started	....	....	
	12:07	Induction	....	18.3	
	12:11		....	16.8	
	12:20	Operation	1.65	10.0	
	12:30		....	8.7	
	12:40		1.45	14.7	Hyperpnea due to trauma of manipulation
	12:55		1.47	....	Reduction of fracture
	1:00		1.55	11.5	
	1:40		....	15.0	Screwing in bone plate
	1:50	Ether off	....	....	Pulse 140–150
	1:55	Recovery	0.54	6.0	
	2:05		....	5.8	Vomited; pulse, 150+
	2:20		0.43	3.0	Pallor, cold extremities, slow, shallow respiration
	2:40		....	....	Carbon dioxid and subpectoral saline
	2.45		....	....	Improvement in color and respiration
	2:50		....	....	Opened eyes
	3:00		....	....	Talking, pulse 130, carbon dioxid stopped
	4:00		....	....	Wide awake; color and respiration good; pulse, 120

Of these forty-one patients, one has developed a mild post-ether pneumonia, and one, following hysterectomy, died of pelvic sepsis. The other thirty-nine have all made excellent recoveries. No patient has shown any strain on the wound from the hyperpnea, or any untoward results from the carbon dioxid.

LABORATORY STUDIES

The ether concentrations of the venous pulmonary air were determined by obtaining Plesch-Higgins [4] air samples, drawing off the ether air vapor into gas collecting tubes over mercury and analysing them by the method of Haggard.[5] The ether tensions found in the alveolar air in equilibrium with the venous blood were for convenience transposed into the figures for venous blood by the formula worked out by Haggard:

$$\frac{\text{Ether in alveolar air}}{\text{Ether in venous blood}} = \frac{1}{15.2}$$

Pulmonary ventilation was measured by a 6 liter spirometer and a simple face mask into which the patient breathed for a few seconds. The volume of the tidal air was so determined, and multiplied by the rate of respiration to give the volume breathed per minute.

These two procedures take less than a minute each, and, as little ether is lost in the process, do not materially interfere with the work of the anesthetist.

The studies of ether tension and pulmonary ventilation during operation and recovery give certain definite findings:

1. Shape of Recovery Curve.—During the first few minutes after administration of ether is stopped, elimination is extremely rapid; so that the normal patient puts out one half of the total ether in his body in the first thirty minutes. The curve then flattens out so that it takes from one to two hours to ventilate out a half of the remainder, and from one to two days for the last traces to disappear from the blood. The shape of the curve has several important clinical applications. The rapidity of deetherization at its onset accounts for the efficiency of artificial respiration after an overdose. The later flattening of the curve accounts for the wide variations in the time required for recovery, as patients with good ventilation and with a light anesthesia reach the the level of consciousness while the curve is still on a sharp incline;

4. Boothby, W. M., and Peabody, F. W.: A Comparison of Methods for Obtaining Alveolar Air, Arch. Int. Med. **13**:497 (March) 1914.

5. Haggard, H. W.: An Accurate Method of Determining Small Amounts of Ethyl Ether in Air, Blood, and Other Fluids, J. Biol. Chem. **55**:131 (Feb.) 1923.

while others in whom the curve has flattened above this level require a disproportionately long time to wake up.

2. Level of Ether Tension During Operation and Recovery.—On comparing the clinical depth of anesthesia with the ether analyses,[6] a perfectly constant relationship is seen running through the entire series; From 1.0 to 1.5 gm. of ether per liter of venous blood gives full surgical anesthesia; 0.7 to 1.0, light anesthesia; with from 0.5 to 0.6, the reflexes are active and the patient often vomits; with from 0.3 to 0.4, the patient opens his eyes; with 0.2, he is fully conscious.

The chief subjective discomfort comes with between 0.4 and 0.2 gm. of ether, although an occasional patient may continue to feel nauseated and overwhelmed by the ether until the last traces leave the system.

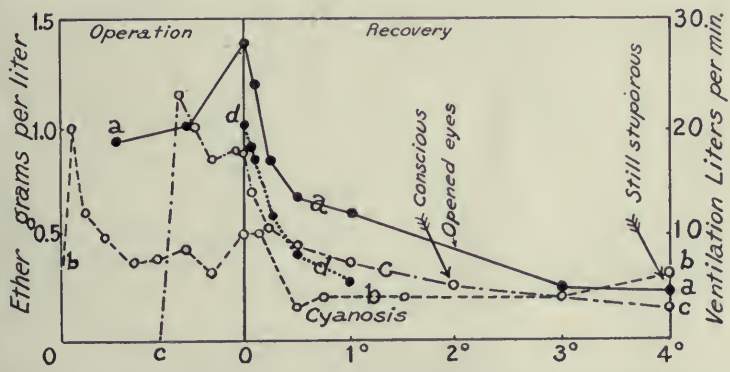

Fig. 2.—*a*, typical curve of ether concentration during anesthesia and recovery as calculated by the author; *b*, typical minute volume of respiration curve, also calculated by the author; *c*, ether concentration curve as found by Gramen in the venous blood of man; *d*, deetherization curve as found in dogs' venous blood by Nicloux. The zero hour is the time at which etherization was discontinued. The time intervals for the period of the operation are drawn on a similar scale. The beginning of anesthesia in the case of *c* is at the point where that curve leaves the base line.

3. Pulmonary Ventilation.—It is generally believed that ether in light anesthesia acts as a stimulus; whereas, in high concentrations, it is a respiratory depressant. But, to my knowledge, no measurements have heretofore been made an actual minute volumes of air breathed during anesthesia in human beings.

Figure 3 shows that respiration may be doubled to quadrupled in ether inductions even after one-fourth grain of morphin is given as

6. The relative values of the anesthetic tensions are independent of the method of calculating ether concentrations in the blood from the analysis of expired air; but the absolute values may be subject to slight revision as analytic methods are still further improved.

preliminary medication. During operation, the average patient under a deep anesthesia breathes about 6 to 8 liters of air per minute (similarly to a normal individual at rest in bed). But if the anesthesia becomes too light or there is severe trauma from manipulation, a prolonged

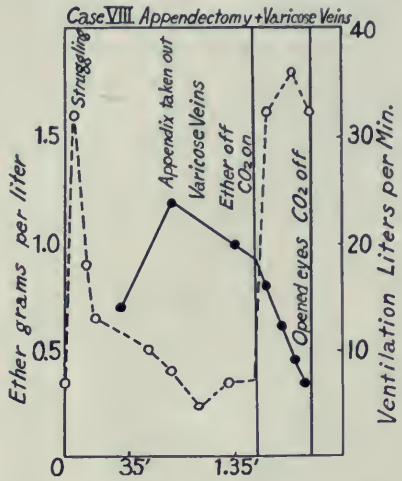

Fig. 3.—Pulmonary ventilation (interrupted line) and ether concentration (solid line) during an operation, and recovery period with carbon dioxid treatment. The record starts at the beginning of anesthesia.

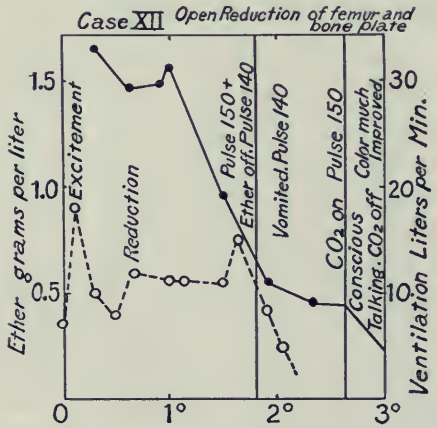

Fig. 4.—Pulmonary ventilation (interrupted line) and ether concentration (solid line) in an operation causing severe trauma and shock. Carbon dioxid treatment was given in the recovery period.

hyperpnea may occur. When the abnormal stimulus causing the hyperpnea is removed, a period of respiratory depression usually follows.

This is particularly well shown in Figure 4. The patient was a boy of 10. The operation was an open reduction for a fracture in the middle third of the femur. The figure shows the initial hyperpnea of induction, soon falling to normal and then being succeeded by exaggerated breathing throughout the long operation, caused by the severe trauma of reduction and putting in a bone plate. At the end of the operation, the breathing was extremely shallow and the pulse so rapid and of such poor tension that it was difficult to count.

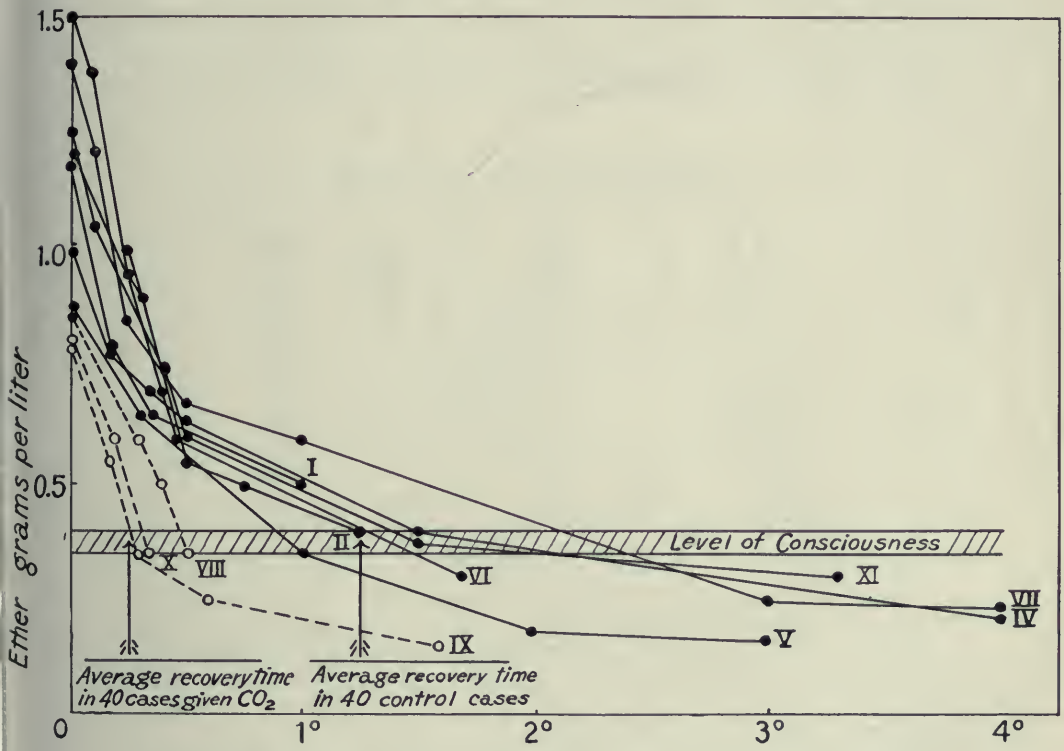

Fig. 5.—A series of ether concentration curves in patients recovering spontaneously (solid lines) and in patients receiving carbon dioxid treatment (interrupted lines). Arrows denote average recovery times of total untreated and treated cases. The record starts at the end of anesthesia, and recovery period only is shown. The zone of recovery of consciousness is indicated.

These cases and their striking response to carbon dioxid are strong evidence in favor of Henderson's contention that hyperpnea may cause such an appreciable loss of carbon dioxid that its tension in the blood is insufficient to stimulate the respiratory center.

4. *Effect of Carbon Dioxid Treatment.*—In Figure 5 are given the curves of all the recoveries during which ether analyses were made.

It shows very strikingly the increased speed of recovery in the cases treated with carbon dioxid. The reason for this can be seen by a glance at the respiratory measurements in Table 2. This shows that the pulmonary ventilation in the patients treated with carbon dioxid was raised to from 25 to 35 liters per minute. The response was instant and universal. By increasing the volume of respiration from 5 to 8 times, the fall of the deetherization curve is made so abrupt that it does not flatten out until the patient is fully conscious and well past the stage of discomfort and depression from the drug.

Figure 6 presents a case in point. A fat, jaundiced man of 51 had been in poor condition for a year following an operation for gallstones. After considerable struggling and exaggerated breathing in induction,

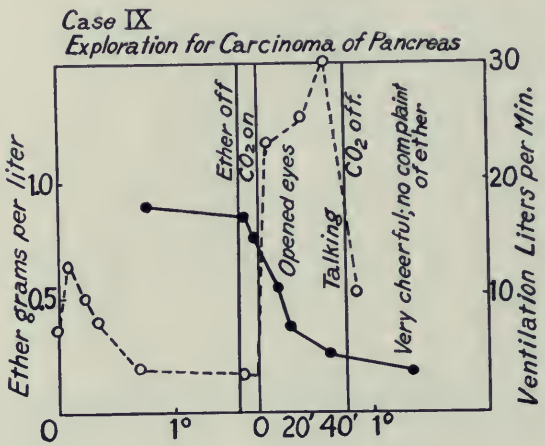

Fig. 6.—Pulmonary ventilation (interrupted line) and ether concentration (solid line) during an operation in which breathing became quite unsatisfactory and marked cyanosis was present. Carbon dioxid treatment given in recovery period produced rapid return to consciousness and permanent improvement in respiration. The first zero hour is at the beginning of anesthesia; the second, at the beginning of carbon dioxid administration.

he developed very shallow respiration, stopped breathing for a moment, and then remained quite cyanotic throughout the operation. Inoperable carcinoma of the head of the pancreas was found, and the wound was closed. He was immediately given carbon dioxid, with rapid improvement in color and return of consciousness in fifteen minutes. After thirty-five minutes' respiration at an average minute volume of 25 liters, he was talking in a rational manner and had experienced no nausea or other discomfort from the ether.

Expressed in quantitative terms, the curve of elimination had continued to fall rapidly and had not flattened until well below the level at which any symptoms normally persist. He continued without any

discomfort from the ether, and made an unusually smooth convalescence. Control cases with the same initial depth of anesthesia and similar pulmonary ventilation took upward of an hour to recover consciousness.

In the case of patients who have regained consciousness but are particularly depressed and nauseated by the ether, carbon dioxid seems capable of producing a definite improvement. Figure 7 presents such a case. A neurasthenic youth of 19, who claimed that he had had a particularly hard time after ether anesthesia a year previously, had to be operated on again to free appendix adhesions. He required one and one half hours to recover consciousness, and then lay in a semi-stuporous condition, with numerous attacks of vomiting, for another period of similar duration. At this point, carbon dioxid was given

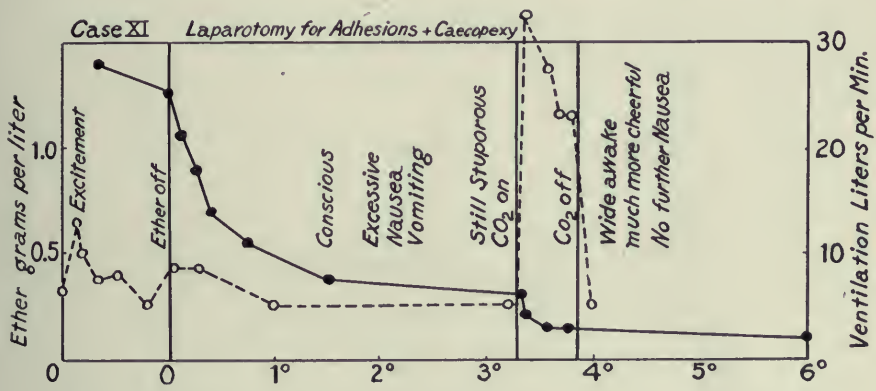

Fig. 7.—Pulmonary ventilation (interrupted line) and ether concentration (solid line) in a case in which carbon dioxid treatment was given after recovery of consciousness to relieve the symptoms of ether intoxication. The zero hour in this instance was the end of anesthesia.

for thirty minutes, reproducing the usual curve on a small scale. By the time it had flattened out, the tension of ether had reached such a low level that all nausea had disappeared, and the patient was wide awake and in a comparatively cheerful frame of mind.

Previous determinations on the rate of normal deetherization have been made by chemical analyses by Nicloux [7] and by Storm van Leeuwan [8] on dogs, and by Karl Gramen [9] on human subjects. The

7. Nicloux, M.: Anesthesia by Ether Compared with Chloroform Anesthesia, Compt. rend. Soc. de biol. **144**:343 (Feb.) 1907.

8. Storm van Leeuwan, W.: Quantitative Pharmacologic Analyses on the Reflex Function of the Spinal Cord in Mammals, Arch. f. d. ges. Physiol. **165**: 84, 1916.

9. Gramen, K.: The Ether Content in Blood, Urine, Milk and Expiratory Air, Acta. Chir. Scandinav., Supplement I, 1922.

Nicloux method of analysis required such large volumes of blood that it was not applicable to human patients. Nicloux's curve of deetherization is compared in Figure 2 with a similar one of Gramen's, to show how exactly they correspond with the figures published in this paper, obtained by an entirely distinct method of analysis and on samples of venous pulmonary air instead of venous blood.

Gramen[9] published a series of 700 observations on the ether content of blood, milk, urine and expired air. This small monograph contains a complete bibliography of all the work done on the subject abroad as well as in this country. It contains a long series of chemical analyses to establish the curve of deetherization, which he performed by Nicloux's method, with a refinement which rendered it sufficiently sensitive to use on small samples of human blood.

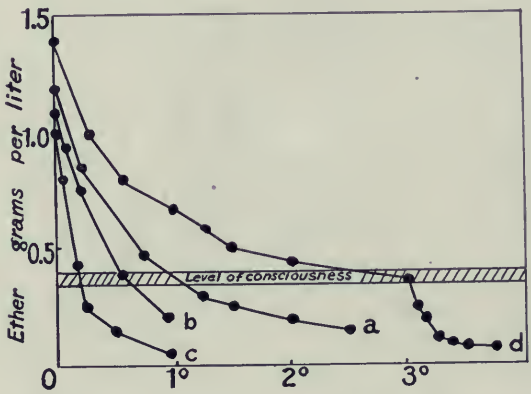

Fig. 8.—A series of ether concentration curves obtained by passing air at measured rates through ether-water mixtures; *a*, rate of air flow, 0.54 liters per minute; *b*, rate of flow, 1.00 liters per minute; *c*, 3.00 liters per minute; *d*, 0.50 liters per minute. At the end of three hours, the rate was increased to 2.5 liters per minute. The level of ether concentration at which human beings recover consciousness is inserted in this diagram for comparison.

Gramen's anesthetic tensions are exactly the same as those reported in this paper. He also obtained the same characteristic curve of deetherization, falling steeply in the beginning and flattening out so in the end that the last traces of ether do not disappear from the blood for from twenty-four to forty-eight hours. He finds the ether content of mother's milk and urine to be the same as that of the blood, and gives figures for the concentrations in the new-born infant after varying degrees of anesthesia of the mother. Finally, he concludes that duration of anesthesia, age, physical condition and weight of the patient are the factors governing the rate of elimination. It will be seen below that these conclusions are not in exact agreement with the results reported in this paper.

5. *The Mechanism of Ether Elimination.*—Haggard [10] has shown that over 90 per cent. of the ether inhaled by a dog can be quantitatively recovered in the expired air. Ether at body temperature is in the gaseous state. That it is present in the blood as a simple solution and subject to the physical laws for gases dissolved in liquids can be proved by a simple experiment. A constant stream of air is blown through a 1 liter Bohr gas meter at different speeds, and then through a 5-liter bottle containing varying concentrations of ether in water, similar to those found clinically at the end of anesthesia, and at normal body temperature. By analysing the amount of ether remaining in solution at definite intervals of time in a series of experiments with different degrees of ventilation and initial ether tension, curves were obtained which reproduced every form of the deetherization curve found in the actual patients.

A number of these curves are reproduced in Figure 8. Curve *a*, with an air flow of 0.5 liter per minute is similar to those found in actual cases in patients breathing from four to five liters (which is about the average seen after long ether anesthesia). Curve *b*, produced by a ventilation of 1 liter per minute, represents an ether patient with slightly elevated respiration of from 8 to 10 liters per minute. In such a case, our artificial ether patient reaches the level of consciousness in thirty-five minutes. In curve *c*, with a ventilation of 3 liters per minute, which is analogous to the curve of an actual patient with a minute volume of 30 liters under carbon dioxid, the elimination is so rapid that the artificial patient reaches the awakening tension in about twelve minutes.

The experiments are important because, from the exact similarity of their curves with those of actual patients given above, they show that deetherization is a purely physical process and a very simple one at that. The process in the lungs must be governed by the difference in concentration of the ether in the blood and in the alveolar air. The concentration in the latter is directly dependent on the amount of pulmonary ventilation.

Using these results in vitro to back up certain constant relationships found in the actual patients, we are justified in recognizing certain general factors which directly govern the recovery of patients from ether:

1. That the rate of deetherization is very nearly in direct proportion to the degree of pulmonary ventilation is shown in Table 3.

These cases are selected for comparison because the initial ether concentration in each is approximately the same. Considering the

10. Haggard, H. W.: Absorption, Distribution and Elimination of Ether, J. Pharmacol. & Exper. Therap., to be published.

difficulty in determining the exact moment at which the point of consciousness is reached and the varying degrees of obesity of the patients, the close mathematical relationship between the recovery times and the rates of ventilation is very striking.

2. A second probable factor is body weight in relation to lung capacity. It has been observed clinically that obese subjects require a longer time to recover consciousness than thin ones. This should follow from the fact that, in two individuals with the same effective area for diffusion of ether from the capillaries into the alveoli, the process should require more time in the fat subject whose tissues at

TABLE 3.—*Relation of Deetherization to Pulmonary Ventilation*

	Initial Ether Tension, Gm. per Liter of Blood	Average Ventilation, Liters per Minute	Time to Reduce Ether Concentration to 0.35, Minutes	
Patient 5	0.85	5.0	60	Normal recovery
Patient 4	0.80	6.5	70	
Deetherization experiment, Curve a	1.00	0.5*	60	
Deetherization experiment, Curve b	1.10	1.0*	35	
Patient 9	0.70	22.0	15	Recovery with carbon dioxid
Patient 10	0.80	35.0	18	
Deetherization experiment, Curve c	1.0	38.0*	12	

* These figures are the actual volumes of air blown through the ether-water mixtures. If they are multiplied by 10, they become of the same magnitude as those for human beings.

TABLE 4.—*Duration of Anesthesia in Relation to Recovery*

Case	Initial Ether Tension, Gm. per Liter of Blood	Average Ventilation, Liters per minute	Duration of Ether Anesthesia, Minutes	Time to Reduce Ether Concentration to 0.35, Minutes
2	1.40 (approx.)*	6	33	90
6	1.38	7	60	90
11	1.30 (approx.)*	7	115	90

* These figures were obtained by continuing curve backward parallel to other similar curves, as first samples were not obtained for some minutes after the end of anesthesia.

any given tension store considerably larger amounts of ether. This has not yet been subjected to quantitative proof, but both clinical observations and the results of the ether experiment in vitro are strong evidence in its favor.

That duration of etherization is not a direct factor in controlling recovery is shown in Table 4.

Gramen states that duration of anesthesia, age, and physical condition influence the rate of recovery. These, in my opinion, are indirect factors, depending on the all-important volume of pulmonary ventilation, as both very old and very weak individuals and those etherized for long periods are more inclined to develop depressed respiration after operation.

COMMENT

From these observations, it follows that the ideal anesthesia should be so conducted that hyperpnea and the consequent abnormal loss of carbon dioxid are reduced to a minimum. At its termination, it should be as light as possible. The first requisite can be best attained by the use of a closed apparatus in which breathing maintains the normal ratio between the carbonic acid and the sodium bicarbonate equilibrium in the body. Gatch [11] reported the advantages of this over the open or semiopen method, twelve years ago. By controlling respiration with the patient's own carbon dioxid, very rapid induction can be insured, with good respiration throughout the anesthesia; while at its termination, the patient is left with an increased supply of carbon dioxid. This causes him to go on breathing deeply and thus brings about a rapid deetherization.

During recovery, if it is apparent that the patient's respiration is definitely subnormal, either from reduction of free carbonic acid or from a depression of the respiratory center itself, the administration of carbon dioxid seems indicated. In the cases here reported, it has never failed to raise respiration to any desired level.

There are several other apparent indications. Of fifty control patients, thirty-five vomited and complained of nausea, tasting ether and other forms of post-ether discomfort, in varying degrees, as long as forty-eight hours after operation. Of the forty-one treated patients, only eight complained of any discomfort attributable to the ether, while, with a single exception, all who had had ether before stated that the last was the least unpleasant recovery from ether that they had experienced.

Therefore, it seems that carbon dioxid treatment should be of definite use in any individual who has had excessive discomfort after previous ether anesthesias; in neurasthenics, and in patient's undergoing operations for ventral hernia and other large abdominal incisions, in which vomiting is especially undesirable. It is well known that ether is deleterious to patients in shock and to those in whom there are present toxins which may be absorbed by the blood. If ether is to be used in these, it is certainly of advantage to have its effects of minimum duration.

Finally, although there is as yet no definite evidence that it is harmful for very sick patients to lie for several hours in a semietherized condition, several patients in cases of this type who have been rapidly deetherized by means of carbon dioxid have made unusually smooth convalescences.

---

11. Gatch, W. D.: The Use of Rebreathing in the Administration of Anesthetics, J. A. M. A. **57**:1593 (Nov. 11) 1911.

The only conditions that have so far been considered as contraindications are excessively high blood pressure, severe cardiac complications, operations on the chest and respiratory passages and marked degrees of acidosis.

That carbon dioxid can be used to stimulate a respiratory center depressed by causes other than ether administration is shown by Cases 27, 28, 29 and 30 in Table 1. The improvement in respiration and in the patient's general condition in all four of these operations on the brain was quite remarkable. Also, a patient with an inoperable brain abscess was kept alive for some time after spontaneous respiration had become definitely insufficient by the use of carbon dioxid instead of artificial respiration. Its advantages in this connection lie in the fact that it can be kept up for long periods with much less disturbance to the patient and infinitely less trouble to the attendant.

TABLE 5.—*Changes in Hydrogen-Ion Concentration of the Blood (Appendectomy; Ether, 55 Minims)*

	Arterial Carbon Dioxid Concentration % by Vol.	Arterial Carbon Dioxid Tension, Mm.	p_H	Arterial Oxygen Saturation, per Cent.
Before ether administration...	54.0	40.0	7.38	98
After ether administration.....	56.0	54.0	7.26	91
After administration of carbon dioxid for 30 minutes....	54.0	51.1	7.27	100

The one theoretical objection which has been raised against this procedure is based on the work of Van Slyke, Austin, and Cullen.[12] These observers, in a series of experiments on the acid-base equilibrium of dogs under ether anesthesia, found a rapid and pronounced increase of the H-ion concentration in the blood. In view of this acidosis produced by ether, it has been questioned whether the addition of carbonic acid to the blood is not an unjustifiable procedure. It has been stated above that no symptoms of acidosis have been seen to develop in any patient treated with carbon dioxid. To check these clinical observations in the laboratory, the changes in hydrogen-ion concentration of the blood were determined by obtaining the carbon dioxid dissociation curve and plotting the carbon dioxid diagram of the blood after the method of Henderson and Haggard.[13] These figures, determined immediately before and after ether anesthesia and after the administration of carbon dioxid for thirty minutes, are given in

12. Van Slyke, D. D.; Austin, J. H., and Cullen, G. E.: The Effect of Ether Anaesthesia on the Acid Base Balance of the Blood, J. Biol. Chem. **53**:277 (Aug.) 1922; Proc. Soc. Exper. Biol. & Med. **17**:169, 1920.

13. Haggard, H. W., and Henderson, Yandell: Hemato-Respiratory Function, J. Biol. Chem. **39**:163 (Aug.) 1919.

Table 5. For these analyses, I am indebted to Drs. A. V. Bock and H. Field, Jr., of the Massachusetts General Hospital.

It is seen that after a relatively short and simple operation, the p_H had fallen from 7.38 to 7.26. Thirty minutes later, after carbon dioxid treatment, the patient was fully conscious and the p_H of his blood had risen to 7.27. Certainly, the acidosis has not been increased by the carbon dioxid. This evidence is only that of a single experiment, and it is important that these observations be repeated in a number of operations of varying duration and severity.

CONCLUSIONS

An extended study of the problem in many clinics where conditions can be carefully controlled will be necessary before the actual practical value of this method can be definitely known; but on the basis of a study of forty cases, the following conclusions are drawn.

1. The use of carbon dioxid to accelerate deetherization by stimulating respiration confers the following benefits: (*a*) the volume of respiration can be raised to any desired level; (*b*) recovery of consciousness is from three to five times more rapid; (*c*) blood pressure, circulation and color are materially improved; (*d*) nausea, vomiting and other subjective disagreeable sensations following ether anesthesia are reduced.

2. Other indications for the use of carbon dioxid as a stimulus to respiration are: (*a*) in cases in which the respiratory center is depressed, not by the ether but by direct pressure or injury; for example, the above mentioned cases of cerebellar tumor, brain abscess and fractured skull, in which carbon dioxid was the means of restoring normal respiratory function; (*b*) in the treatment of failing respiration during the period that ether is given. Whether this is due to a hypocapnea following a period of exaggerated breathing, or to an actual depression of the respiratory center by the ether, the findings in two cases suggest that carbon dioxid can restore normal respiration.

3. In no instance have any signs of acidosis or other harmful effects attributable to carbon dioxid been noted.

4. The tensions of ether at different depths of anesthesia and a characteristic curve of deetherization were obtained and found to be exactly similar to results previously published by Nicloux and by Gramen.

The spirographic measurements showed that ether in induction is accompanied by increased pulmonary ventilation but that the volume of breathing after prolonged anesthesia or periods of hyperpnea falls to subnormal levels.

Experimental aeration of ether-water mixtures gave a series of deetherization curves which were identical with those of actual patients. This shows that the elimination of ether from the blood is a simple physical process governed by the laws of diffusion.

Therefore, the two chief factors governing the rate of recovery are the (1) volume of air entering and leaving the chest and (2) the amount of ether in the body at the end of anesthesia.

ENDOTHELIOMA OF THE SPLEEN

A STUDY OF TWO CASES, WITH REVIEW OF THE LITERATURE OF PRIMARY MALIGNANCY OF THE SPLEEN *

CURTIS E. SMITH, M.D.
AND
G. Y. RUSK, M.D.
SAN FRANCISCO

Malignant neoplasms arising primarily in the spleen are found so infrequently as to be considered pathologic curiosities and so have been of little interest to the clinician. Textbooks of pathology and surgery merely mention the fact that they do occur. The largest group previously reported consists of thirty-two cases, which would lead one to infer that this disease is practically as rare as Gaucher's primary splenomegaly; but search of the literature shows a total of about 100 cases of malignant tumors. In more than 40,000 surgical cases at the Boston City Hospital, there occurred but two primary malignant tumors of the spleen. At the Massachusetts General Hospital, the diagnosis of primary sarcoma of the spleen has been made in four cases. The first came to operation and was reported by Warren. In the other three instances, the diagnosis was made by Cabot and others on the basis of clinical findings and was not substantiated by operation or necropsy. Two cases treated by splenectomy have been reported from the Mayo Clinic.

Many of the earlier cases reported were not studied with convincing thoroughness. In many instances, either clinical histories or microscopic studies are lacking, and a number were reported as carcinoma or unspecified malignant disease. Some were probably confused with Banti's disease or simple hyperplasia. Even in many later reports the terminology lacks uniformity, and one meets a miscellaneous group of cases in which doubt exists as to the exact nature of the new growth.

There are present in the spleen three types of tissue from which neoplasms may arise: (1) the capsular and trabecular framework, which may give origin to fibroma and fibrosarcoma; (2) the lymphoid elements from which may arise either a simple lymphoma (at times so-called lymphadenoma) or a malignant lymphoblastoma, that is the so-called lymphosarcoma, and (3) angiomas and cavernous angiomas, together with the malignant counterpart, the endotheliomas, arising from vascular or sinus endothelium. A group of hyperplasias owe their origin to the pulp, and in particular to the endothelial cells that line the

* From the Department of Pathology, University of California Medical School and Hospitals.

sinuses. Simple hyperplasia of this element is found in many conditions. One of the most interesting is a special form of hyperplasia which borders cosely on the group of true neoplasms and is designated as Gaucher's disease.

Benign tumors of the spleen are not infrequently found both in man and in the lower animals. To enumerate the more common types, one finds fibromas occurring as single or multiple nodules usually about the size of a walnut. Two cases of lymphangioma were reported by Fink, showing multiple foci with extensive involvement of the substance of the spleen and nodules extending to the surface. Cavernous angiomas have been reported by Langhans, Homans, Birch-Hirschfeld, Moltrecht, Bochelmann, Albrecht, Theile, Jores and others. Several of these tumors showed transition from the benign to a malignant type of new growth. Lymphadenomas have been described as single or multiple nodules resulting from a hyperplasia of the malpighian corpuscles, with or without encapsulation. Williams and Bush performed necropsies on 720 healthy dogs and found lymphomatous nodules in the spleens of seventeen, or 2.3 per cent. From two to seven tumors were found in each spleen, varying in size from 0.5 to 4 cm. in diameter. Kitt divided these lymphomatous tumors into two groups: those with universal hyperplasia of the follicles and enlargement of the spleen are called splenoma; while the circumscribed tumors of lymphoid tissue occurring as single or multiple nodules are termed lymphoma. In 256 splenectomies at the Mayo Clinic, four lymphomatous tumors were found. There are several types of large cell hyperplasias, notably those described by Gaucher, Weichselbaum, Boviard, Rolleston, Collier, Brill, Picou and Raymond, Stengel, Schlagenhaufer, Ewing and Risel, as endothelial cell masses, some resembling or actually merging into neoplasms, as in the cases reported by Stengel and Ewing. Anitschkow produced in the spleen, lymph nodes and bone marrow a large cell hyperplasia resembling Gaucher's disease, by feeding large amounts of cholesterin. These cells contained a fatty substance, while those of Gaucher's disease, according to Risel, contain an albuminous material.

Three types of cysts occur in the spleen: 1. The hemorrhagic cysts which may arise from degenerated areas in the pulp or in angiomatous areas and later become serous. Trauma is probably a more common factor with subcapsular hemorrhage and the formation of hematomas. They may later become cystic. Cholesterin is usually present in these cysts. Renggli has described capsular cysts which he believed were due to inclusions of peritoneal endothelium. 2. Dermoid cysts reported by Andral and Kumaris. 3. The parasitic cysts due to *Cysticercus cellulosae, Pentastoma denticulatum* and the echinococcus. According to Litten and others, echinococcus cysts are present in the

spleen in from 3 to 4 per cent. of cases with hydatid disease. Douglas reports sixty-one cases of hydatid disease of the spleen without involvement of other organs. In 1905, Bryan, in a review of the literature, found one dermoid, twelve serous, twenty-four hemorrhagic and four unclassified cysts of the spleen.

At present, malignant disease of the spleen presents a clinical condition in which the diagnosis is usually made too late or at necropsy. These tumors usually grow rapidly, and metastasis often occurs before the patient is presented for operation. In the early cases, an exploratory laparotomy may be necessary to establish the diagnosis; but if the diagnosis is made before metastasis occurs, the operative mortality may prove no higher than in the operation for splenic anemia.

REPORT OF CASES

CASE 1.—*Primary endothelioma of the spleen with extensive metastases. History.*—An Italian farmer, aged 60, entered University Hospital, July 22, 1921, on the service of Dr. Kerr. He complained of pain in the left upper abdomen and left side of the back. Years ago, he had a severe malarial infection, which was cured by large doses of quinin. He had had gonorrhea several times, but no history of syphilis was elicited.

He had always been well until six weeks before entry, when he began to have sharp dragging pain in the back and the region of the left shoulder, which was worse when he was lying on his back. Three weeks before admission, a sensation of tightness with dull aching pain developed in the left upper quadrant. At this time, he was seen by a physician, who examined the abdomen and found no tumor; but on reexamination, one week before entry, a tumor was found in the region of the spleen, which the patient thought had rapidly grown larger. For the past few days, turning over in bed had caused severe shooting pains in the left hypochondrium. Recently, on exertion he had experienced dyspnea which had grown progressively worse. He had been forced to sleep in a sitting posture to relieve the pain in the left side of the back. Constipation became progressively worse, with pitch black stools. There had been slight edema of the left ankle and scrotum since onset. Nycturia was present, with urination 3 or 4 times each night. The patient had lost 15 pounds (6.8 kg.) in weight during the past six weeks. The present weight was 171 pounds (about 78 kg.). There was no hematuria, nausea, vomiting or jaundice.

Physical Examination.—There was moderate dyspnea. The skin and mucous membranes were pale. Adenopathy was not present. The eyes were negative except that fundus examination showed tortuous vessels. There was a moderate sized perforation of the nasal septum. Hearing was diminished. Pulsations were present in the neck, with a slight tracheal tug. There was dulness to flatness over the left side of the chest posteriorly up to the angle of the scapula, with decreased fremitus and distant breath sounds. Numerous coarse, moist râles were present over the bases of both lungs. Below the scapula the entire left thorax bulged, lagged in respiration and was resistant to pressure. The heart was moderately enlarged, and action was somewhat irregular, with frequent extra systoles. A systolic murmur, heard at the base, was transmitted to the carotids. A soft diastolic murmur, heard at the apex,

was transmitted to the axilla. The pulse rate was 96; the blood pressure was systolic 146, diastolic 64. The abdomen was obese and protuberant. No evidence of ascites or enlargement of liver was found.

In the left upper quadrant, a large tumor arose from beneath the costal margin, extending to the midline in front, to the iliac crest below and backward below border of last ribs. It did not pulsate, and apparently did not move with respiration. It was roughly oval, with surface irregular, nodular and of stony hardness. A knob the size of two fists projected from the anterior surface. No definite notch was felt. Tenderness was present. Crepitation was felt at times over the lower border. The left scrotal sac showed varicocele and slight hydrocele. Rectal examination was negative except for hemorrhoids. Edema of both legs was present below the knees. There was general loss of muscular strength. The neurologic examination was negative.

The urine showed a faint trace of albumin, a few pus cells and rare hyaline and granular casts.

Blood examination revealed: hemoglobin, 80 per cent.; white blood count, 14,500; red blood count, 3,960,000; differential count: polymorphonuclears, 80 per cent.; small lymphocytes, 12 per cent.; large lymphocytes, 7 per cent., eosinophils, 1 per cent. The red cells showed slight anisocytosis and poikilocytosis. The blood Wassermann reaction was negative. The stools showed nothing of note. Inflation of the stomach showed that it was pushed over anteriorly and to the right. Inflation of the colon proved that it lay dorsal to the tumor.

July 22: Puncture of the spleen was performed over the most prominent anterior portion. The needle entered the abodminal cavity, then struck a firm capsule, which moved with respiration. Beyond this, the tissue seemed soft. No fluid was obtained, but with suction a small amount of bloody material was withdrawn. Microscopic examination revealed red blood cells and what appeared to be degenerated white cells.

July 23: Lumbar puncture revealed clear fluid, with two cells, and Wassermann and colloidal gold tests negative. Tests of renal function revealed 55 per cent. phenolsulphonephthalein excretion in two hours.

July 24: There were increasing abdominal pain and discomfort. The patient slept poorly.

July 26: Cystoscopy was performed. Functional tests of the right kidney revealed an excretion of 30 per cent. in thirty minutes. The appearance time was three minutes. The pyelogram of the right kidney was normal. A catheter apparently passed 10 cm. up the left ureter, but when the patient was moved to the roentgen-ray machine, the catheter was found curled in the bladder, and no pyelogram was obtained. Tests were repeated next day. Function was lacking on left side.

July 27: A pneumoperitoneal roentgen-ray examination was made. Most of gas remained in pelvis, and none was visible above liver or spleen. A rounded encapsulated tumor was revealed in the region of the spleen, attached from 6 to 8 cm. above its lower edge and apparently growing down from above.

July 29: A hard tumor 3 by 2 cm. was found over the tenth rib on the left side in the posterior axillary line. It was immovable, apparently attached to the rib and not adherent to the skin.

July 31: Hemoglobin was 70 per cent.; white blood count, 20,600; differential count: polymorphonuclears, 87 per cent.; lymphocytes, 7 per cent.; eosinophils, 3 per cent.; basophils, 2 per cent.; myelocytes, 1 per cent.

August 3: There was severe pain under left scapula, which was worse with respiration.

August 10: The tumor was increasing in size. A roentgenogram of the chest showed the diaphragm high and fixed on the left side. A large effusion was noted in left pleura; a slight, on the right side. Roentgenograms of the gastro-intestinal tract were negative.

August 15: The tumor was still growing. The patient was weak, uncomfortable and somewhat irrational. Blood pressure was 100 systolic, 55 diastolic.

August 22: The left side of the chest was flat to percussion except at the apex. There was marked subcutaneous edema over the tumor; the veins were distended, and edema of the ankles was increasing. Hemoglobin was 6.5 per cent.; white blood count, 24,000. The urine showed large traces of albumin and many pus cells. The patient was extremely weak. There were many moist râles throughout both lungs. The pulse was weak and rapid, with a rate of 120. The temperature, previously normal, now rose to 37.8 C. (100 F.). Marked cyanosis and dyspnea was noted at 6 p. m. The heart failed at 9:15 p. m., and the patient died.

The clinical diagnosis was hypernephroma or malignant tumor of the spleen, with metastases to the rib and lungs; arteriosclerosis; cardiac dilatation; hydronephrosis on the left side, with ureteral obstruction; terminal bronchopneumonia.

Necropsy Findings.—The skin and sclerae showed slight jaundice. There were no palpable glands except one in the left axilla. A flattened nodule 2 by 3 cm. was found over the tenth rib, in the posterior axillary line. The abdomen was prominent. A hard tumor was felt filling the left side. There was no fluid in the peritoneal cavity. In the region of the spleen, there was a large, rounded tumor extending from the diaphragm to the level of the anterior superior spine of the ilium, filling the left flank and extending anteriorly practically to the midline. The viscera of the upper abdominal cavity were displaced to the right. Adhesions were found between the upper surface of liver and diaphragm. The right pleural cavity was obliterated by diffuse fibrous adhesions, and the left obliterated in its upper third by fibrous adhesions; while the lower third was converted into a walled-off cavity filled with 2 liters of clear, yellowish fluid. The pericardial cavity was completely obliterated by fibrous adhesions. The heart weighed 500 gm. The myocardium was brown, being slightly mottled with small, irregular reddish areas, and the tissue was soft and flabby. The free borders of the mitral valve were somewhat irregularly thickened. The aortic cusps showed irregular atheromatous degeneration. The tricuspid valve measured 13 cm.; pulmonary valve, 9 cm.; mitral valve, 11 cm.; aortic valve, 10 cm. The heart cavities were all dilated. Atheromatous degeneration of the aorta was present. The right lung showed congestion and purulent bronchitis. The left lung was adherent to the diaphragm, with atelectasis due to compression and purulent bronchitis. There was no pneumonia nor were there metastases in either lung.

The liver weighed 2,000 gm. Near the falciform ligament, there was a tumor nodule 1 cm. in diameter which indented the liver tissue without invasion. Embedded within the substance of the caudate lobe was a nodule 1.5 cm. in diameter. A third nodule, 1.5 cm. in diameter, was located in the transverse fissure in close association with the bile ducts. Multiple sections showed other nodules in the liver substance. These nodules were composed of homogeneous, smooth, opaque, slightly yellowish gray, soft to moderately firm tissue. The large nodules yielded a certain amount of thick, turbid fluid, indicating a moderate degree of softening. The gallbladder was negative. Closely associated with the cystic duct was a tumor nodule similar to those described above.

The spleen weighed 5,300 gm. The tumor measured 25 by 18 by 13 cm. The spleen, left kidney, left suprarenal, mesentery, pancreas, portions of stomach and diaphragm were involved in an adherent mass. The tumor presented a nodular surface covered, over the mesial half, by peritoneum and over the upper pole by adherent diaphragm, while the remaining surface was roughened by adhesions. The lateral aspect showed rib markings. On the mesial surface,

Fig. 1 (Case 1).—Gross specimen of the spleen.

adhesions involved the tail of the pancreas, anterior to this, the fundus of stomach; on the lower anterior surface, the splenic flexure and upper part of descending colon, and on the posterior surface, the left kidney and suprarenal. The tumor felt firm and elastic and on section showed a large, central, spherical mass, 17 cm. in diameter, bounded above and below by a small amount of splenic tissue, the whole apparently included within one continuous capsule.

The tumor tissue was light yellowish brown, and marked by numerous small translucent reddish purple areas, outlined by an indefinite, fairly diffuse grayish white reticulum. Scattered here and there on the cut surface were irregular, opaque, whitish patches; while peripherally situated were several fairly sharply outlined nodules of different sizes, composed of a homogeneous, pale, smooth tissue resembling the nodules described in the liver and diaphragm. The center of the large tumor mass presented an irregular and fairly extensive area of cystic degeneration, so that on first cutting into this there was an escape of considerable, pale, practically clear and somewhat viscid fluid. The recognizable

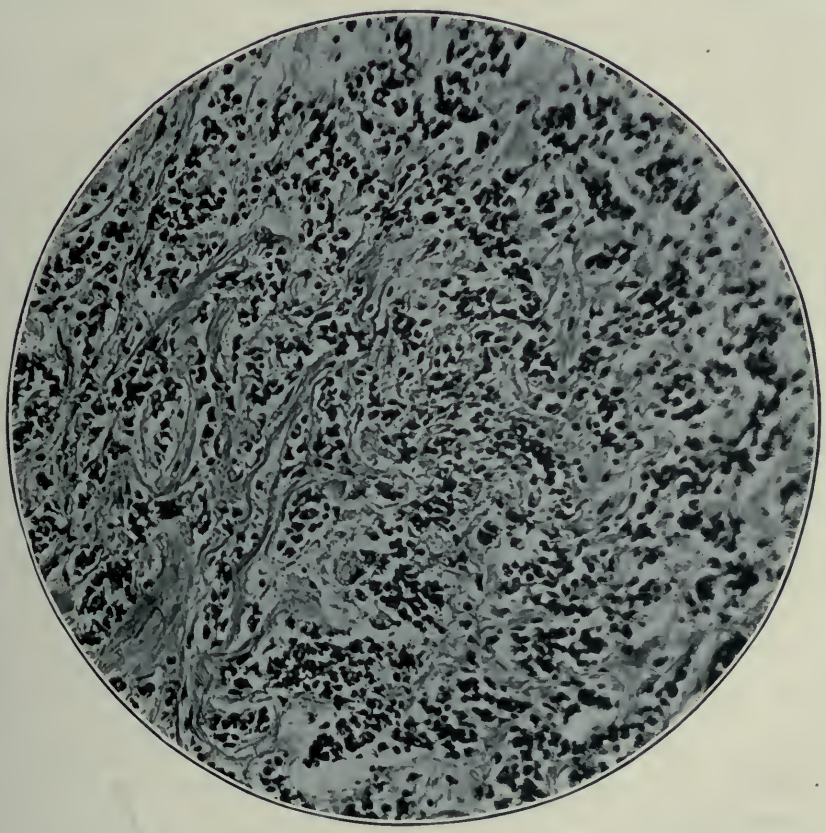

Fig. 2 (Case 1).—Alveolar arrangement of growth in spleen. Marked sclerosis is present.

spleen tissue present was relatively small in amount, being most abundant at the upper pole, and was, in general, fairly sharply marked off from the new growth. It was purplish red, and scattered throughout were small yellowish opaque nodules, averaging from 0.3 to 0.4 cm. in diameter, with borders somewhat blurred and tending to fade off into the surrounding tissue. The capsule surrounding the tumor and splenic tissue was thickened and infiltrated at several points by large tumor nodules.

The stomach was markedly distended and shifted to the midline. When it was opened, the adhesions at the fundus were seen to be caused by a direct

extension of the tumor into the stomach wall, involving an area 4 cm. in diameter and forming an elevation within the stomach 1 cm. high, whose surface appeared slightly, superficially, eroded. Near the lesser curvature in the gastrohepatic omentum was a nodule 2 cm. in diameter, which did not invade the stomach wall. At two points along the ileum were tumor nodules measuring to 2 cm. in diameter, which lay in the mesentery and invaded the intestinal wall, but there was no ulceration of underylying mucosa. The splenic flexure and upper part of descending colon were closely adherent to the tumor, and when this was cut away, a mass of tumor tissue 8 by 3 by 3 cm. was left adherent to and intimately associated with the intestine wall, apparently invading it to some extent, but the underlying mucosa was intact.

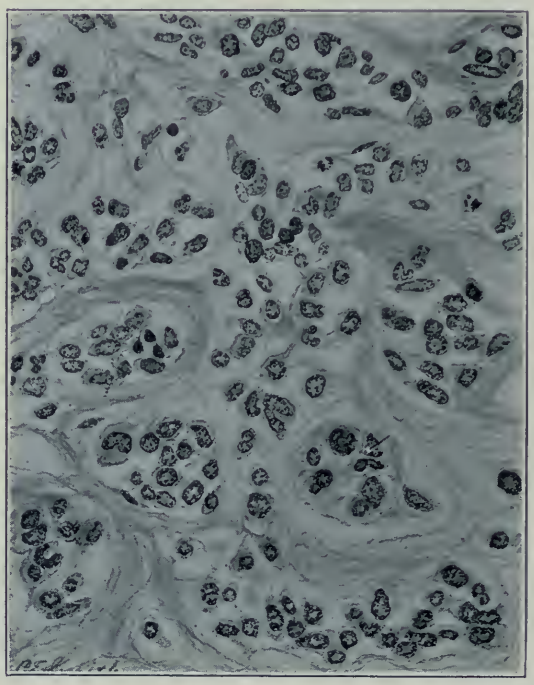

Fig. 3 (Case 1).—Camera lucida drawing of high power field: alveolar structure and various types of cells (made from the same slide as Fig. 2).

The tail of the pancreas was embedded in a continuous mass of tumor tissue that extended outward from the main tumor mass, retroperitoneally. The actual amount of pancreatic tissue present appeared small.

The mesentery was filled with large nodules, up to 2.5 cm. in diameter, which were discrete, moderately firm and diffusely infiltrated, and, on section, showed a smooth, homogeneous, pale yellowish white cut surface, projecting slightly above the capsule. The retroperitoneal nodes were similarly involved, the condition being most marked along the aorta where the nodes had become fused into a continuous mass practically surrounding the vessel throughout its course; thus forming large masses in the posterior mediastinum as well as in the abdomen. These masses measured up to 4 cm. in diameter, and were as

large in the thorax as in the abdomen. Other tumors accompanied the iliac vessels, and a moderate sized collection of nodules was found in the subperitoneal tissues of the lower anterior abdominal wall in the region over the spleen.

The right kidney was large, weighing 175 gm. The cortex was somewhat thickened, but was otherwise negative save for a few hemorrhagic areas in the pelvis. The left kidney was attached to the tumor mass but was readilly shelled off. It was somewhat flattened and smaller than the right kidney. The surface showed a few retention cysts, while a large, fluctuant cyst was found occupying the entire lower pole. On section, this measured 3.5 cm. in diameter and contained clear, brownish fluid. The cortex of this kidney appeared narrow. The pelvis was somewhat dilated, with moderately prominent calices

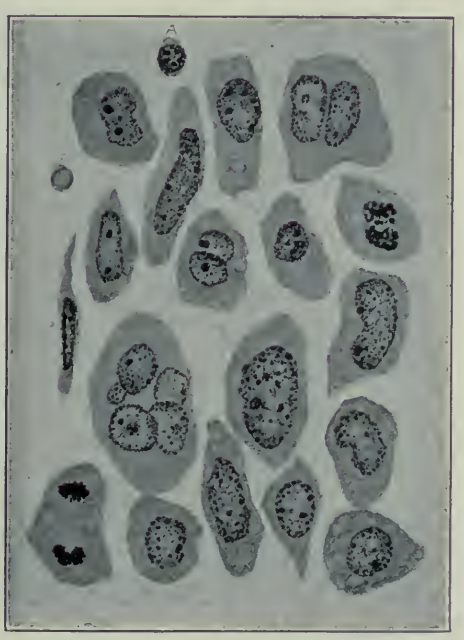

Fig. 4 (Case 1).—Oil immersion camera lucida drawing: various types of cells: *A,* normal lymphoid cell; *B,* red blood cell; *C,* reticular cell of the pulp.

and flattened papillae. Nowhere was there any evidence of invasion by the tumor. The suprarenals both appeared normal.

The tenth rib on the left bore, on its outer surface, two tumor nodules, the larger being 3 by 2 by 1 cm. These were adherent to the periosteum and appeared to be invading the adjacent soft tissues without involvement of the bone.

Microscopic Examination of the Spleen.—Sections from the small portion of remaining spleen tissue showed a greatly thickened capsule and trabeculae. The walls of large and small arteries were thickened and showed considerable hyaline degeneration. The veins were dilated. The pulp showed marked fibrosis, with atrophy of the normal elements; and between the connective tissue fibers were found many greatly dilated sinuses filled with her blood

cells. Very few lymphocytes were found in the pulp, and malpighian corpuscles were practically absent. Where found, they were atrophic, with only a few normal lymphocytes scattered loosely about a thickened artery. There was no lymphoid or reticular hyperplasia in these areas, and little fibrosis considering the general pulp reaction. In this portion of the spleen tissue macroscopically free from tumor nodules, there were small areas resembling dilated sinuses lined by spindle-shaped cells, with oval or rounded nuclei identical with those forming the main part of the tumor. There was no definite center from which the growth arose; but such areas might be considered as a prototype

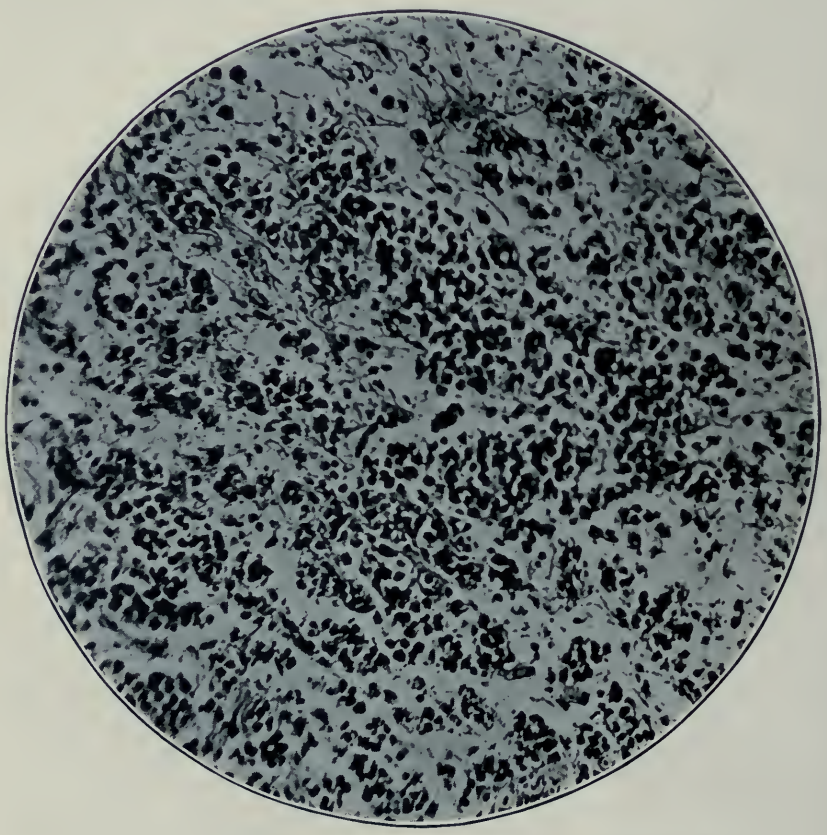

Fig. 5 (Case 1).—Diffuse type of growth in spleen, with less fibrosis.

of the growth as extensively developed in the main tumor. The origin was considered as undoubtedly in the sinuses, and the tumor cells bore a certain resemblance to the endothelial cells of the splenic sinuses. This anaplasia was not found in relation to the atrophic follicles where normal lymphocytes, greatly reduced in number, occurred.

In no sections from the main tumor was there normal splenic tissue, this having been entirely replaced by new growth. There was in all sections much necrosis, large areas being composed entirely of this material. In some places, there was extravasation of red blood cells. The tumor growth for the most

part was composed of tumor cells in a dense, often hyaline connective tissue stroma forming definite alveoli (Figs. 2 and 3). The cells had a fairly definite outline, assuming various shapes, but were mostly spindle shaped or polygonal, with clear, oval or rounded nuclei. These vesicular nuclei varied in size, the smallest being about twice the diameter of the nucleus of lymphoid cells, and stained less intensely. Elongated and crescentic nuclei were found. Many nuclei were hyperchromatic and others showed minute, multiple nucleoli. The protoplasm varied from a small rim to that larger than a phagocytic endothelial cell. It stained rather faintly and occasionally contained vacuoles (Fig. 4). In some sections, the cells were more closely packed together, with only fine connective tissue fibrils between them, as shown by Mallory's connective tissue

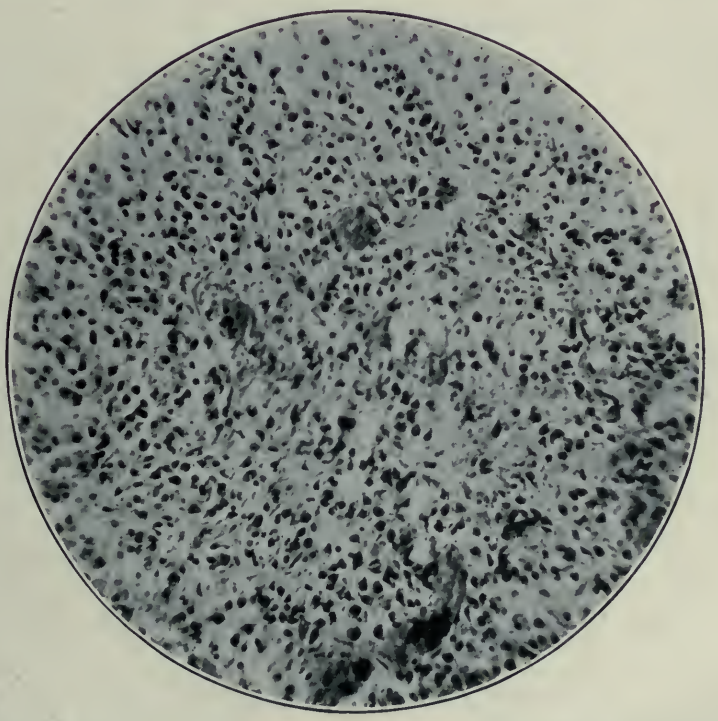

Fig. 6 (Case 1).—Section from mediastinal gland, showing metastasis (low power).

stain; but the alveolar or pseudo-alveolar arrangement was always evident. There was no suggestion that the tumor cells were fibroblastic in origin. In a few areas (Fig. 5), a more diffuse rapid type of growth was seen with much less fibrosis, but even here the typical architecture was maintained. A number of areas showed tumor cells in perithelial arrangement. No proliferation of vascular endothelium was apparent, and in no sections did one find angiomatous areas. Occasionally, a vein showed invasion by tumor cells. For the most part, the tumor cells seemed to lie in sinuses of the spleen, surrounded by overgrowth of fibrous tissue; but the growth was so extensive and diffuse that it was difficult to trace the transition from the normal sinus endothelium.

Sections from nodules in the liver, pancreas, stomach and mediastinal and retroperitoneal nodes showed a more recent diffuse type of growth, with more mitotic figures and giant cells than the primary growth in the spleen; but the same type of cells were found in a diffuse or pseudoaveolar arrangement (Fig. 6).

Dr. Bunting examined slides from this tumor and found it identical with his case, except that there is more sclerosis in the spleen. Dr. Ewing also studied these sections and made the following note: "This appears to me to be an endothelioma of the same type as that in Case 2, but here one is unable to trace the origin of the cells. The cells seem to be mainly duplicates of those of the other, but the nuclei are larger and more hypochromatic. There is also much sclerosis."

An anatomic diagnosis was made of endothelioma of the spleen, with direct extension to the diaphragm, the fundus of the stomach, the pancreas, the anterior abdominal wall and the wall of the descending colon; focal involvement of the wall of the small intestine and marked general involvement of the mesenteric, retroperitoneal and mediastinal lymph nodes; metastases to the liver and soft tissues over the tenth rib on the left; complete obliterative fibrous pericarditis; old chronic mitral endocarditis; cardiac hypertrophy and dilatation, with dilatation also of the mitral and aortic orifices; atherosclerosis of the aorta and coronaries; a large pleural effusion in left chest; bilateral fibrous pleural adhesions, obliterating the right pleural cavity, pulmonary congestion and edema; slight diffuse bronchiectasis and purulent bronchitis; slight hydronephrosis of the left kidney, with slight compensatory hypertrophy of the right; large retention cyst in the lower pole of left kidney; slight obstructive jaundice.

Case 2 came to necropsy a number of years ago, and unfortunately the history and protocol are not to be found; but since the tumor is of the same type as that in Case 1, we are reporting the case, although the data are incomplete. Fortunately, the growth is shown at an earlier stage than that in the preceding case, and we are able to trace the growth from the endothelial cells of the sinuses to the main parts of the tumor.

Figure 7 shows a museum specimen of the tumor.

Case 2.—*Primary endothelioma of the spleen. Gross Description.*—The probable weight of the spleen was 500 gm. The section measured 17 by 17 cm. The surface was smooth. In one pole, there was a firm, whitish, sharply defined tumor measuring 6.7 by 8 cm. and partly surrounded by a thin rim of spleen tissue, from 1 to 2 mm. in thickness. There were no areas of softening or necrosis. The remaining spleen tissue was evenly invaded by a tongue of reddish gray firm tissue, 9 by 2 cm., with a narrow strip of compressed spleen tissue, 2 mm. in thickness over the superior surface, and a fairly firm grayish strip 0.5 to 3 cm. along the inferior surface. No definite nodules could be discerned in the remaining spleen tissue.

Microscopic Description.—The main tumor was not encapsulated but was surrounded by a thin rim of spleen tissue that showed marked fibrosis. There was absence of follicles and lymphoid tissue, but trabeculae could be seen. In the compressed sinuses, there were a few small groups of tumor cells. In the main tumor, there was no trace of normal spleen tissue. It was made up of a diffuse growth of tumor cells lying in spaces resembling sinuses, with

a fine meshwork of fibrous tissue stroma forming a pseudo-alveolar arrangement (Fig. 8). The cells were mainly duplicates of those described in Case 1, but were slightly smaller and less hyperchromatic. There was also less sclerosis than in Case 1. The type of cells found were similar to those shown in Figure 4, and there were many mitotic figures and multinucleate giant cells.

The remaining spleen tissue showed much fibrosis and prominent trabeculae. An occasional atrophic malpighian corpuscle was found, with hyaline arteries

Fig. 7 (Case 2).—Museum specimen of primary endothelioma of the spleen.

and a small collection of lymphoid cells. There were practically no lymphoid cells in the pulp. A few small areas of necrosis were seen. Nests of tumor cells were found about the follicles, but these were mainly in the sinuses, where they resembled the small, polyhedral endothelial cells that normally line the sinuses. This is an earlier type of growth than that in Case 1, and, like Risel, we can trace the origin of the tumor from the endothelial cells of the sinuses through various transitions up to the diffuse portion of the main

tumor, especially into the tongue-like projection described above. Throughout the spleen tissue which appeared free from tumor growth, microscopic examination revealed nests of tumor cells identical with those found in the main tumor, but with fewer mitotic figures and giant cells.

Dr. Ewing, who examined a section from the spleen, made the following note: "This appears to me to be an endothelioma derived from the small polyhedral endothelial cells which line the sinuses. I think that one can trace this origin satisfactorily in the outlying areas about the tumor, where every

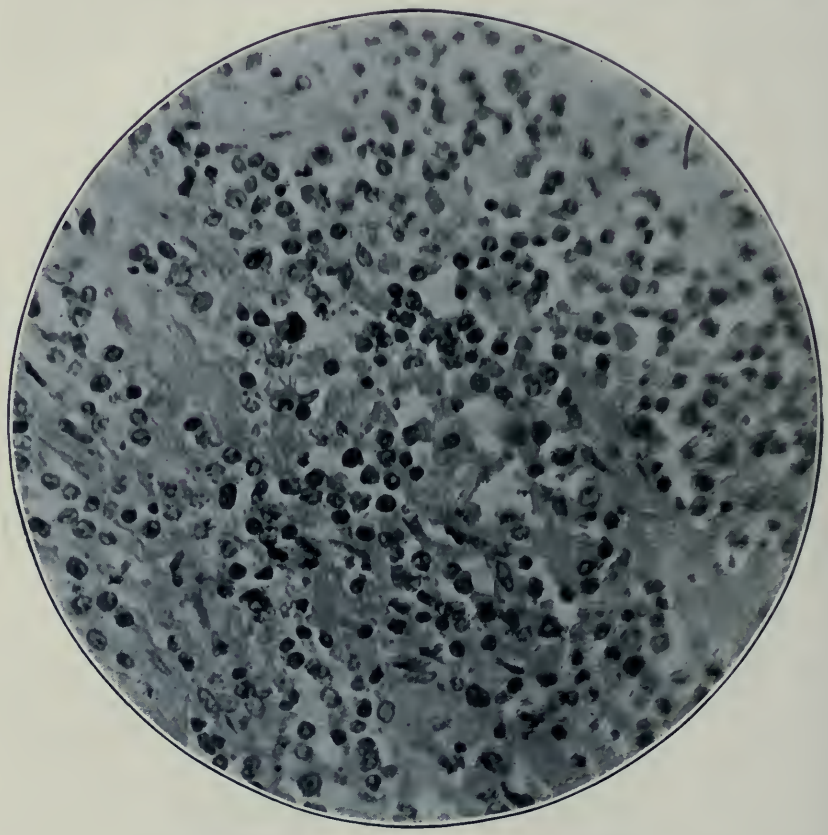

Fig. 8 (Case 2).—Diffuse growth of endothelioma in spleen (high power).

transition seems to occur from slightly increased endothelial cells up to the exact picture of the main tumor."

These cases from the literature may be arranged in four groups.

GROUP I. ENDOTHELIOMA, ENDOTHELIAL SARCOMA, ANGIOSARCOMA

CASE 3 (Weichselbaum[1]).—*Endothelial sarcoma.* A man, aged 21, had a fatal case, which came to necropsy. The spleen was enlarged, and on section

1. Weichselbaum: Notable Form of Multiple Endothelioma of Spleen, Virchows Arch. f. path. Anat. **85**:562, 1881.

showed projecting nodules the size of a millet seed to a pea, soft, reddish gray, and not sharply separated from the spleen tissue. Microscopic examination revealed, in scaffold work, cells arranged as large, irregular plates resembling the various forms of pulp endothelium. Double nuclei appeared. There were no metastases. Weichselbaum believed that this case was similar to Friedreich's. Birch-Hirschfeld examined specimens and thought it a nodular hyperplasia. We believe that this was probably a slowly growing endothelioma.

Case 4 (Langhans[2]).—*Angiosarcoma.* A man, aged 30, had a fatal case which came to necropsy. There was a history of a fall, with trauma to the left side three months before death. A large, pulsating, fluctuating and rapidly growing tumor was found. There was marked dyspnea, but pain developed late. The tumor was 23 by 15 by 10.5 cm., with a nodular surface with adhesions, nine-tenths of the organ being involved. The growth, which was firm and elastic, was a cavernous tumor with vessels forming spaces. Microscopic examination revealed that the endothelium of the spaces was very hyperplastic, with large polyhedral cells continuous with the sinus endothelium, and fibrous and lymphoid tissue not overgrown. An extensive growth of the same type was found in the liver. The writer questioned whether it was primary in the liver as well as in the spleen.

Case 5 (Wagner[3]).—*Endothelioma.* A woman, aged 27, who underwent splenectomy, with recovery, was living four years later, but had a nodule the size of a pigeon's egg in the region of the first and second lumbar vertebrae. A tumor of the spleen was found two weeks after confinement. There were no other symptoms. The tumor weighed 1,285 gm., and measured 19 by 9.5 by 10 cm. It was a uniform yellowish white growth, with no trace of spleen tissue, and no adhesions or nodules. Microscopic examination revealed groups of alveoli filled with large round cells, and large, sometimes multiple, nuclei. No metastases were discovered at the time of operation. Marshand and Aschoff, who examined the tissue, called the growth a large round cell sarcoma, but stated that the alveolar arrangement admitted a diagnosis of endothelioma. Foix and Roemmele thought it to be similar to the growth in their case.

Case 6 (Pasinetti[4]).—*Endothelioma.* A man, aged 47, had a fatal case, which came to necropsy. The course was very rapid. The spleen was hard and immovable, and there was marked cachexia. Microscopic examination revealed primary endothelioma of the spleen, with metastases in the liver and lungs. The description given is incomplete.

Case 7 (Albrecht[5]).—*Cavernous angioma with sarcomatous changes.* At necropsy, the spleen was found to be enlarged. Microscopic examination revealed a flat primitive endothelium changed to high epithelial-like cells. Risel thinks the case similar to his own. Foix and Roemmele call the growth an angiosarcoma. We consider that it is probably a hemangio-endothelioma. The description given is incomplete.

---

2. Langhans: Pulsating Angiosarcoma of Spleen, Virchow's Arch. f. path. Anat. **75**:273, 1879.

3. Wagner: Extirpation of Sarcomatous Spleen, Verhandl. d. deutsch. Gesellsch. f. Chir. **23**:155, 1894.

4. Pasinetti: Primary Endothelioma of Spleen, Riv. veneta di sc. med. Venezia, **37,** No. 3, 1902.

5. Albrecht: Cavernoma of the Spleen, Ztschr. f. Heilk. **23,** 1902.

Case 8 (Bunting[6])—*Endothelioma.* In a fatal case in a man, aged 49, which came to necropsy, there had been pain for only eleven days. The patient was emaciated, and the liver and spleen were enlarged, hard and nodular. The spleen weighed 250 gm. There were few adhesions. The section was uniformly nodular, purplish gray, with pulp obscured. There were congested vascular areas between nodules. Microscopic examination revealed atrophic follicles, new growth replacing the pulp, and a definite network of fibers forming pseudo-alveoli. There were oval or polygonal cells, with finely granular, oval or rounded nuclei, twice the diameter of a lymphoid cell and staining less intensely. Many mitotic figures and few multinucleate giant cells were noted. Metastases were abundant in the liver where the sinuses and vessels were filled with tumor cells. There were also metastases to the pancreas, the gastrohepatic nodes and the subcutaneous tissue over the left chest and abdomen. Bunting first reported this case as a sarcoma arising from reticular cells, but he now thinks that it was an endothelioma from the endothelial cells of the sinuses. Risel holds the latter view; while Foix and Roemmele think that it is similar to the growth in their case. We have examined sections from this case and they show the same type of tumor as in our cases.

Case 9 (Le Fort and Legueu[7]).—*Endothelioma.* A man, aged 56, who underwent splenectomy, performed by Le Fort, with recovery, was well ten months after operation. There was a history of severe malarial infection. A large, smooth tumor had been present for four months, with emaciation and pain for one month. There was no fever, and the blood examination was negative. The tumor weighed 4,800 gm., with many adhesions and a series of cysts ranging in size from that of a bean to that of a child's head, containing dark colored fluid. Microscopic examination by Professor Curtis revealed cystic areas with fibrous tissue and dilated vessels; areas of large, irregular, polygonal cells arranged about vessels with confluent spleen tissue, and compact cellular masses giving the aspect of sarcoma "fuso-cellulaire." No metastases were found at operation. We consider that this is an angioma, with transition to endothelioma.

Case 10 (Theile;[8] from Lubarsch's laboratory).—*Angiosarcoma.* A man, aged 56, who underwent splenectomy, death resulting twenty-four hours later from hemorrhage, had had symptoms for six months; weakness, pain, leukocytosis, and a large, smooth tumor. The spleen weighed 2,500 gm., and measured 25 by 16 by 8 cm. There were adhesions and blood clots where the angiomatous areas extended to the surface, and large and small nodules on the surface. A section showed most of spleen tissue replaced by large and small, circumscribed white areas in pulp, and many small vessels and blood spaces filled with blood. Microscopic examination revealed a network of cavities containing blood and masses of endothelial cells like "vessel sprouts." Angiomatous areas showed transition to true sarcoma, with spindle or round cells and many mitotic figures. The cells resembled undifferentiated angioblasts. Metastases to lung and stomach were noted, and they were abundant in the liver, where

---

6. Bunting: Primary Sarcoma of the Spleen with Metastases, Univ. of Penn. Med. Bull. **16**:188, 1903-1904.

7. Le Fort and Legueu: Splenectomy for Endothelioma of Spleen, Bull. et mém. Soc. de chir. de Paris **29**:1176, 1903.

8. Theile: Angiosarcoma of Spleen, Zentrabl. f. allg. Path. u. path. Anat. **19**:662, 1904.

"sarcomatous plugs" were found in the portal capillaries. The writer stated that this was not a hemangiosarcoma. Risel finds this case similar to Le Fort's, Langhans' and his own case.

Case 11 (Bochelmann;[9] from Grawitz's laboratory).—*Angioma with definite sarcomatous areas.* An infant, aged 1½ years, who underwent splenectomy, performed by Hellwig, with recovery, previously had nine hemangiomas excised from the skin and mucous membranes. A tumor of the spleen was noticed three months before operation. The spleen measured 12 by 8 by 5 cm. A small part of the upper pole was intact. A large reddish yellow angiomatous tumor replaced the spleen tissue. Microscopic examination revealed large endothelial cells lining spaces and continuous with the growth. Some areas were angiomatous, while others showed definite angiosarcoma. According to the writer, malignancy was not to be doubted. No metastases were seen.

Case 12 (Jores[10]).—*Angiosarcoma.* In a fatal case in a woman, aged 45, which came to necropsy, the patient died from heart weakness and dropsy. The tumor was noticed eleven months before death. The spleen was enlarged. reaching the iliac crest. The liver enlarged later. Blood examination revealed leukopenia. Ascites and hydrothorax were also present. The spleen weighed 3,600 gm., and measured 31 by 15 by 16 cm. The surface was irregular, with adhesions. There was no normal spleen tissue left. A dark red blood clot the size of the fist was noted on the upper pole. A section showed soft red opaque structureless masses, with an angiomatous aspect and much necrosis. Microscopic examination revealed endothelial spaces lined with endothelium and filled with blood. A transition from angiomatous to definite sarcomatous areas was in progress. These areas showed thin vascular spaces with spindle cell endothelium. The liver weighed 8,600 gm. Metastatic nodules were present, ranging in size from that of a cherry to that of an apple. There were plugs of tumor cells in the portal veins.

Case 13 (Risel;[11] from Lange's clinic and Marchand's laboratory).—*Endothelial sarcoma.* A man, aged 52, underwent splenectomy by Braun, death ensuing five weeks later. Necropsy was performed. Ten months before death, the patient was kicked in the left side by a horse, and was in bed for four weeks. Five months later, a tender swelling appeared in the region of the spleen, finally filling the whole left flank. The patient lost 40 pounds (18 kg.) in weight, and suffered from irregular temperature and dyspnea. Hemoglobin was 60 per cent.; red blood count, 2,304,000; white blood count, 11,600. The patient stood the operation well. Intense jaundice, enlargement of liver, edema, ascites and hydrothorax developed four weeks after operation, shortly before the patient died. The spleen weighed 2,391 gm., and measured 21 by 22 by 10 cm. The surface was nodular, with adhesions. A section showed many firm, more or less circumscribed, yellowish or whitish nodules, varying in size up to 2.5 cm., with the centers somewhat depressed. In some masses, there were small cystic areas with clear fluid, while others were filled with blood. Microscopic examination revealed follicles and trabeculae absent; lymphoid tissue decreased; some areas of fibrosis and necrosis; red pulp prominent. There were large areas of spindle cells surrounded by broad bands of connective

9. Bochelmann: Case of Angioma of the Spleen, Dissert., Griefswald, 1906.

10. Jores: Angiosarcoma of Spleen and Liver, Zentralbl. f. Path. u. Anat., 1908.

11. Risel: Endothelial Sarcoma of the Spleen, Beitr. z. path. Anat. u. z. allg. Path. **46**:296, 1909.

tissue, giving an alveolar arrangement. Blood spaces were to be seen; also a network of venous capillaries. The sinuses and cystic spaces were lined with elongated, polyhedral, closely packed endothelial cells, with bulging, drawn-out nuclei. Some small reticular cells were found. Proliferating endothelial cells in the arterioles were larger and shorter than in venous sinuses. The endothelial proliferation was continuous with the sinuses, and the connective tissue with the reticulum, resembling epithelial-like tubes lying close together, which could be traced to veins and sinuses. Certain areas resembled spindle cell sarcoma. Most of the cells were polyhedral with vesicular nuclei and clear, sometimes vacuolated, cytoplasm. Many mitotic figures and giant cells were present. There were extensive metastases to the liver, with nodules up to 5 cm. in diameter, tumor cells forming thrombi in the portal system. The cells resembled slightly the syncytial cells of atypical chorio-epithelioma. This case was first reported by Berens.[12]

Case 14 (Temoin and Bonnel[13]).—*Endothelioma.* A woman, aged 27, who underwent splenectomy performed by Temoin, recovered and returned to her work. The spleen had been enlarged for five years, with rapid growth for one year. No symptoms were mentioned except the presence of tumor. The spleen weighed 3,000 gm., and there were large, firm, nodular, adhesions present. A section was reddish with some hemorrhagic areas. There were five or six cystic cavities ranging in size up to that of an egg filled with sanguinous fluid. Nodular infiltration was noted in the substance of the spleen. Microscopic examination revealed: no normal spleen tissue, no necrosis and some fibrosis. The cells were large, irregular and polygonal, having an endothelial aspect. Faint, finely granular nuclei, clear cytoplasm, rare mitotic figures and atypical giant cells were noted. There was "endoperivascular" reaction, with obliteration of some vessels. Others showed a perithelial arrangement. No metastases were mentioned.

Case 15 (Jopson[14]).—*Hemangiomatous endothelioma.* A woman, aged 33, who underwent splenectomy, performed by Jopson, recovered and was in good condition one month later. There was a history of malaria. The tumor, which appeared five months before operation, was hard and nodular, and was located a hand's breadth below the costal margin. The skin was yellow. Hemoglobin was 46 per cent.; red blood count, 2,450,000; white blood count, 15,800; polymorphonuclears, 53 per cent.; fragility, 0.4 per cent. Following is the pathologic report, by Eiman: "Spleen weighed 1,590 gm., and measured 22.5 by 16.5 by 7.5 cm., firm, upper third covered with adhesions; through capsule yellowish areas from pin point up to 2 cm. project; cut surface mottled, grayish red, with irregular, nonencapsulated nodules up to 3.8 cm.; follicles and trabeculae not made out; microscopic examination: architecture disarranged, dense connective tissue; reddish areas showing irregular blood spaces filled with red blood cells and lined with large, polyhedral cells with large vesicular nuclei; these cells also proliferating outside vessels forming diffuse tumor masses; grayish areas showing masses of cells which were virtually spindle shaped, with vesicular nuclei and few giant cells; no metastases seen.

---

12. Berens: Primary Sarcoma of the Spleen and Its Relation to Trauma, Inaug. Dissert., Leipsic, 1905.

13. Temoin and Bonnel: Primary Sarcoma of Spleen, Bull. et mém. Soc. Anat. de Paris **88**:55, 1913.

14. Jopson, J. H.: Primary Hemangiomatous Endothelioma of Spleen, S. Clinics N. America, Philadelphia, **1**:235 (Feb.) 1921.

Cases 16 and 17 (Führer[15]).—These cases were reported in 1856, with incomplete data. The first is described as a "cancroide" of capillary blood vessel structure; the second as a "carcinoma" arising from capillaries, its "blasts" deposited in the form of capillary cells.

Ewing states that endothelial sarcoma is the most common malignant tumor of the spleen. From the relatively small number in the foregoing group, as compared with the total number, it would seem that this may be doubted, but we have included within this group only the cases that seem unquestionably to owe their origin to the endothelial cells of sinuses or blood vessels. If the exact origin of many could be traced, and if there existed a more uniform standard of classification for splenic tumors, it is probable that many cases reported as sarcoma and carcinoma and some given in the miscellaneous group below would conform to the diagnosis of endothelioma, increasing the relative figures in this group. As will be seen in this report, the greater number seem to fall into the group of malignant lymphoblastoma, which Mallory holds is the most common type found in the spleen.

MacCallum is very conservative in admitting endothelioma to an orthodox position in the classification of many tumors, adding that every unusual tumor which lacks characters that will permit its ready recognition stands an excellent chance of being labeled endothelioma and so relegated to oblivion. Ewing finds that tumors derived from the endothelial and reticular cells of lymph nodes form separate, well-defined, rather frequent groups of tumors. In the etiology, chronic irritation, trauma and low grades of inflammation are given an important place. Furthermore, he finds that they have a basis of chronic granulomatous inflammation and develop from the endothelium of the lymph and cavernous sinuses; that somewhat similar tumors arise from the reticular cells of the lymph nodes but usually take the form of large cell lymphosarcoma, and that one finds definite transitions from tuberculosis and Hodgkin's granuloma to endothelioma and lymphosarcoma.

The structure of the spleen renders it susceptible to pathologic reactions analogous to those found in the lymph glands. In addition, the reticulo-endothelial system is more highly organized, and, according to Ewing, undergoes various forms of inflammatory hyperplasia which may border on neoplastic changes not found in lymph nodes.

To the phagocytic endothelial cells of the sinuses are ascribed many functions. Sir Berkeley Moynihan[16] says, in substance, that from the abundant literature we can draw the simple picture that these modified endothelial cells which cling to the reticular meshwork are occupied in

---

15. Führer: Two Cases of Capillary Cell Tumors of Spleen; Their Relation to Cancer Cells, Arch. f. phys. Heilk. **15**:81, 1856.

16. Moynihan: Surgery of the Spleen, Bradshaw Lecture, Brit. J. S. **8**:307, 1920-1921.

different ways at different times. Sometimes they remain stationary and gather up particles suitable as food; at other times, they separate from the meshwork and wander among it, likewise for the purpose of engulfing solid particles (notably effete red blood cells); at other times still, they undergo proliferation. The purely lymphatic cells of the malpighian bodies which lie in a medium richer in oxygen give rise to a very different progeny.

In the foregoing group of cases, a series of transitions are found to the anaplasia of well defined malignant disease. Some cases are definitely angiomatous, finally merging into "sarcomatous" changes. We have exchanged slides with Dr. Bunting, and our cases are strikingly similar, except that his show less sclerosis than our first case. In our cases, no angiomatous areas were found, the cells apparently arising directly from the endothelial cells of the sinuses, and, in the first case, giving rise to a very malignant tumor, with early and extensive metastases. Risel, in a careful and extensive study of his case, traced the growth from the normal endothelium of the sinuses through several stages of proliferation, to the areas showing definite malignant characteristics. We have been able to do this in our second case. The reticular cells were identified in both cases but played no part in the structure of the endothelioma. Ribbert points out that the mere continuity of the tumor cells with endothelium at the margin of the tumor is no proof of their identity. He thinks that proof of the endothelial nature will require the study of the tumor at its inception, which is impossible. In these cases, there is atrophy of all other elements in the spleen except the endothelial cells of the sinuses, from which, in the early stages of growth, one can trace the tumor up to the diffuse areas, which show the characteristics of an endothelioma.

The work of Risel done in Marchand's laboratory is especially convincing. He believes that a number of other cases are similar to his own. Bunting reported in detail one of the first authentic cases, and he holds the same view.

After careful consideration of the data at hand, we believe that the subjoined cases of Gröhe, Villard and Santy, Friedreich, Schönstadt, Stengel, Cerkasov, Menetrier, Golovina-Ammon, Foix and Roemmele, Cesaris, and Arnott and O'Connor should be classified as endothelioma.

GROUP II. LYMPHOSARCOMA

Case 18 (Trelat[17]).—A case in which the age and sex were not given came to necropsy. Pathologic examination was made by Malassez and Ranvier. The growth was reported as primary lymphosarcoma of the spleen, but there was general involvement of the glands, and the spleen was probably secondarly involved.

17. Trelat: Lymphosarcoma of Spleen, Gaz. d. hôp., 1872, p. 453.

Case 19 (Bacelli[18]).—In a fatal case in a boy, aged 13, which came to necropsy, there was a history of malaria, four years before. A large tumor extended 3 cm. below the umbilicus. The spleen weighed 2,400 gm., measuring 22 by 25 cm., with a circumference of 58 cm. Some spleen structure remained, with old hemorrhagic areas. Microscopic examination revealed a fine network containing lymphatic cells with fine protoplasm. Metastases were found in the colon and the wall of the gallbladder. Some writers question the primary origin in the spleen.

Case 20 (De Ritis[19]).—In 1879, this case of primary lymphosarcoma of the spleen, referred to by several writers, was reported, but the report is not available.

Case 21 (Von Hacker[20]).—A woman, aged 43, who underwent partial splenectomy, performed by Billroth, with recovery, died six months later of recurrence. Swelling had been present for ten years, the size of two fists for seven years, and began to increase rapidly two years before operation. There was pain in the region of the tumor, radiating to the left shoulder. The spleen weighed 1,450 gm., and measured 25 by 18 cm. The omentum and intestines were adherent, with a nodular protuberance posteriorly. Microscopic examination revealed atypical lymphosarcoma. No metastases were seen at operation.

Case 22 (Asch[21]).—A woman, aged 31, who underwent splenectomy, performed by Fritsch, with recovery, died six and one-half years later of cardiac disease. Pain had been present for three or four months, and there was a small tumor in the left hypochondrium which grew rapidly. The patient was five weeks pregnant. She had a still-born baby some time before operation. The spleen weighed 2,000 gm., measuring 22 by 14 by 10 cm., of normal outline. There was a growth on the convex side extending to the surface, fairly circumscribed, but not definitely separated from the spleen tissue. Microscopic examination revealed hypertrophy of the spleen tissue, an alveolar structure, large round cells with dark nuclei and clear cytoplasm. No adhesions and no metastases were seen.

Case 23 (Kocher[22]).—Splenectomy was performed by Kocher, but the patient died subsequently from recurrence. The spleen was uniformly enlarged. Microscopic examination revealed lymphosarcoma. Metastases to the liver and mesenteric nodes were present. Kocher admits that this was probably generalized lymphosarcomatosis, and therefore somewhat questionable as to primary origin in the spleen.

Case 24 (Flothmann[23]).—A man, aged 44, underwent splenectomy and died fifty hours later of acute anemia following hemorrhage resulting from operation. The spleen, which weighed 2,000 gm., had many adhesions and was

---

18. Bacelli: Primary Carcinoma of the Spleen, Rome, 1876.

19. De Ritis: Lymphosarcoma of Spleen, Movimento **20**:511, 1879.

20. Von Hacker: Primary Sarcoma of Spleen, Verhandl. d. deutsch. path. Gesellsch. f. Chir. **13**:30, 1884.

21. Asch: Two Cases of Splenectomy, Arch. f. Gynäk., p. 130, 1888.

22. Kocher: A Case of Successful Splenectomy, Kor.-Bl. f. Schweiz. Aerzte, No. 21, p. 649, 1888.

23. Flothmann: Splenectomy for Sarcoma, München. med. Wchnschr., No. 49, p. 867, 1890.

studded with small growths the size of a hazel-nut. Microscopic examination revealed lymphosarcoma. An effort was made to remove a metastatic mass the size of a fist in the omentum. No other metastases were mentioned.

Case 25 (Masi[24] [Tommasi]?).—In a fatal case of a man, aged 31, which came to necropsy, there was a history of malaria, with symptoms, for five months, of a tumor, which was found to be in the left hypochondrium and was attended with severe pain. There was no fever. The red blood count was 1,500,000; the white blood count, normal. Moderate ascites and marked cachexia, but no adenopathy, was noted. There was a large tumor of the spleen with adhesions to the stomach. There was metastasis to the greater omentum and the mesentery. Microscopic examination revealed lymphosarcoma.

Case 26 (Acker[25]).—In a fatal case in a boy, aged 8, which came to necropsy, the tumor was noticed nine months before. It was large, hard and nodular and extended to Poupart's ligament. Pain, dyspnea, leukocytosis, cachexia and anemia were present. The patient died in hospital of scarlet fever. Pathologic examination, by Dr. Walter Reed, revealed: spleen weight of 1,560 gm.; adhesions to omentum and diaphragm; liver enlarged. Microscopic examination revealed: marked congestion; hypertrophy of trabeculae; small malpighian bodies; enlarged glands along the splenic vein, showing epitheloid-like cells; collections of lymphoid cells and necrosis in the liver. The diagnosis was lymphosarcoma or lymphadenoma. The pathologic description is incomplete and the question may arise as to exact type of tumor of spleen.

Case 27 (Jordon[26]).—A boy, aged 15, underwent splenectomy, performed by Jordan. He recovered, but died one and one-fourth years later of metastases. Fourteen months before splenectomy, a gland removed from the neck showed lymphosarcoma. There was a large tumor, attended by pain, in left hypochondrium. The spleen weighed 2,000 gm., and was hard and firm, with a large tumor extending to the hilum and involving the glands there. Microscopic examination revealed lymphosarcoma, with evidently generalized disease, probably not primary in the spleen.

Case 28 (Gröhe[27]).—In a fatal case in a youth, aged 20, which came to necropsy, there was a history of a fall, attended by pain in left hypochondrium, eight months before death. There was a large tumor reaching the navel, with pain, cachexia, leukocytosis and ascites attending. The spleen measured 28 by 13 by 18.5 cm., and there were adhesions to the diaphragm, stomach and liver. The small bit of reddish spleen tissue remaining was mostly nodular, with grayish yellow areas. Microscopic examination revealed large round and spindle cells with large nuclei. There was no definite alveolar arrangement. The malpighian corpuscles were necrotic. There were metastases to the mesentery, liver, intestine and right pleura. Bunting considers this case similar to his own. Risel thinks that it shows a transition from small round cell sarcoma closely related to lymphosarcoma. Ewing considers it similar to the cases of Menetrier and Javrin.

---

24. Masi: Lymphosarcoma Primary in Spleen, Incurabili, Napoli, **3**:3, 1893.

25. Acker: Lymphosarcoma of the Spleen, Arch. Ped. **12**:591, 1895.

26. Jordan: Lymphosarcoma of Spleen, Verhandl. d. Gesellsch. deutsch. Naturf. u. Aertze **2**:152, 1896.

27. Grohe: Primary Sarcoma of Spleen with Metastases, Virchow's Arch. f. path. Anat. **150**:324, 1897.

Case 29 (Casatt[28]).—In a fatal case in a woman, aged 54, which came to necropsy, there was a massive, hard tumor and ascites. The spleen weight was 5,000 gm. There were some hemorrhagic areas, and tumor nodules ranging in size up to that of a stork's egg. Microscopic examination revealed tumor cells in a firm network; some large epitheloid cells, but mostly small round cells with clear, granular cytoplasm; and metastases to liver, mesentery, diaphragm, pleura and mediastinal nodes.

Case 30 (Whiting[29] [reported by Hektoen]).—A man, aged 30, who underwent an operation for acute appendicitis, died of peritonitis and pneumonia. Necropsy and pathologic examination was performed by Hektoen. There were no symptoms referable to the spleen, which weighed 300 gm., and measured 16.5 by 8.2 by 10.1 cm. The capsule was thick. The upper pole was entirely involved by grayish white nodules ranging in size from that of a millet seed to that of a half-dollar, forming a huge, circumscribed mass surrounded by a narrow strip of spleen tissue. The growth was readily enucleated. The omentum was adherent. Microscopic examination revealed very small round cells infiltrating in a granular and homogeneous fibrous tissue stroma. The structure corresponded well with the so-called lymphosarcoma. There were no metastases.

Case 31 (Piazza-Martini[30]).—A case of primary lymphosarcoma of the spleen, reported in 1902, is mentioned by several writers, but the report is not available.

Case 32 (Adolph[31]).—In a fatal case in a woman aged 43, which came to necropsy, the symptoms were tumor in left hypochondrium and secondary anemia. Exploratory laparotomy was performed, and the patient died three months later. Necropsy, by Weigert, revealed a tumor of the spleen weighing 3,800 gm., and measuring 26 by 20 by 11 cm. There were adhesions to the transverse colon and the stomach, and metastasis to the stomach, glands about pancreas, retroperitoneal nodes and liver. Microscopic examination revealed lymphosarcoma.

Case 33 (Kummer[32]).—A woman, aged 53, who underwent splenectomy, performed by Kummer, recovered and was in good condition at the end of four weeks. There was a large tumor of the spleen, attended by cachexia, vomiting and anemia. Pathologic examination by Professor Askanazy revealed a spleen largely intact; a tumor the size of a child's head, and adhesions to the descending colon, pancreas and omentum. Microscopic examination of the tumor revealed lymphoid elements and reticular cells. No metastases were seen.

Case 34 (Hauptmann[33] [from von Jaksch's clinic]).—In a fatal case of a man, aged 39, with necropsy, there was a history of chancre, three years before, and tumor for two months, reaching below the navel, with fever, enlarged left inguinal glands, cachexia, diarrhea, edema of ankles, râles in lungs, and

---

28. Cassatt: Primary Sarcoma of the Spleen, Dissert., Wurzburg, 1899.

29. Whiting: Primary Sarcoma of Spleen, Tr. Chicago Path. Soc. **4**:343, 1899-1901.

30. Piazza-Martini: Lymphosarcoma, Primary Origin in Spleen, Lavori di Cong. di med. int., Roma **12**:521, 1902.

31. Adolph: Lymphosarcoma of the Spleen, Berl. Klin., No. 202, April, 1905.

32. Kummer: Splenectomy for Lymphosarcoma, Rev. méd. de la Suisse romande **28**:72, 1908.

33. Hauptmann: A Case of Primary Sarcoma of Spleen. Med. Klin., No. 7, February, 1910, p. 265.

jaundice before death. The blood count was: hemoglobin, 50 per cent.; red blood count 2,610,000; white blood count 6,400. The patient died of ruptured infarct of the spleen. Pathologic examination, by Prof. Kretz, revealed bloody fluid in abdomen. The spleen weighed 3,700 gm., and reached to the midline and the iliac crest. Infarct and rent were noted in the upper pole, with a large clot. There were large nodules on surface, fine, nodular appearance on section, with some hemorrhagic areas, and adhesions to diaphragm, liver and abdominal wall. Microscopic examination revealed small cells with dark staining nuclei. There were metastases to the liver; the glands at the lesser curvature of the stomach, and retroperitoneal and mediastinal glands.

Case 35 (W. J. Mayo[34]).—A woman, aged 41, who underwent splenectomy, performed by Mayo, with recovery, was well three and one-half years later, and had gained 40 pounds (18 kg.) in weight; but Giffin[35] reports that the patient died nine years later of generalized malignancy. There was a history of many attacks of malaria. Enlargement of the spleen was noted four years before operation, and the organ had been growing rapidly for seven months. A large notched tumor extended to the pelvis. The patient suffered from weakness, anemia, dyspnea, ascites and enlarged liver. The hemoglobin was 50 per cent.; red blood count, 4,504,000; white blood count, 4,600. The spleen weighed 2,375 gm., and was adherent to the tail of the pancreas, which was removed. Microscopic examination revealed lymphosarcoma. No metastases were seen at operation.

Case 36 (Wilson[36]).—A man, aged 45, underwent splenectomy, performed by W. J. Mayo, with recovery, but Giffin[35] reported that the patient died five months later of generalized malignancy. For two months there was enlargement of the spleen, which weighed 1,870 gm., and was broad and thick. The surface was scarred by infarcts, and on section was soft and dark. Microscopic examination revealed diffuse lymphosarcoma; pulp 4; lymphoid element, 4; reticulum, 1; endothelium, 1; pigment, 0; amyloid, 0. There was no evidence of metastases at operation.

Case 37 (Uno[37]).—In this fatal case, in a man, aged 39, there was a large spleen tumor, with pain, ascites, left hydrothorax and marasmus. The growth was the size of a man's head. The whole spleen was occupied by a yellowish white, opaque, tumor mass. There was a small amount of normal spleen at the hilum, with degenerated spaces in the center due to necrosis, and adhesions. Microscopic examination revealed large round or polyhedral cells, bound together with fine interstitial connective tissue. The nuclei were round and resembled lymphocytes. The chromatin was uniform and finely granular. The protoplasm was abundant and vacuolar, and sometimes stained basic. There were two nucleolar bodies in some nuclei. The tumor apparently originated in the germinal follicles. Metastasis to pancreas and anterior mediastinum was noted. There was a large pleural effusion on the left, with atelectasis; also ascites, and cirrhosis of the liver.

---

34. Mayo, W. J.: Surgery of the Spleen, J. A. M. A. **54**:4 (Jan. 1) 1910.

35. Giffin, H. Z.: Present Status of Splenectomy, Minnesota Med. **4**:132 (March) 1921.

36. Wilson: Studies in Pathology of Spleen, Collected Papers of Mayo Clinic, **7**:501, 1915.

37. Uno: Sarcoma of Spleen, Kyoto Igaku Zassi **14**, No. 6, 1917.

Case 38 (Moppert[38]).—In a fatal case in a man, aged 57, which came to necropsy, there was a history of severe malarial and syphilitic infections. Symptoms had been noted for seven months. The tumor was the size of a baby's head, hard and bossed, and pain was referred to the left side of the chest, and to the back and the umbilicus. There were ascites and pleural effusion on the left side. Pathologic examination was made by Professor Askanazy. A tumor found on the inferior surface of the spleen was the size of a child's fist, and had extensive adhesions. A section showed whitish homogeneous areas, with slight necrosis in the center, which were hemorrhagic in some zones. Microscopic examination revealed large round cells, with slightly basophilic cytoplasm. The protoplasm was irregular, with large nuclei rich in chromatin and occasionally double. The follicles were small and poor in lymphocytes. There was thrombosis of the splenic vein. Metastases were present in the retroperitoneal glands, about the kidney, aorta and vena cava, spine, hilum of liver, transverse colon and pancreas. The chest was not opened.

As early as 1838, Richard Bright,[39] of Guy's Hospital, wrote an interesting paper on affections of the spleen, reporting a series of cases. Of these series, Cases 18 and 19 are probably generalized lymphosarcoma with secondary involvement of the spleen.

In the foregoing group, we have included only those cases with a definite diagnosis of lymphosarcoma. It is probable that many cases reported as round cell sarcoma belong to this group, and that the number is much larger than the twenty-one cases here included. Here, again, many pathologic descriptions are incomplete; but, with a definite diagnosis of lymphosarcoma made in all cases, they have to be taken as authentic. Most of the cases were primary in the spleen, except as we have indicated above; yet on careful examination of this series, and considering the final outcome of splenectomy when the growth seemed to be a regional disease primary in the spleen, one must wonder whether the disease does not always tend to a generalized condition, at least when an incipient process is lurking in certain other lymphoid tissue even if this is not simultaneously involved. In the cases of Trelat, Kocher and Jordan, the spleen was probably secondarily involved. Certain writers question the primary origin in the case of Bacelli. The patients of von Hacker, Kocher, Jordan and Wilson died in a relatively short time after splenectomy, of generalized malignancy; while in Kummer's case, the subsequent history is lacking. In Mayo's case, the patient was well at the end of three and one-half years after splenectomy and had gained 40 pounds in weight; only to die nine years after operation of a generalized lymphosarcomatosis.

Ewing describes two types of lymphosarcoma in lymph glands: the first composed of small round cells resembling normal lymphocytes,

---

38. Moppert: Lymphosarcoma of the Spleen, Rev. méd. de la Suisse romande, No. 1 (January) 1920.

39. Bright: Abdominal Tumors and Spleen Affections, Guy's Hosp. Rep. **3**:401, 1838.

which he calls lymphocytoma; the second composed of large round cells, which he calls a reticular cell sarcoma. He believes that these definite types are not found in the spleen unless secondarily involved, but Menetrier draws the same analogy from the spleen, classifying small round cell growths as lymphocytoma and the large round cell type splenoma. In both instances, the large round cell types arising from reticular cells bear a fairly close resemblance to endothelioma.

GROUP III. PRIMARY SARCOMA, ROUND CELL SARCOMA, FIBROSARCOMA

CASE 39 (Moore[40]).—A primary sarcoma of the spleen composed of mixed cells, round and elongated without stroma, grew directly into the stomach, diaphragm and abdominal lymphatics, without secondary growths.

CASE 40 (Cohen and Riesman[41]).—In a case of small round cell sarcoma, in a man, aged 42, which came to necropsy, there had been symptoms for six months; marked enlargement of the spleen, sharp pain, feebleness, anemia, pleural effusion on the left side, intermittent fever and glycosuria. Hemoglobin was 50 per cent.; red blood count, 3,600,000. A parotid abscess developed ten days before death. The spleen weighed 6 or 7 pounds (2,727 to 3,175 gm.). The lower part was involved by a large, mottled tumor, adherent to the omentum and loops of intestine. Section showed a yellowish nonencapsulated soft tumor, the size of two fists. There was a small rim of infiltrated spleen tissue about the tumor. Microscopic findings were "typical of small round cell sarcoma." There were metastases to the stomach, omentum, mesocolon, pancreas, diaphragm, lung, mediastinum and the retroperitoneal and bronchial glands. There was 1,500 c.c. of fluid in the left side of the chest. We believe that this case was probably lymphosarcomatosis.

CASE 41 (Krylow[42]).—In a case of small round-cell sarcoma, in a patient aged 51, splenectomy was performed by Krylow, death ensuing four hours later from hemorrhage. A large tumor had been present for three years. The spleen weighed 4,250 gm., and there were extensive adhesions involving the stomach and pancreas. Microscopic examination revealed that the growth was primary small round cell sarcoma. No metastases were mentioned.

CASE 42 (Carstens[43]).—In a case of small-celled sarcoma in a man, aged 32, in which splenectomy was performed by Carstens, the patient was well three years later. Symptoms had been present for one year before operation; a hard tumor, pain, weakness and anemia. Hemoglobin was 70 per cent.; red blood count, 3,282,629; white count, 11,408, and there were some nucleated red blood cells. The spleen weighed 2,250 gm., and there were adhesions to the omentum. Microscopic examination revealed small celled sarcoma. No metastases were found.

CASE 43 (J. Collins Warren[44]).—In a case of small round-cell sarcoma in a man, aged 36, in which splenectomy was performed by Warren, a small piece

---

40. Moore: Bradshaw Lecture, Lancet **2**:415, 1889.

41. Cohen and Riesman: Case of Primary Sarcoma of Spleen, Tr. Path. Soc., Philadelphia, **17**:250, 1896.

42. Krylow: Splenectomy for Sarcoma of Spleen, Hildebrand's Jahresb. **4**:764, 1898.

43. Carstens: A Short History of Splenectomy, Med. Rec. **67**:11, 1904.

44. Warren, J. C.: Sarcoma of Spleen, Splenectomy, Ann. Surg. **33**:530, 1901.

of spleen was left attached to the stomach. Death occurred six days later from peritonitis and streptococcic septicemia. There was a history of malaria while the patient was in India. Symptoms had been noted for two months: a hard, irregular, movable tumor, loss of weight and anemia. Hemoglobin was 60 per cent.; white blood count, 5,000. The spleen measured 22 by 3 cm., and there were adhesions to the pancreas and the stomach. There was a circumscribed mass the size of two fists, surrounded by a thin capsule of spleen tissue; and a mass the size of the hand at the tail of the pancreas. Microscopic examination by Dr. Whitney revealed that the growth was a small round-cell sarcoma with tissue resembling spleen. There was metastasis or extension to the tail of the pancreas. This is the case given by Jepson and Albert as reported by Collins.

Case 44 (Bush[45]).—In the case of a large round-cell sarcoma in a man, aged 48, splenectomy was performed by Bush, but the patient died six months later of recurrence and metastases. There was a history of malaria, and a fall three years before with trauma to the left side of the back. Eight weeks before, a hard, irregular tumor, which was attended by severe pain, was discovered. Just before operation and while in hospital, the patient suddenly collapsed. Exploratory operation revealed a spontaneous rupture of the spleen, with free blood in the peritoneal cavity. The hemorrhage was checked by packing, and splenectomy was performed six days later. Six months after operation, there was a mass in the region of the spleen, with hematemesis and melena, and death followed shortly. The spleen weight was 1,420 gm. Two large white bosses, which extended to the surface and were fairly circumscribed, measured 3 and 7 cm., respectively. Microscopic examination by Dr. Ophüls revealed large round cells, with clear cytoplasm and few blood vessels. At necropsy, a large, recurrent, cystic mass, the size of a grapefruit, was found in the region of the spleen. There were metastases to the stomach, pancreas, diaphragm, suprarenal, intestines and lung. There was 1 liter of fluid in the left side of the chest.

Case 45 (Prinzing[46] [from Grawitz's laboratory]).—In a case of a large round cell sarcoma in a man, aged 50, splenectomy was performed by Bessel-Hagen. The patient recovered, but died thirteen months later of recurrence, with extension to the stomach and fatal hemorrhage. Necropsy was performed by Prinzing. There was a history of malaria and syphilis. Symptoms had been noted for six months. The spleen was greatly enlarged, and there were pain, weakness and anemia. Before death, hemoglobin was 32 per cent.; red blood count, 1,700,000; white blood count, 20,000. The patient was well nourished and had had no fever. The Wassermann reaction was positive. The spleen measured 20 by 9 by 7 cm. There were many adhesions, and only a small bit of the spleen tissue remained. On removal, a large, soft mass escaped at the hilum, and one mass the size of the hand, another the size of a billiard ball, projected through the capsule. The centers were necrotic. Microscopic examination revealed round cells larger than lymphocytes, large, vacuolated nuclei and abundant cytoplasm, and only a small amount of connective tissue. There were metastases to the retroperitoneal glands, with a large mass involving the left kidney and suprarenal, and one nodule in the gallbladder. There was

45. Bush, Camillus: A Case of Sarcoma of the Spleen, J. A. M. A. **54**:453 (Feb. 5) 1910.

46. Prinzing: Two Cases of Primary Sarcoma of Spleen, Frankfurt Ztschr. f. Path., Wiesbaden, **13**:289, 1913.

a mass the size of two fists between the stomach and liver, with extension through the wall of the stomach, and fatal hemorrhage.

Case 46 (Prinzing[46]).—In a case of large round-cell sarcoma in an obese woman, aged 53, the patient had been sick for four months. The spleen was not easily palpable. There were severe pain, high fever, dyspnea, loss of weight and appetite; the liver was palpable, and there was bloody fluid in the left chest. Spleen puncture caused rupture and death from peritonitis. The spleen, which measured 20 by 8 by 7 cm., was filled by two or three tumor masses extending to the surface, one the size of the fist, on the lower pole. There was a necrotic hole the size of an apple where the rupture occurred. All masses were soft in the center. There were adhesions to the diaphragm. Microscopic examination revealed some cells the size of lymphocytes, others large and forming nests. In general, the cells were slightly smaller than in Case 45. There were large, vacuolated nuclei, sometimes eccentric, with abundant cytoplasm. Metastases were present, to the diaphragm, left pleura and retroperitoneal glands. There was 1,500 c.c. of fluid in the left side of the chest, 500 c.c. in the right, and general peritonitis.

Case 47 (Clark[47]).—In a case of round-cell sarcoma in a boy, aged 15 months, the tumor was noted at the left crural ring shortly after birth. It was thought to be a hernia. Two months before death, there was great swelling of the abdomen, a large tumor occupying the whole left iliac fossa. The tumor growth, which extended throughout the spleen, was adherent to the colon and the left kidney, and the left testicle was involved. On microscopic examination, the growth was found to be a round-cell sarcoma. This case probably should be excluded as one of congenital sarcoma of the testicle with extension to the abdomen and spleen. Lymphosarcoma of infants arising in the testicle has been reported.

Case 48 (Herczel[48]).—In a case of round-cell sarcoma in a boy, aged 14, splenectomy was performed by Herczel, with recovery. The subsequent history is not given. The tumor was noticed one week before operation. The spleen weight was 2,450 gm., and it measured 26 by 19 cm. There was a circumscribed growth in the substance of the spleen the size of an apple. The remainder of the spleen was normal. On microscopic examination, the growth was found to be a primary round-cell sarcoma. No metastases were seen. Risel thinks that the nature of the growth suggests a secondary involvement of the spleen.

Case 49 (Weber[49]).—In a case of round-cell sarcoma in a woman, aged 55, the growth at exploratory laparotomy was found to be inoperable, and the patient died of peritonitis. The tumor had been present for six months. At necropsy, the spleen was found to be the size of a man's head, measuring 24 by 10 by 17 cm., and adherent to the diaphragm, stomach and colon. One-fourth of the spleen was normal, but not sharply defined. There was a large mass, grayish and soft in the center, with scattered nodules in the pulp. Microscopic examination revealed large round cells, with pseudo-alveolar arrangement, differing from lymphoid element. Capillaries were sparse, with flat spindle cells, and follicles were not seen. The origin was thought to be reticular cells. Metastases were present in the omentum, mesentery and retroperitoneal glands.

---

47. Clark: Congenital Sarcoma of Spleen, Brit. M. J. **1**:418, 1883.

48. Herczel: Primary Round Cell Sarcoma of Spleen, Orvosi hetil. **39**:582, 1895.

49. Weber: Case of Primary Sarcoma of Spleen, Dissert., Erlangen, 1901.

Bunting considered this case practically identical to his own. Risel thought that the cells arose from sinus endothelium. The case was probably an endothelioma.

Case 50 (Simon[50]).—In a case of round-cell sarcoma with giant cells, in a woman, aged 38, splenectomy was performed by Garré. The patient recovered, and was well four months after operation, with marked general improvement. She lived in a malarial district. Symptoms had been noted for five months, a large, hard, fixed tumor reaching the midline, with pain and slight ascites. The blood was normal. The spleen weighed 1,700 gm., measuring 22 by 13.5 by 11 cm., with adhesions to the stomach, pancreas and colon. The tumor was at the hilum, being the size of the head and involving most of spleen. Microscopic examination revealed round cells, with a large clear nucleus and small protoplasm. The cells were grouped in small masses, with many mitoses and giant cells. No metastases were present, but there were large glands at the hilum. Simon thinks that this growth developed from trabecular tissue near the hilum. Foix and Roemmele classed it as splenoma.

Case 51 (Markewic[51]).—In a case of round-cell sarcoma, in which splenectomy was performed by Markewic, the subsequent history is lacking. The spleen weighed 2,500 gm., with adhesions to diaphragm, omentum and intestines. Two large nodules involved most of the spleen. On microscopic examination, it was found that the growth was primary round cell sarcoma. There is no note regarding metastases. History and description were incomplete.

Case 52 (Faivre and Morellet[52]).—In a case of round-cell sarcoma, in a man, aged 64, symptoms had been noted for two months, a hard, smooth tumor filling the left flank and extending to the iliac fossa, with dyspnea, pain, emaciation, enlargement of liver, bloody fluid in the left side of the chest and slight ascites. The spleen weighed 1,900 gm., with adhesions to the diaphragm and pancreas, and was smooth and reddish. There was extensive invasion by grayish yellow nodules, one the size of an orange and numerous smaller ones. On microscopic examination (by Professor Auché) it was found that the growth was round-cell sarcoma. There was metastasis to the posterior wall of the stomach, pedicle of liver and tail of pancreas.

Case 53 (Meyer[53]).—In a case of round-cell sarcoma in a man, aged 30, in which splenectomy was performed by Meyer, the patient was well one year later in spite of evidence of metastasis at operation. The growth was a rapidly growing, nodular tumor, and there were marked cachexia and ascites. The spleen was large, with adhesions between the diaphragm and pancreas, and there was an embolism of the splenic artery. The retroperitoneal glands were apparently involved. Data are incomplete. G. Ben Johnston believed this a generalized condition.

Case 54 (Hendon[54]).—In a round-cell sarcoma in a woman, aged 45, splenectomy was performed by Hendon, with recovery, and the patient was well four

---

50. Simon: Splenectomy for Primary Sarcoma, Beitr. z. klin. Chir., **35**:318, 1902.

51. Markewic: Splenectomy for Primary Sarcoma, Lubarsch's Ostertag. **10,** 1904-1905.

52. Faivre and Morellet: Primary Sarcoma of Spleen, Gaz. hebd. de sc. méd. de Bourdeaux **25**:404, 1904.

53. Meyer: Splenectomy for Sarcoma, Ann. Surg. **43**:759, 1906.

54. Hendon: Primary Malignant Disease of the Spleen, Kentucky M. J. **5**:13, 1907.

months later. She lived in a malarial district. Symptoms had been noted for one year, a hard, movable mass being palpable, and the patient suffering from weakness, constipation and fatigue. The spleen weighed 2,250 gm., and there were many adhesions. Microscopic examination revealed that the growth was a round-cell sarcoma. No metastases are mentioned. The record is incomplete.

Case 55 (D'Arcy Power[55]).—In a case of round-cell sarcoma in a woman, aged 49, splenectomy was performed by Power, with recovery; but the patient failed slowly, and died six months later. There was no necropsy. Symptoms had been noted for nine months, a large, irregular, solid tumor extending to the anterior iliac spine and midline, with pain, anemia and cachexia. The spleen weighed 1,980 gm., and there were adhesions, and numerous large, soft glands in the region of the spleen. The lower two-thirds of the spleen was replaced by necrotic growth, there being little spleen tissue left. The accessory spleen was left in situ. On microscopic examination, the growth was found to be round-cell sarcoma. No metastases are mentioned except glands about the spleen, but the patient probably died of metastases.

Case 56 (Deaver[56]).—In a case of round-cell sarcoma in a woman, aged 38, in which partial splenectomy was performed by Deaver, the upper pole was left in; and the patient recovered, and was well six weeks after operation. Symptoms had been noted for six months, a large, freely movable tumor extending to iliac crest, with lower edge bossed; and pain, chills and fever. Hemoglobin was 51 per cent.; red blood count, 3,570,000; white blood count, 9,950. The spleen weighed 1,500 gm., measuring 25 by 15 by 11 cm., and was firm and nodular. Microscopic examination revealed round-cell sarcoma, with hemorrhagic areas, acute splenitis and connective tissue proliferation. No metastases are mentioned, and the subsequent history is not given.

Case 57 (Woodruff[57]).—In a case of medullary sarcoma in a woman, aged 28, which came to necropsy, symptoms had been noted for one year: a tender mass in the left hypochondrium, intermittent fever, pain, emaciation, anemia and ascites. The spleen was two or three times normal size, with adhesions, and a hard lobulated cartilaginous growth attached to the capsule by a pedicle 1 inch (2.5 cm.) in diameter. The tumor, 18 inches (45 cm.) in circumference, showed some softening, with a creamy material resembling brain. About one fourth of the spleen showed invasion with the same appearance as the tumor. No microscopic examination was made. There were metastases to the liver, and adhesions to the omentum, stomach, pancreas, left kidney and diaphragm. This case is evidently a sarcoma arising in the capsule.

Case 58 (Weichselbaum[1]).—In a case of fibrosarcoma of the capsule in a man, aged 21, which came to necropsy, the patient died of mastoiditis and brain abscess. No symptoms referable to the spleen were present. A walnut-sized, balllike tumor was present, projecting 0.5 cm. from the surface, easily shelled out, hard and interlaced with whitish streaks. Microscopic examination revealed spindle cells with fibrous septums containing blood vessels, and spindle and angular cells in the groundwork. There was some extravasation. The tissue

---

55. Power: Removal of Spleen for Sarcoma, St. Bart. Hosp. Rep. **44**:99, 1908.

56. Deaver: Sarcoma of Spleen, Splenectomy, Recovery, Internat. Clin., Philadelphia, **3**:223, 1914.

57. Woodruff: Medullary Sarcoma of Spleen, Cincinnati and Western J. M. **2**:471, 1867.

resembled pulp in some areas. There was no definite capsule. Yellowish pigment was present. No metastases were found.

Case 59 (Heinricius[58]).—In a case of fibrosarcoma of the capsule enucleation of the growth on the spleen was performed, by Heinricius, with recovery; but the patient died seven years later, showing recurrence in the abdominal wall. There was no necropsy. The tumor, which weighed 3,500 gm., arose from a pedicle as thick as a man's arm. The spleen looked normal. On microscopic examination, the growth was found to be fibrosarcoma with myxomatous degeneration.

Case 60 (Jepson and Albert[59]).—In a case of fibrosarcoma in a girl, aged 15, in which splenectomy was performed by Jepson, with recovery, the patient was in good health ten months later. The tumor had been noted five months before, attended by a dragging sensation, and extending 2 cm below the costal margin. The patient was in good health, and the blood was normal. The spleen weighed 256 gm.; the tumor weighed 190 gm., and measured 9.5 by 8.2 by 7.7 cm. It was encapsulated in the lower part of the spleen, nodular, hard and bright red. The spleen tissue was yellowish brown, and did not seem to have been destroyed. Microscopic examination by Albert revealed: cells mostly spindle shaped, some round; nuclei rich in chromatin with small cytoplasm; some fibrous connective tissue between cells; blood vessels poorly formed, lined by endothelial or tumor cells; no definite capsule made out; spleen tissue normal except crowded portions adjacent to tumor; no metastases or adhesions. Risel thinks that the type of cell here might suggest an endothelial origin.

Case 61 (Kendall[60]).—In a case of primary sarcoma in a man, aged 33, which came to necropsy, the patient died from rupture of the necrotic area in the spleen, with peritonitis. There was a history of malaria. Symptoms had been noted for six weeks: a hard, nodular tumor, high fever, ascites, pain and emaciation. Pus was withdrawn at spleen puncture; then a small exploratory incision was made, and a cavity the size of an orange was drained. Later, the patient had severe abdominal pain for forty-eight hours, and died from rupture of another necrotic area the size of a hen's egg, with resulting peritonitis. The spleen measured 11 by 5 by 4.5 cm., had adhesions and was nodular. Section revealed a large number of nodules the size of a walnut, firm, yellowish brown and not encapsulated. Microscopic examination revealed: "a structure of sarcomatous tissues." There was 1,800 c.c. of fluid in each pleural cavity, and peritonitis was present. No metastases are mentioned. We believe that this condition might have been multiple abscesses of the spleen rather than sarcoma.

Case 62 (D'Antona[61]).—In 1895, a case of sarcoma in an ectopic spleen was reported for which splenectomy was performed. It is quoted from Carstens, but the reference is incorrect and the report was not found.

Case 63 (Jameson[62]).—In a case of primary sarcoma in a woman, aged 18, the tumor filled the entire left side and the pelvis, so that vaginal examination

---

58. Heinricius: Fibrosarcoma of Spleen, Capsular Origin, Centralbl. f. chir., 1898.

59. Jepson and Albert: Primary Sarcoma of Spleen, Splenectomy, Ann. Surg. **40**:80, 1904.

60. Kendall: Sarcoma of Spleen, Med. Rec. **20**:123, 1881.

61. D'Antona: Splenectomy for Sarcoma in Ectopic Spleen, quoted from Carstens (Footnote 43).

62. Jameson: Sarcoma of the Spleen, Surg. & Clin., Chicago **1**:258, 1901.

was impossible. The growth was boggy and tender. There was marked ascites. Paracentesis was performed and 8 quarts (liters) of fluid was removed. Later, 12 quarts more was withdrawn. The patient showed anemia. She went to New York, where an exploratory laporatomy was performed. A specimen excised from the spleen tumor showed, on microscopic examination, "a definite sarcoma." The patient returned home showing extreme emaciation, and had a foul discharging sinus in the abdominal wound for a long time. Two years later, she was well and the spleen was barely palpable. This result could be explained only by "the father's unswerving faith in her recovery."

Case 64 (Lecaplain[63]).—In a case of primary sarcoma in a woman, aged 48, which came to necropsy, there was a history of typhoid. Symptoms had been noted for two months, a hard, bosselated tumor occupying most of the left hypochondrium, with pain in the left side of the chest, fever, emaciation, feebleness, anemia and ascites. The red blood count was 3,600,000; white blood count, 6,300. The glands in the left side of the neck and the left axilla were enlarged. The spleen measured 25 by 15 by 8 cm., and was hard and nodular. About a dozen yellow nodules, from the size of a grain of wheat to the size of an orange, were present on the surface, with adhesions to diaphragm and pancreas. Microscopic examination by M. Neé revealed: "Primary sarcoma of spleen"; glands involved in the left side of the neck; glands the size of an orange in the left axilla, along the lesser curvature of the stomach and about the aorta and in the mesentery. We consider that this is probably a case of general lymphosarcomatosis.

Case 65 (Villard and Santy[64]).—In a case of primary sarcoma in a man, aged 22, splenectomy was performed, with recovery, and no subsequent history is given. The patient had a "cold abscess" of the radius incised and drained sometime before. The Wassermann reaction was positive. No symptoms were present except enlargement of the spleen. The spleen weighed 1,240 gm., was of angiomatous aspect, and had nodules the size of an orange. Microscopic examination revealed an angiomatous, pseudolacunar arrangement. There were large cells, abundant protoplasm and numerous mitotic figures. Islets of necrosis were present. No tuberculous giant-cells were found, and no metastases. History and description are incomplete. We believe that this is probably an angioma, with transition to endothelioma.

Case 66 (Council[65]).—In a case of mixed cell sarcoma in a man, aged 58, splenectomy was performed, and the patient was well six months later, and had gained 35 pounds (16 kg.). There was a history of injury to the left flank followed by severe pain. Two years previously, he was told that he had a mass in the left upper quadrant, probably a floating kidney. He had had considerable abdominal pain, and was a morphin addict. There was a mass in the left hypochondrium, 8 by 16 cm., not tender. The white blood count was 20,200; polymorphonuclears, 68.5 per cent.; eosinophils, 5 per cent.; lymphocytes, 26 per cent.; large mononuclears, 3 per cent. The spleen weighed 600 gm. and measured 9 by 27 cm. The surface was irregular and mottled. Micro-

63. Lecaplain: Case of Sarcoma of Spleen, Normandie méd., Rouen, **26**: 105, 1911.

64. Villard and Santy: Presentation of a Tumor of the Spleen, Lyon méd. **120**:342, 1913.

65. Council: Primary Sarcoma of the Spleen, Ann. Surg. **56**:915, 1912.

scopic examination revealed: mixed cell sarcoma with little spleen pulp remaining. No mention is made of any evidence of metastasis at operation.

Case 67 (Duchemin[66]).—In a case of primary sarcoma in a man, aged 46, which came to necropsy, the patient complained of general weakness and loss of weight. There was slight fever. The spleen was two fingers' breadth below the costal margin and felt hard on palpation. There was moderate anemia. The patient gradually failed, and died two months after entering hospital. The spleen weighed 450 gm., and was hard, with many nodules beneath the capsule near the hilum. The nodules varied from the size of a lentil to the size of a half a centime piece. There were many nodules throughout the spleen. No metastases were noted except in the nodes along the ninth to the twelfth dorsal vertebras. Microscopic examination by Dr. Papin revealed: neoplastic zones made up of large cells of various forms and dimensions; giant cells present; cells oval or polygonal, each nucleus having a large nucleolus; mitotic figures found, but rather rare.

In this group, it will be noted that the microscopic descriptions are extremely meager. Most of the growths are undoubtedly lymphosarcoma, either primary, or part of a generalized process. The small round-cell types correspond well with those of lymphoid origin called lymphocytoma. The large round-cell types, which probably arise from reticular cells, and resemble rather closely the tumors of endothelial origin, have been designated splenoma. A few of the foregoing cases, as we have indicated, probably arose from endothelium and have been classified as endothelioma by several writers. The cases of fibrosarcoma of the capsule do not belong strictly to this series; but their origin is of interest and they are included. Jepson and Albert report the only case of fibrosarcoma arising in the substance of the spleen, and Risel thinks that this tumor may be of endothelial origin.

The small round-cell sarcoma respresenting an undifferentiated type of malignant tumor arising from connective tissue is very rare if it is separated from the lymphosarcomas. In many cases, this distinction is impossible. If, however, it is found early, occurring in lymphoid tissue, it presents certain characteristics of value in its differentiation. The early nodules are discrete, with surrounding lymphoid tissue intact; while lymphosarcoma usually appears as a regional growth, with diffuse involvement of lymphoid tissue; but here also circumscribed nodules appear. The round-cell sarcoma invades the blood stream with early metastases to distant organs, especially the lungs, while lymphosarcoma is usually more localized, forming large tumor masses in the region of the glands. Lymphosarcoma may often be distinguished from the tumors of endothelial or reticular origin by their hyperchromatic nuclei with indistinct nucleoli; while the latter have clear vesicular nuclei with one or more prominent nucleoli. Apparently, however, many atypical or

66. Duchemin: A Case of Primary Sarcoma of the Spleen, Thèse de Paris, 1920.

transition forms occur; and, from a single section, it is often difficult to make an exact diagnosis, especially between the small round-cell sarcoma and the small cell type of lymphosarcoma.

GROUP IV. MISCELLANEOUS DIAGNOSES

Case 68 (Friedreich[67]).—In a case of nodular hyperplasia, in a man, aged 56, which came to necropsy, death resulted from apoplexy. There were many small, firm nodules up to the size of a pea, separated from the spleen parenchyma. Microscopic examination revealed spleen parenchyma cells with round or oval nuclei, resembling liver cells misplaced in the spleen. Nodules were found anastomosing with connective tissue and primitive cells reduced to background. Similar nodules were found in the liver. Weichselbaum and Bunting consider this an endothelioma.

Case 69 (Lancereaux[68]).—In a case of embryonic fibroma in a woman, aged 67, which came to necropsy, the patient died of "pulmonary complications." An enormous tumor was present in the left hypochondrium. The spleen was 30 by 12 cm. A nodule the size of an apple projected to the surface. There were three chestnut-sized tumors in the upper pole. The lower half of the spleen was occupied by a mammellated, lardaceous tumor, with a few hemorhagic areas. The growth was fairly well circumscribed, soft and yellowish in the center, with some milky fluid. Microscopic examination revealed: round and fusiform cells, embryonic in type; extension to diaphragm and tail of pancreas; adhesions to liver, stomach and intestines.

Case 70 (Helmuth[69]).—In a case of sarcoma of the myeloid type, in a girl, aged 18 months, in which splenectomy was performed by Helmuth, the patient died from hemorrhage. There was a large tumor of the spleen, weighing 5,000 gm. Microscopic examination revealed: spindle cell sarcoma, with cells myeloid in type. The original report is not available.

Case 71 (Schönstadt[70]).—In a case of mixed tumor, endothelioma and fibroma, in a man, aged 39, which came to necropsy, there was a sudden onset of symptoms, the patient being well four weeeks before death. The spleen weighed 1,360 gm., with adhesions to adjacent organs. Section revealed that the spleen tissue was practically replaced by yellowish white areas, and there was an abscess in the pulp the size of a cherry. Microscopic examination revealed: columns of large round cells and nests of cells poor in connective tissue; some masses of transitional cells; immediately about vessels, masses of endothelial cells, and beyond a zone poor in cells; metastases to right ilium, twelfth dorsal vertebra and colon, and few nodules along lesser curvature of stomach. We consider that this is probably an endothelioma of the spleen.

Case 72 (Javrin[71]).—In a case of splenoma, in a woman, aged 45, in which splenectomy was performed by Javrin, the patient died the following day, from

---

67. Friedreich: Multiple Nodular Hyperplasia of Spleen and Liver, Virchow's Arch. f. path. Anat. **33**:48, 1865.

68. Lancereaux: Embryonic Fibroma of Spleen, Traité d'anat. path., Paris, **2**:597, 1879.

69. Helmuth: Splenectomy for Sarcoma, Reports of Helmuth House, **3**:14, New York, 1888.

70. Schönstadt: Primary Sarcoma of Spleen, Dissert., Würzburg, 1891.

71. Javrin: Removal of Spleen Followed by Death, Am. J. Obst. **41**:85, 1900.

shock. There was a tumor in the left hypochondrium the size of a baby's head, extending from the costal margin to the pelvis. There was marked weakness. The spleen weighed 3,750 gm. Pathologic examination by Ewing revealed: hypertrophy of pulp tissue only, atrophic malpighian bodies; cells identical with large mononuclear phagocytes in the spleen; peculiar, large round cells like spleen lymphocytes; sinuses and follicles partially preserved. Ewing first considered this a simple hyperplasia. Later, in his book on tumors, he calls this a splenoma similar to the cases of Menetrier and Gröhe, both of which showed extensive metastases.

Case 73 (Stengel [72]).—In a case of "neoplasm of spleen comparable to diffuse myeloma or certain infiltrating sarcomas of the liver," in a woman, aged 21, in which splenectomy was performed by J. G. Clark, the patient was in good health three months after operation. The father died of malaria, and the patient had probably had the same infection. Pain, which had been present in left hypochondrium for many years, had grown and a tumor had been palpable for three months. There was tenderness of the spleen extending to the umbilicus and the iliac crest, with loss of weight. Blood and urine were normal. The spleen weighed 1,230 gm., and measured 22 by 13 by 7 cm., with firm, numerous umbilicated nodules, 1 to 2 cm. in diameter, on the surface. On section, a dense tumor involving the whole spleen, with nodules on the surface as outgrowths, but no necrosis or softening, was disclosed. Microscopic examination revealed marked growth of connective tissue forming alveoli containing large cells with pale nucleus; giant cells abundant; endothelial cells present with one or two large nuclei; lymphoid element inconspicuous; malpighian corpuscles atrophied, some showing fibrosis, others transformed to alveoli filled with tumor cells; no metastases or adhesions at operation. We consider this as probably a slowly growing endothelioma.

Case 74 (Cerkasov [73]).—In a case of perithelioma in a boy, aged 11, splenectomy was performed by Cerkasov, with recovery. A rapidly growing tumor had been present for one year. The spleen weighed 1,550 gm. and measured 11 by 15 by 7 cm. There were many blood vessels. The alveoli were filled with oval and spindle cells, occurring mostly in vessel walls against the endothelium but separated from it. No metastases are mentioned. We think that this case is probably an endothelioma.

Case 75 (Menetrier [74]).—In a case of massive splenoma in a man, aged 47, which came to necropsy, the spleen weighed 600 gm., and was hard and nodular, The tumor occupying the upper part of the spleen was yellowish white, hard and friable, with points of softening in the center. Microscopic examination revealed large, polygonal and ovoid cells, with large nuclei and many mitoses, and giant cells. Cells arose from acrophages of the pulp and lodged in stroma formed by hyperthrophy of the reticulum. Metastases were present in the peritoneum, pancreas, suprarenal capsule, glands and lung. This description does not seem to us inconsistent with endothelioma of the spleen.

Case 76 (McConnell [75]).—In the case of perithelioma or endothelioma in a man, aged 29, in which splenectomy was performed, the patient was well

---

72. Stengel: Varieties of Splenic Anemia, Am. J. M. Sc. **128**:511, 1904-1905.

73. Cerkasov: Perithelioma of Spleen, Ztschr. f. Path. u. Anat. No. 4, p. 153, 1907.

74. Menetrier: Massive Splenoma, quoted from Foix and Roemmele (Footnote 77).

75. McConnell: Primary Tumor of the Spleen, Boston M. & S. J. **166**:288, 1910.

two years later. Eighteen months before, the patient felt "something give way" in the left hypochondrium while he was lifting a trunk. There was a mass extending below the costal margin. Five hundred cubic centimeters of soft matter escaped from the spleen at operation, and broken down spleen tissue escaped from a cavity with smooth walls. Microscopic examination revealed some normal spleen tissue left; hemorrhagic areas, and many irregular but sharply defined cell masses arranged mostly about the blood vessels. The nuclei were oval and twice the size of a lymphocyte. The cells stained faintly. No mitotic figures were seen. No metastases were seen at operation. We believe that this might have been a cyst, or organization about an area of hemorrhage.

Case 77 (Golovina-Ammon[76] [from Schmidt's laboratory at Zurich]).—In a case of angiomatous fibrosarcoma in a boy, aged 16, death from tuberculous meningitis occurred. The patient had an old tuberculosis of the lungs. The spleen measured 13 by 6 by 2 cm. Its form was unaltered, but there were many sharply defined, grayish nodules on the surface; a bluish mass was found in the upper pole the size of a walnut, and many distended vessels and many grayish red, nonencapsulated nodules the size of a pea, having a vessel in the center, were found in the substance of the spleen. There was one tuberculous nodule in the lower pole. Microscopic examination revealed: cavernous spaces in the tumor filled with blood; masses of endothelial cells which could be traced to sinuses, and many round or oval cells with elongated nuclei larger than pulp cells. Other areas showed spindle-cell overgrowth apparently arising from the reticulum and trabeculae. The follicles had disappeared in many places, and there was some fibrosis. There was no tuberculosis except in the one nodule. No metastasis was found. This case is quite similar to some reported in Group I. We believe that it is probably an angioma with transition to endothelioma.

Case 78 (Foix and Roemmele[77]).—In a case of nodular reticulosplenoma in a woman, aged 45, which came to necropsy, symptoms had been present for four months, a tender spleen tumor extending the width of four fingers below the costal margin, pain, cough, dyspnea, emaciation, anemia, bloody fluid in the left side of the chest, ascites and enlargement of the liver. Hemoglobin was 70 per cent.; red blood count, 3,150,000; white blood count, 12,500; fragility, normal. The spleen weighed 1,400 gm., and measured 26 by 13 by 8 cm., the shape was preserved, and there were no adhesions. The cut surface was coarsely granular, with innumerable nodules the size of millet seed to the size of a nut. There were three nodules, 2 cm. in diameter. The background of the spleen was brownish. A small accessory spleen showed the same type of growth. There were yellowish nodules along the splenic vein, which were fused in places. Microscopic examination revealed a normal reticular tissue replaced by fibrosis; pulp obscured, and a diffuse infiltrating growth with nodules replacing follicles and forming alveoli filled with cells. These had a small vessel in the center. The cells arose from macrophages and reticulum of malpighian corpuscles. They were polyhedral or round, and had large nuclei and abundant protoplasm. There were many mitoses and giant cells. Transition was seen from inflammatory hyperplasia to true neoplasm. The bone marrow showed myeloid reaction. There were metastases to the left supra-

76. Golovina-Ammon: Case of Angiomatous Fibrosarcoma of Spleen, Dissert., Zurich, 1910.

77. Foix and Roemmele: Primary Sarcoma of Spleen, Arch. de méd. expér. et d'anat. path. **24**:111, 1912.

renal and glands along the splenic vein. This case resembles those of Friedreich and Stengel. We believe that it may be classified as an endothelioma.

Case 79 (De Renzi[78]).—In a case of neoplasm of malignant nature in a man, aged 24, which came to necropsy, there were symptoms for seven months. The tumor when first noted was the size of an orange. It grew rapidly to within 4 to 5 cm. of the pubic arch, and was irregular and of woody consistency. Emaciation, edema, ascites and loss of weight and strength were present, and the face was pigmented. The liver was small. Hemoglobin was 52 per cent.; red blood count, 2,750,000; white blood count, 9,400. The spleen was enormously enlarged and hard, and the surface showed many nodules with indurated margins. Microscopic examination by Professor Gianturco revealed: cells from spleen puncture resembling lymphocytes; nuclei large and rich in chromatin; many irregular cells with delicate projections on one side, and many mitoses. The histology of the spleen showed definitely "a neoplasm of malignant nature." No metastases were found at necropsy. We believe that this is probably a lymphosarcoma.

Case 80 (Cesaris[79]).—In a case of splenoma or fibrosplenoma in a woman, aged 76, which came to necropsy, death was due to myocarditis. Emaciation and edema of legs are the only symptoms given. The spleen measured 12 by 8 by 7 cm., and there were no adhesions. On the posterior surface was a circumscribed tumor, 8 cm. in diameter. Cavernous veins were present, giving the growth a hemangiomatous appearance. Microscopic examination revealed alveolar cavities lined by "epithelium" and filled with blood; diffuse fibrosis; nuclei having fine bluish granules; abundant granules in the cytoplasm, and giant cells. No metastases were found. We consider that this is probably an angioma with slow transition to endothelioma.

This group of cases illustrates remarkably well the difficulty of diagnosis in some of these tumors. Even after Menetrier, Foix and Roemmele and Ewing[80] have traced their neoplasms to their exact origin in certain elements of the spleen, they pause for a terminology which would correspond to the standard classification of tumors found elsewhere in the body; and then invent special names for these tumors of the spleen.

The cases of Friedreich, Schönstadt, Menetrier, Cerkasov, Golovina-Ammon and Foix and Rommelle are probably of endothelial origin, whether vascular, sinus, or the reticulo-endothelial cells of pulp or follicles. The cases of Javrin and Stengel may be modified forms of endothelioma not far removed from the simple hyperplasias. The case of Golovina-Ammon probably represents a transition from a tuberculous granuloma to an early malignant neoplasm of the spleen, with some benign angiomatous areas still present. The case of De Renzi is probably a lymphosarcoma. Some of these cases lack complete descrip-

78. De Renzi: A Rare Case of Primary Cancer of the Spleen, La nuova Riv. clin. terap., Napoli, **16**:293, 1913.

79. Cesaris: A Case of Fibrosplenoma, Pathologica, Genova **12**:3, 1920.

80. Ewing, James: Sarcoma of the Spleen, Neoplastic Diseases, Philadelphia, W. B. Saunders Company, 1919.

tions, and an exact classification is impossible. It is not surprising that new terms have arisen in the attempt to classify many of these tumors; but it would greatly simplify matters if a more uniform standard could be adopted. This classification should be based on the origin from the three histologic elements mentioned above. Since Menetrier published his case with a diagnosis of splenoma, several other cases have been classified as such; but it seems to us that this terminology is not justified on a histologic basis, and that these cases are either endothelioma or a large cell type of lymphosarcoma, as we have indicated above.

GROUP V. CASES REPORTED AS CARCINOMA

Case 81 (Halla[81]).—In a case of medullary cancer of the spleen in a man, aged 50, which came to necropsy, there was a large tumor in the left hypochondrium, attended by cachexia. The spleen was twice the normal size, with a medullary cancer the size of the fist within. No microscopic examination was made. No metastases were found.

Case 82 (Parker[82]).—In a case of carcinoma of the spleen in a woman, aged 50, which came to necropsy, there had been symptoms for six months, a tumor of the spleen filling the left side and the pelvis, a metastatic nodule in the chest wall, a large left pleural effusion, anemia, fever, edema of the left leg and abdominal pain. The spleen weighed 1,600 gm., extending from the diaphragm to the crest of the ilium, with yellowish nodules on the surface. The upper third was occupied by an encephaloid mass, with diffuse nodules throughout. There was no microscopic examination. There were metastases near the liver and in the adherent abdominal wall, and there was a nodule between the ribs, growing externally.

Case 83 (Gunzbourg[83]).—In a case of medullary carcinoma of the spleen in a woman, aged 43, which came to necropsy, there was a hard, nodular tumor reaching the umbilicus, with pain, fever, edema, pleural effusion and ascites. The spleen weighed 4,000 gm. and there were many nodules on cut section. Microscopic examination revealed "large round cancer cells." There was metastasis to the glands in the mesentery and about the pancreas. The growth was probably a large cell lymphosarcoma.

Case 84 (Barth[84]).—In a case of carcinoma of the spleen in a woman, aged 59, the tumor was discovered at necropsy. The spleen was greatly enlarged and contained fairly large cancerous nodules. There was no microscopic examination, and no metastases were found.

Case 85 (Borland[85]).—In a case of cancerous disease of the spleen in a man, aged 22, which came to necropsy, there had been symptoms for five months: enlarged spleen, pain, dysphagia, jaundice, leukocytosis, enlarged

---

81. Halla: Medullary Cancer of Spleen, Prag. viertel. Jahr. **1**:1, 1844.

82. Parker: Carcinoma of the Spleen, New Hampshire J. Med. **6**:104, 1850.

83. Gunzbourg: Primary Cancer of Spleen, Ztschr. f. klin. Med. **4**:5, 1854.

84. Barth: A Case of Cancer of the Spleen, Dict. Deschambre, 1861.

85. Borland: Case of Cancerous Disease of the Spleen, Boston M. & S. J., **76**:282, 1867.

glands in neck, left pleural effusion and ascites. The spleen measured 10 by 5 cm., with surface knobbed and uneven with yellowish white, irregular nodules; and some necrosis seen on cut section. Microscopic examination by Dr. Swan revealed: numerous slender pisiform caudate and stellate cells; nuclei round or oval, with one or two nucleoli; glands of neck showing fine fibroplastic cells; metastases to glands in neck, thorax and abdomen, pancreas and neck of gallbladder; lungs and liver studded with hard nodules the size of pinhead, and extension to the colon with ulceration. We believe that this case is a probably generalized lymphosarcomatosis.

Case 86 (Bridges[86]).—In a case of carcinoma of the spleen in a man, aged 55, which came to necropsy, symptoms had been noted for a year: a large tumor, pain, intermittent fever and emaciation. The growth invaded the stomach, causing fatal hemorrhage. The spleen weighed 5,000 gm., and was adherent to the adjacent organs. There was a white, scirrhous mass in the substance of the spleen typical of a neoplasm. No means of making a histologic examination were available. There was extension to the stomach, with hemorrhage and death. No malignancy was present elsewhere.

Case 87 (Perry[87]).—In a case of cancer of the spleen in a man, aged 50, which came to necropsy, debility and gastric disturbance had been present for nine months, and a large, rapidly growing tumor for three months, with edema, ascites and pleural effusion. The spleen, which weighed 6,000 gm., was of albuminous nature with little fibrous character. Some sacs filled with gummy material were noted. Lister saw the specimen and in discussing the case considered it an intermediate stage between scirrhous and encephaloid cancer of the spleen. No histologic examination was made. There was metastasis to the mesentery. At this meeting, Perry read notes of a similar case that had been under his care. Bunting considers this case a sarcoma.

Case 88 (Brown[88]).—In a case of medullary cancer of the spleen in a man, aged 60, which came to necropsy, sixteen months before the condition was thought to be tertian malaria. There was pain in the region of the spleen. Six months before, the patient began having severe chills, fever and severe pain, with slight ascites, emaciation and rapid pulse. Pathologic examination by Dr. Paddock revealed that the spleen was one-third larger than normal, with a whitish, peculiar nodular appearance, and firm and elastic. Section showed a firm medullary cancer of Paget, with thick creamy fluid from cut surface. Microscopic examination revealed a mass of tumor cells embedded in a fibrous stroma. The malpighian corpuscles were obliterated. No metastasis was found.

Case 89 (Arnott and O'Connor[89]).—In a case of primary (?) cancer of the spleen, in which no history was given, the specimen was exhibited as an instance, supposed to be unique, of primary cancer of the spleen. No other new growth was found in the body. There was a large left pleural effusion without inflammation.

---

86. Bridges: Primary Carcinoma of the Spleen, Chicago M. J. **25**:729, 1868.
87. Perry: Cancer of the Spleen, Glasgow M. J. **1**:275, 1869.
88. Brown: Medullary Cancer of the Spleen, Med. Rec. **5**:196, 1870.
89. Arnott and O'Connor: Primary (?) Cancer of the Spleen, Tr. Path. Soc., London, **24**:222, 1872-1873.

A report of the Committee on Morbid Growths read: " . . . shows everywhere a distinctly alveolar structure, the alveoli filled with cells, many of which contain more than one nucleus; cells larger than those of spleen; regions of disintegration in the growth. The adjacent spleen tissue shows chronic induration and the interalveolar substance of the tumor is continuous with the reticular structure of the organ." We believe that this is probably an endothelioma.

Case 90 (Mosler[90]).—In a case of carcinoma of the spleen in a man, aged 45, which came to necropsy, a large spleen tumor was present, with icterus and ascites. The spleen was greatly enlarged, with hard, circumscribed, yellowish nodules on the surface, the size of a dollar. No microscopic examination was made. Metastases to abdominal cavity and liver were noted.

Case 91 (Notta[91]).—In a case of carcinoma of the spleen in a boy, aged 7, symptoms had been present for six months, the left flank being filled with a smooth tumor; with pain, chills and fever and hematuria. The liver was enlarged and nodular. Litten thought that this was probably a sarcoma of the kidney.

Case 92 (Affre and Moutard-Martin[92]).—In the case of a man, aged 51, the symptoms were: spleen tumor extending to umbilicus, cachexia and anemia. At necropsy, spleen sections showed yellowish white, cancerous nodules 1 to 1.5 cm. in diameter. No microscopic examination was made. A "number of metastases" were noted.

Case 93 (Glaucher and Verite[93]).—in 1882, these authors reported a case of primary carcinoma of the spleen. The case is mentioned by De Renzi, but the original report is not available.

Case 94 (Grasset[94]).—In a case of encephaloid cancer of the spleen in a man, aged 46, which came to necropsy, the symptoms were: enlarged spleen, severe pain, cachexia, diarrhea and melena. The spleen, which was nodular, was adherent to the neighboring organs, with hemorrhagic areas in the interior and encephaloid cancer. Perisplenitis and perihepatitis were present. No microscopic examination was made, and no metastases were found. Bunting considered this splenic anemia; Foix and Roemmele, a primary sarcoma.

Case 95 (Casati[95]).—In 1904, this author mentioned a splenectomy which was peformed for carcinoma of the spleen, with recovery. No descriptions or further history are given.

Case 96 (Cowan[96]).—In a case of scirrhous carcinoma of the spleen in a woman, splenectomy was performed by H. Brown, and the patient died three

---

90. Mosler: Carcinoma of the Spleen, Ziemssen's Handb. d. sp. Path. u. Ther. **8**:139, 1875.

91. Notta: Primary Carcinoma of the Spleen, Arch. gén. de méd. **17,** 1886.

92. Affre and Moutard-Martin: Primary Cancer of the Spleen, Bull. et mem. Soc. méd. d. hôp. de Paris, p. 328, 1876.

93. Glaucher and Verite: Cancer of the Spleen, quoted from DeRenzi (Footnote 78).

94. Grasset: Etude clinique et anatomique sur le cancer de la rate, Montpellier, 1875.

95. Casati: Carcinoma of the Spleen, Zentrabl. f. Gynäk., No. 24, p. 768, 1904.

96. Cowan: Splenectomy for Scirrhous Carcinoma, Am. Pract. & News, Louisville, **16**:24, 1893.

hours later of shock. She lived in a malarial district. Symptoms had been present for thirteen months; a large, firm, immovable tumor, with severe pain. The appetite was good. The spleen weighed from 12 to 15 pounds (5.4 to 6.8 kg.). Yellow, semisolid masses arose from three foci, with apparently normal spleen between. A microscopic examination later by L. Frank revealed: much decomposition of specimen; regular capsule; dense fibrous tissue with cancer cells between. Scirrhous carcinoma of the capsule (metastatic?) was diagnosed. No metastases or other origin of the tumor was found at operation.

Case 97 (Jousset[97]).—In a case of cancer of the spleen in a man, aged 54, with a history of malaria, symptoms had been present for seven months: greatly enlarged spleen, emaciation, vomiting, dyspnea and fever. The red blood count was 2,955,000; white blood count from 9,400 to 16,200. An exploratory laporatomy by Routier revealed a greatly enlarged, firm, irregular spleen, with marked adhesions. There were nodules in the omentum and along the stomach, and the condition was considered inoperable. No sections were removed, and there was no necropsy.

Case 98 (Bamburger[98]).—In a case of cancer of the spleen in a man, aged 18, with necropsy, the spleen measured 30 by 15 cm., and enormous, cancerous nodules were present. No metastases were noted. Description is incomplete.

Case 99 (Hart[99]).—In a case of primary encephaloid growth of the spleen in a girl, aged 4½ years, which came to necropsy, the parents found the tumor in the region of the spleen at the age of 6 months. Six months before death, the growth almost reached the umbilicus. Two months before death, it began to grow very rapidly and filled the abdominal cavity. Emaciation became very marked. On examination, the spleen was hard and nodular, and reached the right iliac crest. Necropsy revealed extensive adhesions to the spleen. The spleen weight was estimated at 6 or 7 pounds (2.7 or 3.2 kg.). The organ measured 14.4 by 10.5 by 8.3 inches (36 by 26.25 by 20.75 cm.). The surface was studded with rounded nodules, brownish yellow mixed with white, with enlarged, tortuous veins over the surface. No normal spleen tissue remained. Section showed an encephaloid type of growth, with occasional hemorrhagic areas. The lymph nodes about the spleen and pancreas were soft, and there was no trace in any other organ. No microscopic examination was made.

Most of these cases are undoubtedly primary lymphosarcoma or endothelioma of the spleen. It will be noted that many were reported before the microscope came into common use, and histologic examinations are usually lacking. By definition, carcinomas could arise in the spleen only from epithelial inclusions, and as no authentic case has ever been reported, we may exclude this diagnosis from the series of malignant tumors of the spleen.

---

97. Jousset: Observations on Primary Cancer of Spleen, l'Art méd., Paris, **100**:170, 1905.

98. Bamburger: Cancer of the Spleen, quoted from Pfister: Primary Tumors of the Spleen, Dissert., Wurzburg, 1901.

99. Hart: Primary Encephaloid of the Spleen, Western Lancet **17**:659, 1856.

In addition to the cases mentioned in the foregoing groups, references are found to cases reported by Marcondas-Recende,[100] Meuki,[101] Ohaashi,[102] Rochard[103] and Sangalli,[104] but we have been unable to obtain these records. This makes a total of 104 cases in our series. Goldstein,[105] in 1922, reviews the literature on primary sarcoma of the spleen but does not report any cases in which the spleen was primarily involved.

Considering all of the reported cases from a clinical standpoint, all cases presented symptoms sufficient to make one suspect the diagnosis of a splenic tumor, except six, where the tumors were found at necropsy, the patients having died of intercurrent disease before the growth had become pronounced. In practically all cases, the diagnosis was confirmed by operation or necropsy. Of the cases in which the sex is given, there were fifty-one males and thirty-two females.

Splenectomy, partial splenectomy or enucleation of the growth was performed in thirty-nine cases. Seven, or 17.9 per cent., died from shock, hemorrhage or other operative complications. Of the thirty-two cases that were followed by recovery, eleven, or 34.3 per cent., later showed evidence of metastasis, local recurrence or extension, at periods varying from five weeks to nine years. Twenty-one patients, or 65.7 per cent. of those who recovered, were well and without evidence of recurrence or metastasis at the time the cases were reported. This, however, does not represent the final outcome in many of these cases; for many were reported before sufficient time had elapsed to count them as cured. Many of these patients were operated on after the disease was well advanced. In other cases, operation was performed at a period when the technic of splenectomy was not so well standardized nor employed so frequently as it now is. Under present conditions, especially if the diagnosis is made earlier, the direct operative mortality may be no higher than the mortality for splenectomy in general.

In considering the possible etiologic factors it is interesting to note the incidence of malaria in these cases. Thirteen per cent. of the

---

100. Marcondas-Recende: Cancer of Spleen, Rev. de Brazil Med., p. 97, 1888.

101. Meuki: Tumor of Lumen of Spleen Blood Vessel, Tokyo Iji-Shinshi, p. 1425, 1906.

102. Ohaashi: Examination of Malignant Tumor of Spleen, Gun Igaku Kwai Zasshi, Tokyo, 1898.

103. Rochard: Tumor of Spleen, Weight 2,500 Grams, Bull. gen. de thérap., Paris, **154**:444, 1907.

104. Sangalli: Carcinoma of Spleen, Bel. della Soc. med. di Bologna, p. 437, 1864.

105. Goldstein: Primary Sarcoma of the Spleen, Am. J. Surg. **36**:57 (March) 1922.

patients had had malaria, and others, in whose cases a definite history was lacking, had lived in a malarial district. A coexistent tuberculosis was found in 2 per cent. There was a history of syphilis or a positive Wassermann reaction in 4 per cent., and a previous typhoid infection in a few instances. The spleen is known to harbor the organisms of malaria for a long time, and the resulting structural changes may favor neoplastic development. In 4 per cent. of reported cases, there is suggested a relation to trauma of the spleen. Carl Berens [12] called especial attention to this factor and drew his analogy from the number of sarcomas that, according to reports and opinions of some, develop elsewhere in the body following trauma.

The symptoms of malignant tumors of the spleen are: (1) rapid enlargement, with or without palpable, irregular nodules; (2) pain, peristent or intermittent, sometimes radiating over the abdomen, or back toward the scapulae; (3) tenderness on pressure over the spleen, and (4) cachexia and general symptoms accompanying malignant growths elsewhere.

In the differential diagnosis, malaria, syphilis, leukemia and splenic anemia must be ruled out. The presence of a hard, nodular spleen should demand exploratory operation at once. Unfortunately, the spleen may be adherent to the diaphragm and neighboring structures and not be palpable in the early stage of the disease; but the presence of pain, loss of weight and enlargement of the spleen to percussion may aid in the diagnosis. Pain is not always present, often appearing late or after the growth has invaded the peritoneum. The cachexia and general symptoms are usually as pronounced as in malignant disease elsewhere in the body. Secondary anemia is often marked, even in the early stages of the disease; but there is nothing characteristic in the blood picture.

In the foregoing cases with complete histories, pleural effusion in the left side of the chest was present in 16 per cent.; while ascites was mentioned in only 20 per cent. The pleural fluid was often bloody and often described as occurring in cases without evidence, even at necropsy, of metastases in the thoracic cavity. In the cases of Hauptman, Bush and Kendall, there was spontaneous rupture of the spleen. Rupture with peritonitis and death occurred in Prinzing's second case, following exploratory puncture of the spleen. Invasion of the stomach with fatal hemorrhage occurred in the case of Bridges and the first case of Prinzing. Jaundice and edema of the legs were found in a small number of cases. Fever and leukocytosis were inconstant findings.

SUMMARY AND CONCLUSIONS

1. We are able to find 104 reported cases of malignant disease of the spleen.

2. We report two cases of primary endothelioma of the spleen arising from the endothelial cells of the sinuses, which we believe is not an uncommon type of tumor of the spleen.

3. Lymphosarcoma is probably the most common type of tumor and is usually part of a generalized process which may appear simultaneously or later in other lymphoid tissues of the body.

4. Neoplasms of the spleen should be amenable to surgical treatment and exploratory laporotomy is justifiable in cases in which a well founded suspicion exists as to their presence.

TWENTY-FIRST REPORT OF PROGRESS IN ORTHOPEDIC SURGERY *

ROBERT B. OSGOOD, M.D.; ROBERT SOUTTER, M.D.; HARRY C. LOW, M.D.; MURRAY S. DANFORTH, M.D.; C. HERMAN BUCHOLZ, M.D.; LLOYD T. BROWN, M.D.; PHILIP D. WILSON, M.D., AND M. N. SMITH-PETERSEN, M.D.

BOSTON

CONGENITAL DEFORMITIES

Congenital Dislocation of the Hip.—Bradford,[1] in a comprehensive paper, has reviewed the history of the treatment of congenital dislocation of the hip. After a wide experience, he considers that the attempt at reduction should be made as early as is possible and before the actual locomotion of the child begins. Any treatment before this should consist of the employment of a traction splint, which in rare cases may accomplish reduction. Bradford advocates reduction by forcible manipulation, under an anesthetic, and he believes that the open method should be reserved for the cases in which this closed method has failed. In the older resistant cases, he advocates the use of the mechanical aids which fix the pelvis and, by use of traction and levers, give the surgeon's hands greater power, accurately applied. He emphasizes the importance of prolonged after-treatment.

[ED. NOTE.—Since plaster of Paris is the only entirely satisfactory method of retaining the reduced hips in place that has thus far been employed, it is difficult to provide for the after-care until the bladder and the bowels of the child have been somewhat trained. If, however, an efficient splint can be devised which can be kept clean, there is every reason apparently, in Dr. Bradford's opinion and in our own, for attempting reduction of congenital dislocation of the hip as soon as the diagnosis is made. The earlier the attempt is made, the better the chance of success. The diagnosis, it is fair to say, is rarely made until the child begins to walk. The splint devised by Dr. Wu and employed at the Children's Hospital in Boston nearly fulfils the requirements. We urge obstetricians and pediatricians to make a routine examination with a view to detect this deformity at birth.]

---

* This Report of Progress is based on a review of 560 articles selected from 618 titles dealing with orthopedic surgery, appearing in medical literature between October 21, 1922, and March 3, 1923. Only those papers which seem to represent progress have been selected for note and comment.

1. Bradford, E. H.: J. Bone & Joint Surg. **5**:76 (Jan.) 1923.

Clubfoot.—Bradford [2] is convinced that the chief deformity in congenital equinovarus occurs at the mediotarsal joint, and consists of a dislocation or subluxation of the scaphoid on the astragalus and the cuboid on the os calcis. If this subluxation can be corrected, the less important deformities, such as the twist of the os calcis and the faulty plane of the metatarsals, are comparatively easy to overcome. He believes that unless actual change in shape of the astragalus and the cuboid has taken place, the deformities may be overcome by patient, repeated forcible corrections.

[Ed. Note.—We agree as to the wisdom and success of this method of treatment. Almost any case can be thus corrected, by careful repeated manipulations and plaster retentions, or so nearly corrected as to require little in the way of bony or ligamentous resections or extensive tenotomies, which interfere with the growth, flexibility and power of the foot. Ober's procedure, properly executed, does not disturb growth, and, with careful after-treatment, should not greatly lessen flexibility. The architectural operation of Hoke on the astragalus, the astragaloscaphoid and calcaneoscaphoid articulations likewise should disturb growth very little, and, in an obstinate case or one in which prolonged after-treatment is impossible, should afford almost perfect early permanent correction at the expense of some perhaps unimportant flexibility. Tenotomies are potentially dangerous.]

Bankart [3] has been employing a method of fixation following correction of clubfoot which depends on the introduction of a strong silk ligament, prepared by Lange's technic, fastened at its lower end to the base of the fifth metatarsal and continued upward through a tunnel in a soft part to the inner side of the tibia, where it is passed through a drill hole. His preliminary correction is obtained by tenotomies of the anterior and posterior tibials, daily manipulation and retention in a metal splint; and, as a last step in the correction, a tenotomy of the Achilles tendon. The object in employing the silk ligament is to obviate long brace treatment. The ligament serves merely for retention.

[Ed. Note.—Our experience leads us to believe that these preliminary tenotomies are unnecessary and likely to leave a weakened musculature. Especially is this true of the tenotomy of the Achilles tendon. The elder Little, who had his own tendons cut by Stromeyer, and enthusiastically demonstrated his cure and popularized the method in England, came to feel, after his wide experience and long practice, that the method of tenotomy should be employed with great caution and that a muscle gradually and patiently stretched was capable of much more nearly perfect eventual function than one whose tendon

2. Bradford, E. H.: New York M. J. **117**:139 (Feb. 7) 1923.
3. Bankart, A. S. B.: Brit. M. J. **2**:1115 (Dec. 9) 1922.

had been divided. We also question whether, in the majority of cases, even a strong silk ligament can be depended on to stand the strain of weight bearing. Unless it can do this, it does not retain the correction. Certainly the experience of most orthopedic surgeons with silk ligament implantations has led them to abandon the method.]

TUBERCULOSIS

Heliotherapy.—Harris'[4] article, based upon a study of the results of heliotherapy in a series of forty-nine cases of surgical tuberculosis, should lead to employment of this method in northern climates even in the winter. Although there were many days in Toronto from October to May which were either too cold or too cloudy to make exposure possible, he found sufficient energy in the sunlight available to improve or cure many cases.

Roentgen-Ray Diagnosis of Tuberculosis of the Bones and Joints.—Walkey[5] considers that the diagnostic roentgenologic signs of bone and joint tuberculosis are: for the joints, (1) a uniform thinning of the cancellous tissue, (2) a well-defined condensation and broadening of the capsule, (3) destruction of cartilage or lessened thickness of cartilage and (4) lack of new bone formation; for the bone, (1) the presence of a local bone focus, usually in the epiphysis, with a circular outline, (2) failure of extension of the process along the shaft, (3) lack of new bone formation or regeneration and (4) tendency to extend to and involve the joint.

[Ed. Note.—While in a general way we agree with Walkey's diagnostic points, we are sure that it is unsafe to exclude tuberculosis as a possibility in the absence of these evidences or to make a positive diagnosis of tuberculosis if they are present. A thinning of the cancellous bone means disuse from whatever cause, as Allison and Brooks have shown (a later note). A thickened capsule may be present in gonorrhea, and in other lesions, destruction of cartilage; and a narrowing of the joint line is by no means peculiar to tuberculous arthritis. Nor is the absence of new bone formation. A local bone focus in the epiphysis, with a circular outline, is surely cause for suspicion, but is by no means commonly seen in tuberculosis. Lovett and Wolbach[6] have reported cases of proved tuberculosis in which the shaft involvement was considerable; and in which there was evident lime salt deposit beneath the periosteum, and extensive bone regenera-

4. Harris: Canadian M. A. J., November, 1922, p. 799.

5. Walkey, A. E.: Canadian M. A. J. **12**:728 (Oct.) 1922.

6. Lovett, R. W., and Wolbach, S. B.: Surg., Gynec. & Obstet. **31**:111 (Aug.) 1920.

tion. Cofield [7] has called attention to the extensive bony bridging often seen in cases of tuberculous spondylitis, occurring as a calcareous deposit in the anterior or lateral intervertebral ligament and appearing in the roentgenogram as hornlike protrusions springing from the diseased vertebral bodies and extending toward the one adjacent to it. Cofield suggests that this hypertrophic process may be the result of a blood-borne secondary infection; but, whatever its cause, new bone formation seen by the roentgen ray cannot be taken as evidence that a tuberculous infection is not present as the essential lesion.]

Tuberculous Spondylitis.—Girdlestone,[8] writing on the place of ankylosing operations in the treatment of Pott's disease (100 cases), considers the operation a logical and not a radical one. In young children, his experience leads him to believe, it is rarely needed and is less satisfactory. In adults, his results make him feel that it is reliable and of great value as a part of the conservative treatment of spinal caries.

Calvé and Galland,[9] on the basis of sixteen cases of their own and a study of others, conclude that the method has proved a failure in children and is not necessary in well-to-do adults who are not called on for violent efforts, and who are willing to wear apparatus. They insist on a prolonged use of jackets or braces after the ankylosing operation. This operation they consider of great value in women and laboring men. Their patients have worn celluloid jackets for two years.

Stefanow [10] has studied the distribution of pus in cold abscesses in vertebral caries, in twenty-three cadavers. A laminectomy or transversectomy was performed, and then holes were drilled through the vertebral bodies in sagittal or oblique directions. A mixture of flour, plaster and fluid of the consistency of pus was now injected through the drill holes under varying amounts of pressure. In the cervical region from 50 to 100 c.c. had no effect on the neighboring organs. Larger amounts pushed the esophagus or the pharynx and trachea to the right, the injected (abscess) material descending as far as the sixth dorsal and upward to the occiput. Injections in the dorsal region gave similar results, the mass following the aorta down to the hiatus. In the lower dorsal segments, abscesses would seem to follow the crura of the diaphragm, and in the lumbar region, the large vessels. Only when the pressure of the injected material was considerable, did the retroperitoneal fascia perforate and the abscess appear as a paranephritic

7. Cofield, R. B.: Bony Bridging in Tuberculosis of Spine, J. A. M. A. **79**:1391 (Oct. 21) 1922.

8. Girdlestone, G. R.: Brit. J. Surg. **10**:372 (Jan.) 1923.

9. Calvé, J., and Galland, M.: Jour. de Chir., December, 1922, p. 565.

10. Stefanow: Verhandl. d. Russ. Clin. Gesellsch., May, 1922.

abscess. Gravity apparently played a lesser rôle than has been supposed. The chief paths are those along the great vessels and the spaces between muscles and fasciae.

Tuberculosis of the Pelvis.—Aievoli [11] reviews the literature of tuberculosis of the bony pelvis, and quotes Valtancoli's figures from the Istituto Rizzoli. There were forty-nine cases of tuberculosis of the pelvis, as compared with 1,271 of the spine and 750 of the hip. Sacro-iliac joint tuberculosis is more common in males than in females, and between the ages of 20 and 30, abscesses are common. Tuberculosis of the pubic bone occurs in childhood most frequently. The author suggests that tuberculosis of the bony pelvis is often not recognized.

Tuberculosis of the Ankle Joint and the Tarsus in Children.—Fitz Simmons [12] has studied the end-results from operative and non-operative treatment of tuberculosis of the ankle joint and the tarsus in eighty-eight cases occurring in ten years (1910-1920) at the Children's Hospital in Boston. In the previous decade (1900-1910), there were 213 cases; an indication of decrease in surgical tuberculosis in this community which has been noted in other regions of the body. Forty-three of these eighty-eight cases were treated conservatively, by plaster fixation, and twenty-five end-results of these were observed. Two patients developed secondary foci, one in the elbow and one in the knee. The remainder were all well, and half of them recovered without deformity and with normal motion or very slight restriction. There were no deaths. Forty-five cases were treated by operative procedures, varying from opening of an abscess to excision of the tarsal bones. Twenty-seven of these were available for study. Three of these patients developed tuberculosis of the spine; one patient developed general tuberculosis; one died of tuberculous meningitis. Only three of those operated on had good motion. Twelve had slight deformity, three had marked deformity and ten still had discharging sinuses. From these data, Fitz Simmons feels justified in concluding that operative treatment in these cases is usually harmful. Time is not saved; deformity is not decreased; motion is not preserved. The operative cases which did best were those in which the procedure consisted of the opening of an abscess which was about to rupture. Heliotherapy Fitz Simmons considers an important aid.

Traumatic Tuberculosis.—Three German-Swiss articles have appeared, by von Meyenburg,[13] Zollinger [14] and Pometta [15] on the rela-

11. Aievoli, E.: Riforma med. **38**:705 (July 24) 1922.
12. Fitz Simmons, H. J.: Boston M. & S. J. **187**:838 (Dec. 7) 1922.
13. von Meyenburg, H.: Schweiz. med. Wchnschr. **52**:1093 (Nov. 9) 1922.
14. Zollinger, F.: Schweiz. med. Wchnschr. **52**:111 (Nov. 9) 1922.
15. Pometta: Schweiz. med. Wchnschr. **52**:1124 (Nov. 9) 1922.

tion of trauma to tuberculosis of the bones and joints. Von Meyenburg considers that injury rarely causes tuberculosis of the bones or joints, and that we must consider the possibility of a preexisting focus elsewhere before we admit any causal traumatic relationship. To establish this, he says that the injured person must be proved to have been free from tuberculous disease before the injury; and the injury itself must have been definite and of an appropriate nature, and have been received, in the case of spinal and pelvic tuberculosis, within a year, and in other joints, more recently. Pometta has found that most cases reported to the Swiss accident insurance institute as traumatic tuberculosis have been attributed to an event which could not really be considered a possible causal trauma. In other cases, the tuberculous disease was already present in the part when the accident occurred.

[Ed. Note.—These articles have a more or less important bearing on the question of industrial insurance and workmen's compensation acts.]

Subcutaneous Injection of Tuberculoprotein.—Toenniessen [16] has employed for diagnostic purposes an extract of tubercle bacilli, rich in protein, which he calls tuberculoprotein. In its chemical structure and in its biologic reaction, it is essentially different from the old tuberculin. It contains neither tuberculin acid nor tuberculothymin acid. Its advantages are its exact dosage, its perfect absorption, and the complete solution of the active substances which the human body does not have the power of extracting from the bodies of the tubercle bacilli. The tuberculoprotein is extracted in a perfectly soluble form and is free from the bodies of the bacilli. The reactions after subcutaneous injection are divided into negative and positive, and the latter into weak, medium and strong. In a negative reaction, there is at most only a slight reddening at the site of injection, but no infiltration or temperature rise. A weakly positive reaction consists of a marked reddening and infiltration, but no rise of temperature. It is seen in persons who may have no symptoms of tuberculosis, but have old quiescent foci. Medium reactions consist of the same local signs and a rise of temperature after the second but not after the first injection. This indicates a mildly active process. Strong reactions are those in which a rise of temperature occurs after the first injection. If there is a high fever, with little or no skin reaction, the prognosis is considered bad. The dosage in mild cases is 0.1 mg. In advanced lung tuberculosis, 0.01 mg. produces high fever and a focal reaction.

Friedrich [17] reports the experience of the surgical clinic at Erlangen with Toenniessen's tuberculoprotein. He considers the method safer

16. Toenniessen, E.: München. med. Wchnschr. **69**:957 (June 30) 1922.
17. Friedrich: München. med. Wchnschr., April 27, 1923, p. 528.

and surer than the old one. In twenty-four cases of well-marked tuberculosis, twenty-one presented a distinct skin reaction and a rise of temperature, but eight presented only a focal reaction. In fourteen cases of supposed tuberculosis, there was a skin and temperature reaction in all cases and a focal reaction in seven. In the third group of twenty-one doubtful cases, which were afterward found to be non-tuberculous, there were no focal reactions, but there was frequently a rise of temperature after repeated injections. In half of these, by careful investigation, old quiescent foci in the lungs or bronchial glands were discovered. Friedrich is working on a modification of the method, which he hopes will make the first injection conclusive.

SYPHILIS

Symmetrical Synovitis of the Knee in Congenital Syphilis (Clutton's Joints).—Lane [18] contributes a good review of the literature on this subject and emphasizes as important diagnostic features: 1. Insidious development. 2. Chronic course. 3. Symmetrical distribution. 4. Freedom from pain and the mobility of the joints to passive motion. 5. Association with other syphilitic stigmas. 6. Amenability to treatment. 7. The fact that in the roentgenogram, the bones appear unaffected, the patella is markedly floating, and the articular space is widened. The average age in Lane's cases was 15 years. The ultimate result was perfect recovery of the joints under antisyphilitic treatment.

Parrot's Disease.—Hallez [19] maintains that congenital syphilitic osteochrondritis of the epiphyses in the new bone may go on to suppuration. He asserts that it can be cured when recognized by pushing antisyphilic treatment.

Charcot's Spine.—Ridlon and Berkheiser,[20] reviewing ten cases seen by one of the writers in fifty years of practice, thus summarize their findings: 1. Spinal arthropathies may occur in any portion of the spine, but in their experience have been confined to the lumbar vertebrae. 2. They are commonest in males, only one case in a female being met in their experience. 3. The ages varied from 32 to 68. 4. The average number of years between the initial infection and the occurrence of the arthropathy was eighteen years. 5. The onset was insidious, and was sometimes accentuated by traumatism. 6. The bony changes consist of bone destruction, bone proliferation and displacement, usually laterally. New bone deposits are abundant, and in their cases have been apparently attached to the vertebrae. They have seen

18. Lane, J. E.: Am. J. Syphilis **6**:611 (Oct.) 1922.

19. Hallez, G. L.: Médecine **3**:852 (Aug.) 1922.

20. Ridlon, John, and Berkheiser, E. J.: Neuropathic Arthropathies—Charcot's Spine, J. A. M. A. **79**:1467 (Oct. 28) 1922.

none with bone plaques separated from the spine, such as are frequently seen in the knee, ankle and other joints. 7. None of their cases had local pain or tenderness or showed signs of stiffness other than mechanical, resulting from bone destruction and bone deposits. 8. Bone changes in the spine frequently appear before any ataxic symptoms develop, but they may appear coincidentally with or subsequent to the recognition of the ataxia. 9. Of their ten cases, only one presented neuropathic changes in other joints. 10. The pain, paresthesia and paralysis which appear in the lower extremities in some of these cases seem to be mechanical, from bone pressure on the nerves at their exits. In some instances, these symptoms may be relieved by stretching the spine and correcting the deformity as far as possible, maintaining the correction by a corset or jacket.

RICKETS AND ALLIED DISORDERS

Distribution of Phosphorus and Calcium in Rats on Rachitic and Anti-Rachitic Diets.—McCann and Barnett,[21] who have conducted experiments as to the calcium-phosphorus balance, have reached the following conclusions: 1. Rachitic rats have less phosphorus and calcium per hundred grams of body weight than normal rats. 2. This reduction is the same whether the rickets has been produced by a diet poor in phosphorus and rich in calcium or by one poor in calcium and rich in phosphorus. 3. In rachitic rats, the bones may contain a smaller percentage of the total phosphorus than is found in normal rats. This difference is not marked except when fair growth has occurred. 4. When the rickets is prevented from developing in rats given a diet poor in phosphorus but rich in calcium by the administration of cod liver oil or by exposure to sun light, the total phosphorus content per hundred grams of body weight is well within the normal range. The writers say that the foregoing points are of interest in that they tend to support the view that the two types of rickets have more in common than the somewhat diverse anatomic pictures might indicate. Moreover, the fact that identical abnormal bone composition can be produced by two diets having opposite calcium and phosphorus values would seem to indicate that this abnormal mineral content of the bones is not the result of a simple deficiency of one or the other element, but that some intermediary mechanism must come into play.

Etiology of Rickets.—It is interesting to find still widely divergent views as to the probable etiology of rickets, as evidenced by two recent British articles. Mellanby,[22] in discussing the question, upholds the

21. McCann, G. F., and Barnett, M.: J. Biol. Chem. **54**:203 (Oct.) 1922.
22. Mellanby, E.: Brit. M. J. **2**:849 (Nov. 4) 1922.

dietetic view. He says that rickets is a disease accompanying growth and is due primarily to defective feeding. A rickets-producing diet is one of unbalanced nature, in that it contains too little of those food stuffs responsible for the calcification of bone and too much of those substances responsible for the growth of the tissue, these latter substances being either neutral or antagonistic to the deposition of calcium phosphate in the growing bony matrix. With the assumption that the diet contains a sufficiency of calcium and phosphorus in a form that can be absorbed from the alimentary canal, the most potent influence for procuring the calcification of bone that Mellanby has observed up to the present is something in the nature of a vitamin, having a distribution and properties somewhat similar to fat soluble A. On the other hand, food stuffs responsible for growth and the laying on of tissue which are indifferent or antagonistic to calcification include the cereals. Generally speaking, therefore, rickets is a disease which follows the ingestion of diets relatively poor in antirachitic vitamin and rich in growth-producing elements, more particularly cereals. The complication which has made this hypothesis of the etiology of rickets difficult to grasp is the new conception that the various essential factors of a diet are so interdependent that the many dietetic problems must be considered from the point of view of balance and that it is no longer possible to speak of "excess" or "deficiency" of substances in an absolute way. For instance, the amount of fat soluble vitamin which may be sufficient in one diet becomes a relative deficiency when more cereal is eaten, or the calcium in any one diet may be adequate, but will become inadequate if the fat (butter) be greatly increased. In general, the minimum of any substance is a variable, dependent on the other factors of the diet eaten. The new dietetics, which insists on the importance of quality as well as quantity, must also find a way of expressing the fact that the value of a diet depends on the relative amounts of its essential constituents and not on absolute amounts. The author suggests that the following statements will cover most of the conditions in which diet and sunlight interact. 1. When a child is well fed, the presence or absence of sunlight makes no difference to its health so far as rickets is concerned. 2. In the case of a child fed on mediocre, border-line diet, exposure of the skin to sunlight will probably prevent rickets. 3. In the case of badly fed children, that is, when diets contain much cereal and a deficiency of fat soluble vitamin and calcium, sunlight will not prevent rickets, but may ameliorate the symptoms to some extent. Mellanby considers exercise, as well as sunlight, as of secondary importance to diet in the etiology of rickets.

Findlay [23] upholds the virus theory, pointing out that the influence of diet on rickets is very different from its influence on known

23. Findlay, L.: Brit. M. J. **2**:846 (Nov. 4) 1922.

deficiency diseases, such as beri-beri and scurvy. Rickets, he thinks, is always associated with confinement, and he suggests that the want of fresh air, lack of exercise, absence of sunlight, overcrowding, and bad hygiene in general, may favor the development of some virus. He believes that only by supposing the presence of some virus can we explain the geographic and social distribution and the age and seasonable incidence of the disease. He urges more earnest investigation along these lines.

Significance of Clinical Roentgenographic and Chemical Examinations in the Diagnosis and Incidence of Rickets.—Hess and Unger [24] have made investigations on a group of about 250 babies less than 18 months old, cared for in a model home with a central diet kitchen. The children were almost all Jewish. The observations were all made by one man. They consider that with our broader conception of rickets, the diagnosis has become increasingly difficult. Of the immediate clinical signs, they consider the beading of the ribs as the most reliable. The disadvantage of this sign is that it does not help one to differentiate between the active and the inactive stage of the disease. The authors think that roentgenoscopy of the epiphyses has proved disappointing. It does not always enable one to differentiate between lesions at a time when the diagnosis is uncertain. A negative roentgenogram, therefore, has little value in early rickets. It is a most valuable sign, however, in determining whether rickets is healing and whether the therapeutic agent is of any value. The inorganic phosphate of the blood is generally diminished in rickets in the early stages long before the roentgen ray gives evidence of the disorder, and frequently as early as, or earlier than, the beading of the ribs. It is not, however, pathognomonic, as there are other factors leading to a diminution of the inorganic phosphates, and rickets is occasionally encountered when the blood analysis is normal in this respect. A group of well-nourished, breast-fed infants examined clinically and by roentgen ray at the end of March showed rickets in more than 5 per cent. of the cases. Rickets is not only more prevalent in winter, but its incidence increases month by month until April. It is far more frequent in March and April than in December and January. The authors maintain that, if the incidence is studied at its flood, nearly all bottle-fed infants will show some indication of rickets.

The Pelves of Rickety Children as the Precursors of the Rickety Flat Pelves of Women.—Ashby [25] has measured the pelvis in a large series of normal and rickety children, performing the usual obstetric measurements in an effort to determine whether he can find in children

24. Hess, A. F., and Unger, L. J.: Infantile Rickets, Am. J. Dis. Child. **24**: 327 (Oct.) 1922.

25. Ashby, H. T.: Brit. M. J. 2:905 (Nov. 11) 1922.

the precursor of the adult female rachitic pelvis, which so often causes difficulty during labor. When the two series of measurements were compared, some marked differences became apparent, the most marked being the relative smallness of the external conjugate in rickets. This difference becomes more marked as the children grow older. The diminution of the external conjugate is the marked feature of the rickety flat pelves of women. The author concludes that the cause is rickets, and that the sacrum is bent and displaced forward by the body weight, the promontory being carried nearer the symphysis.

Osteomalacia.—White [26] discusses the literature of this disease. It would seem that in inefficient diet lies, if not the cause of osteomalacia, at least a very potent factor in its production. These points are considered: The disturbance of the calcium and phosphorus metabolism may be due (*a*) to a lack of the alkaline salts in the diet (famine osteomalacia); (*b*) to a drain from the alkaline storage of the body, associated with a deficient diet, as in cases of osteomalacia of pregnancy and lactation; (*c*) to the combined action of a diet faulty in more than its salt content, which by the production of acid in its oxidation and by favoring the development of acid forming bacteria causes a drain of the body alkali for the neutralization of this acid; or (*d*), and this is the more probable, especially in the severe form, to the combination of all these factors acting on the ductless glands and through them altering definitely the inorganic metabolism. 2. In severe osteomalacia the power to retain and absorb calcium and phosphorus is practically lost, while in the cases developing during famine and in pregnancy and lactation this power is retained. These subjects immediately recover when calcium and phosphorus are presented in usable form. This permanent loss of power to absorb or retain calcium and phosphorus can be explained only by some definite changes in the endocrine balance. 3. It is an important fact also that, while this disease is common among Cebidae monkeys, it has never been found among our macaques. This may be due to the fact that, owing to the storage sacs in the mouths of macaques, more food proportionally to the body weight is consumed; and to a probable essential difference in the basal metabolism of these families and individuals. All the factors enumerated do tax the metabolic resources of the body and depress the functions of the endocrine glands. Detailed and accurate quantitative studies of normal metabolism and the effect of the foregoing factors on the ductless glands will give a more definite answer to the problem. The starting point of treatment must be a diet adequate in vitamins and containing a proper inorganic balance.

---

26. White, E. P. C.: Osteitis Deformans in Monkeys, Arch. Int. Med. **30**:790 (Dec.) 1922.

Osteitis Deformans in Monkeys.—White [27] studied carefully three monkeys which developed Paget's disease as it has been described in man, both clinically and pathologically, because the animals showed the same general type of inorganic metabolism that was exhibited in man; because of the alkali hunger that was shown by one of the monkeys and by two human cases, a hunger which was severe and which preceded the deformity and disappeared after the deformity was established, and because the disease developed in animals fed on a diet insufficient in its organic and vitamin content, to which an excess of calcium was added. From this study, it seems possible that Paget's disease may be just one stage in a deficiency disease. It may be a reparative response (1) through a disordered neurotrophic mechanism; (2) through the perversion of the calcium governing glands which have been disordered by an improperly balanced diet; or (3) through the addition of an excess of calcium to the diet of an animal whose body fluids were unable, through previous faulty diet or other disorders, to hold it in solution.

Osteitis Deformans (Paget's Disease).—Jack [28] reports a case which, clinically and roentgenologically, was Paget's disease, with marked bony changes involving the skull, femora, tibia and pelvis. In spite of a negative Wassermann reaction, rapid improvement followed six intravenous injections of neo-arsphenamin. The author reviews the pathology of the disease, pointing out the vascular lesions which resemble those of syphilis. Lannelongue, in 1903, considered Paget's disease a manifestation of hereditary syphilis in the aged. Several other cases have been reported in which improvement followed antisyphilitic treatment.

Osteofragilis; Marmorknochen; Albers-Schönberg Disease.—Davis [29] reports an unusual case of the bone disease first described by Albers-Schönberg. Nine other cases have been reported, but no others in this country. The literature is reviewed. Albers-Schönberg, besides calling attention to the marble-like changes seen in the roentgenograms of the bones, noted the characteristic appearance of parallel bands of lime salt deposit in the diaphyses of the bones of the hands and feet, the fibula and the ribs. The etiology of the condition is unknown. Examination of the skull revealed a peculiarity in the region of the sella turcica, the posterior clinoid process consisting of a club-shaped solid bony prominence, which apparently indented the region of the sella. The crista galli showed the same changes. The general picture

27. White, E. P. C.: Osteomalacia, Arch. Int. Med. **30**:620 (Nov.) 1922.
28. Jack, C. M.: Am. J. Roentgenol. **9**:626 (Oct.) 1922.
29. Davis, G. G.: Osteosclerosis Fragilis Generalisata; Marmorknochen; Albers-Schönberg Disease, Arch. Surg. **5**:449 (Nov.) 1922.

suggested an unusually pronounced calcification of the whole skeleton. The patient sought advice for a fractured femur, and two other fractures were discovered, the origin of which was unknown to him.

Congenital Osteosclerosis.—Ghormley [30] reports a case of what was considered congenital osteosclerosis, and reviews the literature. His own case was that of a boy of 8 years, who came to the clinic on account of pain in the left hip, and lameness. The case was thought to be a beginning separation of the upper epiphysis of the femur, until the roentgen ray revealed a curious density of the bones of the hip; whereupon, a general roentgen-ray study of the entire skeleton was made, which showed much the same condition throughout the bones. Besides the curious density of the flat bones and the rather hazy outline along all of the bones, the vertebral bodies showed a marked density at either pole. There was thickening of the cortex of the ribs, the marrow cavity being in places obliterated. There was also thickening of the cortex of all the long bones, and the density was greater in the proximal than in the distal portion. The skull was thicker than normal. On the femoral necks, especially in the left, there seemed to be a breaking down of the bone just below the epiphysis, so that the latter had slipped inward and downward. The laboratory tests were all negative except that the blood phosphorus was a little high. Roentgenograms of the mother and father showed the mother's bones to be normal, but practically the same condition existed in the father as in the child. No dietary discrepancies could be found, and the Wassermann tests were negative. A search of the literature has failed to locate any cases similar to this in the living person. There are, however, several cases described at necropsy as osteosclerosis, some as congenital and others associated with disturbance of the blood forming organs. Frangenheim has collected three necropsy reports of congenital osteosclerosis. Two were in infants with a normal blood picture; a third was in a child of 10 weeks who died of acute myelocythemia. The two other infants showed an enlarged thymus. Assmann has collected in addition four cases in adults who died at ages ranging from 17 to 68 years. Two died of leukemia and the others of primary anemia. Newerck and Moritz report one case with similar bone changes. Schwarz reports a case of leukemia with osteosclerosis. Heuck in necropsies on two cases of leukemia found marked thickening of the diaphysis of the femora and the humeri, as well as the vertebrae and skulls. The majority of the authors take the view that the sclerosis is secondary to an irritation which goes with the morbid process in the blood. All of these were necropsy reports, and roentgen-

30. Ghormley, R. K.: Bull. Johns Hopkins Hosp. **33**:444 (Dec.) 1922.

ray findings were not available; but Ghormley takes the view that the conclusions would have been similar to those in his case, although this one seems to have been an inherited condition. In his case, there was a daily afternoon rise of temperature to 100 F., but no cause was found. Operation was refused. A plaster spica was applied, with relief of the pain and limp.

POLIOMYELITIS

Loeffler,[31] in five cases of persistent outward rotation of the leg following poliomyelitis, has devised an operation which has been successful up to six months following the operation. He hopes that the favorable position will continue to be maintained. A longitudinal incision is made slightly in front of the great trochanter, and the fascia lata is split in the same direction. The border of the split fascia facing the trochanter is pulled backward strongly, while the leg is held in marked inward rotation. The more anteriorly the fascia is split, the greater is the correcting tendency. This edge of fascia is sutured into a flap lifted by an osteotome from the trochanter, and a plaster is applied.

Transplantation of the Tensor Fascia Femoris in Cases of Weakened Gluteus Medius.—Legg[32] has devised an operation designed to overcome or at least lessen the ungainly limp associated with a gluteus medius paralysis. He divides the insertion of the tensor fascia femoris into the fascia lata and transplants it into the posterolateral cortex of the femur, lifting a bone flap and suturing the periosteum, over the new insertion. The tensor fascia femoris must be well developed, and there must be a fair gluteus maximus in order to derive marked benefit from the operation.

[Ed. Note.—We have observed some of the cases in which Legg has operated, and we believe that he has made a real contribution to the surgery of infantile paralysis. In well selected cases, the improvement in gait has been quite remarkable.]

Report of the Commission Appointed by the American Orthopedic Association for the Study of Stabilizing Operations on the Foot.—The problem presented this year to the commission (Cook, Stern and Ryerson[33]) on stabilization of paralytic feet, was "What is the best method of treating the drop-foot?" By this is meant the foot which has no power of dorsiflexion, and to which no such power can be supplied by tendon transplantation, and furthermore in which no tendency

31. Loeffler: Zentralbl. f. Chir., Nov. 18, 1922, p. 1715.

32. Legg, A. T.: Transplantation of Tensor Fasciae Femoris in Cases of Weakened Gluteus Mediums, J. A. M. A. **80**:242 (Jan. 27) 1923.

33. Cook, Stern, and Ryerson: J. Bone & Joint Surg., January, 1923, p. 135.

to lateral deviation or deformity exists. Several different methods of alleviating the condition have been considered in this study: 1. Arthrodesis of the ankle joint by excision or by graft. 2. Silk ligament suspension. 3. Gallie's, Putti's and Codivilla's methods of suspending the foot by fastening the tibialis anticus and peroneus tertius to the tibia. 4. The suspension of the foot by strips of fascia lata or the fascia of the leg. 5. The diamond-shaped excision of skin or bone flap from the front of the ankle and tarsus. 6. Astragalectomy. 7. The use of braces or elastic bands. The first two operations have fallen into disfavor and are apparently rarely performed in this country. The commission feels that there is a distinct field for the third type of operation, tenodesis, and would have liked to see many more cases in which operation had been performed years ago. It is believed that strong strips of fascia lata could be successfully employed in the way that they have been used in reconstruction of the lateral ligaments of the knees; but it is felt that sufficient time has not yet elapsed to demonstrate the permanence of the fascia lata. The excision of diamond-shaped pieces of skin or a skin-bone flap made from the front of the ankle joint, the incision being sutured so as to hold up the foot, is of temporary benefit only, since the remaining skin soon stretches and allows the foot again to drop, or the bone fractures and then the skin stretches. Astragalectomy has a distinctly beneficial effect in drop-foot, especially when the foot is entirely flail. A few cases have been examined in which free motion subsequently developed in the mediotarsal and anterior joints, but the results as a rule have been sufficiently good to warrant its use in selected cases. It will be seen, therefore, that the commission does not feel convinced that any of the operative methods here considered can be confidently recommended as a standard procedure. They consider that the lateral deformities of paralytic feet are far more disabling than drop-foot, and that they require operation in a far higher percentage of cases than does simple drop-foot. It was found that several types of drop-foot braces were cheerfully and comfortably worn by both children and adults; whereas, braces used to control the other varieties of foot deformities are not well tolerated. The plain elastic straps fastened to the shoe, the spring-wire supports with a coil at the sides of the heel and the flat spring bent to fit under the sole and up the back of the leg are all useful and agreeable. The commission urges that tendon transplantation be almost universally supplemented by stabilization of enough of the smaller joints of the foot to prevent or correct all tendency to varus or valgus deformity, since, as has been said, the examination of a large number of post-operative cases has shown that the lateral deformities are of much greater importance than drop-foot.

SCOLIOSIS

The Roentgen Ray in the Diagnosis of Scoliosis.—Lamb[34] reports an interesting and, if verified, an important method of recognizing the early stages of structural or fixed scoliosis. He reviews the pathology of the condition, showing that the greatest difficulty exists in the differentiation of fixed and functional curves in the beginning. A patient with a fixed type of deformity may be able to pull himself into an apparently straight position either standing or lying, and the presence of deformity cannot be demonstrated either by employment of roentgen rays or by marking the alinement of the spinous processes on the skin. On the other hand, a person with a normal spine may assume a scoliotic position when standing or lying that may be very misleading. Only when fixed rotation of an extreme type has developed can the condition be definitely recognized by the usual method; and, at this stage, correction is obtained with great difficulty. Photographs and roentgenograms are presented of a model with a normal spine, standing in what he calls the normal scoliotic position. In this position, the body is slightly tilted to the side and rotated forward; the shoulder on the side of the curve is elevated, and the head is brought back into the median line. He shows, however, that, with the normal spine, the individual can assume a symmetrical or analogous scoliotic position in either direction; while a patient with a fixed type of scoliosis, even though a very early one, cannot. To differentiate the conditions it is, therefore, only necessary to have the patient assume these scoliotic positions, first in the one, and then in the other, direction; and on roentgenologic examination, the difference between the fixed and functional types of deformity is at once apparent. The roentgenograms are made with the patient in the standing position, and Lamb uses a special frame with dowel markers, to ensure the patient assuming as nearly as possible symmetrical positions. He presents illustrative photographs and roentgenograms.

Corrective and Operative Treatment of Idiopathic Structural Scoliosis.—Whitman[35] considers the problem of the treatment of scoliosis and emphasizes its difficulties. He suggests the following plan: When a border-line case of scoliosis is first seen, a photograph, roentgenogram and tracing of the spine should be taken, and exercises instituted. If the patient grows worse, she passes into a second class, and should receive exercises plus support. If this is not sufficient, and the curve increases, corrective treatment by means of jacket is indicated. Most cases improve under this treatment, and then relapse the moment the support is discontinued. Such patients must be held in the corrected

34. Lamb, F. W.: Am. J. Roentgenol. **9**:723 (Nov.) 1922.
35. Whitman, A.: New York State J. Med. **22**:449 (Oct.) 1922.

position for years, while accommodative changes in the spine take place. It is in this connection that operative treatment seems useful. He assumes that the primary curve is in the dorsal spine, at least in the patients he has operated on. This assumption is based on the fact that the dorsal curve was the first thing noticed by the patient and is the first evidence on physical and roentgen-ray examination. His procedure is as follows: The patient is treated by corrective jackets until the maximum amount of improvement is obtained, usually for over a year. If the patient chooses operation in preference to prolonged fixation by means of jackets or braces, she enters the hospital and is placed on the convex stretcher frame. When she is accustomed to the frame, the operation of spinal fusion is performed on the primary curve. She is replaced on the frame, where she remains for two months. During the second month, she is turned on the face daily. A short plaster jacket is then applied, and is worn for two months. This is then replaced by an ordinary corset, and exercises are instituted for the weakened lumbar muscles. Whitman has operated in fifteen cases of this type since July, 1920. Eleven patients have been either entirely without support or wearing nothing but an ordinary corset for periods of from four months to seventeen months. The apparent outcome in these cases is not yet reported as end-results, but there has been thus far no progression of the deformity, and the patients are all satisfied with their condition. There have been no deaths or infections.

In the discussion, Mackenzie Forbes supported the idea of operative treatment in cases of progressive deformity and in those with correctable deformity. Sayre stressed preventive treatment and questioned the advisability of operation. Fitch emphasized the part played by anatomic variations in the fifth lumbar vertebra in producing scoliosis. Sever was against operation, and questioned the statement that the dorsal was the primary curve.

[Ed. Note.—We find ourselves in essential agreement with this plan of treatment of structural "idiopathic" scoliosis which Whitman outlines, but unfortunately we often have referred to us a case which has had no effective treatment and is in so advanced a stage that little can be expected from forcible jacket correction. The extent of the curve also would seem to demand so extensive an operation that, in these usually debilitated persons, it is always a question of surgical risk. Moreover, the poliomyelitis cases are in our opinion the ones in which decision for or against operation must most often be made. These patients are usually young children with growth problems ahead. Dr. Hibbs has recently reported with great candor the results of his early cases of several years' standing. To us, the photographs of many showed no betterment. Some of them appeared to us a little worse so far as the curvature was concerned; but a few seemed better, and the

great majority were in better nutrition, and what had been a progressive curve had remained stationary without retentive apparatus. We believe that, at least in selected cases, most of which will be, not of the so-called idiopathic structural type, but of the progressive crippling poliomyelitic type, spinal ankylosing operations will stand the test of time and be looked on as preventive if not corrective, and as conservative to general health and activity.]

ARTHRITIS

Etiology and Treatment.—Fletcher [36] in 150 unselected cases of chronic arthritis has studied the effect of dietetic treatment alone. All these patients were kept in bed for two weeks, and after the disease seemed reasonably stationary, a routine was established. The diet consisted of three glasses of milk, three of buttermilk, one or two oranges and a half a grape fruit daily for one week. The amount of food was gradually increased by the addition of vegetables and fruits containing less than 15 per cent. of carbohydrates, eggs, fish, fowl, meat, soups, junkets and jellies, and finally a small amount of brown bread. This made up a daily intake of from 1,500 to 2,000 calories. Patients who were under weight were given in addition cod liver oil and cream. The bowel movements were made free by enemas on alternate days when necessary, and in a few cases liquid paraffin was given. No other form of treatment was administered for four weeks. Fletcher is convinced from his observation that dietetic treatment plays an important rôle in the therapy of the disease. Women seem to respond to dietetic treatment more favorably than men.

Relationship Between the Iliocecal Coil and Chronic Arthritis.—Smith,[37] after a roentgenologic study of 100 cases of arthritis and a study of the findings in sixty abdominal operations, is convinced that there is, in these cases, an intestinal focus of infection, associated with an intestinal abnormality which disturbs the function of the ascending colon. The cecum is usually of the congenitally mobile type, caught back to the side wall of the abdomen in nature's attempt to anchor the ptotic organ. He has found a reduplication of the peritoneum, beginning at the right colic artery, and extending to the parietal peritoneum over the right kidney. There is a kink in the colon, causing an hour-glass appearance, the cecum being thin and toneless. Thus, the function of the colon is disturbed and the cecum becomes a sac filled with excellent culture mediums for streptococci, which overmaster the other bacteria and become a focus of infection, causing arthritis. By removing the ascending colon in good surgical risks, and by simply

36. Fletcher, A. A.: Canadian M. A. J. **12**:633 (Sept.) 1922.
37. Smith: Editorial, Surg., Gynec. & Obst., December, 1922.

dividing the constricting band at its junction with the parietal peritoneum in debilitated persons, covering denuded surfaces with omental grafts, Smith has noted remarkable improvement in arthritis. He says that, after the division of this band, the colon rolls out, regains its normal color and contracts to mechanical stimulation.

[Ed. Note.—The two preceding articles of Fletcher and Smith are suggestive bits of evidence that, in the treatment of chronic arthritis of Type 1 at least, whatever else we may do in the way of eradicating possible foci of infection (teeth, tonsils, etc.), we should never fail to pay closest attention to the intestinal tract. By careful diet along the lines laid down by Pemberton, and now by Fletcher; and by persistent effort by cathartics and enemas and abdominal massage, by postural treatment and perhaps by operation, to evacuate the large intestine, we shall probably accomplish more in ameliorating this distressing disease than by any other single method of attack. Cure is not too optimistic a word to apply to the results in many of these cases thus treated.]

Synovectomy in Chronic Infectious Arthritis.—Swett[38] thus describes his operative procedure in eight cases of chronic infectious arthritis. In the last of his reported series (fifteen operations), the patient was operated on two years ago. He has carefully followed his cases. The joints were opened over the site of greatest thickening, and all the redundant diseased synovial membrane was dissected out with scissors and forceps, down to what seemed healthy tissue. The joints were then closed without drainage and were not fixed. No disastrous complications followed, and there was little local or general reaction. One case was not improved, and in one other the improvement was slight. In six of the eight cases there was marked improvement in the function of the joints operated on, and pronounced general constitutional improvement as well. There was some apparent amelioration of the condition in other joints. Swett does not expect improvement to follow this procedure when there is extensive cartilaginous involvement; nor does he consider that it takes the place of other forms of treatment.

[Ed. Note.—So far as we are aware, no one knows definitely whether or not synovial membrane has the power of regeneration. Synovial membrane wounds assuredly form smooth and painless scars, as we have learned from the less radical removal of villi from within the knee joints. In these cases of proliferative arthritis, the mass of synovial tissue often presents mechanical obstruction to free and painless movement; and Fayerweather and others have demonstrated that these joint villi often contain bacteria and may, therefore, represent foci of infection even when the joint fluids are sterile to culture and on

38. Swett, P. P.: J. Bone & Joint Surg. **5**:110 (Jan.) 1923.

cytologic examination. In the type of cases described by Swett, the operation may well have a place in the local and perhaps the general treatment of chronic infectious arthritis.]

OSTEOMYELITIS

Acute Osteomyelitis in Children.—Willis and Willis[39] thus summarize their views on acute osteomyelitis in children: 1. The treatment of the disease is wholly surgical, though supportive medical treatment may be required. 2. The earlier the operation, the better the outlook for life and limb. 3. The essential object of surgical treatment is prompt and efficient drainage of the medullary cavity. 4. Too often there are errors in diagnosis, delay in treatment and insufficient operative procedures. 5. The most important diagnostic indications are (*a*) pain, neither superficial nor often, at the beginning, sharply localized, but of a deep and burning character, increased by continued pressure over the infected area; (*b*) loss of function in the affected part; (*c*) marked rise in temperature and in white blood count. 4. The roentgen ray is of little or no value in the early stages and may be misleading. The authors consider the prognosis always grave for life and limb.

[Ed. Note.—We disagree with the statement that the essential object of surgical treatment of acute osteomyelitis in children is prompt and efficient drainage of the medullary cavity. Homans' review of a large series of cases of acute osteomyelitis at the Children's Hospital in Boston many years ago, and Starr's wide experience at the Sick Children's Hospital in Toronto seem to show conclusively that, in the vast majority of cases, the infection starts in the cancellous tissue of the metaphysis near the ends of the long bones, and not in the medullary cavity. Early drainage of the medullary cavity would, therefore, be likely not only to prove an inefficient surgical procedure, but also actually to cause infection of the cavity, which may never be involved if the cancellous tissue near the epiphyseal line is promptly and adequately drained. A recent case illustrates this point well. In a child of 10, with high temperature, prostration, acute pain in the left lower leg, and slight heat and edema over the upper tibia, most marked at the junction of the upper and middle thirds, where was also the most marked tenderness, a diagnosis of acute osteomyelitis of the medullary cavity was made, and the shaft was drilled over this area. No pus was found, and the cultures from the medullary cavity were sterile. The child had a slight drop in temperature, followed by a still sharper rise to 105 F., and a second operation, two days after the first, at which

39. Willis, J. C., and Willis, J. C., Jr.: New Orleans M. & S. J. **75**:337 (Jan.) 1923.

the metaphysis was explored, released a large quantity of pus, which had by this time extended to the upper medullary cavity and was exuding slightly through the upper drill hole, which two days before had been sterile to culture. Most of the recent work on osteomyelitis of Bancroft and Speed and others has shown that, in acute osteomyelitis in children, one may easily be too radical in operating. Operative procedures in the active stage should be instituted as soon as the clinical diagnosis can be made, and should consist simply of providing adequate drainage for the infected area of bone. This area in children, we believe, in the vast majority of cases, is located near the end of the bone above or below the true medullary cavity. In a doubtful case, this should be explored first, and we believe it will rarely be necessary, in an early case, to open the medullary cavity. At this stage, no definite operation is possible, since we cannot determine macroscopically the exact extent of the bone which is devitalized beyond repair. Our experience and that of others leads us to believe that, in children, we generally underestimate the regenerative power of bone.]

Osteomyelitis Due to Colon Bacillus.—Winslow [40] reports a case of suppurative osteomyelitis of bone due to the colon bacillus. There was a sudden onset, intense pain and fever, and the subsequent development of an abscess, which ruptured spontaneously two months later. At a subsequent incision to provide more adequate drainage, a pure culture of colon bacillus was obtained. Winslow states that only six cases have been previously reported, the femur being involved in this total series of seven cases three times; the costal cartilages, three times, and the tibia, once.

Charbonnel [41] also reports a lesion of the tibia occurring in an otherwise healthy man of 45, evident two months after apparent recovery from dysentery. The lesion healed after incision; but four years later, a large abscess developed, from which the colon bacillus alone could be cultivated.

The Use of Large Reverdin Grafts in the Healing of Chronic Osteomyelitis.—Reid [42] reviews the various methods that have been advocated for the purpose of filling or obliterating large bone cavities following operations for osteomyelitis. The standard methods are useful in the case of deep lying bones or in the shaft of superficial bones, but they are difficult to apply when the cavity is in the end of the bone; and in different circumstances. He reports several cases of chronic osteomyelitis with large bone cavities which it was impossible to close and which he grafted by the Reverdin method after preliminary

40. Winslow, N.: Ann. Surg. **76**:695 (Dec.) 1922.
41. Charbonnel: Rev. de chir. **60**:345, 1922.
42. Reid, M. R.: Bull. Johns Hopkins Hosp. **33**:386 (Nov.) 1922.

treatment of the cavity by the Carrel-Dakin method. Prompt healing followed. He has subsequently used the method in other cases, with uniformly good results. If the surface has been chemically sterilized, the grafts take almost invariably, and it has been possible to cure long-standing cases of osteomyelitis in a few weeks' time. Study of some of the cases in which plaster molds of the healed bone cavity were made from time to time have shown that these cavities decrease in size, and nature tries to eliminate the defect.

NEOPLASMS

Vascular Tumors of the Knee Capsule.—Haas [43] records two cases of hemangioma of the knee joint. In the first case, a man of 30 years had been treated for an intermittent painful swelling which had been diagnosed as tuberculosis, and immobilized. At the age of 23, he came under Haas' observation with hydrops and limitation of motion, accompanied by a grating sensation, but no palpable tumor. At operation, the joint was found filled with angiomatous masses covering the synovial membrane. The cartilage and bone were, so far as could be determined, unaffected. Removal of these masses relieved the symptoms for two years, but they recurred. The joint was explored again seven years after the first operation because of intolerable pain. At this time, recurrence of the angiomas was found, with accompanying erosion of the capsule and bone, and a resection was performed. The second case was in a woman of 20, who at birth had shown a few small red tumors beneath the left knee. These tumors grew slowly. At 5 years, one was excised, but promptly recurred. At 22 years, the knee was opened because of symptoms (presumably like those of Case 1), and the tumor was found to have perforated the capsule and eroded the bone. The differential diagnosis from tuberculosis, Haas thinks, may be difficult, but may perhaps be possible by the sign of Gangolphe and Saberaut. This sign is a marked difference in the circumference of the knee in the suspended and dependent positions.

Metastasis to the Lungs from a Pure Myxoma.—Bloodgood [44] reports a case of pure myxoma of the astragalus which he considered malignant, as one of a series of cases, in December, 1920. The patient is now complaining of pain in the chest and elbow, and the roentgenograms show shadows in the lungs which are presumably metastatic tumors. Another patient of his series died ten years after the first operation, with evidence of metastasis in the lung and scalp. There would seem to be fairly definite evidence, therefore, that this type of tumor is malignant. Although there has been some discussion among

43. Haas, Alfred: Deutsch. Ztschr. f. Chir. **173**:130 (Aug.) 1922.
44. Bloodgood, J. C.: Ann. Surg. **77**:106 (Jan.) 1923.

the group of consulting pathologists to the Registry of Bone Sarcoma as to whether a true pure myxoma of bone exists, Bloodgood's studies convinced him that it does exist, and that it has a distinct gross and microscopic appearance. When the tumor is opened, a viscid gelatinous material resembling tapioca exudes under pressure. The frozen sections are more characteristic than the sections made after long hardening, as the intercellular substance is probably expressed as the tissue hardens. A tumor of this sort should be explored, with proper precaution to prevent transplantation of tissue, by the use of the electric cautery and chemical cauterization with pure phenol, followed by alcohol and a 50 per cent. solution of zinc chlorid.

Carcinoma of the Bone Marrow.—Piney,[45] after a study of the histology of normal bone marrow and the development of blood-forming tissue, is led to the conclusion that metastatic deposits in bone are due to arterial or capillary embolism. The evidence that leads him to this conclusion is the detection of cancer cells in the vascular channels of the bone marrow, these channels containing red corpuscles in addition to the epithelial cells. Moreover, there is evidence that the bone marrow contains no lymphatic channels.

A Brief Summary of the Salient Features in the Diagnosis and Treatment of Bone Lesions.—Bloodgood[46] endeavors to state briefly the salient facts gathered from more than 1,000 records of bone lesions. This includes only those cases of tuberculous and pyogenic osteomyelitis which may resemble clinically, and by roentgen ray, a possible periosteal or central malignant lesion. Roentgenograms should be made of the corresponding bones as well as of the affected bone immediately after trauma to the bones and joints. This is now being done more often than formerly, and many preexisting bony lesions are being found. In the majority of cases, they are partially or completely healed bone cysts or healed tuberculosis. When a single bone lesion is found, the entire skeleton should be examined by roentgen ray. Demonstration of multiple central lesions practically excludes central sarcoma, and the diagnosis rests between metastatic carcinoma, multiple myeloma, multiple bone cysts and chondroma. When a distinctly periosteal type of multiple lesion is found, malignancy is practically excluded. Multiple exostoses are not malignant. Roentgenograms of the lungs should be made as a matter of routine in bone lesions. Evident pulmonary metastasis has been found frequently before the development of clinical symptoms. Demonstration of pulmonary tuberculosis probably means that the bone lesion is also tuberculous. A spindle-shaped periosteal growth surrounding the bone may indicate

45. Piney, A.: Brit. J. Surg. **10**:235 (Oct.) 1922.
46. Bloodgood, J. C.: Am. J. Roentgenol. **10**:42 (Jan.) 1923.

an infectious ossifying periostitis. The demonstration of a tumor in the soft parts, either by palpation or by roentgen ray, indicates periosteal involvement, irrespective of whether the appearance of the bone indicates a central lesion or not. The roentgenographic appearance of calcified areas in the soft parts separated by a clear area from the bone is evidence of tuberculosis and against sarcoma. In every case in which there is a lesion of bone, there should be a Wassermann test; a complete blood examination; an examination of the urine for Bence-Jones bodies, and a search for foci of infection in the tonsils, nasopharynx, teeth and genito-urinary tract. When the roentgenogram reveals an evident periosteal lesion and the Wassermann reaction is negative, a dose of arsphenamin should be given as a therapeutic test. Bloodgood had four cases in which the cure which followed this treatment was the only means of eliminating sarcoma. A central lesion with definite bony shell and no extra-osseous soft part lesions in a patient under 15 years of age is not sarcoma or a malignant tumor, but probably a bone cyst. The next possibility is a giant-cell tumor; rarely a chondroma, and very rarely tuberculosis. Immediate operation is not necessary, and one may watch and wait. If ossification does not start immediately, especially following a pathologic fracture, operation should be performed. If the patient is over 15, there is possibility of sarcoma, and nothing is to be gained by delay. The order of frequency of central bone lesions after this age is: (1) giant cell tumor, (2) bone cyst, (3) sarcoma, (4) chondroma, (5) myeloma. Bloodgood's method of attacking central bone lesions is as follows: The tumor should be explored, every precaution being taken to avoid implantation of cells into the soft parts. Under an Esmarch bandage, the bone is exposed and the shell is opened with the electric cautery. If there is any question of the tumor's not being benign, it should be curetted with the hot iron. Bloodgood swabs the cavity with pure phenol and alcohol, and packs it with gauze saturated with 50 per cent. zinc chlorid. If the evidence is in favor of sarcoma, he advises implanting radium in the cavity, following this with roentgen-ray or radium therapy. The wound may be kept open or closed, according to its size. Bloodgood's personal experience with immediate bone transplantation into large cavities is unfavorable. He knows of only one case of proved central sarcoma in which the patient is alive and well five years or more after amputation. As to periosteal bone lesions, only two permanent cures of periosteal sarcoma following amputation are on record. On the other hand, recent experience shows that the number of benign periosteal lesions resembling, clinically and roentgenologically, periosteal sarcoma is increasing. These are: ossifying periostitis; infections, traumatic, syphilitis or tuberculous; exostoses, and some rare examples of osteomyelitis. In view of the fact that cure is so infrequent, amputation should be performed only when other

means have failed. Arsphenamin and roentgen-ray and radium treatment should first be tried. If good effects are to follow employment of radium or roentgen ray, they should appear in two weeks.

PERIPHERAL NERVES

Resuture of Peripheral Nerves.—Stopford [47] has analyzed fourteen cases of resuture of peripheral nerves, seven of the ulnar, five of the two; median nerve, fifteen; brachial plexus, seven; external popliteal The end-result was followed in all but one case. The purpose of his analysis was to arrive at some basis on which advice could be given as to whether an attempt should be made to resuture peripheral nerves in those cases in which no benefit had been derived from the initial operation for resuture. Under favorable conditions, regeneration can occur. The end-results are similar to those seen after a successful secondary suture, and the causes of failure seem to be the same: a disturbance of intraneural anatomy; the effect on the cells in the anterior horn and the posterior ganglions of a third injury to the nerve fibers, and the intraneural fibrosis. Resuture would seem to be contraindicated when extensive intraneural fibrosis had been encountered at the first operation and when three years or more had elapsed since the initial injury to the nerve.

Peripheral Nerve Injuries Associated with Fractures.—Lewis and Miller [48] contribute a noteworthy article on this subject. Their own experience covered twenty-nine cases, and in addition they found 210 cases reported in the literature. Of these 253 fractures, the majority were simple and the nerve injury was not due to the direct action of the violence producing the fracture. The location of the fractures associated most frequently with the nerve injuries was as follows: humerus, 210; bones of forearm, twenty-four; femur, five; bones of leg, five. The various nerves injured were: musculospiral, 136; ulnar nerve, sixty-two; median nerve, fifteen; brachial plexus, seven; external popliteal nerve, eight; median and ulnar nerves combined, two; radial and ulnar nerves combined, one; radial, median and ulnar nerves combined, one; sacral plexus, one; anterior crural nerve, one; sciatic nerve, one; anterior tibial nerve, one; musculocutaneous nerve of leg, one. The various nerve injuries may also be subdivided into the primary and secondary groups. In the primary group, the nerve symptoms appear at the time of the original trauma; while, in the secondary, the symptoms develop later and may come on very slowly. Of the 239 cases analyzed, onset of paralysis was primary in sixty cases (25.1 per cent.); secondary in ninety-nine (41.4 per cent.); late, in fifty-two (21.7 per cent.), and not

47. Stopford, J. S. B.: Brit. J. Surg. **10**:216 (Oct.) 1922.
48. Lewis, D., and Miller, E. M.: Ann. Surg. **76**:528 (Oct.) 1922.

recorded in twenty-eight. Of sixty cases of primary paralysis, the operation of neurolysis was performed in thirty-six, and end-to-end suture of the divided nerve in twelve, resection of the humerus being necessary in five of these twelve cases in order to allow the nerve to be approximated. Of ninety-nine patients having secondary paralysis, eighty-three were operated on and sixteen were not. In thirty-four, the nerve was found caught over the end of the displaced fragment; in thirty-one, the nerve was imbedded in scar and callus; in seven, the nerve was interposed between bone fragments, and in seven, the nerve was imbedded in a bony tunnel. Pseudo-arthrosis was present in six; the nerve was anatomically divided in three, and a bone splinter was found lodged within the nerve in one. Neurolysis was performed in seventy-four; end-to-end suture in eight. As far as end results are concerned, of the sixteen patients not operated on, six completely recovered; one partially recovered, and the result was not recorded in nine. Of the eighty-three patients operated on, fifty-seven were operated on within six months, and of these forty-six recovered completely; eight recovered partially, and one was unimproved. The remaining patients were operated on at periods varying from six months to three and one-half years after injury, and of these, four partially recovered; three were unimproved, and the result was not recorded in one. By far the greater majority of the late paralyses were associated with fractures of the lower end of the humerus, a paralysis of the ulnar nerve developing years after the injury, when the nerve became traumatized by stretching, either as the result of a cubitus valgus, or because of the development of bony outgrowths. Other points to be noted are that 36 per cent. of the muscolospiral injuries were associated with fractures of the middle third of the humerus, while 32 per cent. were associated with fractures in the lower third. Ninety per cent. of the ulnar nerve injuries were fractures of the lower third of the humerus, as were also 75 per cent. of the median nerve injuries. The following conclusions are drawn: 1. Nerve injuries are associated with fractures much more frequently than is supposed. They are frequently overlooked because of the hasty and incomplete examination of fractures. When fractures are examined, the possibility of a nerve injury should always be kept in mind. 2. The character of the injury varies greatly, from the slightest contusion, from which the patient rapidly recovers, to anatomic division and callus inclusion, which demand surgical interferences. 3. It is often impossible to differentiate by the most careful neurologic examination between physiologic interruption of the nerve current and anatomic division of the nerve. 4. There is a tendency in these cases to wait too long for spontaneous recovery. 5. When recovery has not begun within three months after the injury, the injured nerve should be explored and the surgical procedure demanded by the pathologic

findings be instituted. 6. Neurolysis is the operation which will be most frequently required. Resection of the humerus should no longer be performed in order to permit of end-to-end suture of the musculospiral nerve. Tendon transplantation should be performed in these cases. 7. The prognosis is very favorable in injuries of this type, because of the frequency with which the musculospiral nerve is injured and because of the relative infrequency with which it is divided, only neurolysis being necessary. 8. In the late ulnar nerve palsies, transposition of the nerve to the front of the elbow will be necessary in the cases of cubitus valgus. When bony outgrowths cause the paralysis, removal of such outgrowths and the placing of the nerve in a healthy bed may be all that is required.

The Surgical Treatment of Chronic Sciatica.—Taylor [49] believes that chronic sciatic pain is not simply a neuritis, but often a perineuritis as well, or the latter alone, with adhesions binding the nerve to surrounding tissues. Taylor adds eight cases to the four he has already reported, making ninety-nine cases which have been treated by operation reported in the literature. In most of Taylor's cases, the pain has been in the left leg. He quotes Renton's classification of sciatic pain. 1. Patients who are quite free from pain at rest, but suffer intense pain on exercise or the assumption of a certain position. 2. Patients who have some pain at rest, but, like Class 1, suffer more on exercise or in certain positions. 3. Patients with pain of an indefinite character, present intermittently at rest and sometimes improving on exercise. In the first class, the inflammation has subsided, but adhesions have developed and cause a drag on the nerve. This type Taylor considers most favorable for operation. In the second type, there is probably some actual inflammatory process in the nerve itself, and many of them may be benefited by operation. The pathology in the third type is not clear and operation offers little chance of benefit. The operation which Taylor performed is exposure of the nerve from just below the gluteal fold distally, as far as there is any tenderness. The nerve is gently raised and stretched and any adhesions are carefully dissected away. The wound is closed without closure of the fascia. The patient is kept in bed for three weeks without apparatus, then is allowed to be up by degrees, and he leaves the hospital four weeks after the operation. All his patients have made rapid and uneventful surgical recoveries, and, as with the eighty-nine cases of Renton of Scotland and Pers of Copenhagen, relief has been almost universal and permanent for many years.

Heile [50] has found surgical intervention also successful in certain cases of rebellious sciatica. His findings have included pressure from

49. Taylor, W. G.: New York M. J. **116**:693 (Dec. 20) 1922.
50. Heile: Deutsch. Ztschr. f. Chir. **174**:10 (Sept.) 1922.

a network of abnormal veins about the nerve and intraneural adhesions, and in one case a separation of the nerve fibers to allow the passage of the pyriformis muscle. He has employed intraneural injections to separate the nerve fibers and has slit the nerve sheath in order to release the nerve from pressure. While acute and chronic conditions of the epineurium may be responsible for the pain, at operation it should be preserved by delicately lifting it and dividing the adhesions between the single nerve cables. The anastomoses between the nerve cables must not be disturbed.

[Ed. Note.—We have had no experience with exploration of the sciatic nerve for the relief of chronic sciatic pain. We have been impressed with the fact that relief of sciatic pain is so often possible through a better understanding of the numerous pathologic conditions which occur about the lumbosacral and sacro-iliac joints. These observations of Taylor and Heile are, however, most suggestive, and since there should be little risk in these exploratory operations in obstinate and obscure cases, we are inclined to believe they might well be undertaken in selected cases of the type which Taylor describes.]

BODY MECHANICS

Orthostatic Albuminuria.—Post and Thomas [51] consider, under this name, the condition variously described as intermittent, cyclic, postural, variable and adolescent albuminuria. The essential sign is the absence of albumin in the urine excreted while the patient is lying down and its subsequent presence in the urine at times after rising. Evidence confirms the important rôle which lordosis plays, but proves that it is by no means the sole factor. This variable appearance of albumin is not an entity, but the result of two or more causes, none of which alone is capable of producing the condition. The cause must be attributed to a stasis of the renal circulation as well as a stasis in other parts of the body, producing analogous results in body tissues and in the blood stream itself. Observations in about forty cases indicate that the appearance of variable amounts of nucleo-albumin and serum albumin in the urine is analogous to changes which take place in the blood and body tissues. It is accompanied generally in certain types of young, rapidly growing undernourished individuals, whose vasomotor mechanism is unstable and who are subject to frequent or chronic infections, by a pulse pressure which is smaller in the upright than in the lying position. It seems to presage no progressive renal disease. Repeated and accurate functional tests and blood chemistry studies have revealed

51. Post, W. E., and Thomas, W. A.: Orthostatic Albuminuria, J. A. M. A. **80**:293 (Feb. 3) 1923.

neither constant deviations from the normal nor constant variations between the findings in the upright and in the horizontal positions.

Blanton [52] reports a case of this type, in which the albumin persisted for three weeks, even while the patient was in bed. The amount, however, was greatly reduced by rest and support of the back, changing from 2 to 0.3 gm. The patient had marked general vasomotor disturbances as well.

Peacock,[53] after a study of 200 cases of orthostatic albuminuria from the Veterans' Bureau, reaches the following conclusions: 1. Many cases of orthostatic albuminuria are due to sagging kidneys, which is not the case in the albuminuria of nephritis. 2. Many of these cases occur in athletes; those who are subjected to physical strain, as in lifting, or those giving a very clear history of injury. 3. A single urinalysis is never sufficient, as many patients will not show albumin in the morning specimen, but it will appear after the patient has been up and around all day. 4. Pyelograms should be taken in the recumbent and sitting positions, as the ptosis will often be missed otherwise. 5. Those patients submitted to nephropexy showed marked general improvement, and in many cases there was a disappearance of the albuminuria. This change has been noted also after the patient has worn a binder. 6. A definite chain of lesions may be associated with sagging kidneys; namely, kinks of the ureters, dilation of the renal pelvis, hydronephrosis, stone, obstruction of the ureter and pyonephrosis. Pyelitis and sagging kidneys go hand in hand. The writer suggests a special method of nephropexy which he says, in carefully selected patients, those with good abdominal walls and healthy muscle tissue, is very successful. He does not advise it in those with relaxed fascias and a general ptosis.

Results of Exercise for the Correction of Postural Defects.—From the results of his work at Yale, Cook [54] says that the defects of posture found among young men do not tend to disappear without corrective work, but that they can be overcome by such work, some, owing to the nature and severity of the defect, requiring a longer period than others. Since these defects are formed long before the student enters college, it is certain that much could be accomplished in the way of prevention, or in the way of correction, if suitable supervision were given the children of the grade and high schools and the preparatory schools. The question is often raised as to whether this correction is permanent or temporary. Cook examined in the fall those men who were given correctional work the preceding year, and in these cases he was gratified to find that the improvement continued.

---

52. Blanton, W. B.: Am. J. M. Sc. **164**:742 (Nov.) 1922.
53. Peacock, A. H.: Northwest Med. **21**:393 (Nov.) 1922.
54. Cook, R. J.: New York M. J. **117**:155 (Feb. 7) 1923.

BONE AND JOINT SURGERY

Traumatic Ossifying Myositis.—Bull [55] has met four cases of this condition. In three, sarcoma was suspected. The history and the roentgenologic examination become, therefore, of great importance. In the roentgenogram, the shadow of the involved area is, in the early stages, ill-defined, of uneven density and separated from the bone. As the case progresses the shadow becomes more distinct and more dense, and approaches the bone. Three of his reported cases were explored, and the microscopic examination proved the diagnosis to be correct.

Sprain of the Rhomboideus Minor Muscle.—Replogle [56] has made a study of 150 cases of injury to the shoulder girdle. Investigating the causes of this injury, such as swinging a sledge, firing a furnace, lifting a heavy object or sudden pulling with arms extended, Replogle found that pain occurs at the end of the pitch of a shovel or at the end of a swing of a sledge; in other words, at the position where the lateral angle of the scapula is raised and the rhomboideus minor is on the greatest tension. Clinically, pain is produced only on those movements which elevate the lateral angle of the scapula, change the angle of the spine, and depress the base of the spine of the scapula, producing tension on the rhomboid muscles. Occasionally, there is slight pain and tenderness near the spinous process of the last cervical vertebra at the origin of the rhomboideus minor, and in 30 per cent. of the cases there was slight tenderness along the vertebral border of the scapula below the spine in the region of the rhomboideus major. The treatment is based on anatomic lines, in an effort to cause relaxation of the overstretched muscle. The shoulders are thrown back so as to lessen the interscapular space, and crisscross adhesive straps are applied to maintain this position. The arm is placed in a sling, and a small pad is placed under the adhesive over the point of tenderness, to hasten, if possible, the absorption of the serous effusion at the point of the rupture or strain. The treatment gives immediate relief of the aching, and pain on abduction is greatly reduced. Replogle says that the frequency of occurrence of sprain of the rhomboideus minor, the unusual constant symptomatology and clinical picture and the efficacy of simple and proper treatment, together with the fact that it is of sufficient seriousness to cause industrial disability, demand accuracy in diagnosis of this lesion.

The Semilunar Cartilages of the Knee.—Roberts [57] is convinced that early active movement after removal of the semilunar cartilages of

55. Bull, P.: Norsk. Mag. f. Lægevidensk. **83**:992 (Dec.) 1922.
56. Replogle, J. P.: Ann. Surg. **76**:641 (Nov.) 1922.
57. Roberts, P. W.: New Approach to Semilunar Cartilages, J. A. M. A. **79**:1608 (Nov. 4) 1922.

the knee is of much advantage. He expects to obtain right angle flexion in six days after operation, and practically complete joint function in two weeks. He has employed a new method of approach, the purpose of which is to allow flexion of the knee without strain on the skin wound. His incision is in the form of a U, about 1 inch (2.5 cm) wide and 1½ inches (3.7 cm.) long, just at the side of the patellar tendon. The skin and fascial flap is turned upward, and at its base the joint line and the cartilage are exposed. The latter is seized with forceps and dissected out.

[Ed. Note.—For a simple, transversely torn cartilage, this incision would be adequate and the approach neat; but, on careful search, we find so many types of injury to the cartilages which require different operative procedures for satisfactory correction that we still believe the vertical lateral incision, continued backward just below the joint line for a short distance, is the best incision for the average case. It allows for any necessary extension in either direction, and if the wound is closed accurately in layers, we have encountered no weakening of the scar or interference with early movement. With the principle of early active movement and quick resumption of function, we are in agreement.]

Phemister [58] reports two cases of cysts of the external semilunar cartilage of the knee, which he says are the first to be reported in this country. He adds them to twelve other reported cases in other countries. The treatment consists in operative removal of the cyst and the external semilunar. In two of four cases in which only the cyst was removed, a second operation was necessary for removal of the cartilage. The pathologic findings are identical with those found in the ganglions of the wrist. They are most common in adults, from 16 to 55. Trauma seems to have some part, but is less important than in the ganglions of the wrist. The cysts seem to attain their maximum size within a few weeks, after which they remain stationary and continue to produce pain and a variable amount of interference with motion in the joint, until removed. There is no recorded case of spontaneous disappearance either of the symptoms or of the swelling.

Endoscopy of the Knee Joint.—Bircher,[59] for the purpose of determining the nature of the knee lesion and the extent of accompanying arthritic changes in the joint, has made use of a method which he calls arthro-endoscopy. The joint is filled with oxygen or nitrogen gas, and a laparoscope, consisting of a trocar and cystoscope, is introduced into the joint, with aseptic precautions. He states that it is thus possible

58. Phemister, D. B.: Cysts of the Semilunar Cartilage of the Knee, J. A. M. A. **80**:593 (March 3) 1923.

59. Bircher: Beitr. z. klin. Chir. **127**:239, 1922.

to obtain a clear view of a large portion of the joint. He firmly believes that the method will be considered in time a routine method in many cases of injury or disease of the knee.

Injuries to the Crucial Ligaments and Avulsion of the Tibial Spine.—Painter [60] reports four cases of severe knee joint injury, in three of which the crucial ligaments were torn and in one of which there was a fracture of the spine of the tibia. He considers the two lesions as alternative forms of the same injury. Two of the cases of torn ligament were treated by open operation, the midpatellar incision being used. One patient was operated on two years after injury, and the other underwent operation two weeks after the accident. In the former, the anterior ligament alone was damaged; in the latter, both ligaments were involved. In neither was it possible to approximate and suture the torn ends with any prospect of good repair. Both, however, finally had very satisfactory joints, following immobilization for several months. Another case of torn anterior crucial ligament was first seen three months after injury, and, following the prolonged use of a cage splint, this patient also obtained a good result. The case of fractured tibial spine was seen immediately after injury, and under anesthesia was manipulated into complete extension. Immobilization was maintained for six weeks, with a good result. Painter gives a complete abstract of all the literature and shows that the consensus of opinion, based on both clinical and experimental work, is that these injuries are produced either by violence of such a nature as to crush down all anatomic structures or by a momentary lapse in the synchronous protective activity of the supporting musculature, chiefly when force is applied in such a way (abduction) as to rupture the internal lateral ligament, which constitutes the external defense of the crucial ligaments. From his own experience, Painter is convinced that there is no need of elaborate operative procedures and that with conservative treatment alone and thorough fixation, good results may usually be expected.

Hallux Valgus.—Roberts [61] considers that the fundamental causes of the postoperative recurrence of the deformity are the distorting line of pull of the tendon of the extensor hallucis muscle and an alteration in the plane of the articular surfaces of the bones which form the great toe joint. Correction of either the abnormal line of tendon pull or of the plane of the articular surface alone is not sufficient when there is a marked deformity. To overcome this after the removal of the exostoses, it has been his custom to sever the tendon of the extensor

60. Painter, C. F.: Boston M. & S. J. **187**:765 (Nov. 3) 1922.

61. Roberts, P. W.: Operation for Hallux Valgus, J. A. M. A. **80**:540 (Feb. 24) 1923.

hallucis a short distance above its insertion, and to dissect the tendon and its sheath free to a point somewhat above the head of the first metatarsal. Both structures are then displaced, mesially, and the slightly macerated end of the tendon is implanted in a shallow channel on the medial side of the base of the first phalanx, covered with periosteum and other fibrous tissue and firmly sutured in this position. Thus, the line of pull is established inside the center of motion of the joint. In very mild cases, this change of tendon insertion may be all that is required to prevent a recurrence of the outward deviation of the toe. In more marked cases, a wedge of bone is excised from the base of the first phalanx. In his experience, this procedure has proved more satisfactory than reshaping the head of the metatarsal, both from an operative and from a functional point of view.

Osteochondritis Dissecans.—Roesner [62] is still convinced that the traumatic theory of the etiology of this condition is the correct one. The tibial spines vary much in size in different individuals. Experiments on the cadaver have demonstrated that forced extension of the knee, while the lower leg is held in outward rotation, produces lesions of the cartilage of the inner condyle of the femur from the impact of the spine of the tibia. This is the seat of the typical lesion in osteochondritis dissecans.

Hellström [63] also holds to the theory of a traumatic etiology, but he believes the injury to the cartilage is caused in most cases by the forcing of the patella against the condyles. The trauma may not be violent, but repeated and slight. In Hellström's five cases, the disease was not limited to the inner condyle, and it has been known to occur in the elbow joint, the shoulder joint and the head of the second metatarsal bone.

Freiberg,[64] on the other hand, thinks that the evidence upholds Axhausen's theory of an infarction, commenting on the symptoms and pathology in several cases. The roentgen-ray appearance in these cases would seem to be very characteristic and significant. The invariable situation on the internal condyle of the femur, the separation of the bone, leaving a niche in the condyle always of the same general shape and varying only in size (the phenomenon pointed out by Ludloff), all point to some peculiarity of the local circulation as the fundamental factor. The process seems almost inevitably akin to that of infarction as we see it in the kidney. In the knee, Ludloff calls attention to an artery, the arteria genu media, which ramifies over the posterior crucial

62. Roesner: Beitr. z. klin. Chir. **127**:537, 1922.
63. Hellström, J.: Acta. chir. Scandinav. **55**:190 (Sept. 19) 1922.
64. Freiberg, A. H.: J. Bone & Joint Surg. **5**:3 (Jan.) 1923.

ligament and the internal condyle of the femur. This artery is frequently a terminal vessel, and its blocking could easily explain the occurrence of such a circumscribed necrotic process as that with which we are at present concerned. Ludloff believed that, by simultaneous hyperextension and inward rotation of the joint, this vessel would be susceptible to damage by internal trauma. For the present, at least, it seems that we must look on this interesting condition as the result of trauma, perhaps, but only as an indirect result. The rarity of the lesion is probably to be explained by the necessary concomitance of the several elements: (*a*) the existence at this point of terminal arterioles; (*b*) a long tubercle of the tibial spine, and (*c*) internal trauma, occurring in a position of hyperextension and outward rotation of the tibia on the femur. Arthrotomy with the removal of all loose bodies is our only resource. There is no evidence that further formation of loose bodies ever occurs if the original ones have been removed. This will be most certain if the diagnosis is established early; that is, before the bodies have wandered from the niche in the condyle. We have here another argument for the need of the roentgen ray in every joint lesion of subacute or chronic character; only thus can identification be made before locking has occurred or a loose body has been felt at a point distant from its bed. Experience has shown that, for quite a time, loose bodies are attached by a pedicle. Thus, early operation may be simple and consist of a short incision, as for a loose meniscus. Once the loose bodies have wandered, the procedure will have to be adapted to the circumstances.

Arthroplasty of the Elbow.—Campbell[65] considers that only two main groups of cases are suitable for arthroplastic attempts: (1) those in which ankylosis follows a traumatism, with crushing of joint surfaces, and (2) those which are the result of acute localized infectious arthritis. He has devised and carried out in several cases a new technic for the arthroplasty of the elbow. An external lateral incision is made, and an aponeurotic flap is dissected from the posterior aspect of the triceps, with its base attached to the olecranon. The ankylosed joint is exposed and the articular surfaces are remodeled. The triceps muscle is divided longitudinally and made into two flaps, which are sewn to the anterior capsule over the raw surface of the humerus. The aponeurotic flap is now sewed back to the triceps, and the skin is closed. The author begins gentle passive motion in three weeks. In the case of a young woman with a right angle ankylosis of 19 years' duration, following an acute infection, the result of this operation was full extension and flexion to beyond a right angle. A second case was

65. Campbell, W. C.: Ann. Surg. **76**:615 (Nov.) 1922.

that of a man of 50, who had suffered a trauma, followed by bony ankylosis. The result in this case was 50 per cent. of normal motion in six months.

Kalima[66] describes two types of elbows on which arthroplastic operations had been performed one month and one year previously, the patients having died from intercurrent disease. Earlier investigations (Sumita) have shown that, in the arthroplastic joint, during the early stages, a mucous bag or follicle (Schleimbeutelbildung) is formed. This is brought about by degenerative changes which predominate within the transplanted structures, until, later on, the constructive processes prevail and decide the final characteristics of the joint. Both patients were operated on in such a way that the artificially shaped joint surface of the humerus was covered with a fat-fascia transplant, with the fatty layer turned out toward the joint surface of the ulna. In addition, the head of the radius was resected and a separate fat transplant was placed between the radius and the ulna. In the first case (of one month's duration), marked degenerative changes were seen in the center of the fat layer, so that a cavity was formed; the periphery of the fat layer had already been transformed into cellular connective tissue, and organized union between the transplant and the bone ends could be seen everywhere. In the second case (of one year's duration), there was a different structure. The ends of the bones were covered with a thick layer of whitish, firm tissue; a good joint cavity existed; the joint surfaces consisted of firm, fibrous connective tissue; no metaplasia of cartilage was seen, and the inner surface of the capsule had become differentiated into a synovial membrane with numerous villi. The new joint, besides its functional mechanical attributes, was characterized by having all the components of a normal joint.

Arthrodesis of the Shoulder.—Schulz[67] proposes a new technic for arthrodesis of the shoulder. The incision is made along the spine of the scapula, carried over the acromioclavicular joint and continued distally over the shoulder for 6 cm. The joint is opened and the head dislocated. The glenoid and the head are denuded of cartilage and a portion of the acromion process from which the periosteum has been removed is forced downward into a socket prepared for it in the head of the humerus by making two parallel saw cuts and chiseling out the base. As the portion of the acromion is fitted into this mortise, the denuded head is held in contact with the glenoid. The advantages which Schulz claims for the method are that (1) the apposed denuded surfaces are considerably greater than by other methods; (2) the

66. Kalima: Resti arst. **1**:258, Nos. 5-6, 1922.
67. Schulz: Rozhledy v. Chir. u. Gynaek. **2**:15, 1 H., 1922.

musculature of the shoulder girdle is absolutely preserved, and (3) the trapezius becomes attached not only to the acromion but to the humerus as well. The operator can determine the extent of abduction, elevation, and rotation which the procedure will furnish, by the depth and position of the cut into the head of the humerus.

Method of Treatment of Irreducible Acquired or Congenital Hip Dislocations.—The operation proposed and carried out by Lorenz [68] consists of an osteotomy of the femur in an oblique direction, the osteotome entering the bone well below the lesser trochanter on the anterolateral aspect, and being driven upward and backward, emerging at a level corresponding to the upper lip of the acetabulum. After a complete separation has been accomplished the limb is abducted, and the lower fragment is pushed inward and upward until it lies securely in the empty acetabulum on the capsular wall. The lower end of the upper fragment is forced inward to form an angle with the upper end of the lower fragment in its new position. With the limb abducted, this position becomes quite stable, and no retentive sutures or internal fixation of the fragments are used. A long plaster spica in 35 degrees of abduction is applied, and the patient is allowed to be out of bed and to walk on crutches in two weeks. A short spica is substituted in two months, and, at the end of the third month, massage and gymnastic exercises are begun. Lorenz believes that the applicability of the operation, which he calls the bifurcation operation, is manifold.

Ashley [69] comments on the bifurcation operation and publishes four postoperative roentgenograms, with brief case reports.

Hahn [70] reports from Vulpius' clinic nine operations by this method of Lorenz and von Beyer. He says that lordosis was lessened by the operation; discomfort in sitting and standing was relieved, and gait and walking endurance improved. In five of the cases, the Trendelenberg sign disappeared.

[Ed. Note.—While this procedure may accomplish its object and bring about a greater stability, it seems to us a less strictly surgical procedure than a more complete restoration of normal conditions or an arthrodesis in the position of deformity. These more anatomic procedures are not impossible or unduly dangerous in the hands of experienced joint surgeons.]

Bone grafts.—Delagenière [71] continues to be enthusiastic over the results of the osteoperiosteal bone grafts, and describes the technic of

68. Lorenz, A.: New York M. J. **117**:130 (Feb. 7) 1923.
69. Ashley, D. D.: New York M. J. **117**:136 (Feb. 7) 1923.
70. Hahn: München. med. Wchnschr., Jan. 19, 1923, p. 82.
71. Delagenière: Bull. de l'Acad. de méd., Paris, Dec. 5, 1922, p. 396.

their application in cranioplasty, pseudarthrosis, etc., his experience comprising nearly 300 cases. He obtains his grafts from the medial aspect of the tibia.

Thomas [72] also is convinced that the osteoperiosteal graft has very wide fields of usefulness, especially in the treatment of old ununited fractures. The grafts are laid along the sides of the bone fragments or wrapped like a cuff about the seat of the pseudarthrosis.

Simon and Aron [73] have experimented with the long bones and joints removed from embryos of guinea-pigs from 6 weeks to 2 months old, transplanting them into other guinea-pigs, young and old. These implants finally broke down and were absorbed, but the authors were interested to find that the interval before this occurred was much longer with the embryo bones than with adult bone.

A New Bone Saw.—Langworthy [74] has devised a new type of motor saw which eliminates some of the difficulties encountered with the instruments now in use. It consists of a motor which is covered with a sterile bag from which passes off, at a right angle, a flat arm about 10 inches (25 cm.) long, which carries on the end the revolving saw. The mechanism of power transmission is not explained, but it is obviously possible to use the saw in a deep wound. The saw arm is held directly in the fingers like a pencil, and fine manipulations are possible. This ability to use the saw in a deep wound and the possibly more delicate and easy application of the saw itself would seem to be great advantages. The various parts and their attachments are extremely simple and strong, and the instrument is said to stand very hard service.

DISLOCATIONS

"Snapping Shoulder."—Kappis [75] thinks that the so-called voluntary dislocation of the shoulder is much more rare than the snapping shoulder, which is often mistaken for it. He has collected thirteen cases, in ten of which the snapping mechanism was in front; in two, behind, and in one, both in front and behind. In none of these cases was there any affection of the joint itself, not even a relaxation of the capsule. The snapping is caused generally by the head gliding beneath a contracted bundle of the deltoid. In another type of case, the snap is caused by a catching of the tuberosity in a gap between the short tendon of the biceps and the coracobrachialis. These conditions

72. Thomas, H. B.: Treatment of Old Ununited Fractures of Long Bones, J. A. M. A. **80**:309 (Feb. 3) 1923.

73. Simon, R., and Aron, M.: Arch. franco-belges de chir. **25**:869 (July) 1922.

74. Langworthy, M.: Surg. Gynec. & Obst. **35**:646 (Nov.) 1922.

75. Kappis: Arch. f. orthop. Chir. **20**:555, No. 4, 1922.

usually occur in young subjects, and disappear with age, no treatment being necessary. Kappis does not deny that habitual dislocation of the shoulder exists, but when it occurs it is always associated with very definite joint changes.

Forward Dislocation of Both Bones of the Forearm at the Elbow.—Cohn [76] reports one case and reviews the literature on the subject of uncomplicated forward dislocation of the elbow, finding a total of twenty-two other cases recorded. The injury is probably produced by a blow on the back of the flexed elbow in most instances and is accompanied by extensive laceration of the soft parts. Some of the cases have been reduced by closed methods with little difficulty, flexion of the elbow with traction downward on the forearm being the chief requisite. Cohn's case was a long standing one, of seven weeks' duration, and open reduction was necessary. A good functional result, with from 70 to 80 degrees of flexion and extension, was obtained at the end of a year.

Traumatic Dislocation of Hip Joint in Infancy.—Maffei [77] has made a study of forty-nine cases of traumatic dislocation of the hip in infancy, forty-six collected from the literature and three of his own. Traumatic dislocations of the femur, which are rare in adults, are exceedingly rare in children. The cause in children is usually a fall with the thigh flexed and adducted. The diagnosis is usually easily made from a manual and visual examination and from the roentgen-ray findings. The treatment depends on the duration of the dislocation. In some instances, it is necessary to perform an open operation. In the earlier cases, the dislocation can be reduced without operation. The prognosis, except in cases of long standing, is good.

Downward Dislocation of the Patella Reduced by Manipulation.—Aud [78] describes an unusual lesion in a boy of 17, who tried to board a fast going train and failed, being dragged along with his legs flexed under him. He had severe pain in the left knee and was unable to rise. On examination, the leg was in a position of almost complete extension, with inability to flex or extend. The knee was greatly swollen and very painful. The roentgen ray showed that the patella had been turned vertically through a right angle, the upper border being engaged between the femur and the tibia. There was no fracture of the patella, but the taut patellar tendon had partially torn loose the tubercle of the tibia. Under general anesthesia, the dislocation was readily reduced by manipulation. With the thigh over the right shoulder of the

76. Cohn, Isadore: Surg. Gynec. & Obst. **35**:776 (Dec.) 1922.

77. Maffei, F.: Chir. d. org. di movimento **6**:604 (Oct.) 1922.

78. Aud, Guy: Downward Dislocation of Patella, J. A. M. A. **78**:1457 (May 13) 1922; Kentucky M. J. **20**:690 (Oct.) 1922.

operator, the leg was forcibly flexed, and at the same time traction was made on the leg. The patella readily snapped into position. Passive motion was started in a week. Six weeks after injury, there was complete recovery, with no limitation of motion.

FRACTURES

Fracture of the Radius.—Sucha[79] divides fractures of the radius into four groups: (1) those above the insertion of the biceps; (2) those below the insertion of the biceps and above the insertion of the pronator radii teres; (3) those below the pronator radii teres and above the pronator quadratus, and (4) those below the pronator quadratus. The treatment in these groups must be based on a knowledge of the musculomechanics of the production and reduction of the deformities occurring in those fractures. In Group 1, since no motive ligaments or tendons, except a few fibers of the supinator brevis, are attached to the upper fragment and the biceps tends to misplace the lower fragment, the deformity is corrected by flexing the elbow and relaxing the biceps with a small pad, to hold forward the short fragment in alinement with the shaft. In the second group (below the insertion of the biceps and above the insertion of the pronator radii teres), the biceps pulls up the upper fragment and the supinator brevis supinates it, while the lower fragment is pulled in toward the ulna and rotated inward by the two pronators. Therefore, in order to reduce, one should first pronate, but not too far, because the upper fragment is supinated. This lets the radius away from the ulna and allows it to rotate back to its normal plane. Next, the elbow is flexed to aline the lower fragment with the upper, and the arm is dressed in moderate supination and flexion. In the third group (below the pronator radii teres and above the pronator quadratus, the biceps still plays a large part in the deformity of the proximal fragment. This fragment is also slightly pronated by the pronator radii teres. In order to reduce, the elbow is flexed to relax the biceps; pronation is done to relax the pronators; the hand is forcibly adducted to further throw the upper end of the lower fragment away from the ulna, and the arm is dressed in flexion of the elbow to a right angle, in pronation to the position of the palm facing the body and with the hand in extreme adduction. In the fourth group (below the pronator quadratus), the deformity is the result of the force applied and not the action of any particular muscle or muscles. Reduction once properly accomplished will in most cases be easily maintained. Any splint employed should be made to fit the part. The author prefers plaster of Paris.

---

79. Sucha, W. L.: Nebraska M. J. **7**:349 (Oct.) 1922.

Treatment of Fractures of the Forearm with Great Dislocation Treated with Pin Traction.—Koopmans [80] reports a series of cases of difficult fractures of the forearm treated by skeletal traction with pins. One pin is passed through the lower ends of the radius and ulna, transfixing both in the lateral plane. With the patient recumbent, the arm is suspended by traction strips, fixed to the protruding ends of the pin and leading to an overhead pulley and weight. Counter traction is obtained by a second pin, which transfixes the olecranon process. The author presents a series of roentgenograms taken before and after treatment, in which each of the cases shows very marked improvement in alinement. No bad results have followed the employment of this method.

[Ed. Note.—An efficient traction method for fractures of the forearm is greatly needed, but Koopmans' method is open to the objection that it transfixes both radius and ulna, and thus prevents correction of the rotary deformity of the radius, which is nearly always present in these cases. It would seem from his illustrations that the pin must pass through a portion of the inferior radio-ulnar joint, which is undesirable from the standpoint of restoration of function.]

Resection of the Distal End of the Ulna in Cases of Shortening of the Radius Following Fracture.—Head,[81] in four cases of marked shortening following fracture with overlapping or loss of substance, or impaction and comminution of the lower radial epiphysis, found that the distal end of the ulna projected so far as to interpose a mechanical block to wrist joint motion and to ulnar flexion of the head, whether a true subluxation of the ulnar head did or did not exist. He reports that successful results were obtained by a subperiosteal resection of the distal head of the ulna.

Crushing Fractures of the Spine.—Wallace [82] has made a thorough study of these lesions in eighty-two cases, and discusses the symptoms and diagnosis in detail. Trauma is always the cause, and he finds three causes of injury: (1) a blow from a heavy object falling on the upper back or shoulders; (2) the fall of the patient from a height, striking on the head or shoulders; (3) crushing between two objects, sharply flexing the spine. His treatment is mechanical, and he describes an especially adapted bed and frame. Operation he considers unnecessary in early cases. The following points should aid in diagnosis: (1) the history of the accident; (2) the presence of prominent spinous processes or angular deformity; (3) localized tender spinous processes; (4) limitation of motion; (5) roentgenograms

80. Koopmans, R. A.: Surg. Gynec. & Obst. **35**:793 (Dec.) 1922.
81. Head: California State J. M., Jannuary, 1923, p. 1.
82. Wallace, J. O.: J. Bone & Joint Surg. **5**:28 (Jan.) 1923.

taken in the anteroposterior and lateral planes. Many fracture crushes of the spine, without cord involvement, are unrecognized. A too general impression prevails that if a man can walk he has not fractured the spine, and only treatment for sprains and contusions of the soft parts is instituted and the patient is allowed to be ambulatory without support much too early. Wallace's practice is to correct any existing deformity, and to immobilize the spine in the best possible position for at least six months. In early cases thus treated, there is, in the author's opinion, no necessity for internal fixation of the spine by operations designed to produce an artificial ankylosis.

Royal Whitman,[83] writing on the diagnosis and treatment of incomplete epiphyseal fractures at the hip, divides fractures of the neck of the femur into two distinct classes: fracture of the neck proper and fracture at the epiphyseal junction. In childhood, the fracture is practically always of the neck and is similar to the adult form except that it is more often incomplete, the neck having been forced downward and backward, leaving a wedge shaped interval on the superior surface near the junction with the shaft. Epiphyseal fracture is extremely uncommon at this age. This latter type of fracture, sometimes called epiphyseal slipping, occurs, with rare exceptions, in adolescents. It may be immediate and complete, as the result of direct violence, but in most instances is incomplete and presents the characteristics of a progressive deformity rather than of a fracture. The deformity consists of a gradual downward and backward displacement of the head on the neck, the rate of progress being determined by the strain or injury to which the weakened tissues are subjected. Whitman describes the roentgen-ray picture as follows: The upper border of the head and neck form an unbroken line in the same plane; the lower border of the epiphysis projects downward in its relation to the neck; the epiphysis appears shallower than normal; the neck, because of its outward rotation, appears shorter and thicker than normal. For treatment, Whitman says that epiphyseal slipping is, in the great majority of cases, a form of fracture, and it should be treated as such by the abduction method. From a therapeutic standpoint, there are three classes: (1) cases of slight deformity in which it is only necessary to fix the limb in an attitude of abduction for a time sufficient to permit repair; (2) cases in which the deformity may be corrected by forcible manipulation; (3) cases in which direct operation is necessary. He concludes his article by saying that, from a therapeutic standpoint, the importance of a clear distinction between coxa vara and epiphyseal displacement is obvious, since, in the first instance, joint motion is mechanically destroyed, being restricted by a deformity which may be

83. Whitman, Royal: Ann. Surg. **76**:624 (Nov.) 1922.

corrected by an extra-articular osteotomy. Epiphyseal displacement, by contrast, disorganizes the joint, and it can be remedied only by an intra-articular correction, either indirectly by leverage, or directly by open operation.

[Ed. Note.—These cases which Whitman speaks of as incomplete epiphyseal fractures of the hip occur, as he says, almost exclusively in adolescents, of both sexes, and in our experience a large proportion of them on careful search, will be found to present other signs of the lack of normal bone structure; which has erroneously been called adolescent rickets. The cause has been variously ascribed to endocrine disturbance and faulty nutrition or faulty assimilation of the normal bone forming elements. Many of these patients, to be sure, give a history of trauma and of more or less sudden increased disability; but, in our experience, the element of trauma is often absent, or so slight as to seem alone insufficient. Moreover, the history of some disability previous to the attributed trauma is so nearly constant as to lead us to believe that some preexistent abnormality of bone growth was present, and to hold this mainly responsible for these lesions rather than the trauma. We have observed a case seeming to illustrate perfectly this hypothesis. We are also inclined to believe that more of these patients in whom the roentgenogram reveals any considerable displacement may, with fairness, be subjected to open operation. We have, in many cases, employed the abduction treatment which Whitman advises, following the exact methods of reduction and fixation which he quite rightly considers necessary in order to accomplish the objects of the manipulation. Subsequent stereoscopic roentgenograms have revealed that, although we have been able to restore the normal angulation of the neck, we have not accurately replaced the displaced epiphysis. Free motion has also been slow in returning, and in several instances is apparently permanently impaired. On the other hand, in cases subjected to open operation we have found much more rotary displacement than the roentgenogram revealed. This displacement it has been possible to correct with seemingly less trauma than forcible manipulation might well have caused, and motion has been satisfactorily restored.

Fractures of the Femur in Children.—Cole's [84] conclusions after study of the end-results in thirty-one cases of fracture of the femur in children, eighteen of which were treated by overhead traction, are: The immediate shortening due to overriding of fragments in growing bones tends to correct itself, even though the fragments have healed in an overriding position. Alinement is more important than the

84. Cole, W. H.: Results of Treatment of Fractured Femurs, Arch. Surg. **5**:702 (Nov.) 1922.

position of the ends of the bones. Perfect functional results may be obtained from a transverse fracture with overriding by using overhead traction. The younger the patient, the more nature compensates for malposition and surgical inefficiency. Overhead traction is more applicable and will give better results than any other method in treatment of fractured femurs in children under 10 years of age.

Fractures of the Tibial Spine Combined with Fractures of the Tuberosities of the Tibia.—Sever [85] reports eight cases of fracture of the tibial spine, associated with fractures of the tuberosities of the tibia. In none was there blocking of extension by the bony fragment, which has always been considered a sign of this fracture. The end-results in the cases which could be followed were, on the whole, good, although knock-knee and relaxation of the ligaments, with symptoms of weakness and, occasionally, pain on heavy use, were found in several. The cases were treated by simple immobilization for a considerable period, in the position of extension.

The Delbet Walking Plaster in the Treatment of Delayed Union in Fractures of Both Bones of the Leg.—The results obtained in practice have convinced Abbott [86] that cases of ununited fracture of both bones of the leg, of several months' standing, should be treated by some form of weight-bearing appliance, preferably the Delbet plaster-of-Paris splint. Its use has made it possible to avoid operations in a number of instances. This method has proved successful when operation with plating has failed. Satisfactory results have also been obtained in cases in which operation had been performed either with or without bone grafts. The article is well illustrated and exact details of the application of this useful plaster are given.

Fractures of the Lower Articular End of the Tibia.—Lounsbury and Metz [87] recognize two types of lipping fracture of the lower end of the tibia, the anterior and the posterior. They illustrate by diagrams an operative procedure which they have found satisfactory for obtaining and maintaining reduction in cases which cannot be held by any other method. A vertical incision is made over the medial surface of the tibia, carried down over the malleolus and curving anteriorly to the distal end of the astragalus. The incision is carried down to the periosteum of the tibia, and the periosteum is reflected toward the medial tibial surface. The exposed fracture is reduced and held by a Lowman clamp; and an autogenous bone peg, secured

85. Sever, J. W.: Surg. Gynec. & Obst. **35**:558 (Nov.) 1922.

86. Abbott, L. C.: Delbet Walking Plaster, Arch. Surg. **5**:485 (Dec. 2) 1922.

87. Lounsbury, B. F., and Metz, A. R.: Lipping Fracture of Lower Articular End of Tibia, Arch. Surg. **5**:678 (Nov.) 1922.

within the field of operation, is driven in to maintain the reduction. By keeping beneath the periosteum, the tendons are retracted with their sheaths and the vessels are displaced without fear of hemorrhage.

Fractures of the Astragalus.—[Ed. Note.—An editorial in the *New York Medical Journal and Medical Record,*[88] advising that astragalectomy be performed at once in all comminuted fractures of the astragalus and in all compound fractures, may possibly be misleading. The prognosis for future perfect foot function in these cases is surely poor when the fracture is treated by any other method; but, in adults, function is often long delayed and imperfect following astragalectomy. One of the reasons for the poor results is the failure of the surgeon to secure and retain a backward displacement of the foot, which Whitman and Chutro have emphasized as of prime importance. No mention of this essential is made in the editorial, and disappointment is sure to follow when the astragalus is simply taken out after complicated fractures unless attention is paid to this factor.]

RESEARCH

Bone Atrophy.—The changes in bone which result from lack of use of the extremities in various clinical conditions were observed by Allison and Brooks,[89] and these observations were compared with those made on experimental animals. The same atrophic changes in bone were observed when the lack of use was due to anterior poliomyelitis or spastic paralysis. The character of the changes was the same in all instances, but the amount of the changes varied directly with the extent of the lack of use. There was absolutely no evidence that bone atrophy was ever the result of specific nerve influence on bone, and it is, therefore, unwarranted to assume that bone atrophy is ever a neurotrophic phenomenon. The initial atrophic changes in bone due to nonuse of an extremity are the same regardless of the age of the individuals, but the ultimate result of the changes is different. In the person who has reached complete growth, for instance, the process of bone atrophy is operating alone. In the person who is in the growing period at the time of onset of nonuse, the process of bone atrophy is associated with the process of growth, which is inhibited, but not arrested, by nonuse. The changes in bone which result from lack of use during adult life are such that the general shape and contour of the bone, as a whole, are only slightly modified. After a long period of nonuse, the compact bone of the shaft becomes porous. The porosity explains the linear striae seen in the roentgeno-

88. Editorial, New York M. J. **117**:167 (Feb. 7) 1923.

89. Allison, Nathaniel, and Brooks, Barney: Bone Atrophy, Arch. Surg. **5**:499 (Nov.) 1922.

gram. Bone atrophy and recovery from bone atrophy are manifestations of the function of bone cells to produce bone matrix, which is, in whole or part, distinct from the function of the bone cells to regenerate themselves.

Anatomy of the Bone Marrow.—Piney [90] has studied the retrogression in the red marrow of the bones and finds that its replacement by fat begins at the periphery of the limbs and gradually progresses in a centripetal manner until the final adult stage is reached, at about 25. The change is evident at about 7, and, at the ages of from 16 to 18, the red marrow in the limb bones is mainly confined to the ends of the long bones. In the adult stage, it is present only in the ribs and vertebrae.

Circulation in the Mammalian Bone Marrow.—By the use of methods of perfusion and injection so planned as to approach the physiologic limits set by the animal under experimentation, C. K. Drinker, K. R. Drinker, and C. C. Lund [91] have demonstrated the following facts: 1. The capillaries conducting blood in the bone marrow of the mammal in a condition of normal blood formation are closed structures, lined throughout with endothelium, and not in communication with the marrow parenchema. 2. Under conditions of active red-blood formation, the extremely delicate walls of these capillaries are grown through by irregularly placed cells in varying stages of maturity. The capillaries are thus, for a varying length, open structures, but the opening presented does not result in flooding the marrow parenchyma with blood, because of the packing of the immature blood cells, which is an essential phase in the process of encroachment on the capillary wall. 3. The normal mature erythrocytes are delivered to the blood stream through the extraordinarily thin endothelial membrane lining the capillaries. This process must occur constantly and under the influence of such slight difference in pressure between the outside and inside of the blood vessels as to cause no actual vascular rupture. 4. If further investigation should show that the red cells develop intravascularly in endothelial bays, temporarily out of the path of the blood current, it should not alter the conception of cell delivery experimentally developed in this paper, since again the problem of accommodation of a growing tissue in a closed space must enter into the physiologic analysis of the problem. 5. The stimulus causing growth of red-blood forming tissue is also responsible for delivery of these cells to the circulation.

---

90. Piney, A.: Brit. M. J. **2**:792 (Oct. 28) 1922.

91. Drinker, C. K.; Drinker, K. R., and Lund, C. C.: Am. J. Physiol. **62**:1 (Sept.) 1922.

Growth and Transformation of Bone.—Mueller,[92] in a large series of experiments, has studied bone growth and transformation. He resected a portion of the radius in dogs, and observed characteristic changes in the ulna opposite the defect. New bone is laid down on the side next the radius. The ulna grows thicker and becomes slightly bent. A kind of callus is formed without a fracture. In another series, a joint taken from a toe was transplanted in the radial defect. The same changes were observed in the ulna. When a portion of the ulna, which in a dog is much thinner than the radius, was resected, no changes were observed in the radius. When a portion of the radius was resected in young growing animals, the picture was different. There were no changes in the shaft of the ulna, but distinct and typical changes in its epiphyseal cartilage and epiphysis. The epiphyseal line increased in width to nearly double in five weeks. The regular arrangement of the cartilage cells became disturbed and the changes resembled very closely rachitic changes. Mueller suggests that the epiphyseal changes in rickets may be considered physiologic reactions of the growth zone to strain.

Experimental Study of the Healing of Fractures.—This study was undertaken by Ely [93] to clear up several obscure points in the process of healing of fractures and to ascertain the exact rôle played by the periosteum. After an ordinary fracture, hemorrhage takes place from the marrow canal under the periosteum. The periosteum is stripped up from the cortex by this hemorrhage and by the fracture itself. Then come the deposition of fibrin, the formation of granulation tissue and the formation of fibrocartilage in the space beneath the periosteum, which has been stripped up. Probably the function of the periosteum is only important in the early stages, up to the formation of the cartilaginous callus, and probably the periosteum serves to prevent the hemorrhage from escaping and to keep the granulation tissue from being disturbed. It has no bone-forming function, and bone is not built out of it. The subsequent ossification of the cartilaginous callus is carried out almost entirely, if not exclusively, from the external aspect of the cortex. The internal callus plays no effective part in the union. It is rudimentary, when present.

Bone Repair Following Injury and Infection.—Bancroft [94] classifies the various theories of bone repair under three headings: (1) Periosteal; (2) osteoblastic, and (3) extracellular deposition of calcium salts. The periosteal theory assumes that the periosteum

92. Mueller: Beitr. z. klin. Chir. **127**:251, 1922.

93. Ely, L. W.: Healing of Fractures, Arch. Surg. **5**:527 (Nov.) 1922.

94. Bancroft, F. W.: Bone Repair Following Injury and Infection, Arch. Surg. **5**:646 (Nov.) 1922.

and endosteum are definite bone-forming organs, and that bone is produced by them and from no other source. The osteoblastic theory contains two different conceptions. One supposes that bone repair is accompanied by bone cells which are liberated from their lacunae by injury. The second assumes that wandering fibroblasts are drawn into the area of injury, and there assume bone-forming function. The theory of the extracellular deposition of calcium salts supposes that there is no specific bone-forming cell, but that repair is accomplished, as elsewhere, by connective tissue, in whose extracellular framework calcium salts are deposited in the same proportion as in bone, the connective tissue cells thus becoming bone cells. The author considers the latter the more plausible theory. He has studied the process of bone repair following fracture and bone grafting procedures both experimentally and clinically. In order for a graft to prove successful, he feels that it must satisfy the three following conditions. It must (1) maintain the shape of the limb; (2) establish a new blood supply quickly, and (3) stimulate osteogenesis. He condemns the intramedullary graft and advocates the bone-peg and the osteoperiosteal graft (Delagenière). From a study of the reparative process in both clinical and experimental osteomyelitis, he urges that more conservative methods be used in the treatment of acute osteomyelitis in children. Adequate drainage should be established, with as little trauma as possible. Bone which appears dead on roentgen-ray or gross examination may frequently be saved, and radical excisions are not only often unnecessary, but are also frequently the means of causing deformity and retarding convalescence. He feels that the process of bone repair has been made to appear too complex. It is easier and simpler to imagine that bone is produced by deposition of lime salts in connective tissue. Such a conception permits an explanation of the formation of bone in the soft tissues in all parts of the body. In bone grafting, we must assume that the transplant serves merely as a framework for the formation of new bone and that it stimulates osteogenesis. Early motion increases the blood supply and favors union.

Fracture of the Tibial Spine: An Experimental Study.—Blaisdell[95] has investigated the mechanism of fracture of the tibial spine by experiments on the cadaver. In four experiments, the tibia was drawn forward and a little inward; and in the other four, the lower end of the femur was driven backward and a little outward. Both were intended to exert strain on the anterior crucial ligament in its longitudinal axis. Out of eight experiments, the tibial spine was

95. Blaisdell, F. E.: Fractures of Tibial Spine, Arch. Surg. **5**:561 (Nov.) 1922.

fractured four times; the crucial ligament was lacerated three times, and an avulsion fracture of the femoral condyle resulted once. Two clinical cases are quoted in which the mechanism is apparently the same as the experimental one. In discussing the clinical aspects of this injury, the author points out that it may result from comparatively slight trauma and that the objective symptoms may be slight. From the standpoint of diagnosis, if the tibia cannot be displaced forward, it may be assumed that the anterior crucial ligament is uninjured, and if, in full flexion, it cannot be displaced backward, the posterior ligament is not damaged.

MISCELLANEOUS

Osteoporosis or Lipomasia from Fixation and Nonuse.—Bloodgood[96] calls attention to the marked changes in bone structure as revealed in roentgenograms following simple fixation and nonuse. In the three cases which he reports, two were referred with the possible diagnosis of sarcoma and the third, of tuberculosis. He suggests that these changes are a fertile field for investigation. One of his patients, eight years after the period of nonuse, still showed changes in bone structure, although clinically and functionally well.

Köhler's Disease.—Alberti[97] reports twenty-two cases of Köhler's disease of the second metatarsophalangeal joint, six of his own and sixteen cases collected from the literature. The roentgen-ray examination reveals alteration in the distal half of the second metatarsal, the cortex being thickened greatly and progressively from the middle of the diaphysis to the metatarsal head. The neck of the metatarsal bone, in consequence of this thickening, more or less disappears. The greatest and most typical alterations are those in the head of the metatarsal. At first, the head shows a little flattening of the articular surface, with some circumscribed areas of rarefaction in the head. Later, the deformity of the head increases and there is some shortening of the metatarsal. The articular surface appears irregular and the structure of the head is sometimes more dense than normal, but more often there are irregular zones of rarefaction. The proximal phalanx of the second toe, ordinarily, commences to be altered later. In early cases, it shows almost no change. Later there is a little broadening of its base to correspond with the broader head of the metatarsal. Aside from this enlargement, marked changes are not ordinarily seen. The disease is usually in only one foot. The condition is not of very frequent occurrence. It developed in the cases studied between the ages of 10 and 47, and was about equally divided between the two sexes. It occurs perhaps more in occupations requiring prolonged

96. Bloodgood, J. C.: J. Radiol. **3**:403 (Oct.), **3**:528 (Dec.) 1922.
97. Alberti: Chir. d. org. di movimento, October, 1922, p. 569.

standing. The previous history in the cases is not especially remarkable, except that in some instances there has been tuberculosis. The disease begins very slowly, with a little pain in the front of the foot corresponding to the base of the second toe, usually worse toward night. Progress of the disease is slow. Sometimes it seems to clear up spontaneously as regards symptoms. In general, the prognosis is favorable. The treatment is either protection and building up of the general condition of the patient, or, in rare instances, resection. Various theories have been suggested as to the cause, but no one cause seems definitely proved.

Treatment of Disabilities of Hand and Wrist: Anatomic Review in Relation to Function.—Cochrane [98] thoroughly analyzes the points of anatomy of the hand and wrist which have to do with the function and carrying out of the fine movements of the hand. He recognizes that early massage and active motion would prevent many chronic disabilities. A sound plan of splinting and physiotherapy must be carried out. Joint stiffness and deformity following fractures cause most disability. The arches of the hand must be restored if the functional result is to be good. Loss of arches of the hand and joint stiffness and tendon stiffness form two of the difficulties. He speaks of the various fractures and their special treatment. The field for prevention of deformity in the first place, during the active stage, and the field for reconstructive surgery, when deformity and disability exist, are both large.

Acromegaloidismus.—Ehrmann and Dinkin [99] have observed forty cases of what they call acromegaloidismus, a condition resembling genuine acromegaly, but distinct from that condition in that it is not progressive. In fourteen cases, enlargement of the pituitary gland was indicated by the widening of the sella in the roentgenogram. The habitus is more or less characteristic, showing the typical enlargement of the nose, chin, hands and feet. The roentgenogram revealed the typical changes of the fingers and toes. The occurrence of several cases in one family indicates the constitutional character of the affection, which is explained by the authors as being caused by a hypersecretion of the pituitary gland, which itself may be of normal size, though, as stated above, an enlargement is not infrequent. This affection is compared with hyperthyroidismus. A passing hypersecretion of the pituitary gland may be seen during the age of puberty. Thus the characteristic bigness of hands and feet of growing children may be explained.

---

98. Cochrane, W. A.: Edinburgh M. J. **29**:97 (Sept.) 1922.
99. Ehrmann, R., and Dinkin, L.: Klin. Wchnschr. **1**:2138 (Oct. 21) 1922.

The Bone Lesions of Smallpox.—Sheldon [100] reports two cases of bony deformity, apparently due to smallpox, which was contracted in youth. Both cases were in Chinese. One showed shortening of the humerus and of the bones of the forearm; the other showed fusion of the distal extremities of the tibia and fibula and fusion of these with the astragalus. There was also complete ankylosis of the right elbow, the medullary canal of the humerus being continuous with those of the radius and ulna, but no shortening. There was marked shortening of the first and fifth metatarsals of the feet; of the first, second and fifth metacarpals of the right hand, and of the fifth metacarpal of the left. The author reviews the previous report of Musgrave and Sison on the same subject. The latter state that the bone lesions are usually observed in persons with a history of smallpox during early childhood, but the deformity may follow variola contracted at any time before the complete ossification of the bones. The greatest age at which such a complication of variola has been observed was 14 years. The close resemblance in the character of the deformities; their constant association with a history of smallpox during early life, and the absence of similar lesions under other conditions seem to warrant the conclusion that the deformities are a complication of variola. Musgrave and Sison sum up the anatomic and histologic findings as follows: The process appears to be due to destructive lesions in the epiphyses of the bones. The ends of the bones are enlarged and irregular in shape, and similar changes may be encountered in the carpal, metacarpal and phalangeal bones. The circumferential growth is not disturbed in the least, thus proving that the periosteum is not affected. The bones are markedly shortened and stunted in longitudinal growth. Sometimes they are reduced to less than one half the length of the normal bone. The obvious conclusion is that the seat of the primary lesion is at the epiphyseal junction. Sheldon notes that all of the cases thus far reported, with the exception of one from Mexico, come from the Orient, and he therefore raises the question as to whether the particular variola of the Orient differs from that of the Occident or whether we are failing to recognize these cases.

Clinical Study of Phrenic Shoulder Pain.—Cope [101] considers the subject of referred pain in the shoulder resulting from diaphragmatic irritation in various types of acute abdominal disease. He cites cases to show that this symptom frequently is present and is due to stimulation of the sensory terminals of the phrenic nerve. The pain is felt in some part of the segmental areas, corresponding to the third and

100. Sheldon, F. B.: Am. J. Roentgenol. **10**:35 (Jan.) 1923.
101. Cope, V. Z.: Brit. J. Surg. **10**:192 (Oct.) 1922.

fourth and sometimes even to the fifth cervical segment of the cord. There is an important localizing correspondence between the part of the diaphragm irritated and the position of the referred pain in the shoulder, and, depending on this fact, the pain may be felt in the supraspinous, supra-acromial, supraclavicular or subclavicular regions.

Spinal Flexibility.—Bradford [102] considers the subject of spinal flexibility in its relation to scoliosis. He compares the amount of movement possible in the spines of infants, children and adults and points out the various factors which may enter during the early years of growth to produce structural changes such as faulty attitudes and improper muscle balance. He reports a simple method of tracing and recording spinal curves and changes in body contour. When the flexibility of the spinal column is to be noted, the patient is bent to one side and the other alternately and steadied in the required position, tracings being taken. Although anteroposterior tracings can be made and are important, in studying beginnings of threatened twists the side flexibility seems of the most value as a premonition of possible rotation through faulty weight bearing. There will be found much variation not only in the lack of symmetry in the side motions in an individual, but also in the location of the centers of greater side flexibility in different individuals. These variations may, in flexibility tracings, be regarded as the result of variation in habitual attitude or variation in growth in children.

BOOK REVIEW

RECONSTRUCTIVE SURGERY OF THE UPPER EXTREMITY. By Arthur Steindler, M.D., Professor of Orthopedic Surgery, Iowa State University Medical School. New York: D. Appleton and Company, 1923.

This book on reconstructive surgery of the upper extremity by the man who has given perhaps more attention to this branch than has any other surgeon in America is most timely. Most of reconstruction surgery in children has been devoted to the lower extremity, quite naturally, since locomotion is the first problem which presents itself. From the point of view of wage-earning capacity, the upper extremity is of even greater importance; and to these problems Professor Steindler has been devoting himself for many years, with conspicuous success.

The book, of 300 pages, is concisely written and generously illustrated with original drawings and original photographs of methods and results in the author's own experience. Operations, many of which have been devised by Professor Steindler, are clearly described and illustrated by excellent line drawings. Complete bibliographies follow each chapter.

The book is recommended most highly to all who are interested in extremity surgery. It is a valuable contribution to medical literature.

---

102. Bradford, E. H.: Boston M. & S. J. **187**:785 (Nov. 30) 1922.

Correspondence

"BLOOD TRANSFUSION: A STUDY OF TWO HUNDRED AND FORTY-FIVE CASES"

To the Editor.—The paper by Dr. Glover H. Copher on "Blood Transfusion" that appeared in the July issue of the ARCHIVES OF SURGERY, pages 125-153, contained an interesting discussion of blood transfusion, with instructive analysis of 245 cases. The references are extensive.

In regard to direct transfusion, however, the author's attitude does not appear to be entirely consistent. On page 136, he says: "One still reads an occasional report of a direct transfusion by vessel to vessel anastomosis in this country (Horsley, J. S.; Vaughan, W. T., and Dodson, A. I.: Direct Transfusion of Blood, Arch. Surg. **5**:301 [Sept.] 1922) and abroad. Horsley, Vaughan and Dodson, in using this method recently in twenty-four cases, did not observe even a chill in any of the patients. This method has not been used in this clinic because of its many obvious disadvantages." Immediately following this, he says: "No method of blood transfusion has been devised that is not followed by a varying percentage of reactions." The series that we reported was small, but there were no reactions in that group. Since then, we have done thirty transfusions, sixteen being done by my partner, Dr. Dodson, and fourteen by me. The first transfusion in the reported series of cases was performed, Nov. 16, 1920, and the last, May 30, 1922. Since May 30, 1922, thirty transfusions have been performed; the last July 11, 1923. During this entire period, all transfusions at St. Elizabeth's Hospital have been direct, as described. In none of the cases has there been a reaction, either a chill or any unusual rise of temperature. When the patient had chronic sepsis and fever before the transfusion, the rise of temperature often continued for at least a few days after the transfusion, but the range of this temperature was similar to what it was before.

On page 136, Dr. Copher says: "Because of the fewer posttransfusion reactions, which we hold to be harmful, the transfer of whole blood without the addition of a chemical is desirable in most cases in which assistants and apparatus are available." On page 137, he says: "Severe reactions following transfusion have undoubtedly been the precipitating factor in the death of very sick patients;" and, on page 138: "Blood is not toxic at the moment of removal but becomes so during the early clotting changes and its toxicity is increased by contact with foreign substances." These observations of Dr. Copher are borne out by many surgeons. The period of normal clotting of blood is about three to four minutes. There is undoubtedly a progressive chemical change toward clotting which in all probability is inaugurated very shortly after the blood leaves the vascular system. These changes may be somewhat delayed by such methods as are used in transferring whole blood, or the chemistry of the blood may be so altered by the addition of foreign chemicals, such as citrate of sodium, as to postpone clotting indefinitely. But it is obvious that, aside from technical difficulties, the ideal method to avoid toxic changes in the blood would be to transfer the blood unchanged from the vascular system of the donor to the vascular system of the recipient with the least possible intervening time.

This can be accomplished either by vascular suture or by employment of a type of cannula that permits only the endothelial surface of the blood vessel to be presented to the current of blood. Such a transfusion requires rather extensive exposure of the blood vessels of the donor and of the recipient. A short jointed cannula, such as the Bernheim cannula, necessitates only an inch incision over the radial artery in the donor, and an incision even shorter in the patient. A very small portion of the blood stream from the artery of the donor touches the inside of the cannula, which is coated with oil, and this contact is for a brief fraction of a second. Half of the cannula is inserted into the donor in the operating room, and in the patient's room the other half is placed in the patient. The donor walks to the patient's room and sits in a chair or lies on a stretcher beside the patient. There is no more disturbance of the patient than there would be in a citrate transfusion, unless the short incision over the vein is counted against this method.

The patient and the donor are watched carefully, especially by observations of blood pressure and pulse rate, to detect any indications for discontinuing the transfusion. After the transfusion is discontinued, the donor goes to the operating room, where his small wound is sutured.

From the standpoint of the welfare of the patient, this method seems most satisfactory. It is undoubtedly true that professional donors may object to even an inch incision over the radial artery. We have used the same radial artery more than once in a transfusion. The scar from the original incision can be excised and the incision slightly extended upward, exposing the stump of the radial artery. In a large clinic where many professional donors are used, this aversion to even a short incision may be serious; but when the donor is a friend or relative of the patient, there is usually no such objection.

The measurement of the amount of blood transfused seems immaterial. Any therapeutic agent is used for the results to be obtained, or supposed to be obtained, thereby, and not in order to administer a certain measured amount. In giving an anesthetic, for instance, enough ether is given under competent observation to keep the patient in a state of unconsciousness. No one would think of measuring the dose of ether before the operation, and be satisfied when that dose is given. The same is true of every drug. If a small dose does not produce the physiologic effect, it is increased. So in transfusion of blood. The usual object of transfusion is to put into the recipient a sufficient amount of blood to produce certain definite clinical results, unless the donor in the meantime shows signs of danger. These results should be obtained, if possible, regardless of whether it takes 300 c.c. or 1,000 c.c. of blood; and by accurate observation of both donor and patient during the transfusion these results can usually be safely obtained.

Another feature of this direct transfusion is the fact that arterial blood is used instead of venous. While the difference may be slight, it would seem that arterial blood, which is well oxygenated and contains a maximum amount of nutrition, would be more valuable for a depleted patient than venous blood with its waste material.

On page 140, Dr. Copher says: "In seventy-nine sodium citrate transfusions for various indications at the Barnes Hospital, thirty-seven, or 46.8 per cent., were followed by rise of temperature of more than 1 degree, either accompanied or unaccompanied by other symptoms. Twenty-four of the thirty-seven patients had chills. In seventy-nine transfusions by the use of syringe cannulas, eleven patients, or 13.6 per cent., had a similar reaction. All except three of the foregoing transfusions were performed on adults. In another

group of cases extending over the same length of time at the St. Louis Children's Hospital, there was a much lower percentage of reactions."

It is difficult to see how, with this record, which is certainly a good average record for the methods that he uses, Dr. Copher can so entirely dismiss the results of the direct transfusion that we have described, in which there was no reaction at all, particularly when the added number of cases, making a total of fifty-four, is considered, because, as Dr. Copher very justly says, "Posttransfusion reactions" are "harmful." In fact, a severe posttransfusion reaction in a desperately ill patient—and this is the type in which transfusion is most needed—may do as much harm as the transfused blood does good.

J. Shelton Horsley, Richmond, Va.

ARCHIVES OF SURGERY

VOL. 7 NOVEMBER, 1923 No. 3

A CLINICAL AND PATHOLOGIC STUDY OF TEN BONE TUMORS *

JOHN J. MORTON, M.D., AND WILLIAM C. DUFFY, M.D.
NEW HAVEN, CONN.

In spite of the many excellent publications on tumors of bone in the recent literature, the average surgeon is puzzled as to the diagnosis and treatment. A review of some of the cases which we have observed convinces us that there is good reason for bewilderment.

We gather from the writings of different men that there are three general approaches to a diagnosis of the type of any bone tumor. The clinical course, with the known age incidence of the various kinds of neoplasm, the location in the bone and the slowness or rapidity of growth give us the first lead toward the solution. The second factor which is of material assistance is a correctly interpreted roentgenogram, the large proportion of tumors giving characteristic appearances. Lastly, the diagnosis may be clinched by a microscopic study, either by means of a frozen section at the time of operation or by more thorough pathologic study after the tumor has been removed.

We have applied these three methods of study to our small group of cases.

REPORT OF CASES

CASE 1.—*History.*—C. S., a teamster, aged 47, admitted to New Haven Dispensary, Sept. 7, 1920, with a complaint of "sore hand," in 1903 fell and broke his left wrist. In 1908, he again fell and broke the wrist in the same place. In 1910 and in 1911, the arm was broken at the wrist in falls from a house and from a wagon.

In 1913, he came to the New Haven Dispensary, complaining of a sore hand. Examination revealed a fracture of the lower third of the left radius. Roentgenograms taken Feb. 25, 1913, showed a many chambered cavity of the lower end of the radius. The cortex was preserved and the roentgenologist considered the picture typical of giant cell tumor (Fig. 1). Splints were applied The patient next appeared, Sept. 7, 1920, with a tremendous swelling involving the lower third of the left forearm to the wrist. This growth had been slowly enlarging for seven years.

Physical Examination.—The patient's condition was normal throughout except for the large, nodular, irregular swelling which surrounded the left wrist, measuring from 6 to 7 inches (15 to 17.5 cm.) in diameter. It was soft in places and had many tender areas, but the general consistency was firm and solid. On palpation, it did not feel like bone, and there was no egg-shell

* From the Surgical Section, Yale University School of Medicine.

crackling elicited. The mass was firmly adherent to the bony structures. The skin over it showed evidences of tension by its shiny, red appearance and orange peel character, and by the purple distended veins (Fig. 2).

The roentgen-ray revealed a destructive process of the whole lower third of the radius. There was also an irregular overgrowth of bone in the same region and invasion of the surrounding soft parts. The roentgen-ray appearance was now typical of an osteogenic sarcoma of the radius (Fig. 3).

Fig. 1 (Case 1).—Many chambered cystic growth at the lower end of the radius. The appearance suggests giant cell tumor.

Operation.—The patient was sent to the New Haven Hospital for roentgen-ray therapy. In September, 1920, an amputation was performed by Dr. T. S. McDermott at Springside Hospital.

Pathologic Examination (Fig. 4).—The specimen consisted of a forearm and hand, the normal contour of which was greatly distorted by a huge tumor surrounding the wrist like a cuff. The tumor tissue, it was estimated, weighed

between 1 and 2 pounds (453.6 and 907 gm.). The diameter of the neoplasm was approximately 12 cm. The tumor had not only destroyed the lower end of the radius, it had also involved the carpus and more extensively the surrounding soft parts. On section, the tumor appeared to have developed largely as a circumscribed encapsulated growth. Although some of the extensor tendons passed through the main mass of its structure, one was led to believe by the circumscribed appearance of the most peripheral portions of the growth that this involvement of the tendons took place by a process of envelopment and, later, fusion of the surrounding tumor processes. The circumscribed appearance referred to appeared to be really due to encapsulation. This was best seen on the side of the tumor farthest up the forearm, where a nodular process of the main mass was extending upward along the lateral surface of the radius, push-

Fig. 2 (Case 1).—Appearance of tumor when patient entered the dispensary.

ing away the tendon and belly of the flexor carpi radialis without infiltration of either. The same encapsulation prevailed in those parts of the periphery of the tumor nearest the skin. The latter everywhere was separated from tumor tissue, although where the skin was under greatest pressure, it seemed adherent to the thin capsule.

At its lower end, the tumor had obliterated the wrist joint, and extensions of it had pushed between the carpal bones. As a result, the appearance was more suggestive of infiltration, in the sense of invading neighboring structures by diffuse growth through the tumor capsule. Here, in places, the cartilage covering of individual carpal bones was destroyed by pressure atrophy or invasion (?), but the carpal bones themselves did not show definite invasion (macroscopically).

The specimen was not examined until after fixation in formaldehyd, but it was much firmer than the typical giant cell tumor, and for the most part was of a quite dense consistency, suggestive of that of fibrous tissue. This density was especially marked where the lower end of the radius was replaced by tumor. Here, and near the ulna, the consistency was that of diffuse new bone formation. There was, however, a soft area 3 or 4 cm. in diameter on the radial side of the mass opposite the wrist joint, which was light brown and of crumbly consistency. In the gross, this was thought probably to be

Fig. 3 (Case 1).—Roentgen-ray appearance of growth shown in Figure 2. There is bone destruction and new bone formation, suggestive of osteogenic sarcoma.

a place which would show either giant cell areas or malignancy on histologic examination. (In both of these assumptions, we were wrong).

For the most part, the tumor tissue was rather pink, and the cut surface suggested a growth in the form of fibrous whorls and nodules.

Numerous blocks were selected for microscopic study.

Microscopic examination: Sections were cut from several different portions of the tumor. All showed essentially the same picture, that of a very fibrous

tumor with extensive hyalinized areas (Fig. 5). No giant cells were found in any of the sections, although diligently searched for. Sections from the single area of soft tissue noted in the gross showed a diffuse necrosis of cells, the preexisting nature of which it was impossible to determine definitely. They appeared as vague shadows often polyhedral in outline. The periphery of this area of necrosis was surrounded by a zone of round-cell infiltration, most of

Fig. 4 (Case 1).—Gross specimen. The lower end of the radius is replaced by tumor tissue.

the cells being apparently of the lymphoid type, with occasional polymorphonuclears. There was no suggestion of tuberculosis.

Sections of the bone-containing tissue in the tumor showed definite new bone formation (osteoid tissue), with deeply staining bone cells forming delicate interlacing patterns (Fig. 6). This is an unusual picture in central bone tumors.

The histology is similar to that of the periosteal ossifying sarcoma studied by Le Count[1] and of the central "sclerosing osteogenic sarcoma" of Ewing.[2]

The final diagnosis was: medullary sclerosing osteogenic sarcoma of the lower third of radius.

April 20, 1923: The patient was seen today. The amputation stump was well healed and showed no signs of trouble. Careful examination of the

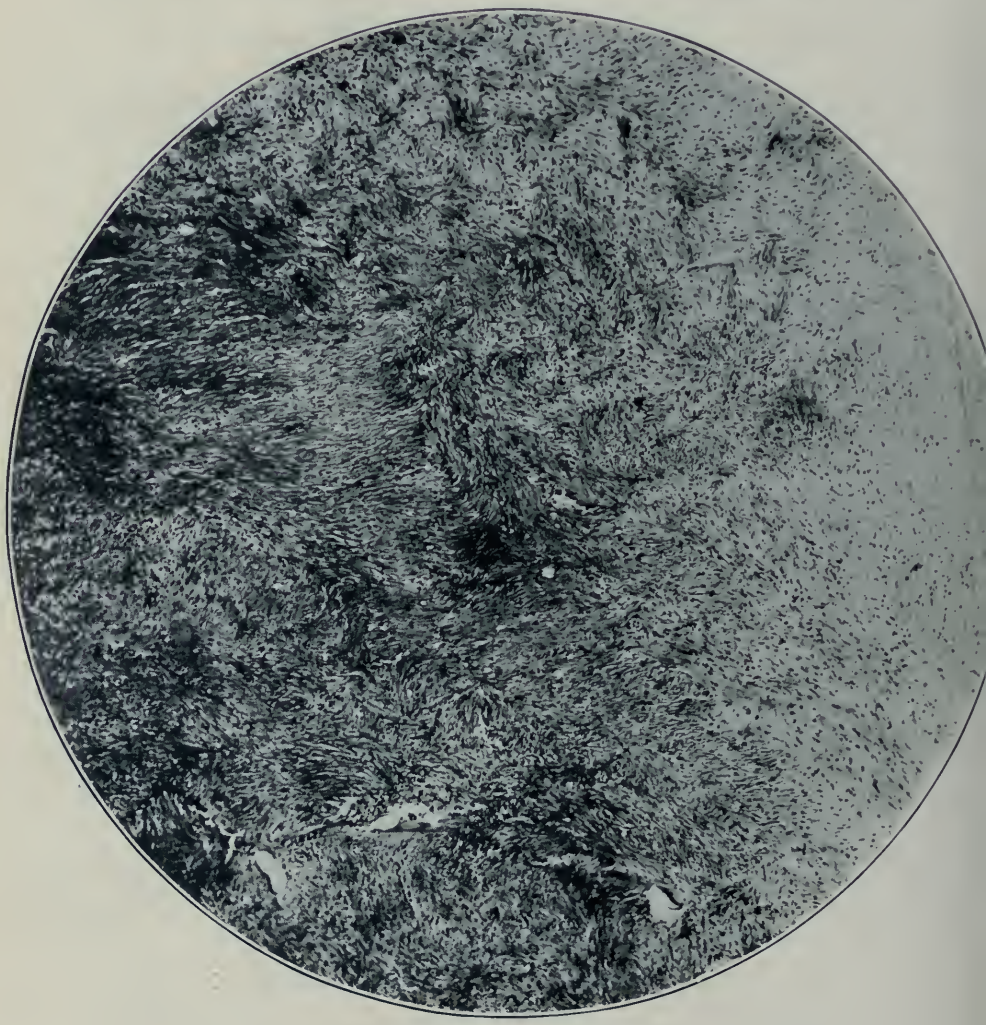

Fig. 5 (Case 1).—Arrangement of fibrous tissue in whorls.

axillary lymph glands and chest did not reveal any evidence of metastasis. The patient is working daily and feels normal in every way.

1. Le Count, E. R.: Bull. Johns Hopkins Hosp. **20**:361-370, 1909.

2. Ewing, James: Neoplastic Diseases, Philadelphia, W. B. Saunders Company, 1919, p. 270.

From a clinical point of view, the tumor in this case should be a benign growth. The history of repeated fracture, with the slow painless enlargement of the left wrist over seven years before the patient sought relief, favors a process which certainly could not be

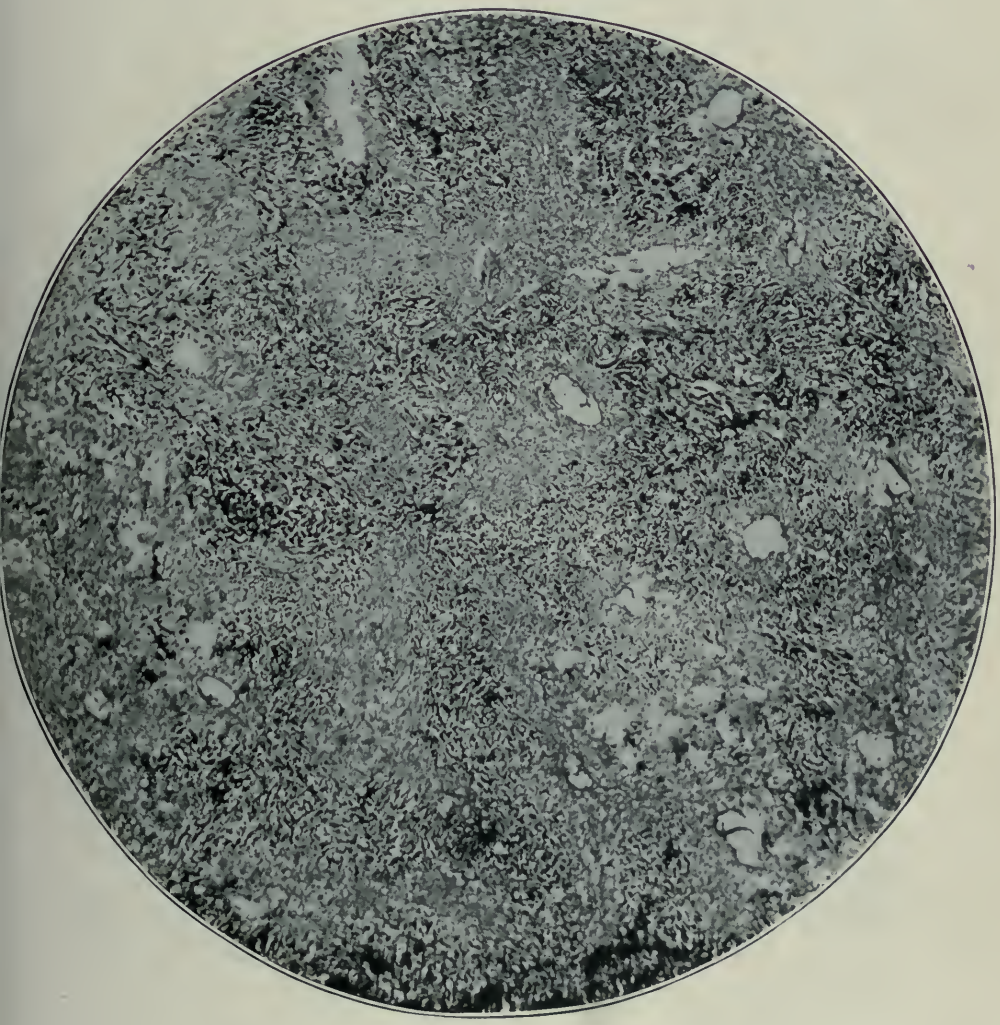

Fig. 6 (Case 1).—The interlacing bony strands, presenting the appearance of a black network.

of a very malignant character. The course since amputation is also in accord with such a view. The first roentgenogram would be interpreted by a majority of roentgenologists as a giant cell tumor of the lower end of the radius. This is a favorite site for such tumors. The

bone is not eroded and there is no formation of new bone. The many chambered cavity with expansion of the cortex, replacement of the normal contour and architecture, and extension to the very end of the epiphysis are typical of giant cell tumor. The roentgenogram taken seven years later would certainly not bear such an interpretation. Here, we have actual destruction of bone, and irregular new bone deposit. Although Bloodgood has shown that giant cell tumors may break through the cortex, his roentgen-ray pictures do not give the new bone

Fig. 7 (Case 2).—Appearance of tumor when patient was admitted to hospital, in March, 1922.

formation and patchy destruction as in this case. Most interpretations of this roentgenogram without the clinical history would be osteogenic sarcoma.

From the gross pathology of this tumor, it is rather difficult to say positively that the growth did not start as a periosteal tumor, although one inclines definitely to the opinion that the neoplasm was of central

origin. The mesial cortex of the radius for a distance of 6 cm. was entirely replaced by tumor continuous with that filling the shaft. Similarly, there was no trace left of the epiphyseal line, and only traces remained of the epiphysis itself. The lateral surface of the radius could be traced slightly better, but apparently had been perforated at several points and destroyed entirely at the lower end. The new growth of bone was not of the extensive degree and radiating form usually found in the bone-producing tumors of periosteal origin.

The question as to whether it is periosteal or of central origin is of considerable interest because of the greater rarity of bone-producing

Fig. 8 (Case 2).—Roentgen-ray appearance of growth shown in Figure 7. The new bone formation about the lower end of the ulna suggests periosteal sarcoma.

tumors of central origin, and, more important, on account of the relatively slower growth of the central "sclerosing" tumor, with consequent influence on prognosis.

Le Count, in 1909, made an excellent study of ossifying bone tumors, in which the literature was carefully reviewed. The histology of bone production was studied as manifested in his patient with periosteal osteosarcoma, who died with pulmonary osseous metastases. With regard to the rarity of the central type of tumor (the myelogenous

ossifying tumor), he states that Benecke, in 1904, when reporting such a case, was able to find but one other such case in the literature (that reported by Virchow). Ewing (1922) describes the central type of ossifying tumor and reintroduces the term "sclerosing" to include this neoplasm in his classification. Originally, Virchow and Volkmann used the term "sclerosing osteoid sarcoma." This "sclerosing" central tumor is apparently a very distinct clinical-pathologic entity. Histologically, it is characterized by the production of hyaline osteoid tissue, the so-called "bone-cartilage" of Billroth (cited by Le Count), which is at first loosely spaced or composed of delicate interlacing strands (Fig. 6), but which later may become hard, compact bone. Clinically, the disease

Fig. 9 (Case 2).—Gross specimen after removal.

runs a course of from five to twenty-five years (Ewing), metastases probably occurring early, yet taking years to develop sufficiently for thoracic signs to be detected.

Dr. Morton has raised the interesting question as to whether such a tumor as that reported above might be a result of a reparative process in a giant cell tumor that had broken through the bone capsule. There is no basis for such a hypothesis, except possibly the analogous process that occurs in bone cysts some of which have giant cell tissue in the cyst lining. There is scarcely sufficient data, however, for intelligent discussion of this possibility. It seems likely that if the present tumor is the result of efforts at healing of a giant cell tumor the repeated trauma extending over a period of several years has had the effect

of stimulating this reparative tissue to such an extent that the process has become one with the power of independent growth beyond the original desideratum.

In summary, we have here a tumor with a clinically benign course, with one roentgenogram typical of giant cell tumor, and another typical of osteogenic sarcoma, and a pathologic picture which shows no giant cells, but a dense fibrous tissue and lacy bone structure which is probably malignant.

We feel confident that amputation was, in this case, the ideal treatment. It removed a growth of probable malignant nature, possibly before metastasis had occurred, and the after course has been satisfactory. Local excision and grafting would have been a slow and by no means sure procedure, possibly accompanied by infection and almost surely resulting in poor function of the wrist.

Case 2.—*History.*—J. W., a cigar maker, aged 51, admitted to New Haven Hospital, March 6, 1922, with the complaint of tumor of the left wrist, had always been a strong and healthy person. There was a Colles fracture of the left wrist at 14 years, and "rheumatism" in the left arm about the wrist since 1914. Otherwise there was nothing of note in the personal history. A small tumor appeared on the dorsum of the left wrist just above the joint in February, 1916. It was excised shortly after it was noted. In two or three months, the wrist became painful, and the growth recurred in the position as previously. In August, 1917, a surgeon removed the tumor and diagnosed the condition as "spindle-cell chondroma," presumably from a microscopic section, although this has not been verified.

The next trouble developed about one year later (Sept. 1, 1918), with the reappearance of swelling near the left wrist.

Examination.—The patient was admitted to the New Haven Hospital, four months later, when Dr. John Churchman made the following note (January, 1919): "The tumor is now a growth between the radius and ulna about 1 inch above the styloid process, involving both bones, across the arm to the dorsum of the wrist in the shape of a band. On the palmar surface, the bony growth is not prominent. There is some irregularity of the tendon sheath, which may be the result of operation. There are three scars on the palmar surface of the arm."

Operation (Jan. 7, 1919).—Dr. Churchman performed a resection of the tumor of the radius. The tumor mass involved the ulnar side of the lower end of the radius. No attachment to the ulna or to the extensor tendons was made out. The involved area was chiselled away, leaving a small arch of bone as the remainder of the lower end of the radius. The joint cavity of the wrist was opened on the posterior surface.

Course.—Recovery was uneventful, and the patient was discharged.

January 15: The pathologic report gave a diagnosis of chondroma (Fig. 10).

Shortly after the patient left the hospital, the growth recurred, slowly increasing in size. He went to New York, where he was admitted to the St. Luke's Hospital, July 19, 1920. The tumor at this time seemed to be situated between the two bones of the forearm, bulging out the volar surface of the wrist. It was hard, slightly tender, movable and about the size of a walnut. It was

excised, and the following pathologic report was made: "Section of the tumor shows it to be composed entirely of cartilage cells, many of them showing marked irregularities in form and distribution throughout the matrix. The growth has a very delicate fibrous sheath which carries a few blood vessels and extends into the tumor substance a short distance. The lacunae are very

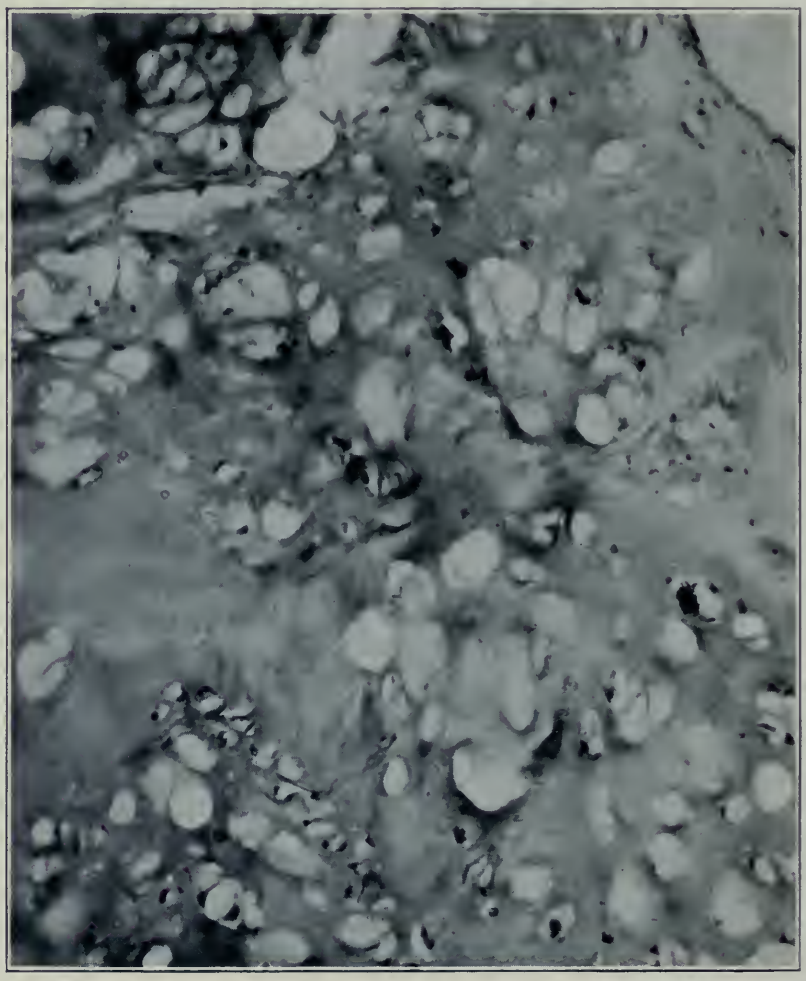

Fig. 10 (Case 2).—Microscopic section; chondroma (Jan. 15, 1919).

irregular, being without any of the normal paired arrangement. There is no fibrous stroma which is at all cellular and there appears to be no tendency toward calcification or ossification within the growth."

Recurrence promptly took place again, almost as soon as the scar of the operation had healed. The swelling occupied the volar surface of the left wrist. It slowly increased in size at first, and later assumed a more rapid growth. There had been pain radiating into the hand and fingers.

The patient entered the New Haven Hospital, March 6, 1922. Examination showed him to be obese and well developed. The findings were relatively negative. The lungs gave no evidence of a pathologic condition. There was an enlarged, easily palpable gland in the left axilla. On the volar surface of the left wrist, there were two tumors. One on the radial side distended the soft tissues over it markedly and measured roughly 3 by 3 by 4 cm. It was about the size of an English walnut, slightly tender, hard and movable. There was no inflammation of the overlying skin. The growth merged into a similar tumor on the ulnar side of the wrist, which was about four times as large, of similar consistency and firmly attached to the ulna itself. Between these two swellings, there was a linear scar of a previous operation, and there were two other scars, a large one over the middle portion of the dorsum of the arm, which extended from the wrist upward for 12 cm., and a smaller on the volar radial side. The condition at this time is shown by Figure 7.

Supination of the wrist was less than one half normal. Otherwise, the motions were not limited.

Roentgen-Ray Examination.—There was considerable swelling of the distal end of the right forearm, with some rather unusual pathologic condition of the radius and ulna. Beginning just below the head of the ulna, there was a fairly definite increase in density of the entire bone, obliterating the medullary cavity to some extent. The inner surface of the ulna was thickened, but had a smooth contour which extended partly around the bone, and was most marked on its anterior surface. There was definite bone formation with bone laid down perpendicular to the shaft. The radius showed a very slight irregularity, approximately 3 cm. from the lower end of the inner surface. The bone itself was apparently not greatly involved, but its dorsal and inner side near the end showed some deformity due to pressure. It was impossible to make a diagnosis from the roentgenogram alone. The lesion resembled a periosteal sarcoma. Owing to the fact that it was of such long duration and that there were two postoperative recurrences, it would seem that the tumor was more or less benign. It was, however, probably a mixed tumor which to some extent was malignant (Fig. 8). There was considerable fibrosis throughout both lungs.

Laboratory Findings.—The Wassermann reaction was not reported. The red blood count was 4,200,000; white blood count, 8,100; polymorphonuclears were 72 per cent.; large mononuclears, 16; small mononuclears, 12. Urinalysis revealed an occasional hyaline cast, and a few erythrocytes and leukocytes. Bence-Jones bodies not reported.

Second Operation.—March 7: A gland was removed from the left axilla under local anesthesia. The pathologic report was hyperplasia of the lymph gland.

March 10: Dr. Morton excised the lower half of the left ulna with the tumor. A bone graft was made to replace the removed bone. The tumor attached to the tendon sheath of the wrist flexors was removed.

Convalescence was uneventful and the patient was discharged on March 28, 1922.

Pathologic Examination (Fig. 9).—Grossly, the specimen consisted of a tumor partly surrounding the distal end of the ulna. The tumor was nodular and the greater part of it projected from one side of the bone. It was firm and cartilaginous, pearly white, with areas which had a slightly bluish tinge. The portion of ulna excised measured about 8 cm. in length including about 1 cm. beyond the upper end of the tumor. A longitudinal section through the center of the ulna showed that the tumor was closely attached to the bone,

from which small irregular shaped spicules were seen extending into the growth. There was no actual invasion of the bone. The tumor extended around, about three-quarters of the circumference of the bone. On cross section, the tumor measured about 2 cm. anteroposteriorly. Transversely, it measured about 6 cm. With the specimen, there was a small oval nodule measuring about 3 cm. in its greatest diameter. It was dark blue and slightly softer than the main tumor. A section through the mass showed that the center was cystic. The cut surface of this as well as of the main tumor was translucent and pale bluish gray. There were several small bits of tissue from which blocks were cut for histologic examination. Several blocks were also cut from other portions of the tumor.

Microscopic examination: The numerous sections studied showed marked differences from those made on previous admission to the hospital. At that time, there was a close resemblance between the tumor cells and normal cartilage, and there was much less evidence of activity. The different sections of the tumor showed essentially the same picture. The tissue resembled cartilage, although it varied quite markedly from the normal cartilage in structure. The variation was most conspicious in the number and arrangement of the cells and in their different staining characteristics. In most areas the cells were quite numerous and were irregularly arranged. They were largely polymorphous. Many showed two nuclei within a single cell. The nuclei were large, and were round or oval. The cytoplasm was pale pink and was homogeneous in appearance, varying quite markedly in size and shape. Occasionally, definite mitotic figures were seen. The matrix varied somewhat. In different areas, it appeared as a pale homogeneous, formless pink-staining material. The relative amount of cells and matrix varied considerably in different portions of the tumor. There were dense fibrous bands running through the tumor and dividing it into lobules of various sizes. These connective tissue septums extended inward from the capsule, which was moderately thickened and consisted of relatively dense and partly hyalinized fibrous tissue, with areas in which blood vessels were quite numerous.

There were a number of small areas that were definitely myxomatous in character, composed of typical myxoma cells, often stellate or triangular in shape, and situated in the substance of the tumor. The matrix here was very thin and delicate in appearance. There were also numerous areas showing a pale pink-staining matrix with very few cells (Fig. 11). The sections from the bits of tissue removed from the intermuscular septum showed no definite invasion by the tumor.

The diagnosis was myxochondroma, recurrent.

The patient remained well till August 7, when he noticed a small lump on the outer side of the forearm. On examination, a hard nodule about the size of a pea was palpable in the tissues near the ulnar side of the joint. A 2-inch (5 cm.) incision was made under procain anesthesia, and a small tumor exposed, apparently attached to the tendon sheath of the flexor carpi ulnaris. The tumor was removed with a portion of the tendon sheath and underlying muscle.

Pathologic examination revealed chondromatous tissue.

Nothing further was heard from the patient till March 13, 1923, although he had been repeatedly advised about reporting early and seemed to understand the reasons. Sometime in December, 1922, he observed a small swelling on the ulnar side of the wrist. It gradually increased in size and forced him to give up his work by interfering with the function of the arm. It was not painful.

On examination, there was a swelling easily seen about 2 inches (5 cm.) above the wrist on the ulnar side of the arm. It was very hard, smooth and encapsulated, and was not attached to the overlying skin. It was movable from side to side but not up and down. It did not move with the muscles and tendons of the wrist and hand. It was not tender, showed no signs of inflammation and felt about the size of a large plum. There was disturbance in the

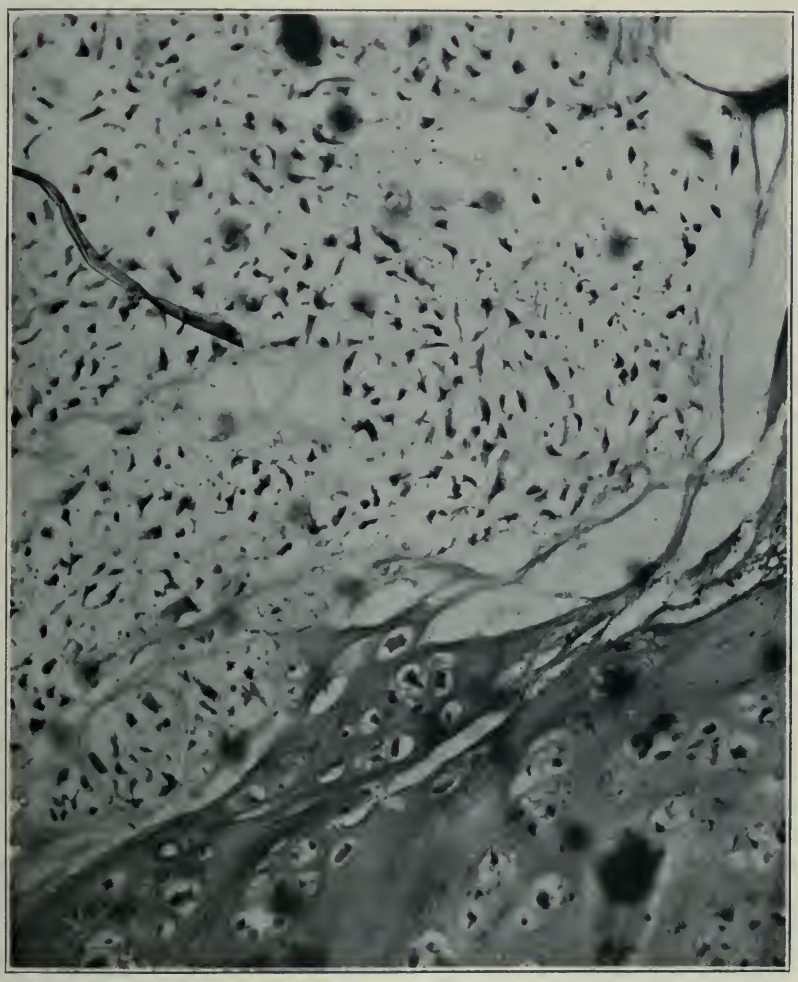

Fig. 11 (Case 2).—Microscopic section; myxochondroma (March 10, 1922).

sensory distribution of the median nerve and atrophy of the opponens and abductor muscles of the thumb. The Wassermann and Bence-Jones reactions were negative.

Third Operation (March 15, 1923).—The myxochondroma was removed. It was attached to the periosteum of the bone graft. The operative area was cauterized with actual cautery.

Summary.—A man of 51, always healthy, with a history of Colles fracture of the left wrist and rheumatism, had had a growth about the left wrist, either on the ulna or radius since 1916. It had been removed surgically, usually very thoroughly, with portions of the bone, seven times, with recurrence within six months as a rule. The growth consisted of cartilage, and in one specimen an area of myxomatous tissue was found.

May 15: There was no evidence of recurrence on very complete examination.

Bloodgood [3] called attention to the recurrence of apparently benign tumors after piece-meal removal and after enucleation. Such tumors as lipomas, intracanalicular myxomas, mixed tumors of the parotid and especially myxomas and myxochondromas of bone were included in the list. Numerous reports of recurring chondromas of bone may be found in the literature (De Witt Stetten,[4] Dittrich [5]). It is likewise known from animal experimentation that embryonal cartilage cells survive and grow better than any other transplanted normal tissues. Case 2 is, then, not unique in this regard. The clinical course in a middle-aged man covering a period of seven years is not that of a malignant growth. The repeated recurrences indicate that either complete removal has never been accomplished or that the tumor is potentially a very actively growing type. Pathologic studies do not bear out the latter hypothesis. The roentgen-ray examination of this tumor revealed irregular outgrowths of bone from the periosteum in a direction perpendicular to the shaft, with isolated deposits of bone in the soft parts; and the suspicion of periosteal sarcoma would be entertained by most roentgenologists, if no knowledge of the clinical history were at hand. The periosteal bony strands are, however, a little coarser than those seen in the general run of sarcomas.

With respect to the matter of frequent recurrence of chondromas after local removal, particularly after the so-called shelling out of these tumors, which has been emphasized by Bloodgood, it is of interest to seek for an explanation. A rational explanation would seem to be based in part on the fact, referred to above, of the ready transplantability of cartilage cells. In studying the sections of the tumor under discussion, it has occurred to us that an important additional factor is furnished by the peculiar structure of the peripheral portions of these tumors. On examination of the slides, one is struck by the fact that the cartilage cells and matrix extend to the edge of the chondroma nodule and that there is an entire absence of a true capsule in the sense of a fibrous or connective tissue periphery adherent to the tumor proper.

Chondromas may be covered with periosteum or merely with a capsular structure analogous to the perichondrium of normal cartilage.

---

3. Bloodgood, J. C.: Ann. Surg. **72**:712-725 (Dec.) 1920.
4. Stetten, D.: Ann. Surg. **71**:200, 1920.
5. Dittrich: Deutsch. Ztschr. f. Chir. **172**:178-192, 1922.

Even in the chondroma, this covering may be composed of dense fibrous tissue. It is striking in the sections of this case that no such fibrous layer exists and that the tumor cells may in places be seen to extend to the edge of the growth. Where this is not the case, the periphery consists of either young (embryonal) cartilage cells or else clear hyaline cartilage matrix.

That the importance of the peripheral structure of chondroma has been realized before is indicated by Ewing's [2] statement (page 184): "To account for the invasive properties, one must assume that the active growth and infiltrative properties reside in the undifferentiated cells of the periphery of the cartilaginous nodules."

These facts seem to emphasize the importance of more careful study of the so-called "encapsulation" of benign tumors. Often it has seemed to us in these and other tumors that there is no real "encapsulation" in the sense of a fibrous covering and that many times the word circumscribed might be better applied. It is generally admitted that often the capsule is adventitious, representing the varying degree of reaction of adjacent tissues or even the approximation of such tissues (as periosteum) without "reaction" in the sense of a multiplication of connective-tissue cell layers.

The presence of myxomatous tissue in the tumor tissue removed at one of the operations in this case is a point of interest. A greater tendency to recurrence as well as to metastasis has been attributed to this histologic complication by Bloodgood.[3] It has also been thought that when once myxomatous tissue appears in a chondroma of bone, it is very apt to appear regularly in the recurrences. It should be noted that this latter possibility has not prevailed in the three recurrences in turn in which the growth was removed by Dr. Morton following the removal of the growth which contained myxomatous tissue.

The question of the proper treatment in this case is one that cannot be decided easily. Bloodgood [3] would have us amputate when myxomatous tissue is found and recurrence takes place, unless his views have been modified by further experience. Many reports of repeated local operations with final cure lend support to the more conservative approach to the problem. Chemical or thermal cauterization of the operative field should undoubtedly follow excision in every instance.

Case 3.—*History.*—L. M., a baker, aged 30, admitted to New Haven Hospital, Nov. 10, 1920, with the complaint of a "broken leg," two months previously (September, 1920), fell from a bicycle and broke the left femur about 6 inches (15 cm.) above the knee. He was in a hospital for a month and then was discharged but remained in bed at home. Two days before admission, while getting out of bed with the aid of a crutch, he lost his balance and fell, breaking the femur again. A physician was called, and a posterior plaster-splint was applied before the patient was sent to the hospital.

Physical Examination.—The patient, a well-developed man, lay quietly in bed. The general physical examination was negative. The left thigh was encased in a plaster cast open in front and extending as high as the crest of the ilium. There was no evidence of swelling about the knee. There was an old fracture at the middle of the femur, with a small amount of motion at this point. There was 1¼ inches (3.2 cm.) of shortening of the left leg. The vital signs were normal. The urine showed a slight trace of albumin; also calcium oxalate crystals, but was otherwise negative.

Roentgen Ray Examination.—There was an old fracture of the left femur 20 cm. from the lower end. The lateral view revealed overriding of about 2.5 cm. There was marked callus formation, particularly on the outer side.

Blood taken for the Wassermann test was reported four plus for both alcoholic and cholesterinized antigens.

Treatment.—The patient was given a course of neo-arsphenamin, starting with 0.3 gm. and increasing to 0.6 gm. Treatments were given twice a week, six doses in all, with no apparent reaction.

November 24: A plaster spica was applied.

December 3: A roentgen-ray examination revealed fairly marked callus.

December 11: The patient had complained of pain in the left knee for the last two or three days. A small window was cut in the cast.

December 14: Roentgen-ray examination revealed that the position was approximately the same as on December 3. Callus formation was well marked.

December 23: A course of mercury and iodids was started.

Jan. 13, 1921: The cast was removed, January 12. Slight effusion in the knee was noted. The leg was fixed on a posterior splint. Roentgen-ray examination was requested and the condition was reported to be the same as on last examination.

January 25: The patient had been up in a wheel chair for several days.

January 27: The splint was removed. There was good bony union. The swelling at the knee noted, January 13, was more marked. There was a rounded, tense, fluctuating tumor about 2 inches (5 cm.) in diameter just below and internal to the patella. It was not painful, tender or reddened and did not pulsate. Flexion of the knee was limited to about 20 degrees. The patella was floating and could be balloted. There was slight lateral mobility of the knee joint, but no crepitus. The patient had no fever. Examination suggested effusion into the knee joint.

January 28: Roentgen-ray examination revealed considerable swelling of the soft parts on the inner side of the left knee. The lower end of the femur appeared to be fairly normal. The patella was normal in appearance and position. The joint space was considerably increased in width. There was almost complete destruction of the inner side of the head of the tibia, extending down the shaft approximately 6 cm. The cortex in this area had been destroyed, and there was no evidence of any bone production. Extending into the soft tissues was a rather diffuse, hazy area of increased density. The lateral view was negative except for some joint haziness. Diagnosis of sarcoma of the inner head of the tibia, of very malignant type, was made (Fig. 12).

January 28: A distinct pulsation was demonstrated in the tumor. By aspiration, about 5 c.c. of blood was obtained with difficulty. Culture of this blood showed *Staphylococcus aureus.*

January 29 (Note by Dr. J. M. Flint): "The patient when seen just after admission for refracture of the soft callus showed nothing abnormal about the knee. His leg was taken from the cast by the present observer and the mobility

at the site of the fracture elicited. The record of the onset of the present condition is in Dr. Smith's note. There is marked swelling over the inner aspect of the knee, beginning at the internal condyle of the tibia, 5 cm. below the tuberosity and extending up above the patella. The tumor measures approximately 15 by 20 cm. It extends backward to the edge of the popliteal space. This is soft and elastic and pulsates distinctly on pressure. Compression of the femoral artery stops the pulsation. Aspiration withdrew blood with difficulty and it clotted immediately. There is no bruit or thrill, over the most prominent part of the tumor. The roentgen ray shows a clean cut erosion of the entire internal condyle of the tibia which just escapes the joint surface.

Fig. 12 (Case 3).—Destructive process of the upper inner condyle of the tibia. There is no evidence of giant cell tumor.

There is apparently no effusion in the joint. Roentgen-ray examination shows no abnormal separation of joint surface or elevation of the patella. There is no periosteal reaction or new bone production. The picture does not look like a bone cyst but more like an extremely rapidly growing endosteal sarcoma."

January 31: The limb over the most prominent portion of the tumor measured 36 cm. in circumference at a point 3 cm. below the lower edge of the patella. The pulsation was even more apparent than before. Aspiration withdrew blood which clotted but did not appear to be in an open cavity.

Operation (February 3): Dr. Duffy performed midthigh amputation. The growth, which was cut down upon, appeared to be just below the internal lateral ligaments of the knee, and was quite cellular in appearance; obviously, a malignant type of sarcoma.

March 17: The patient had been about in a wheel chair for several weeks. There was a very slight bloody discharge from the lateral end of the scar. The patient's condition was greatly improved, and he was discharged.

June 1, 1923: The patient was alive and well, and had had no trouble since amputation.

Pathologic Examination.—In the head of the tibia just below the articular surface of the knee joint was a large mass about the size of a baseball. Its largest transverse diameters were about 5.5 by 7 cm. The specimen was fixed in Kaiserling's solution by injection through the popliteal artery and had well preserved color. The tumor appeared to be well encapsulated except where it was invading the bone, and there the advancing edge was rather diffuse. The tumor was practically against the popliteal vessels, only 1 or 2 mm. of tissue separating them. The color was a yellowish brown mottled with hemorrhagic areas from pinpoint size to 3 cm. Several cystic areas measured up to about 3 cm. in diameter and were filled with gelatinous material. The specimen did not have the appearance which is understood to be usual in the benign giant-cell tumor and did not resemble currant jelly so far as I was able to determine. The tumor had destroyed the head of the tibia and pressed upward directly on the cartilage of the knee joint (Fig. 13). A number of specimens were taken for microscopic study.

Grossly, one would not expect the presence of a great deal of fibrous tissue, and the impression, as at operation, was that the growth was malignant.

Microscopic examination: The capsule was very thin, varying from 0.1 mm. to 3 mm. in thickness, and composed of fibrous tissue. No place was found where it was definitely broken through, although there was some infiltration of its inner layers in a few places. A few fragments of cartilage were seen; often in relation with the capsule, sometimes isolated in the interior of the neoplasm.

The striking features of the tumor when viewed under the lower power were (1) the number and relatively uniform distribution of the giant cells, which are of the typical epulis type, and (2) the marked vascularity shown by the presence of numerous capillaries, sinuses, venules and occasional larger vessels, up to 5 mm. in diameter. In the case of one of the last, the close relation of the tumor cells was evident. These could be seen infringing on and in masses jutting into its lumen. The circumscription of the mass of red blood cells in the latter argued against this being a hemorrhage. Elsewhere, a number of hemorrhages were to be seen, and in several instances these were in various stages of organization by young cells of the fibroblastic type, rather myxomatous often times in appearance.

The small blood sinuses which dotted the low power field were similarly in close relation with the surrounding stroma or giant cells, which occasionally seem definitely to compose the sole limits of such blood spaces.

The giant cells seemed of the type characteristically present in the benign giant-cell tumors. But it is well established that the question as to whether these tumors are benign or malignant must be largely determined in each instance by the growth propensities of the cells of the stroma (i. e., the cells between the giant cells), as manifested by their appearance of malignancy or benignancy. In this case, the growth was at first considered benign; but on further study of the stroma cells, there was evidence that the stroma was more active than in the typical benign tumor: there were (1) the increased vascularity and intimate relation of tumor cells with the lumina of blood vascular spaces; and (2) occasional mitoses present in the stroma.

The stroma varied from a tissue composed of rather mature fibroblasts to one in which fibroblasts were quite young, and cells approaching the type characteristic of spindle and round cell sarcoma were found. In these areas, the structure was rather similar to that in a case of "malignant hemorrhagic

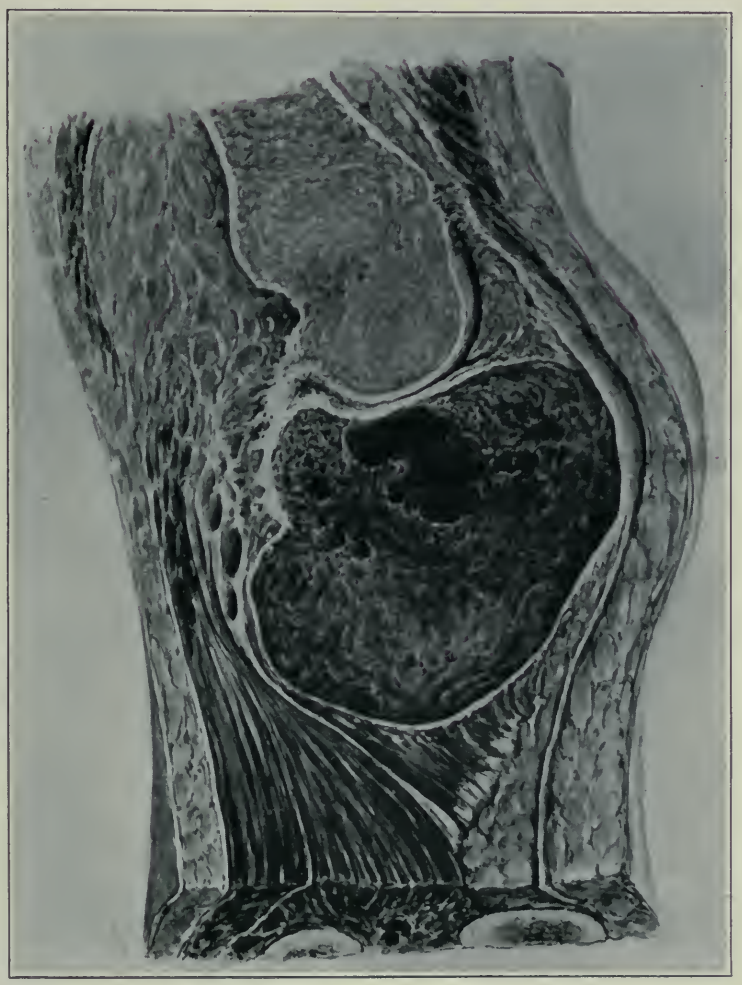

Fig. 13 (Case 3).—The tumor extends to the joint cartilage above and rests posteriorly on the popliteal vessels. There are cystic areas in the tumor.

bone cyst" reported by Bloodgood[6] and shown in Figure 23 of his publication on "Bone Cysts, Benign and Malignant."

In places, medium or large polygonal cells containing large numbers of unstained highly refractile granules were present in considerable numbers.

6. Bloodgood, J. C.: Proc. Alabama M. A., 1919.

These were identified as the so-called xanthoma cells which Ewing[7] has noted as occurring in giant-cell tumors, or sometimes as the chief type of cell (xanthosarcoma). This feature must be counted a relatively unusual one; although possibly when present only in small numbers, they may be overlooked (Fig. 14).

A diagnosis was made of giant-cell tumor of borderline type, with areas of xanthosarcoma, possibly malignant.

From a clinical standpoint, this patient presented a most confusing problem. While in a plaster cast, under treatment for a fractured femur, he developed a tumor near the knee joint which, in spite of the splinting, grew quite rapidly and pulsated. Pulsating bone tumors are as a general rule of malignant character (bone aneurysm of Bloodgood; telangiectatic sarcoma of Ewing). Bloodgood[8] states, however, that pulsation occurred in a giant cell tumor operated on by Halsted some years ago. The roentgenogram in our case, also, revealed a destructive process which completely eroded the upper inner portion of the tibia. The rapid course, the pulsating character, the roentgenogram, the cellular appearance at operation, and especially the vascularity —all favored a malignant process. We did not appreciate until after the specimen was dissected that the pulsation was probably entirely transmitted because of the relation of the popliteal. The fact that this patient had a four plus Wassermann reaction may have had some influence on the course of the tumor.

The pathology is interesting. The neoplasm seems definitely a borderline case between benign and malignant. It is a variant of the giant cell tumor, atypical in its marked vascularity and presence of xanthoma tissue (xanthosarcoma?). Ewing[7] states that this feature when associated with the giant-cell tumor usually indicates a more progressive tumor. All of these facts seem to correlate fairly well with the clinical history and physical findings.

Amputation was performed in this case because the process was thought to be malignant. In view of subsequent study, a frozen section diagnosis based on a single fragment of tumor would have given little aid and might have been a positive disadvantage if a relatively acellular area had been chosen. It is an open question whether or not amputation is indicated when a benign giant-cell tumor practically encroaches on a weight-bearing joint. Ewing has questioned the curetting of such tumors as he has seen quite a number of infected useless joints following this procedure. Such a sequel would indicate faulty operative or dressing technic, and without doubt the dead space is largely responsible for such an outcome. Resection and grafting seem to be a more logical

7. Ewing, James: Review and Classification of Bone Sarcomas, Arch. Surg. **4**:485-533 (May) 1922.

8. Bloodgood, J. C.: Ann. Surg. **52**:175-176, 1910.

choice for this class of case and weight-bearing could be handled by a walking caliper splint. From an economic point of view, amputation is the best short cut available.

Case 4.—*History.*—L. C., a boy, aged 2½ years, admitted to New Haven Hospital, Feb. 13, 1917, with the complaint of tumor of the right thigh, and whose

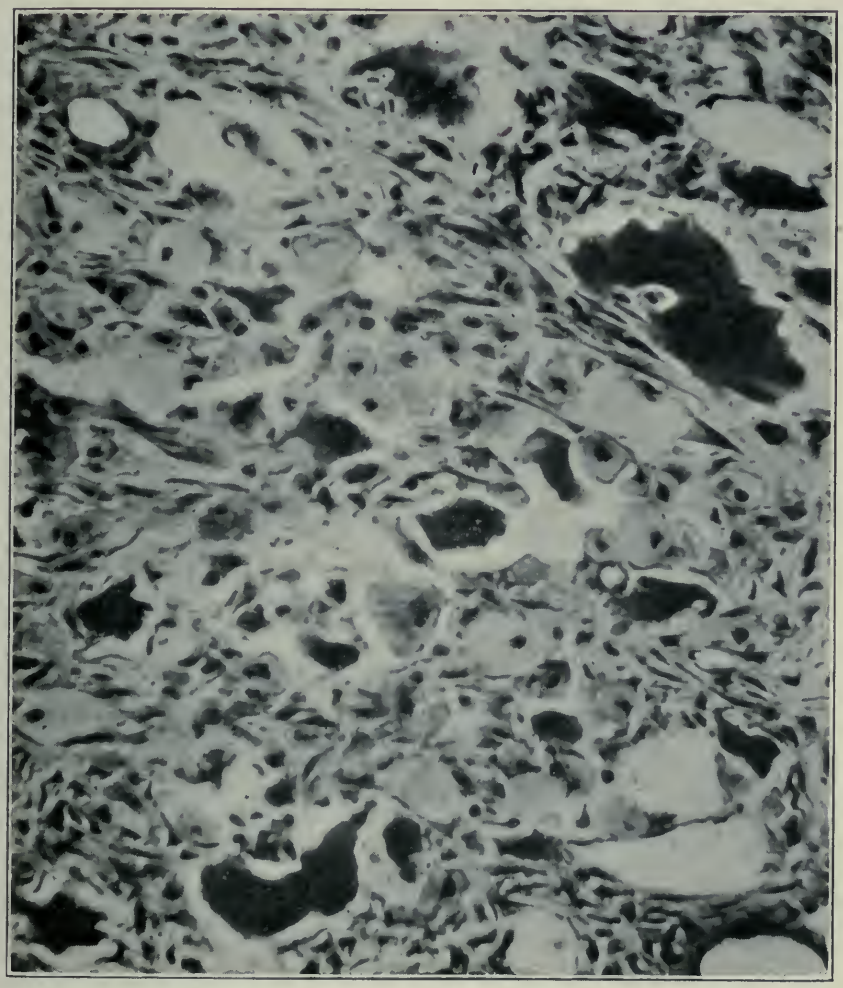

Fig. 14 (Case 3).—Numerous large cells with clear cytoplasm, containing refractile lipoid granules which are not here apparent, are present throughout the central portion of the photomicrograph. These are the so-called xanthoma cells. (Nuclei of giant cells retouched.)

family and personal history were unimportant, four months previously (November, 1916), fell on the floor and struck his leg. His mother noticed a small swelling on the lower part of the right thigh and took him to a physician for

treatment. The swelling went down somewhat but did not disappear entirely. One week later, the boy seemed well and was able to walk. Two months previously (January, 1917), he fell again, and the leg reacted as previously. February 8, five days before admission, he fell a third time, as if the leg were weak. The swelling became much greater and he was taken to Gaylord Farm for roentgen-ray examination. On entry, the boy was unable to walk and cried out as if in pain. The swelling seemed to be increasing in size and was tender. The child had always been well except for this illness.

Physical Examination.—This was negative except for the local condition. The right thigh presented a definite tumor at the lower half above the knee. There was no reddening or evidence of inflammation, although the surface temperature was increased. The tumor was firm and did not give an egg-shell crackling on pressure. It extended up to the middle of the femur. The knee joint was apparently free. The child did not appear to be particularly well nourished. There were a few palpable glands in the right inguinal region. Urine examination was negative.

On admission, the temperature was 99 F., the pulse rate, 100. Roentgen-ray examination revealed a markedly enlarged lower third of the femur just above the epiphyseal line. The cortical bone was thinned out. There were a few fine trabeculae within, dividing the growth into many chambers. The outer shell was markedly thinned at the medial posterior angle of the growth about 5 cm. above the epiphysis, and the tumor there appeared to invade the soft parts (Fig. 15).

Operation (February 15).—Amputation of right thigh was performed, through the middle third.

March 4: The patient was discharged from the hospital. The drains were all out, and the wound was clean. Healing was by first intention. There were no signs of inflammation. The general condition was good.

June 1, 1923: The boy was well, with no signs of malignancy.

Pathologic Examination.—Gross pathology (Fig. 16): The cystic structure began 0.5 cm. above the lower epiphyseal line of the femur and extended up the shaft of the bone for a distance of almost 7 cm. The shaft of the bone throughout the involved area was expanded to a maximal width of 4 cm.; whereas, the normal width of the shaft above the pathologic area is 1.5 cm.

The pathology was that of a multilocular cyst with smoothly lined cavities varying from a few millimeters up to 2.5 cm. in diameter. The cavities were lined throughout by a smooth surfaced wall, which varied in thickness from 0.5 mm. to 1.5 cm. In the Kaiserling and oil-preserved specimen, the color of the wall still remained to some extent, and varied from a dark yellow-gray to a reddish yellow. There were some blood clots present in the cysts, but the fluid content had escaped, leaving no record of its character. There was no apparently granular or friable tissue except blood clot, or any appearance which excited suspicion of malignancy. The diagnosis was benign bone cyst of the lower third of the shaft of the femur.

Microscopic examination: Sections from the cyst wall showed characteristic osteitis fibrosa tissue, in which there was a large amount of poorly developed or degenerating cartilage. This was laid down in the form of interlacing trabeculae, the interstices of which were filled with connective tissue of the fibroblastic type. There was no definite myxomatous tissue present. The picture presented resembled that in Bloodgood's[6] publication on bone cysts

(Fig. 12, page 21). Indeed, if one were not familiar with the roentgen ray and gross appearance of the area involved in this case, it would not be difficult to make the incorrect diagnosis of malignancy. The structure differed somewhat from myxochondrosarcoma. There were no mitoses and hyperchromatism was not striking (Fig. 17).

Fig. 15 (Case 4).—Many chambered cavity limited to the diaphysis, with a break in the cortex posteriorly.

It is interesting to note that the cartilage scattered through the wall of osteitis fibrosa tissue is at a distance of several centimeters from the epiphyseal line (Fig. 17).

Microscopic examination confirmed the diagnosis of benign bone cyst of the shaft of the femur.

The finding in a child of a central tumor in a long pipe bone following an injury would call for conservative procedures according to the knowledge that we have today. If, in addition, the roentgen-ray picture was that of a many chambered cavity sharply limited to the diaphyseal side of the shaft with the cortical shell well preserved or fractured, the most probable diagnosis would be benign bone cyst. Such a case calls for curetting or collapse of the cystic cavity, or even noninterference. In Case 4, all the foregoing features seem to point to such a conclusion,

Fig. 16 (Case 4).—The multilocular cystic cavity with the expanded cortical bone at either side. The thin bone shell may be noted.

and yet amputation was performed. The clinicians must have been influenced by the run-down appearance of the child and the thinning out of the cortical shell posteriorly as shown by the roentgen ray. This was probably interpreted as invasion of the soft parts by the tumor. Such cases of malignancy in apparently benign bone cysts have occurred.[9]

9. Meyerding: Personal communication to the authors.

Bloodgood [10] states that, in a number of cases of bone cysts with osteitis fibrosa, a diagnosis of malignancy had been made from the frozen section. In none of Bloodgood's cases in children under 15 years was the subsequent course that of a malignant tumor, although in only one case had the operating surgeon proceeded on the diagnosis

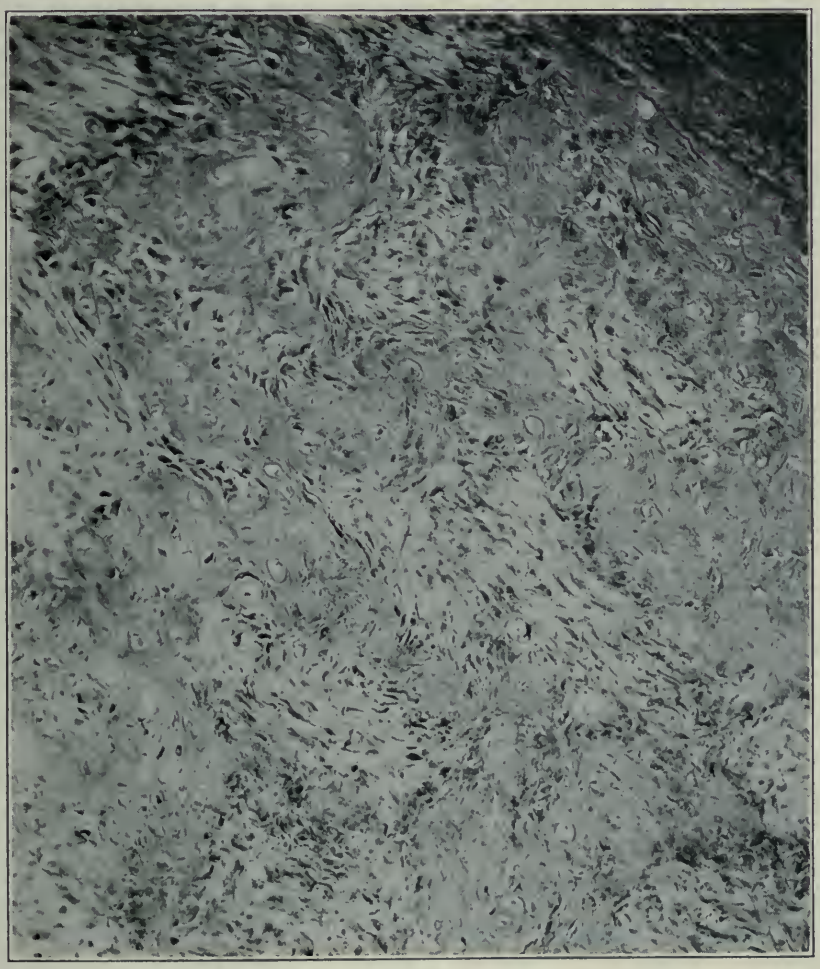

Fig. 17 (Case 4).—Cartilage trabeculae in osteitis fibrosa lining of cyst cavity; section from block taken several centimeters from epiphyseal line.

of malignancy from the frozen section, and performed an amputation. The danger of an incorrect microscopic diagnosis is great, unless correlated with the gross picture in this type of case.

10. Bloodgood, J. C.: J. Radiol. **1**:147-241 (March) 1920.

Case 5.—*History.*—A. A., a boy, aged 8 years, admitted to the New Haven Hospital, May 21, 1915, with a complaint of pain and swelling of the right thigh, and whose family history and personal history was negative, three weeks previously (May 1) had been pushed by a boy and had fallen on a railroad track, striking the inner side of the right thigh against the rail. He thought the knee was injured, but walked home.

Physical Examination.—The general findings were normal. The local process consisted in a large round swelling, 10 cm. by 15 cm. in diameter, under the vastus internus muscle on the anterior internal aspect of the right thigh, 20 cm. above the patella. The mass felt hard and firm, with a slight amount of elasticity about the edges. There were no pulsations or thrills, and the popliteal artery was easily palpated.

Roentgen-ray examination revealed an elevation of the periosteum, with the shadow of either a large hematoma or an abscess, and nothing suggestive of periosteal sarcoma. The temperature was 98; pulse, 110; respiration, 20. The blood count was: white blood cells, 11,800; polymorphonuclears, 73 per cent.; lymphocytes, 22 per cent.; mononuclears, 4 per cent.; eosinophils, 1 per cent.

May 22: The swelling was aspirated and about 5 c.c. of fresh blood was obtained. A culture showed no growth.

The patient was not seen again till July 24, when the following note was made: "The tumor has increased considerably in size, now extending for some distance under the popliteal space, where it is quite firm and hard. A roentgenogram shows very distinct ossification of the periosteum around the upper and lower margin together with a little parallel striation which simulates sarcoma. There is considerable destruction of bony substance on the inner aspect of the thigh."

July 25: The patient was discharged, unimproved, against advice.

October 5: He was again admitted to hospital. The tumor broke down and became an open sore after he left the hospital. It increased rapidly in size up to two months previously, when the patient was forced to go to bed. Since then, the sore had not grown much larger, but the leg was quite painful.

On examination of the right leg, over the vastus internus muscle chiefly, almost midway between the knee and the thigh there were two ulcerated open wounds, approximately 10 by 8 cm. in diameter. There was a very foul discharge and no suggestion of formation of healthy granulations or indications of healing.

October 13: Roentgen-ray examination revealed pathologic fracture at the junction of the middle and lower third of the right femur. The lower half of the bone was swollen. The structure was more or less destroyed. The periosteum was thickened and elevated. The upper third of the bone seemed to be normal. Urinalysis revealed a slight trace of albumin. The Bence-Jones reaction was positive. Casts, pus, white cells and red cells were not found.

October 21: The Wassermann reaction was negative.

Operation (October 21).—Amputation of the right thigh was performed, incision being made on either side of the thigh. The tumor appeared malignant, and the condition was confirmed by frozen section. The leg was amputated just below the trochanter by circular incision, and was closed with a drain (Fig. 18).

October 30: The drain was removed. There was no infection. A dry dressing was applied.

November 23: The patient was discharged, the wound having healed.

September 21, 1916: The patient was admitted for a third time. Since leaving the hospital, he had remained well until within the last three weeks, when he noticed that the stump was gradually becoming swollen, although painless. He felt well otherwise.

Examination revealed: no mass in the abdomen; liver edge not felt; spleen not palpable; no evidence of involvement of lungs. A high thigh amputation of the right extremity had been performed. The scar was well healed. There was an uniform enlargement of the stump without tenderness. The skin was slightly reddened, and the superficial veins were dilated. There were no palpable glands.

Urine examination, September 23, was positive for albumin, but no Bence-Jones bodies were reported.

October 12: The patient was discharged to Dr. Coley in New York for treatment. The condition was absolutely inoperable, the roentgen ray showing that the growth had extended to the head of the femur and very probably beyond. We lost trace of this patient.

Pathologic Examination.—Gross pathology: It may be noted here that neither of us had any first hand or other information of the case except that contained in the foregoing history; and also that the frozen section from which the diagnosis of sarcoma appears to have been made originally evidently was not preserved, and there was no positive evidence of tumor in celloidin sections of the original blocks.

The museum specimen consists of one half of the bisected lower three-fourths of the femur, with the upper one fourth of the tibia attached. The color was not well preserved (Kaiserling's solution and oil).

The soft parts over the fracture (Fig. 19) were swollen and involved by two large irregular ulcerations 6 and 4.5 cm. in diameter, respectively, and separated by a narrow bridge of skin and subcutaneous tissue. The ulcerations were deeply excavated (to a depth of 1 cm.), but the skin edges are not undermined.

The cut surface of the femur showed an increase of the normal antero-posterior bowing. At the point of greatest angulation, no definite fracture was seen in the half of the bone at hand. The periosteum was intact throughout, but beneath it on the posterior surface of the femur there was a zone of new growth of bone resembling normal callus which extended 6 cm. to either side of the level of the point of greatest angulation. Near the upper limit of this callus, it was softer and had a slightly moth-eaten appearance.

The medullary canal of the bone appeared to be obliterated for a distance of 6 cm. This appearance was due apparently to a sclerotic process rather than to the section having missed the medullary canal. This was confirmed by dissecting away the periosteum and comparing the thickness of the bone here and elsewhere. Throughout this sclerosed area were small irregular clefts, suggesting an inflammatory process. No pus was encountered anywhere in the bone and no sequestration.

The specimen was divided transversely through the ulcerated area down to the shaft of the bone and the latter dissected away. The soft parts in the neighborhood of the ulcers suggested only an inflammatory process. One purulent collection 1 cm. in diameter was found just below the base of an ulcer.

The periosteum was found to strip easily from the bone, leaving a surface of moth-eaten appearance, involving the entire convex surface of the lower one half of the shaft. On incising a small prominence in the soft parts just over the periosteum, we were surprised to expose the cut surface of what appeared to be a tumor nodule 1.8 by 1 cm. This area was soft, gray with red mottling

and slightly granular on the cut surface, resembling somewhat a lymph node, save that its periphery was slightly convoluted and its surface a trifle granular. It resembled malignant tissue and lay immediately upon the periosteum, but seemed distinct from the latter.

In résumé, it may be stated that until the nodule described above was found, more or less by chance, the gross appearance seemed to be essentially that of a low grade chronic osteomyelitis.

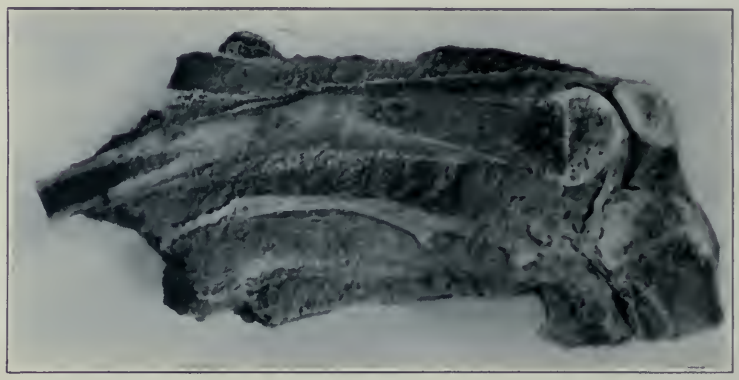

Fig. 18 (Case 5).—The gross specimen showing angulation of the bone and increased bone formation with a posterior periosteal reaction.

Fig. 19 (Case 5).—Roentgen-ray appearance of specimen shown in Figure 18. The bone appears moth-eaten. There is a fine shadow of new bone posteriorly.

Following miscroscopic examination of the previously described nodule which in the gross gave suspicion of malignancy, we again examined the gross specimen, for we had as yet secured no evidence of malignancy in the bone itself. The nodule referred to above came from outside the periosteum. Blocks were accordingly secured from the soft, crumbly, rather reddish tissue beneath the periosteum, about 4 cm. above the location of the nodule. This tissue had been inspected before and classified as normal or infected, rather vascular or hemorrhagic callus.

With regard to the question of fracture of the femur as shown by the roentgen ray, we must note that, on bending the stripped femur, we were unable to secure any false motion.

Microscopic Examination: A section from the soft parts and ulcerated area of the thigh showed only chronic and subacute inflammatory changes. The usual pyogenic inflammatory exudate was present, with no evidence of tuberculosis or syphilis. Toward the ulcerated surface of the thigh, the picture of a vascular granulation tissue was especially marked. The ulcer surface was divested of epithelium.

The section examined contained portions of four separate blocks of decalcified bone. Histologically, these showed no definite trace of tumor formation. Sections from two of the smaller fragments showed some evidence of a chronic and subacute inflammatory process involving the periosteum as well as cortical and medullary bone. The lack of involvement of some entire blocks as well as the apparent histologic appearance seemed to indicate a nonfulminating, low-grade, chronic inflammatory process.

Sections of the suspicious nodule found lying on the periosteum showed a solid cellular growth composed of small polyhedral cells. There was no supporting connective tissue stroma for the great majority of cells, which lay free in sheetlike masses containing a few blood vessels and occasional delicate fibrous trabeculae. There were scattered areas of necrosis present involving small masses of cells 0.25 to 0.5 mm. in size.

The blood vessels present supported adjacent tumor cells which were rather consistently arranged radially from the smaller vessels. The character of the cells indicated a malignant tumor, as evidenced by fairly frequent mitoses, as many as three appearing in a single high power field. The tumor cells had very small amounts of clear cytoplasm and generally vesicular nuclei. The appearance was that of an endothelioma described by Ewing[7] as "diffuse endothelioma of bone" (Figs. 20 and 21).

Sections from the soft callus-like material and superimposed periosteum showed definite malignancy of the same character as that noted above. The periosteum was infiltrated by the small polyhedral or round type of cell, and on the underside of the main layer of periosteum were large areas made up of similar cells. The only bone present consisted of small fragments within the layers of the periosteum itself or of fibrous trabeculae extending from the main periosteal layer (Fig. 22).

With regard to the tumor cells, we were again impressed with the lack of connective tissue stroma except in relation to the periosteum. Blood vessels were scarce in the tumor tissue, but it is an interesting fact that vascular spaces containing red blood cells occurred lying surrounded by tumor cells without any definite vascular walls.

The final diagnosis was endothelioma of the femur (the diffuse type of Ewing), apparently subperiosteal in origin, associated with fracture, chronic osteomyelitis and extensive chronic infection of soft parts and ulceration of skin. There was a mestastatic extraperiosteal nodule.

The difficulties in diagnosis are well brought out by a review of the history. On the patient's first visit to the hospital, three weeks after injury, there was a hard elastic swelling of the thigh and no signs of infection. The roentgen ray revealed a slight elevation of the periosteum and nothing else of note. Under the circumstances, a diagnosis of hematoma was warranted as there was nothing to indicate an actual

malignant process. The importance of a thorough followup is evidenced by the rapid progress of the growth in the two months after discharge from the hospital. The diagnosis of a bone tumor was established by the roentgen-ray picture and the clinical findings when the patient was seen the second time. Unfortunately, we could not find the roentgenogram in this instance; but a picture of the specimen after amputation shows a mottled destruction of the shaft, with a fracture, cortical thickening about this area and a fine deposit of subperiosteal callus posteriorly (Fig. 19). The surgeon explored the growth, considered

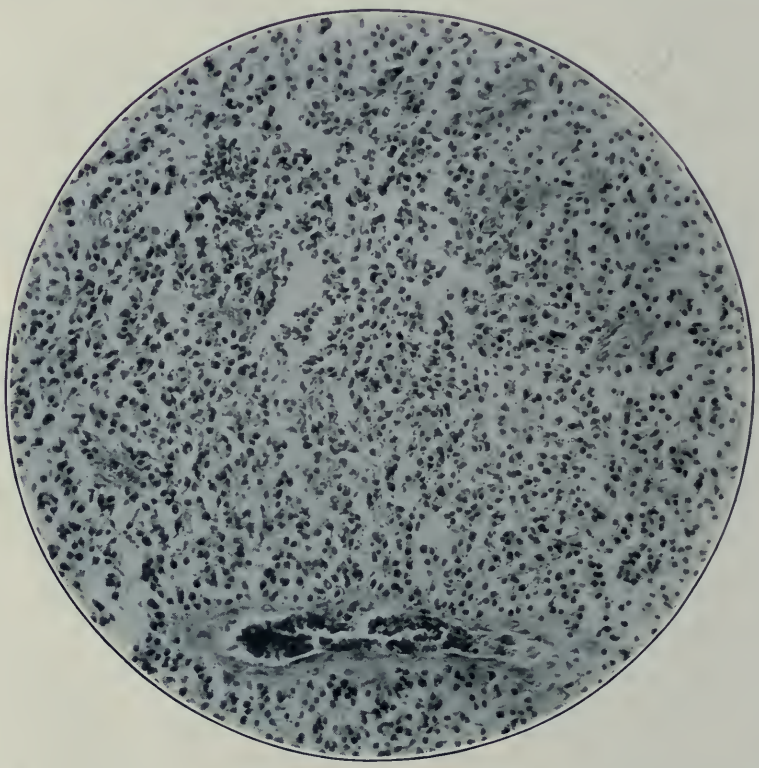

Fig. 20 (Case 5).—The small polyhedral or round cell with poor staining cytoplasm and absence of connective tissue stroma may be noted. The small blood vessel shows very closely associated tumor cells.

that the grayish islands of infiltrating tissue were sarcoma, and amputated. The frozen section confirmed the operator's judgment. The presence of two ulcerations of the thigh and infection, and the roentgen-ray picture, which might easily be interpreted as that of osteomyelitis, might offer another difficulty in differential diagnosis. The tumor mass with the induration of the soft parts would serve to rule out an infection of the bone, and the lack of a marked general reaction

would be an additional support. Bence-Jones bodies give further assistance, although not pathognomonic for bone tumor. If this tumor could have been diagnosed with accuracy as of periosteal origin, most of the modern writing would favor nonsurgical interference, but a course of radiotherapy. Coley would certainly advise the use of toxins as well. We feel that the pendulum is swinging perhaps a little too far toward conservatism.

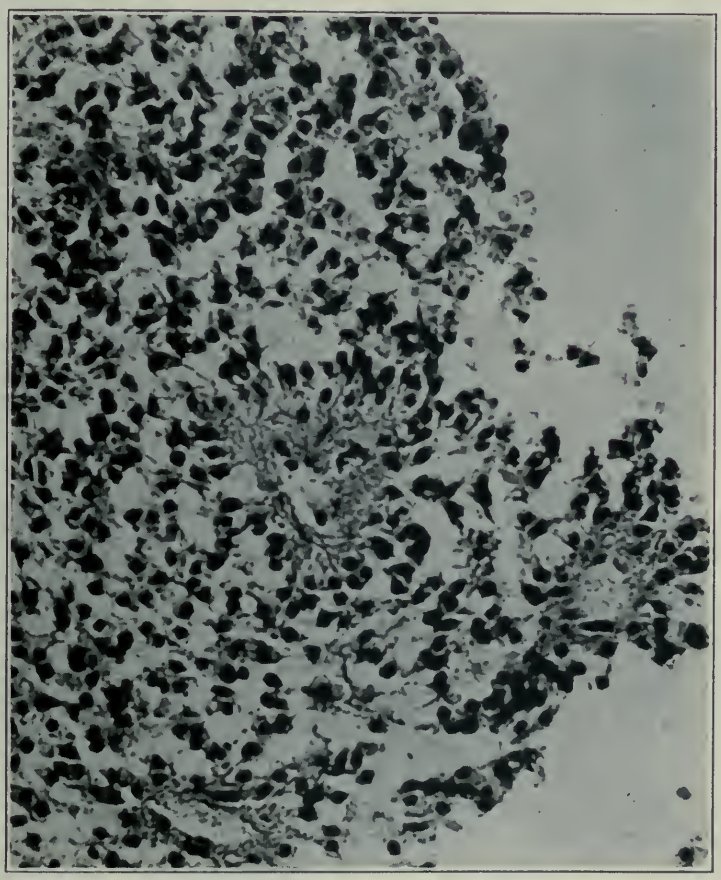

Fig. 21 (Case 5).—Radiation of cells from the small central blood vessel, which shows hypertrophy of its lining cells.

The questions as to the relation between the various manifestations of this case are by no means absolutely clear even in the light of the pathologic findings. 1. Did the tumor bear a causal relationship to the fracture which occurred? 2. What caused the extensive superficial ulceration opposite the point of fracture? 3. Was the infection of bone and periosteum related to the fracture? 4. Was the latter a compound

fracture? 5. Could there have been a subperiosteal infection dating from the time of the primary injury when no fracture, but only elevation of the periosteum, was determined roentgenographically? 6. Was the malignant process present before the original injury noted in the clinical history?

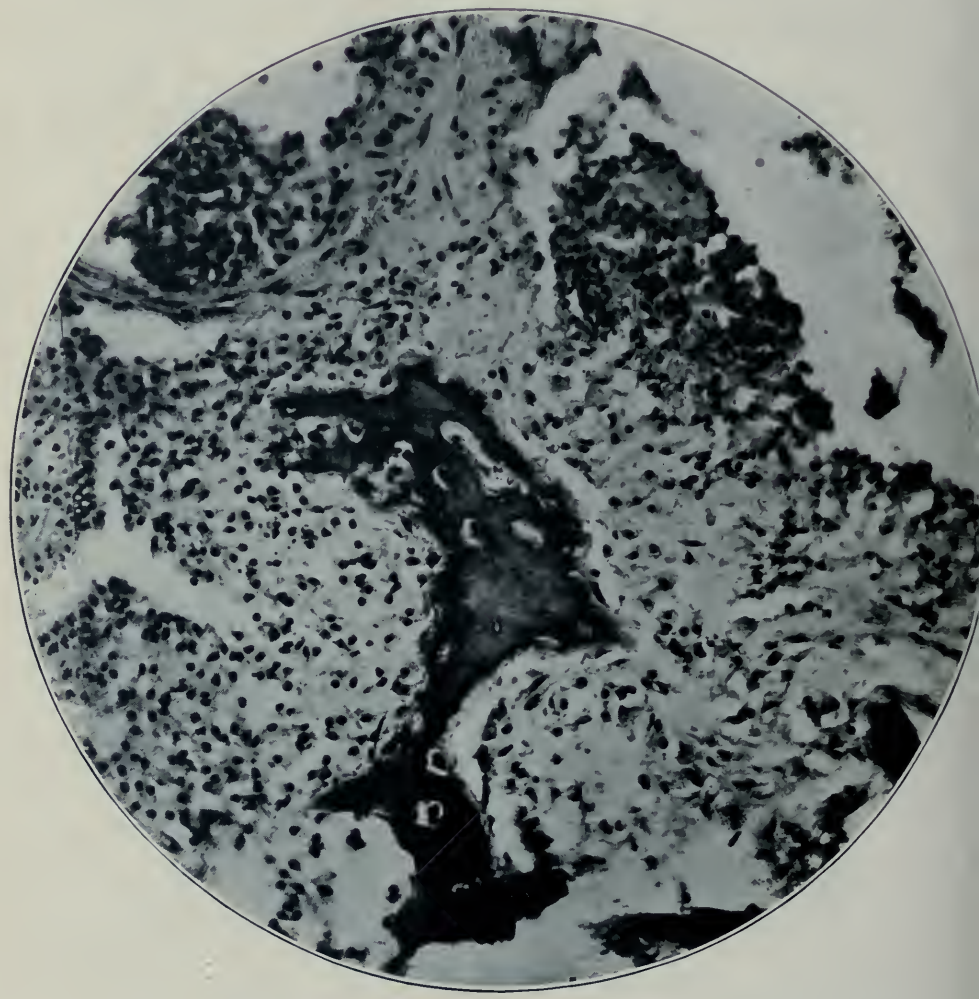

Fig. 22 (Case 5).—An island of periosteal bone partly surrounded by tumor cells.

These questions involve both clinical and pathologic data, many of which are lacking. With regard to the pathologic findings, we may in brief review these questions.

From the lack of extensive involvement of the shaft of the bone as determined by gross and microscopic examination, the tumor probably

did not cause the fracture. The demonstrated involvement by neoplasm was chiefly in a narrow zone beneath the periosteum. Also, it has been noted that firm bony union seems to have occurred.

With regard to questions 2, 3 and 4, it may be stated that, in view of the pathologic findings, it seems fairly reasonable to assume that the fracture occurred shortly after the patient's discharge from the hospital unimproved or about three months before his final admission. It seems improbable that the fracture was compound in view of the good union, with only slight angulation. However, infection might have been caused at this time by the injury (of which we have no knowledge) that caused the fracture. It was then that the ulcers appeared and continued to enlarge. We have no means of knowing what rôle his treatment at home may have played.

With regard to Question 5, there is evidence that there was quite a swelling (10 by 15 cm.) present three weeks after the original injury (less than six months before operation). At this time, elevation of the periosteum was noted, and hematoma or abscess was suspected from the roentgenogram. Instead of gradually subsiding, the swelling steadily increased in size, for, two months later, the swelling (which it may be recalled had been determined pathologically to consist largely of inflammatory tissue, and with absolutely no tumor tissue "breaking down"—the clinical interpretation) had "increased considerably in size, now extending . . . under the popliteal space where it is quite firm and hard." At the same time, "destruction of bone on the inner aspect" of the femur was noted in the roentgenogram.

From the foregoing facts, we feel that both inflammatory and neoplastic processes must have become active within a few weeks after the original (?) injury, or at any rate the injury which first directed attention to the thigh.

It seems impossible to say whether the malignant process antedated the original injury as noted in the clinical history. The apparent association of a low grade osteomyelitis with endothelioma of bone is a most interesting one. Ewing [7] states that "competent observers firmly maintained" that some of his cases were osteomyelitis. But in the case under discussion, we have microscopic evidence of osteomyelitis, in association with the tumor which seems to us very similar in its histology, clinical course and roentgenographic appearance to the type of lesion so ably described by Ewing as diffuse endothelioma of bone. Possibly the case we report is unique in having a proved associated infective element.

The tumor described is one which many pathologists still might call a small round-cell sarcoma. Its histologic and roentgenographic characters seem to resemble very closely the diffuse endothelioma of bone

described by Ewing. In this connection, we are glad to express our appreciation of his efforts at clarifying this little known entity.

Case 6.—*History.*—E. P., a railroad laborer, aged 20, admitted to the New Haven Hospital, Nov. 8, 1920, with a complaint of pain in the right shoulder, about ten weeks previously was lifting heavy stones, his usual occupation, when he felt a sharp pain in the shoulder. He continued with his work, but the pain persisted. This continued for several days, when he consulted a physician, who gave him a liniment. This did not help him. About four weeks before admission, there was tenderness in the shoulder, but no noticeable swelling and no elevation of temperature. There was loss of motion, particularly abduction. The arm was put in a Sayre bandage, which relieved the pain. Six days before admission a swelling was first noticed. It gradually increased in size. The patient had a fever on the day of admission.

Physical Examination.—The patient, a well developed, well nourished man, lay quietly in bed, seemingly suffering no pain. There was no enlargement of the glands of the neck. The points of interest centered in the local examination. The right shoulder was definitely swollen and was held lower than the left. The skin covering it was normal in texture and moist. The surface temperature was higher than on the opposite side. The shoulder showed evidence of strapping with adhesive, and over the scapular region and on the back there was a marked papulopustular eruption where the strap had been fastened. The enlargement of the shoulder was globular and smooth and firm to the touch. It involved the head of the humerus completely. The clavicle and acromion seemed to be unaffected. The insertion of the pectoralis major and latissimus dorsi could not be palpated, seeming to enter the hardened mass. The glands of the axilla were not enlarged or tender. There was, however, exquisite tenderness on deep palpation over the whole of the enlargement. Motion of the arm was limited in all directions. The patient complained of pain on slight pressure and abduction of the arm. Measurements were: around the shoulder from axilla over acromion, right, 18 inches (45 cm.), left 14½ inches (36.3 cm.); neck of humerus, right, 11½ inches (28.8 cm.), left, 10 inches (25 cm.); at epicondyles of humerus, right 8½ inches (21.3 cm.), left, 8½ inches.

There was no impairment of the muscular action of the forearm or fingers (Fig. 23).

November 10: The tumor was aspirated. A few drops of bloodlike fluid were obtained. It was sent to the laboratory for culture. Later, the swelling was again aspirated and the needle pushed against the bone in two places. About 20 c.c. of dark blood-stained fluid which clotted very slowly was obtained. A smear of this fluid showed no organisms when stained with methylene blue and carbol fuchsin. With blood stain, it showed ordinary white blood cells. No red cellular débris and no tumor cells were found.

November 12: The culture from aspirated fluid was reported negative.

November 15: Dr. Duffy reported that sections of clot of aspirated fluid showed no tumor cells.

November 16: Measurements were: round shoulder, axilla over acromion, right, 19½ inches (48.7 cm), left, 14½ inches (36.3 cm.).; around neck of humerus, right, 14 inches (35 cm)., left, 10 inches (25 cm.)

Roentgen-Ray Examination (November 8).—The soft tissues of the shoulder particularly on the upper and outer portions showed some enlargement. The glenoid cavity and bone of the scapula surrounding the cavity were increased

in density, somewhat hazy and irregular. The anterior head of the humerus and upper portion of the humerus showed some irregularity and haziness in outline. There seemed to be a definite area of destruction in the outer portion of the head. The cortex in this position had been destroyed. On the inner side, opposite and just below the glenoid cavity, there are two areas of rather decreased density. There was also an area on the inner surface, 9 cm. from the upper end, in which the cortex had been destroyed and the medullary cavity appeared to be somewhat mottled. The lower half of the humerus appeared to be normal (Fig. 24).

Fig. 23 (Case 6).—Appearance of patient on admission to hospital.

November 12: Examination of the chest was negative. Repeated examination of the shoulder showed approximately the same condition, with some slight advancement.

The diagnosis was: acute destructive process, probably malignancy, although the picture is atypical; probably medullary sarcoma of the round-cell type.

November 19: The blood was typed as of Group IV.

Operation (November 19).—Dr. Flint performed an interscapulothoracic amputation of the right shoulder, by Le Conte's method.

December 11: The wound healed and the patient was able to be up. He complained of some pain in the region of the scar and constant severe pain referred to fingers of the amputated limb.

December 20: The patient was discharged. He was feeling well and his general condition seemed very good. He had slight pain at times in the scar. There were three small areas not covered with epithelium.

Vital Signs.—The patient entered the hospital with a temperature of 101 F. and a pulse of 105. Respirations were 20. The fever for the first week remained

Fig. 24 (Case 6).—Destruction of head of humerus and dense shadows in the soft parts.

constantly elevated above 100 F. and reached a point as high as 104 F. It was practically of a continuous type. The pulse rate gradually fell during the first week from 110 to 80. During the second week of his stay previous to operation, the temperature was of an intermittent type, going from normal to 102 F., and dropping back to normal. The pulse rate remained constantly at 80. Following operation, there was a slight postoperative rise in temperature and pulse, with a gradual subsidence to normal, which continued throughout the remainder of his stay in the hospital.

Laboratory Findings.—Urine examination (on two occasions) revealed nothing of importance except a slight trace of albumin and an occasional hyaline cast. Test for Bence-Jones bodies on two examinations were reported negative.

Blood examination, Nov. 9, 1920, revealed: white blood cells, 21,800; polymorphonuclears, 77 per cent.; large mononuclears, 10 per cent.; small mononuclears, 13 per cent.

November 11: White blood cells numbered 14,600; polymorphonuclears, 81 per cent.; large mononuclears, 9 per cent.; small mononuclears, 10 per cent.

November 16: The white blood cells numbered 9,800; polymorphonuclears, 75 per cent.; large mononuclears, 9 per cent.; small mononuclears, 14 per cent.

The Wassermann reaction, November 9, with alcoholic and cholesterinized antigens, was negative. Culture from aspirated fluid showed no growth.

Pathologic Examination.—A huge tumor about the size of a grapefruit, involving the upper end of the humerus, had broken through the head of the humerus at the point indicated by the roentgen ray. The tumor was very vascular in certain places, but there was not so much blood in it as would be expected from the aspiration.

The specimen was divided longitudinally. Similarly, the humerus itself was split and the medullary cavity of the latter was found to be filled with tumor almost the entire length. There was also a pathologic fracture of the upper third (Fig. 25). In spite of the presence of fracture, there was no expansion of the shaft. The absence of this feature, with preservation of the cortical bone everywhere save in small areas, together with the radiate arrangement of much of the tumor tissue from the periosteum, indicated that we were dealing with a periosteal rather than a medullary neoplasm. Many blocks were taken for microscopic study. The blood vessels were dissected out and the axillary vessels were found to be compressed. The axillary glands were greatly enlarged, some of them being suspicious, but there was no positive gross evidence of lymphatic involvement. Marked dilatation of the collateral blood vessels was noticed in one area.

Microscopic examination: A preliminary section was diagnosed spindle-cell sarcoma. In all, fifteen blocks were taken and sections from these were studied microscopically. The growth was a spindle-cell sarcoma, with slight tendency to the round-cell type in places. The latter areas, however, were rare, and throughout the greater part of the tumor the characteristics conformed rather clearly to the spindle-cell type. Mitoses were fairly numerous, perhaps slightly more so in the areas with round-cell tendency. A striking feature was the degree of vascular involvement by the tumor cells, which in many places composed the wall of the vascular spaces, definite tumor cells encroaching on the lumen of the vessel (Fig. 26). In one place, a large cell containing a mitotic figure was seen free within the lumen of the vessel. Sections of the axillary lymph glands showed no definite metastatic involvement, although one gland had a suspicious area, which was by no means definite sarcoma. A striking thing about the appearance of the lymph glands was the degree of vascular dilatation. This was probably the result of collateral circulatory changes.

The final diagnosis was: periosteal spindle and round-cell sarcoma.

Second Admission (December 25).—The patient returned to the hospital four days after his discharge because of pain across the upper abdomen and sometimes in the left lower chest. He attributed this to overeating. He had a temperature of 103 F. on admission, but the temperature fell and reached normal four days after entrance and he felt much better.

Examination showed dulness over the lower third of the left side of the back. This did not extend into the axilla. Fremitus was slightly diminished over the lower left side of the back as compared to the right. No change in the breath or voice sounds was noted, and there were no râles. Elsewhere, there were

normal resonance and breath sounds, and no râles. The incision of the old operation was well healed, except for two small spots where epithelization was not complete. At the root of the neck on the right, there was a small area about the size of a quarter, which was sensitive even to very light pressure. Otherwise there was no tenderness about the scar. There was no induration. The white blood count, on admission, was 16,000. The urine was negative except for albumin.

Fig. 25 (Case 6).—From a drawing of the specimen removed at operation. The lack of expansion of the bone shaft and the apparent periosteal origin are evident. The fracture of the shaft is shown. The deceptive circumscribed character of the very malignant growth may be noted. The axillary glands (at right) were negative microscopically.

The patient was discharged ten days after admission. The temperature and pulse reached normal on the fourth day after admission. The impression was that the fever was caused by a small patch of bronchopneumonia.

When this man entered the hospital, he had a tumor mass which had all the earmarks of a rapidly developing malignant growth. The clinical course, roentgen-ray findings and pathology all conformed to type in this instance. The patient had fever, which usually indicates the rapidity of the tumor growth; and a further evidence was the local

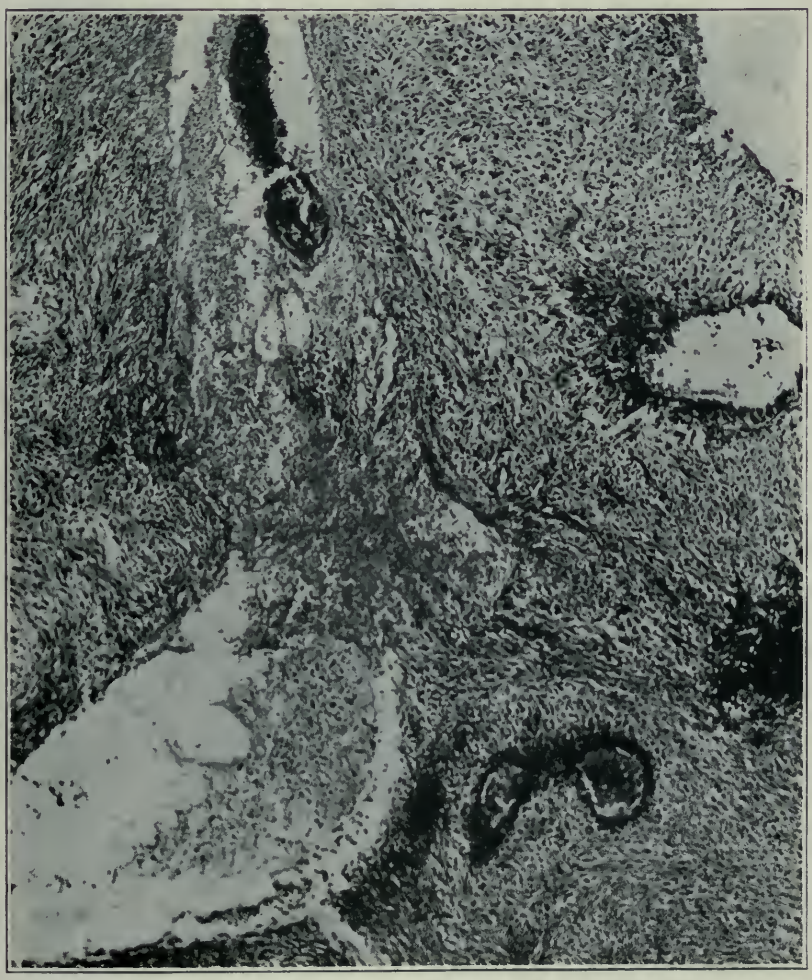

Fig. 26 (Case 6).—Vascular spindle cell sarcoma with invasion of blood sinus by tumor cells at right lower center.

heat, which argues for active vascularity. We would not attempt so radical an operation today from our present knowledge. These osteogenic growths in young people, especially when the upper humerus is involved, give a hopeless prognosis by operation. The pathologic

picture, which shows malignant cells lining blood spaces, proves how futile it is to expect that metastases have not already established themselves. It has been stated that it is often impossible to say definitely whether a given bone tumor originated as a periosteal or as a medullary growth. The gross pathologic process in this case indicated rather definitely a periosteal origin but the growth did not present the typical radiating bony spicules in the roentgenogram. The very rapid progress probably gave no time for the formation of bone.

Case 7.—*History.*—G. K., a man, aged 59 years, was admitted to New Haven Hospital, Aug. 9, 1920, with the complaint of pain and swelling of the right leg, which developed three years previously (1917), when he stepped from a street car and turned the right ankle. At this time, he felt a sharp pain in the lower part of the leg, and a few hours afterward, the leg became swollen and painful. He was unable to use the leg at all for a week. For two weeks, he used crutches. The leg did not bother him after that, although it felt somewhat weaker than formerly. Three weeks previously (July, 1920), while walking on the street, he felt a slight pain in the right lower leg. The leg gave way and he fell to the ground. He got up and was able to walk only with great difficulty. After the fall, the leg became swollen. The next day, he was seen by his physician, who applied a plaster splint. Roentgenograms of the leg were taken, and he was sent to the hospital for operation.

Physical Examination.—The general findings were normal. There was a swollen area about 7 cm. in diameter on the outer side of the right leg, about 7 cm. above the external malleolus of the fibula. This area was hard, tender and continuous with the shaft of the bone. It did not fluctuate.

Operation (Dr. Whittemore).—August 10, the growth on the right fibula was excised.

August 19: The wound was in good condition. There was very slight tenderness over the lower end of the wound in an area about 1 cm. in length. The ankle showed a small amount of swelling. The patient could move the foot in all directions without pain. There was no anesthesia of any part of the foot, and there was no limitation of motion in the ankle joint. The patient was discharged to his local physician for further care.

The vital signs were normal throughout the stay in the hospital.

Laboratory Findings.—The urine was negative. Blood tests revealed: white blood cells, 8,600; polymorphonuclears, 50 per cent.; large mononuclears, 4 per cent.; small mononuclears, 44 per cent.; eosinophils, 2 per cent. The Wassermann tests of the blood were negative to both alcoholic and cholesterinized antigens.

March 16: The patient remained well and reported that he had had no further trouble with the leg. His general health was good. He was able to get around as he had before, and the operative wound had showed nothing of note.

The original roentgenograms were not available. Roentgenograms of the tumor were taken, however, and revealed a destructive lesion of the bone, irregular in outline, extending up the shaft nearly to the line of incision (Fig. 28).

Pathologic Report.—Grossly, the specimen was a small tumor. It showed a portion of the fibula above and below a fusiform shaped tumor. On longitudinal section, the tumor was rather irregularly shaped and of a homogeneous, cellular appearance. The bone was replaced by tumor tissue at the midportion of the specimen, but apparently it did not extend into the bone on either end (Fig. 27).

Microscopic examination: Where the neoplasm lay adjacent to the soft parts, it appeared to have been growing essentially as an encapsulated tumor.

Fig. 27 (Case 7).—The external surface of the tumor, showing the periosteum apparently unperforated by the tumor.



Fig. 28 (Case 7).—Roentgenogram of the excised tumor, showing a destructive process of the bone, with a fairly clear-cut edge in most places but small areas of infiltration in others.

In places, a definite fibrous capsule, varying in thickness from 0.25 to 1.5 mm., showed only a moderate degree of invasion by the cells of the new growth. The fibrous character of this capsule, its absence where the tumor was extending into the shaft of the bone, as well as the presence of striated muscle fibers in its peripheral layers suggested that it was either intact periosteum or else tendon sheath, probably the former.

As just suggested, the absence of encapsulation where the tumor was in contact with the shaft of the fibula was in striking contrast to conditions else-

where. Here, it was entirely without a connective tissue capsule, and its cells were seen to have extended along the haversian canals for a distance of 0.25 to 0.5 mm. Bone destruction here had progressed, without any new formation of bone.

Sections through the central portion of the growth showed a central, quite benign area, 1 cm. or more in diameter, composed of fibrous and myxomatous

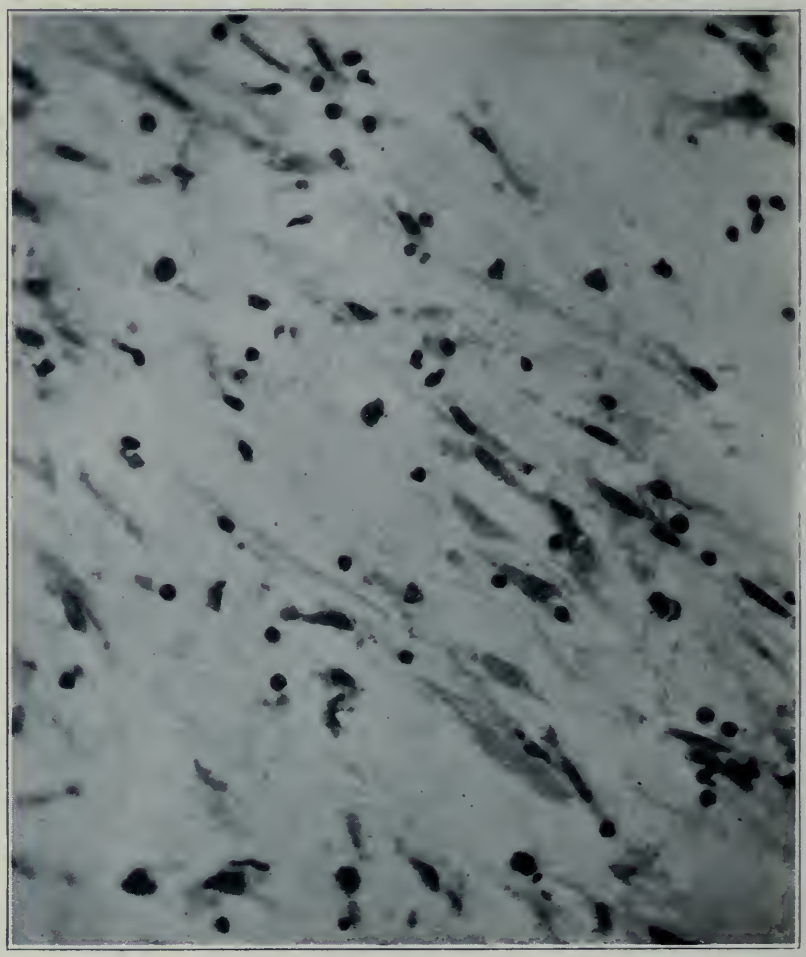

Fig. 29 (Case 7).—A myxomatous area from the central portion of the tumor. There are a few scattered lymphocytes throughout.

tissue, the latter predominating. Here, no mitoses were to be seen, and aside from a scattering of small lymphocytes, no other types of cells were seen (Fig. 29).

At the periphery, this fibrous and myxomatous area, shaded off rather abruptly into the main portion of the tumor, which consisted of spindle cells with relatively little fibrillar substance. Here, one saw a number of mitotic

figures, in some instances as many as five in a high power field, but in general they were few in number. There was relatively little fibrillar substance, and in places the tumor cells showed a slight transition from the spindle shape, becoming ovoid or round. Throughout the bulk of the tumor proper, there was not the hyperchromatism often seen in definite spindle-cell sarcoma (Fig. 30).

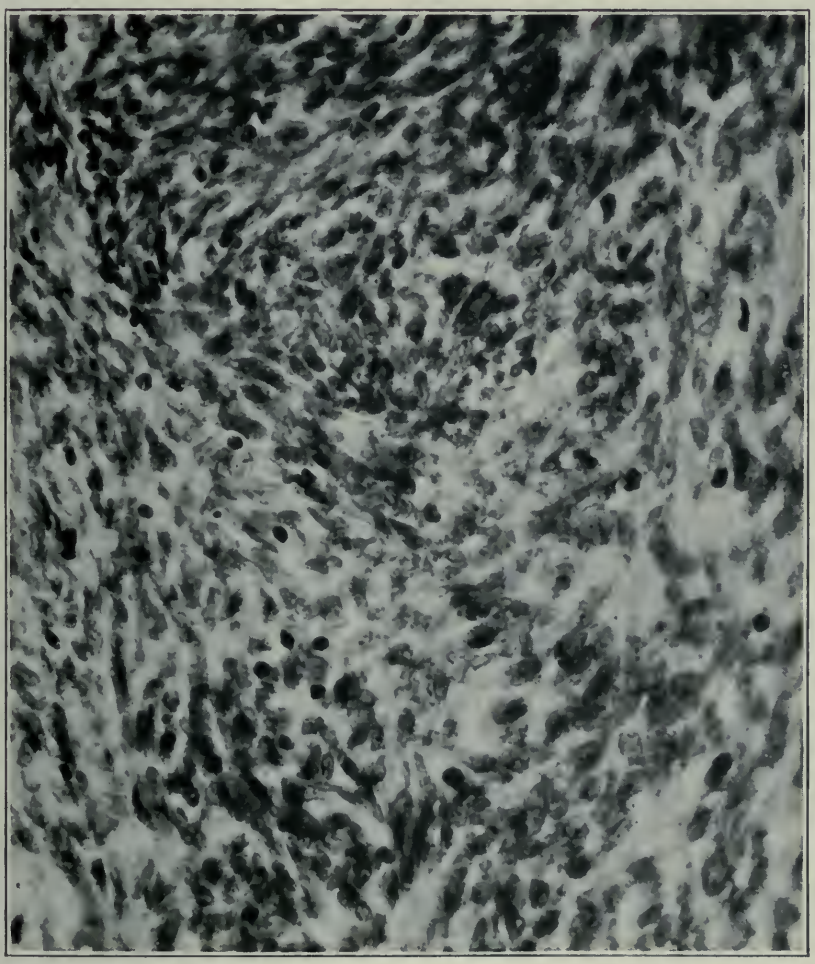

Fig. 30 (Case 7).—High-power photomicrograph of a cellular area; fibrosarcoma.

The relation of the tumor cells was a close one, and in certain areas there was evidence of actual obliteration of small vessels by the ingrowing tumor cells. The evidence of this was particularly striking in one small area where the wall of the venule was practically destroyed, but a few clumps of red blood cells persisted in what was left of the lumen. These were surrounded by ovoid tumor cells.

Giant cells of the epulis type were entirely absent. The only giant cells present consisted of a few osteoclasts in close proximity to bone which was being absorbed.

Only a trace of new bone formation was present in the "capsule" (periosteum?) overlying the tumor. This area was about 0.3 mm. in diameter. Elsewhere, no new bone was found.

One other histologic feature must be noted, the rather marked lymphocytic infiltration occurring irregularly throughout the tumor; sometimes diffuse and sparse, at other places definite small foci composed almost solely of lymphocytes. The significance does not appear obvious. There was a moderate diffuse lymphocytic infiltration in the capsule of the neoplasm.

We are dealing here with a tumor at the junction of the middle and lower thirds of the fibula, in a man of 59 years. The tumor may have been present for some time but gave little clinical evidence till three weeks before admission. The original roentgenogram could not be found, but a plate of the specimen showed that there was a destructive lesion which extended along the shaft both above and below the growth and almost completely eroded the main portion. There was scarcely any attempt at new bone formation. The edges of one side of this tumor were quite sharply demarcated from the cortex. From a frozen section, a diagnosis of malignancy was made: spindle-cell sarcoma. Nevertheless, the surgeon decided on a local resection and gave very little margin. In this, he had the backing of Bloodgood's opinion that, in a central lesion of the fibula, resection is the operation of choice. The result to date, two and one-half years after operation, has attested to the excellent judgment used.

In view of Bloodgood's experience with myxomatous tumors of bone, and his recent statement (1923) that "any bone tumor which contains typical myxomatous areas is for practical purposes as malignant as a sarcoma," this tumor should receive special consideration. Fortunately for study of the histology of the myxomatous tissue, the carefully preserved original frozen sections in this case, made at time of operation, are still available and show the undoubted area of pure myxoma.

It seems apparent that this neoplasm bears certain histologic earmarks of malignancy. That this is not of a high degree, however, is evidenced by the course of the case following local resection. If it were necessary to make a diagnosis from the microscopic examination alone, one would incline toward the side of malignancy. Otherwise, it seems that this was a borderline case.

We have here, then, a tumor which was taken early, as far as the clinical evidence is concerned; was diagnosed as malignant by frozen section; was removed by excision with a small margin, and yet the patient has remained well.

The diagnosis was osteogenic sarcoma, "solid medullary" (Ewing); probably the fibrospindle-cell-fibrosarcoma of Bloodgood (this latter term in Bloodgood's classification is taken to mean a slightly less malignant type than the "spindle cell sarcoma" of bone).

Case 8.—*History.*—A. G., a girl, aged 16 years, entered the Hospital of St. Raphael, March 16, 1923, with the complaint of swelling of the right leg. For the past two years, the right leg had gradually increased in size just below the knee joint on the outer side of the leg. Except for the increasing deformity, there were no symptoms.

Physical Examination.—The general examination was negative. At the upper and outer side of the right leg, there was a fusiform swelling of bony hardness, 7 by 15 cm. in diameter, involving the upper portion of the fibula, with which it was intimately connected. There was a sense of elasticity but no fluctuation or egg-shell crackling could be made out. The tumor was not tender or inflammatory and did not pulsate. The overlying skin and subcutaneous tissues could be moved freely over the growth. There were no vascular or nerve changes.

Roentgen-ray examination revealed a spindle shaped expansion of the head and upper shaft of the fibula with a markedly thinned but intact cortex and delicate bony partitions traversing the expanded area (Fig. 31).

Operation (March 16).—Dr. W. F. Verdi performed a resection involving the upper third of the fibula, and the tumor. The muscles were very adherent to the tumor, which added to the difficulty of removal.

March 19: The patient died from pulmonary embolism.

Pathologic Report.—Gross Pathology (Fig. 32): The excised specimen after fixation in formaldehyd measured 14 by 5.5 cm. in the long and the transverse diameter, respectively. It consisted of an outer bony and cartilaginous shell representing the expanded and partly absorbed shaft of the upper third of the fibula. The bony shell of the tumor measured 0.5 to 3 mm. in thickness and crepitated slightly on pressure.

The interior of this shell bound cavity was filled with tumor material, which extended up to the cartilaginous surface of the head of the fibula and down the shaft nearly to the limit of the excised portion. Extension had occurred through the epiphyseal line, which was entirely obliterated save for a narrow rim lining the interior of the bony shell, about 2.5 cm. from the upper end of the bone. The center of the mass was occupied by cystic structures from 0.5 to 4 cm. in diameter, the contents of which had escaped. Several blood spaces containing clot appeared, up to 1 cm. in size. The cut surface, however, did not look very vascular in a diffuse sense, although the formaldehyd fixation may have affected such an appearance.

The greater part of the tumor was composed of solid cream gray tissue, which was rather soft in consistency. The cut surface was mostly smooth, but was somewhat granular in places. There were several discolored areas due to old hemorrhage, but no definite suggestion of xanthoma.

There was no definite gross evidence that the tumor had broken through the covering shell, although the latter was greatly thinned in places. No large vessels appeared to penetrate the bony shell. No bone trabeculae or areas of cartilage were to be seen on the cut surface. The gross impression was that the growth was probably a benign giant-cell tumor.

Microscopic examination: A thin layer of bone and cartilage varying from 0.1 mm. up to 1 mm. was seen on the peripheral side of the tumor section. This shell was being destroyed, as evidenced by the osteoid appearance of much of the bone, with evidence of absorption by osteoclasts. At intervals, there were apparent small interstices in the bony wall. One of these breaks in continuity was 1 mm. or more in width, and the vascular, rather fibrous peripheral portion

Fig. 31 (Case 8).—Expansion of upper fibula with fine trabeculae across the growth.

of the tumor had extended through the gap (Fig. 33). Other instances of this same phenomenon could be seen elsewhere in the section but the breaks were smaller, and nowhere did the tissue which has broken through extend to the very edge of the tissue removed.

Contrary to the gross impression, the neoplasm contained many small vascular spaces strewn throughout the tumor tissue. The relation of these spaces and

the stroma cells was intimate, as is usual in bone tumors even of doubtful malignancy. The possibility of metastases having already occurred when such a histologic condition is found cannot be easily set aside.

Giant cells were fairly abundant, but not so numerous as is frequently the case in the benign giant cell tumor. Some of these were of the typical epulis type, but many only approximated this type, in that they were smaller, and con-

Fig. 32 (Case 8).—Cut surface of the bisected tumor in the upper third of the fibula. Extension through epiphyseal line above, central cystic areas and thin bone shell may be noted. (For this case history, we are indebted to Dr. William F. Verdi.)

tained only a few nuclei, and the latter were often larger and more vesicular than in the characteristic epulis type giant cell.

The structure of the stroma cells varied in different parts of the tumor. The cells were of the fibroblast type, with well marked fibril formation, shown in

the cytoplasm, indicating a fairly adult type of cell. There were areas, however, in which the cells were of a more embryonic type and more suggestive of malignancy. In such places, as many as three mitoses to a high power field were found. It is of interest that these areas suggestive of malignant appearance were not found in the most peripheral portion of the tumor, where it was destroying the bony shell by pressure and its associated effects.

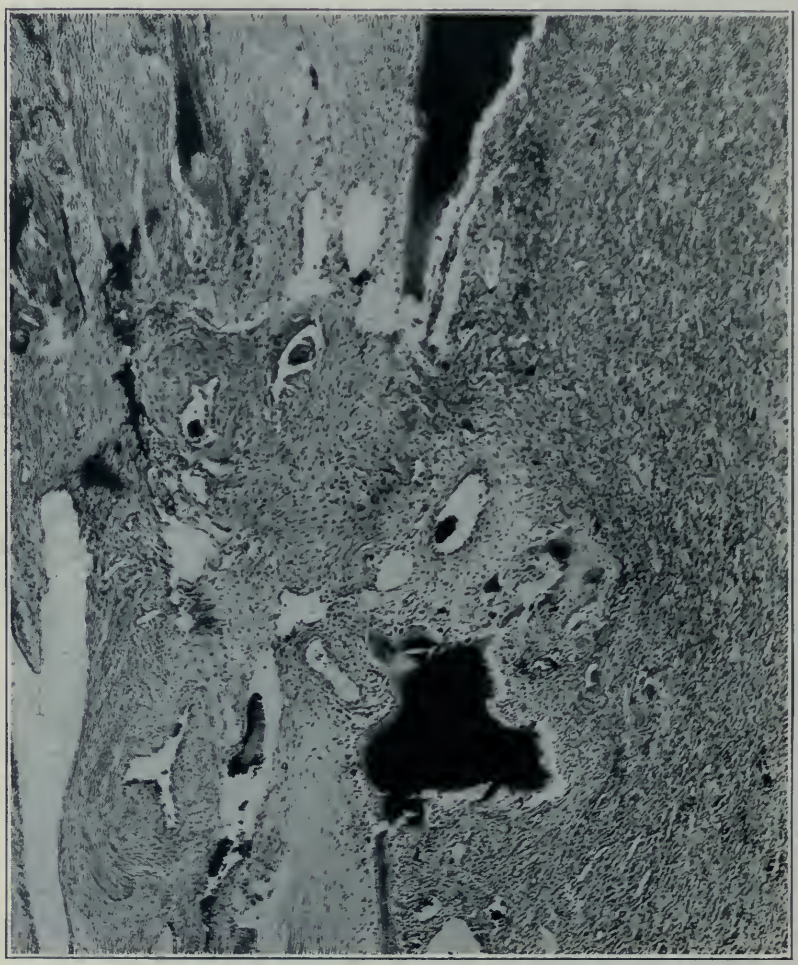

Fig. 33 (Case 8).—Tumor on right. The bone shell is broken (center) and tumor tissue has extended through into the periosteum.

Throughout the preliminary sections studied, there were found unusual hyaline cytoplasmic areas (Fig. 34), from which fibroblastic stroma cells seemed to radiate. These suggested a focal origin of some sort but constituted a picture we had never encountered before in bone tumors. It suggested the somewhat analogous areas of hyaline stroma in acoustic nerve tumors. A study of sections from additional blocks demonstrates that such areas originate

from foci of bone undergoing absorption. Progressive stages in the development of these rosette-like areas of hyaline material were seen, from those in which the center was marked by a blue-stained, usually circular area of bone (Figs. 35 and 36), in which sometimes viable bone cells were still apparent, to those containing no trace of bone tissue but only the clear glasslike pink-staining hyaline material. Here the cellular association was suggested by clear

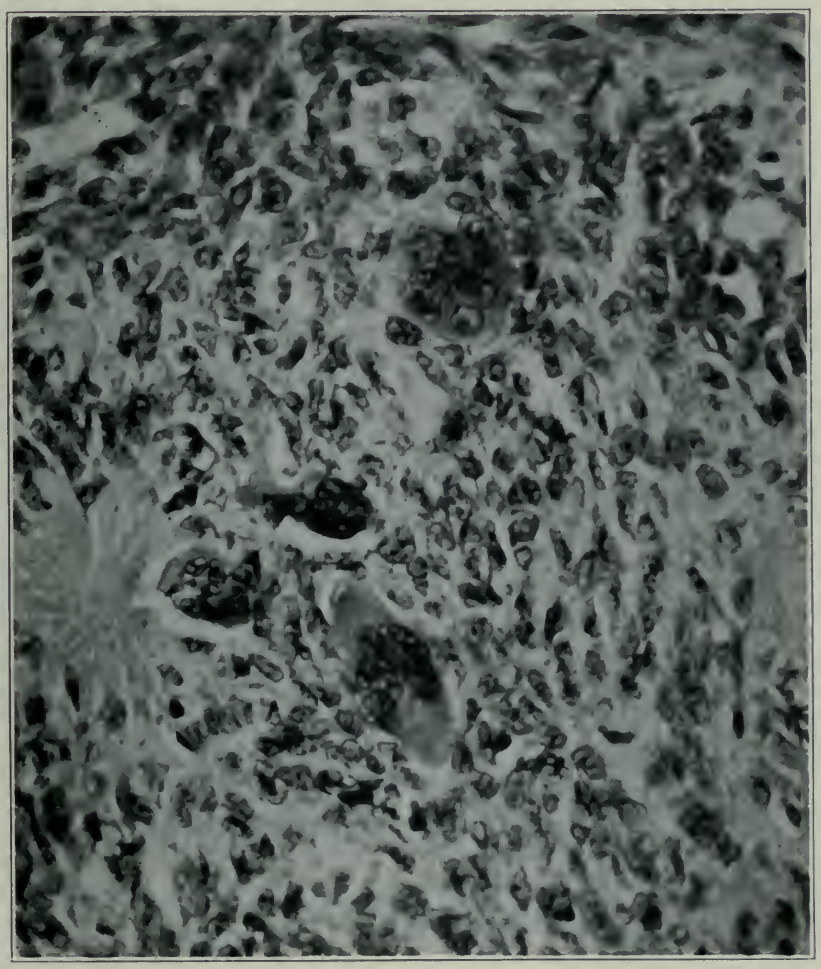

Fig. 34 (Case 8).—Good examples of the giant cells present in this tumor. To the right of the topmost one there is mitosis in one of the stroma cells. A peculiar hyaline area near the left border below the center may be noted.

spaces between radiating segments of the material, as well as by shadows of nuclei occasionally seen in the hyaline portions and viable nuclei adjacent to the periphery of these radiating segments. The nuclei were arranged in line with the long axes of the segments. In intermediate transitory areas, the minute bone fragments contained no demonstrable nuclei and appeared as osteoid

tissue gradually losing its calcium salts. In addition to these small foci of bone, less numerous spicules were seen, undergoing a similar process of absorption. It is of interest that this process appeared to be taking place without the intermediation of osteoclasts.

The final diagnosis was medullary giant cell tumor of an atypical borderline type, probably benign.

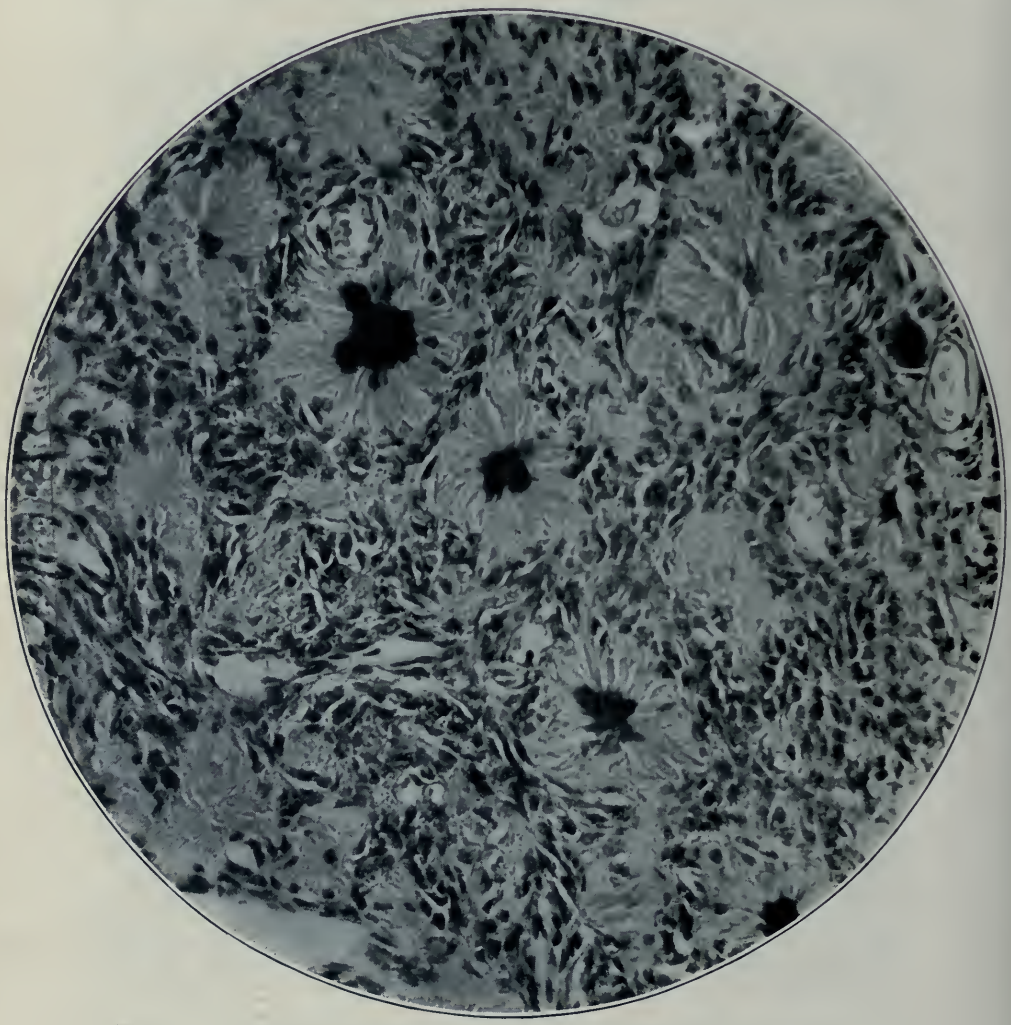

Fig. 35 (Case 8).—Remains of bony trabeculae in central portion of tumor, undergoing absorption by connective tissue cells without action of typical osteoclasts.

This case is of interest because of the age incidence and painless course. Bloodgood [10] states that pain has always been a symptom in his group of cases of giant-cell tumor. Giant-cell tumors, also, are not common at such an early age. The roentgen-ray picture shows the

typical extension completely to the end of the bone and the fine trabeculation across the involved area. The gross picture showed a very light creamy brown color, with areas of cysts filled with blood clot. This brings up the question of the gross appearance of giant cell tumors. We have been taught to look for "currant jelly" areas as an index of giant-cell growths. Both this case and Case 3 were atypical in this gross appearance. Stewart [11] reported a case of giant cell tumor in which

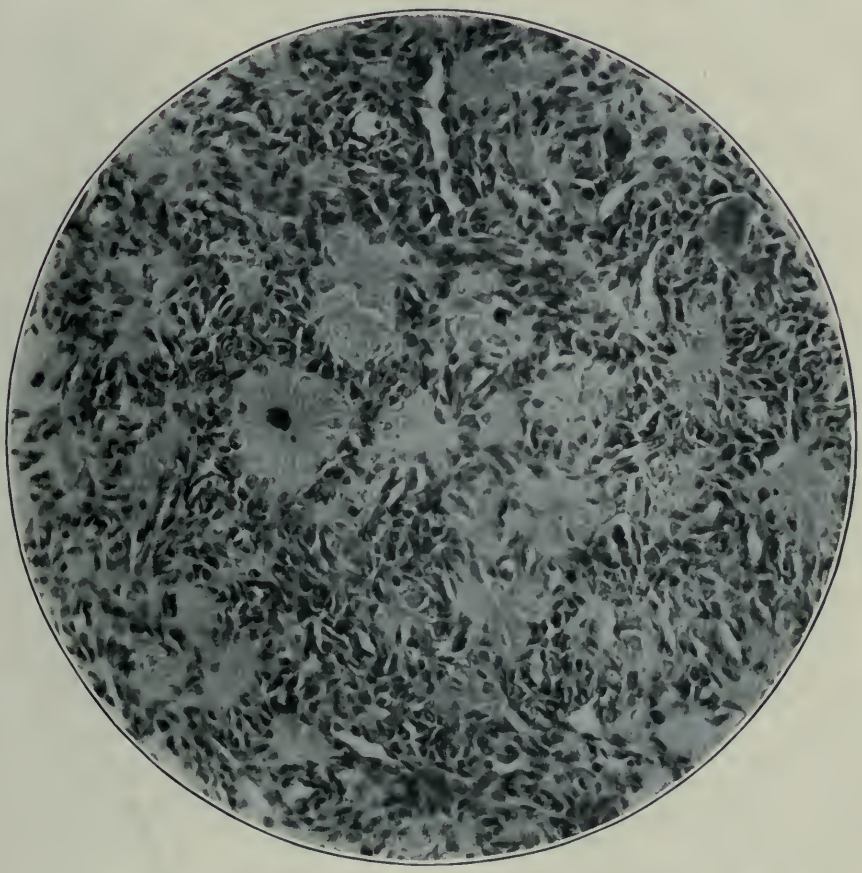

Fig. 36 (Case 8).—Absorption of minute foci of bone nearing completion, leaving roughly circular radiate areas of hyaline tissue. The appearance of this material, with pale vesicular nuclei, peripherally placed, surrounding the minute fragments of bone near the center may be noted.

these areas were white throughout, a character usually given to highly malignant growths.

This neoplasm certainly seems one in which an arbitrary diagnosis for or against malignancy from the microscopic examination alone would

11. Stewart, M. J.: Brit. J. Surg. **10**:322 (Jan.) 1923.

be very uncertain, and in which the gross, roentgen-ray and clinical characters should receive consideration in reaching conclusions. From the standpoint of the gross pathology, the tumor appeared to be a benign one but with evidence of beginning destruction of the bone shell. Microscopically, there were areas suggestive of malignancy, and definite perforation of the bone shell was seen in small areas. In the giant-cell tumor, this latter phenomenon, even when grossly present, has lately been discounted (Bloodgood) as a definite criterion of malignancy.

It hardly seems necessary to emphasize again here what has been so clearly stated by Bloodgood and Ewing, that the character of the stroma cells is the microscopic index of the benignancy or malignancy of the neoplasm, rather than the appearance, number, etc., of the giant cells. Even with this information and some experience, it appears to be impossible to decide definitely one way or the other in all cases. Therefore, it would seem that a definite group of giant-cell tumors of questionable malignancy must be recognized. In these, the clinical features and roentgen-ray findings may bear great weight in the diagnosis. Proper definition of this group can be accomplished only by intensive study of each case, checked by the clinical (ultimate) results.

The peculiar picture presented by minute foci of bone in this case is a unique one for giant-cell tumor.

A frozen section in this instance would cause the pathologist a great deal of worry and the ultimate judgment would probably rest on the surgeon. Resection would seem to have been the logical method of procedure.

Case 9.—*History.*—H. K., a fireman, aged 36, entered New Haven Hospital, Feb. 23, 1919, with a complaint of soreness over the right elbow. Four weeks before (January, 1919), while pulling a carload of coal, he fell, striking the ground with the right elbow. The elbow was only slightly swollen and painful and did not keep him from working. February 19, four days before admission, the elbow became quite painful, and was opened in the accident room. The patient quit working the next day because of pain on motion of the arm. February 22, the day before admission, the elbow was again opened, and the patient was advised to come to the hospital for operation.

Physical Examination.—The patient was well developed and well nourished. The general condition was normal. The right elbow showed an incised wound 3 cm. in length over the olecranon process. The edges of the wound were gaping, and from the center of this wound there protruded a small rounded mass, 1 cm. in diameter, directly over the tip of the olecranon process. The tumor mass was attached to the bone by a firm pedicle. There was considerable induration about the wound. A discharge not purulent, but serosanguinous was present. No bone area was exposed. There was very little tenderness. Movements of the elbow joint were normal and caused no pain. There was no sensory disturbance of the forearm. The wrist and fingers moved normally. No enlargement of the glands in the right axilla was noted.

Operation (February 24).—Dr. Deming excised the tumor of the right elbow. An elliptic incision was made well around the old wound and the superficial tissue and a portion of the olecranon were removed, together with the tumor. The base of the tumor was firmly attached to the bone. This portion was chiseled so that the fragment of bone 2 cm. in length was removed (Fig. 37).

March 8: The wound was healing. There was no discharge and no induration. Movements of the elbow were normal. The patient was discharged, to return to the hospital for dressings.

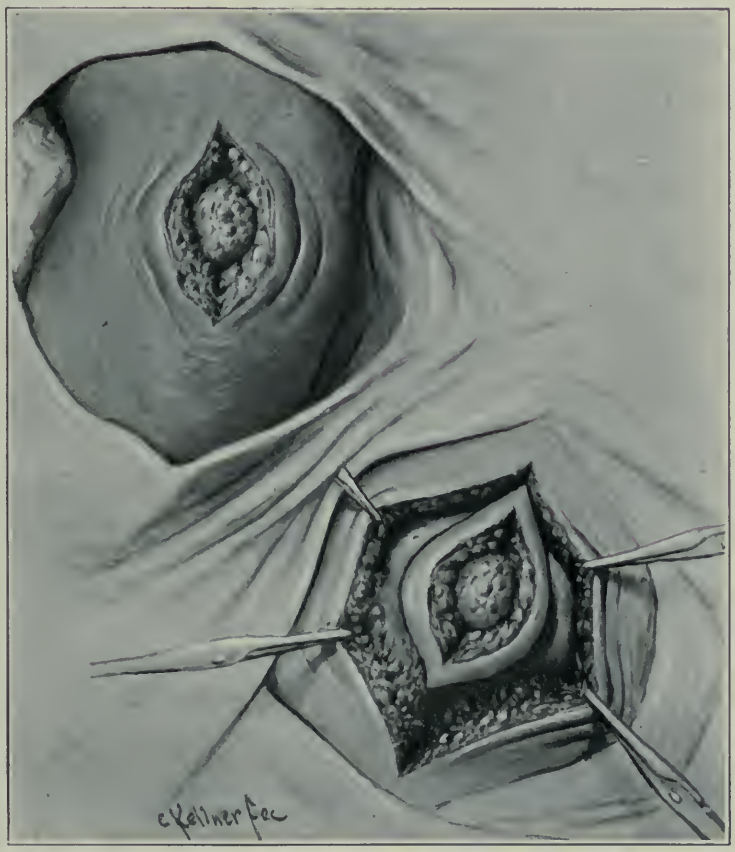

Fig. 37 (Case 9).—Above: Appearance of wound when patient was admitted to hospital. The protruding tumor-like mass is evident. Below: Appearance at operation, showing the amount of skin margin in removal of the mass.

Roentgen-ray examination was negative, except for a small exostosis.

Urine examination was also negative. Blood examination was not made. The patient was lost sight of.

Pathologic Examination.—Gross pathology: The excised mass (preserved in oil) consisted of an underlying fragment of bone 3 by 1.5 cm. in diameter, superimposed on which was a mass of tissue now in its shrunken condition 1.5 cm. in diameter. This was quite firm and fibrous in texture and constituted

the supposed tumor. Just beneath it, a longitudinal section of the bone showed the questionable exostosis which appeared in the roentgenogram. The specimen was excised with a wide margin. There was no definite gross indication of malignancy. One could judge little of the original color from the present color. Blocks were taken through the center of the questionable mass, including underlying bone for microscopic examination.

Microscopic examination: At the point noted as an exostosis in the gross description, new bone formation was seen to be progressing, with corresponding activity of osteoblasts, in one of which a mitosis was seen. The periosteum was somewhat thickened, especially at this point. There was some mononuclear infiltration and an occasional polymorphonuclear could be seen. Extending outward from the periosteum throughout the mass of suspected tumor tissue, one found only a chronic rather vascular granulation tissue with no evidence of a neoplasm or specific granuloma (tuberculosis or syphilis). The bone underlying the periosteum was normal.

Near the periosteum in one area was a cleft in the section filled with red blood cells and fibrin, with beginning organizatin. Whether or not this was the remains of the traumatized bursa, it is impossible to say definitely but it was rather suggestive. No giant cells of the epulis type were found, but two or three smaller giant cells of the foreign body type were found in the inflammatory tissue; which is most unusual. These were in the vicinity of what appeared to be lymph spaces.

On the surface of the granulation tissue, there was an exudate consisting of red blood cells, serum, fibrin and relatively few polymorphonuclears and lymphocytes. Foreign body substances were searched for, but no definite ones were found.

The final diagnosis was chronic inflammatory tissue tumor (granuloma), associated with chronic traumatic periostitis and probably bursitis of traumatic origin. There was no definite evidence of foreign body implantation.

This man showed a growth on the olecranon process. It was of short duration and apparently accompanied by infection. From our study of the roentgenogram, which shows only a slight periosteal reaction, and the microscopic picture, which gives no evidence of malignancy, we would conclude that this case should be classed as a periostitis and not a true bone tumor. The ultimate outcome is not known.

The specimen is interesting as illustrating the difficulty which may be experienced in distinguishing granulation tissue from tumor tissue even in the microscopic sections. This is a truism which even experienced clinicians have freely admitted. It emphasizes the importance of a clinical check up (by means of ultimate results) on pathologic diagnoses of tissue removed at operation. With regard to this difficulty in the case under consideration, it may be noted that certain areas in the mass of granulation tissue consisted largely of younger fibroblasts simulating true myxomatous tissue. Such cells, however, showed more tendency to fibril formation than prevails in true myxoma.

Case 10.—*History.*—J. S., a man, aged 63, entered New Haven Hospital, Nov. 13, 1916, complaining of a sore, swollen toe. He had had pleurisy twenty

years previously, and an operation for swelling in the right groin ten years previously. The family history was unimportant.

Three years before (1913), the patient noticed that the right great toe was red. There was slight soreness. The toe gradually grew larger. During the last year, the toe had become painful and for the last six months he had been unable to sleep at night because of paroxysms of throbbing pain. Walking aggravated the pain. Ten years before (1906), the same toe was broken, but the patient had no medical attention.

Physical Examination.—The patient, a well developed and fairly well nourished old man, lay in bed with the right leg flexed on the thigh. His teeth were badly worn and many were capped. The thorax was asymmetrical. The

Fig. 38 (Case 10).—Appearance of toe at time of patient's admission to hospital.

right chondrocostal junction of the sixth and seventh ribs seemed much enlarged and thickened. There was a short systolic murmur at the heart apex transmitted to the neck. The radials, brachials, and temporals were thickened and tortuous. In the right inguinal and femoral regions, there were two operative scars, between which there was a pulsating expansile tumor, 4 by 6 cm. in diameter. There was no thrill or bruit heard. Underneath the artery, in the neighborhood of the perineum was a definite tumor the size of an egg. It felt like a bony tumor originating from the horizontal ramus of the pubis. The right hip was ankylosed. There was some edema of the right leg. The right great toe was much enlarged and lobulated, the skin was reddened and

fluctuation was present on the top. The swelling reached the metatarsophalangeal joint. There was local heat present. The rest of the foot appeared normal (Fig. 38). There was a slight swelling of the left knee due to an old dislocation.

November 15: Aspiration into the fluctuating area showed straw-colored mucoid material so thick that only a very little could be obtained (about 4 drops) even with a No. 18 needle. The vital signs were normal. The urine was clear, with a slight trace of albumin and no microscopic elements. Bence-Jones tests were not reported. Blood examination revealed: white blood cells, 9,200; polymorphonuclears, 83 per cent.; large mononuclears, 1 per cent.; lymphocytes, 16 per cent.; hemoglobin, 80 per cent. The Wassermann test of the blood was negative.

Operation (November, 21).—Dr. Flint performed a partial amputation of the right foot. The mass was disarticulated at the scaphocuneiform joint and the first cuneiform bone was removed with the mass.

The postoperative course was satisfactory and, December 3, the patient was discharged from the hospital to the care of a local physician.

Second Admission (Jan. 22, 1918).—The swelling on the dorsum of the foot recurred about three months after operation and slowly became larger. It was painful when the patient walked but at no other time.

The patient was undernourished, and had atrophic skin. The chest was asymmetrical owing to enlargement of the costo-chondral articulation of the seventh and tenth rib. The percussion note was hyperresonant except opposite the second intercostal space near the sternal line, where the note was dull. Posteriorly, no area of dulness was found. Breath sounds were everywhere normal. An occasional moist râle was heard. The abdomen was asymmetrical, owing to the fulness corresponding to the place on the rib. The abdomen was sensitive and palpation was very unsatisfactory, but the impression was that there was an enlarged lobe of the liver. The percussion note was dull. The upper extremities were normal. There was a diffuse swelling over the right external ring in the inguinal region. Extensive impulse was felt through the dilated ring on coughing. There were two surgical incisions over the right groin, the longer being about 8 inches from the anterior-superior spine, parallel to Poupart's ligament and down to the midthigh. Beneath this scar was a large mass aparently attached to the femur. Just medial to this was a swelling extending from Poupart's ligament down the leg nearly to the knee. This was freely movable and apparently a part of the adductor muscle. The hip was ankylosed. The foot showed an amputation at the tarsal-phalangeal joint. The scar was well healed. Just above this was a hard fusiform enlargement which involved the entire dorsum of the foot and obliterated the internal malleolus. It was very tender and the skin was not movable over it. The right leg was normal except for marked cavus.

Roentgen-Ray Examination (January 27).—The first metatarsal and phalanges were absent. There was atrophy of all of the bones of the foot, most marked in the tarsal bones and terminal head of the metatarsal. The cuboid showed marked periosteal reaction and some osteitis. There was some increased bony tissue. The articular spaces were clearly outlined.

January 31: There was evidence of bony destruction of the great trochanter of the femur. The destruction, however, was peripheral. The pubic bones near the symphysis showed a rather marked halisteresis. There appeared to be no

proliferation or other destruction of bones. The sixth, and especially the seventh and eighth ribs on the right showed a definite destructive process involving the cartilage and considerable of the terminal costal portion.

February 11: The patient received daily increasing doses of Coley's serum up to 4½ minims. The mass over the right groin previously fixed became movable. The other tumor masses remained about the same.

February 23: The patient refused daily increased doses of serum. The present dose was 9 minims. The tumor over the ribs showed no change, nor did the groin. The foot remained very tender. The measurements were unsatisfactory. The circumference of the foot anterior to both maleoli and around the arch of the foot was 29 cm. The skin was now movable and the outlines of a nodular mass involving the metatarsal bone could be made out. Previously, the tumor could not be outlined.

March 8: The patient received injections in the buttocks and right calf of leg, up to 25 minims, with no reaction. The tumor, which at first appeared to grow smaller, was now increased in size and the pain became more intense.

March 28: The patient was able to walk about the ward. No change was seen in the tumor masses. The patient was allowed to go home until arrangements were made to send him to New York Memorial Hospital. He was discharged, unimproved.

Vital signs had been normal throughout his stay in the hospital. The urine examination was negative. The white blood cells numbered 9,400. The red blood cells were normal in appearance. Hemoglobin was 80 per cent.

Third Admission (August 5).—No history in the interval was given except that the pain in the foot became continual and increased in severity. The patient could not sleep well on this account, especially in the last six weeks.

The abdominal muscles were held rigid, but there was no tenderness in the abdomen. Liver dulness extended 1½ inches (3.7 cm.) below the costal margin in the midclavicular line on the right.

On the right foot, covering the dorsum and apparently connected with the bones of the tarsus, was a rounded tumor about 8 cm. in diameter. The skin over the tumor was tense and red, but apparently not adherent. The tumor was tender to pressure and caused the patient much pain. In the right inguinal region, there was a nodule 2 by 4 cm. in diameter. It was hard, not tender, and fairly freely movable.

Second Operation (August 8).—Dr. Whittemore performed circular amputation of the right leg at the junction of the lower and middle thirds.

August 25: The stump was very tender to pressure. There was no swelling. A small unhealed area remained in the center. There was no reddening. The patient was discharged from the hospital with instructions to return for dressing.

The urine showed a slight trace of albumin and a few casts. Otherwise, it was negative.

Sept. 12, 1919: The patient died from malignancy.

Pathologic Examination.—Grossly, the specimen consisted of a half section of a tumor mass about as large as a medium sized lemon, although less regular in outline. It involved the first phalanx of the great toe and had destroyed this together with the proximal portion of the terminal phalanx, which showed an irregular erosion.

The specimen had apparently shrunken considerably, the skin lying in wrinkled folds, although it seemed to have been under considerable tension from the underlying tumor at the time of amputation. The exposed cut

surface of the tumor was soft and irregular, resembling an old sea sponge. On close inspection, the softer portions of the tumor seemed to have fallen out. On making a fresh cut, a smooth, soft, but elastic surface with large hemorrhagic markings was seen. The tumor seemed encapsulated toward the skin and at its upper extension, but the destruction of the phalanges gave sufficient evidence of its invasive character. No cartilage was recognized.

The gross diagnosis was sarcoma of the proximal phalanx of the great toe.

Microscopic examination: Sections from five different blocks, all of them containing tumor tissue were available for study. Of these, only two showed definite malignancy, one was doubtful and two were negative, although they were selected directly from the tumor.

Fig. 39 (Case 10).—Roentgen-ray appearance of growth shown in Figure 38. There is marked destruction of phalanges and invasion of soft tissues.

The neoplasm was not an infiltrative one, so far as can be judged from these sections alone, but apparently was circumscribed with definite encapsulation. The periphery was rounded and composed of lobules, which in turn often showed at their periphery a narrow zone of cartilage. This abruptly shaded off into myxomatous tissue toward the centers of the lobules. At times, the entire lobule contained only myxomatous tissue, which for the most part was associated with an abundant ground substance, or matrix, possibly mucinous in character, staining a light blue and apparently a result of secretory or degenerative processes of the cells (Fig. 40). In the sections containing no definite malignant tissue, this material was very prominent and appeared to have played a rôle in the extensive areas of necrosis present. Some of these were 1 cm. or more in diameter. In such areas, no viable cells were to be seen, but unstained shadows of cells were scattered throughout.

When there was definite sarcoma, it occurred frequently in areas apparently in transition from myxomatous zones. In such places, the spindle-cell type of sarcoma prevailed, with occasional giant cells of the malignant type.

The diagnosis was myxochondrosarcoma of the proximal phalanx of great toe.

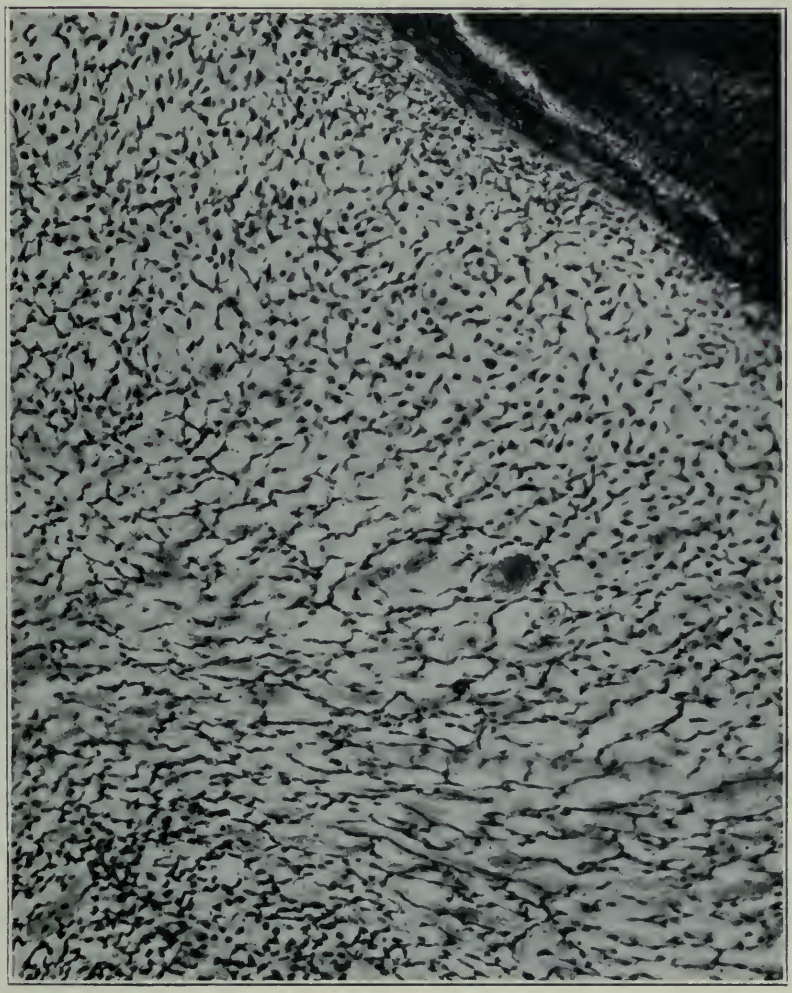

Fig. 40 (Case 10).—Myxomatous tissue, with no areas of definite sarcoma.

The evidence of malignancy in this case consisted in the painful swelling and deformity of the toe; the age incidence; the marked bone destruction and invasion of the soft parts, well shown by the roentgen ray (Fig. 39), and the pathologic studies, which demonstrated areas of myxoma, sarcoma, etc. Were one to attempt a diagnosis from frozen section alone, there is the possibility that an area of pure myxoma

might have been selected. In fact, only two blocks of five studied showed signs of definite malignancy. This is a source of error that must be kept in mind when the decision rests on the microscopic section. The combined gross and microscopic appearances and the clinical behavior must be taken into consideration in every instance and the surgeon's judgment must rest on an evaluation of all the factors, together with his knowledge of the outcome in similar instances as reported by his colleagues. The question naturally arises as to the operative procedure chosen for this case. If the surgeon had been more radical, attempting a Syme's amputation or even a lower third of the leg, would recurrence have taken place?

This neoplasm is of a type which is known to recur with great regularity and ultimately to kill by metastasis. It seems to constitute a group, the nature of which is recognized late, after one or more operations. A more radical procedure based upon a diagnosis made at the first exploratory incision might lead to better results. These tumors are usually quite soft, and it might be well if only myxomatous material was suspected at operation, to adopt Bloodgood's [12] idea of their malignancy.

The occurrence of a destructive process in the femur and ribs is hard to explain on the basis of metastases unless dissemination was very widespread, as the sarcomas of bone use the blood stream as a pathway. The marked improvement under Coley's toxins indicates that this form of treatment might have been a very valuable asset early in the disease.

SUMMARY

From our study of this group of cases, we are impressed with the difficulties which confront the average surgeon in arriving at the proper diagnosis and deciding on the proper treatment in any group of bone tumors. Certain growths are well defined and conform to type; but there are so many exceptions to the rule that each case must be most carefully studied and weighed before action is taken. Were we to trust to the roentgen-ray picture for our diagnosis, we would be deceived in a number of instances; were we to depend on microscopic section alone, especially at the operating table itself, we would be often misled. And the clinical behavior may at times be confusing, although in general it is a most valuable index. By considering all methods, weighing them carefully, our decision must be arrived at, and then in many cases the only true test we have is that of time. The surgeon who will perhaps make the fewest mistakes will combine a knowledge of the gross and microscopic appearances and clinical behavior of the commoner types of bone tumor. We agree with Ewing [7]

12. Bloodgood, J. C.: Ann. Surg. **77**:106 (Jan.) 1923.

that "the gross anatomy of the lesion is often a safer guide than the variable and uncertain structure of a small piece of tissue." This experience can be obtained only through the collection and study of a group of these neoplasms, such as is planned by the Registry for Bone Sarcomas. The Registry would confer a great boon on surgeons if a series of accurately drawn and colored plates of the various types of growth were published and placed on sale so that operators could know what "the currant jelly" of the giant cell, etc., actually looks like in the gross. Many such colored plates would undoubtedly be published in case reports were it not for the expense, and contributions of this kind to the Registry could no doubt be obtained.

It would be a fairer test of the value of the Registry, if the diagnosis could be given from the available information that the clinician has; namely, clinical history, roentgen-ray findings and pathology. When the end-result is likewise known, judgment is not in some cases so difficult. We feel also that through the Registry we may get a point of view which may not represent the whole truth on the subject as there are undoubtedly many men who have amputated limbs for bone tumors and for one reason or other, medicolegal, for example, do not wish too close an investigation as to the nature of the tumor removed. In this way, many of the real cases of cure in amputation for osteogenic sarcoma may be hidden under a bushel of failures.

Finally, when the tumor has had a very rapid growth and has progressed extensively when first seen, more conservative treatment with radiotherapy and other measures, at least until we get more information, would seem to meet the situation better than the radical amputations of the past.

NOTES ON FIVE CASES OF PAGET'S DEFORMING OSTEOMYELITIS

WITH DESCRIPTION OF THE SPECIMEN OF A FEMUR FROM A SIXTH

LEONARD W. ELY, M.D.

SAN FRANCISCO

Three cases of Paget's deforming osteomyelitis have been observed at the Stanford Clinic during the past few years. To these I have added one private case. Data in the possession of several of my San Francisco colleagues indicate that the disease is not so rare as is generally thought.

REPORT OF CASES

CASE 1.—*History.*—A man, a hardwood finisher, aged 57, was admitted to the neurologic clinic, Dec. 18, 1912, with a complaint of noises in the ears and in the right side of the head. His mother died of cancer. He had been married thirty-three years, and his wife and four children were alive and well. The wife had miscarried four or five times. No history of syphilis was elicited, but alcohol and tobacco had been used excessively.

The onset of the present condition was insidious, about seven years previously, with "wrecking of the system." The patient was at that time 5 feet 4 inches (1.6 meters) tall. Pain developed in the back, and the back began to bend, and the arms and legs to bow. Five years previously the buzzing noises began in the right ear and right side of the head. The pain in the back slowly increased, until two years previously it became so bad that the patient was forced to give up work.

Physical Examination.—The patient was very short, measuring but 4 feet and 9¼ inches (1.45 meters). He had a posterior spinal curvature, and the legs and forearms were bowed, the right forearm more than the left. The distance from the tip of the olecranon to the styloid of the ulna, was, left, 25.5 cm.; right, 26.5 cm. The neck was extremely short and thick, and the head was large. The parietal diameter was especially great, and the upper part of the head was disproportionally large.

There was contact hearing only. The eye fields were concentrically contracted; vision in both was 20/30, and the fundi were normal. The teeth were much worn; some were loose, and pyorrhea was present. The tonsils were atrophic. The chest was barrel shaped; the vertebral column was apparently shortened, and the ribs almost touched the ilia. The clavicles were thickened, and the costal margins flared markedly. The lungs showed signs of chronic emphysema. The heart was enlarged to the left, and a systolic murmur was heard at the apex, imperfectly transmitted. The peripheral arteries were markedly sclerotic. The abdomen was protuberant. Some general glandular enlargement was present. The blood pressure, systolic, was 155 mm. The urine was free from albumin and casts.

The red blood corpuscles numbered 4,650,000; the white, 8,000. Hemoglobin was 84 per cent. The spinal fluid analysis and Wassermann tests (blood and spinal fluid) were negative.

Treatment.—After a short stay in the hospital, the patient resumed his visits to the neurologic clinic. He received thyroid tablets and potassium bromid, and was treated with the galvanic and static currents. He improved in some respects for a while, but his stature slowly decreased.

Second Admission (April 12, 1916).—His height now was only 4 feet and 6 inches (1.37 meters). He gave a history of an attack of diarrhea about two

Fig. 1 (Case 1).—Front and side views.

months before admission, with chills and some fever, lasting about three weeks. After this, nycturia and smoky urine developed. Since January, 1916, the urine had on different occasions shown albumin, and hyaline and granular casts, a few white blood corpuscles, and many red blood corpuscles, the last becoming more numerous. He was put on a chronic nephritis diet, and left the hospital after two weeks. For the subsequent course of the disease, I am indebted to Dr. Walter Schaller, into whose care he passed.

The Course.—The symptoms of Paget's disease slowly increased, so that locomotion became impaired, and the patient was forced to resort to the use of canes, and then crutches. The gait became waddling, and he suffered from pain in the thighs.

Early in July, 1918, the urine showed bile pigment, and then the sclerae and the skin became jaundiced, and the stools became clay colored, with an offensive odor. Somewhat later, the patient began to complain of slight distress in the upper abdomen, and a feeling of pressure. Examination revealed an enlarged liver, about 3 inches (7.5 cm.) below the costal margin and quite tender. Chills and fever soon became pronounced, the chills finally occurring twice a day. The patient gradually grew worse, finally going into a definite coma. He died, Sept. 6, 1918.

Necropsy (Dr. Knapp.).—The body was that of a dwarfed, gray-haired man, about 55 years old, emaciatetd and jaundiced, and showing marked skeletal deformity. The spine was bent forward on the pelvis, and was kyphotic and scoliotic. The legs were much bowed out; the chest was very prominent laterally, and the lower ribs were spread widely apart. The head was very large, with small, pinched features. The temporal, frontal and parietal regions were bulging, and the occipital region was flattened. There was no definite change in the bones of the face, but the features appeared small in comparison with the skull. The clavicles were large and curved. The radii were bowed, the right much more than the left. The left clavicle was removed for histologic examination. The teeth were very poor, only a few stumps remaining.

There was a very small amount of subcutaneous dark fat. The muscles were dry and pale. There was marked calcification of the costal cartilages. The diaphragm was at the fourth rib on both sides. The colon was distended with gas. There was about 200 c.c. of bile-stained fluid in the abdomen. The omentum was short, and contained little fat. The liver was about three finger-breadths below the costal margin. The gallbladder was completely covered over with dense adhesions, in which the duodenum and the hepatic flexure of the colon were firmly massed together. In this mass, in about the position of the common duct, there was a large calculus, about 5 by 1.5 cm. in diameter. There was much fecal matter surrounding it, and it appeared to be partly within the duodenum. On dissection of the adhesions from the liver, a large amount of greenish, purulent material escaped from its under surface, apparently from the bile duct.

There was nothing noticeable in the region of the thymus. A small amount of fluid was present in the pericardium. The heart was of normal size. There was a marked fibrous thickening of the pericardium over the right auricle. The chambers and the valves of the heart were normal, but the wall of the left ventricle seemed somewhat thicker than normal. The aorta was normal, except for a small yellow patch near the tricuspid valves. The large arteries seemed remarkably elastic for the apparent age of the subject.

The thyroid was small, but otherwise not remarkable. The spleen was slightly enlarged, and the splenic vein was quite prominent. The capsule was irregularly thickened, and in one thickened area considerably calcified. The cut surface showed normal but rather indistinct markings.

The right kidney was of normal size. The capsule was adherent, and the surface was finely granular, with irregular depressed scars in the cortex. The cut surface showed the cortex and pyramids very pale and cloudy. The pelvis and ureter were normal. The suprarenal showed postmortem softening. The condition of the left kidney was the same as that of the right. The prostate was normal.

The rectum, sigmoid, colon, appendix, ileum and pancreas appeared normal. The liver was considerably enlarged, and felt boggy. Its cut surface showed innumerable small, and numerous quite large, abscesses, filled with greenish, necrotic material. In the more normal parts, the liver lobules were surrounded by a distinct greenish discoloration, as of stagnant bile.

The diagnosis was: Paget's deforming osteomyelitis; chronic cholelithiasis with obstructive jaundice; multiple liver abscesses; abdominal, pleural and peri-

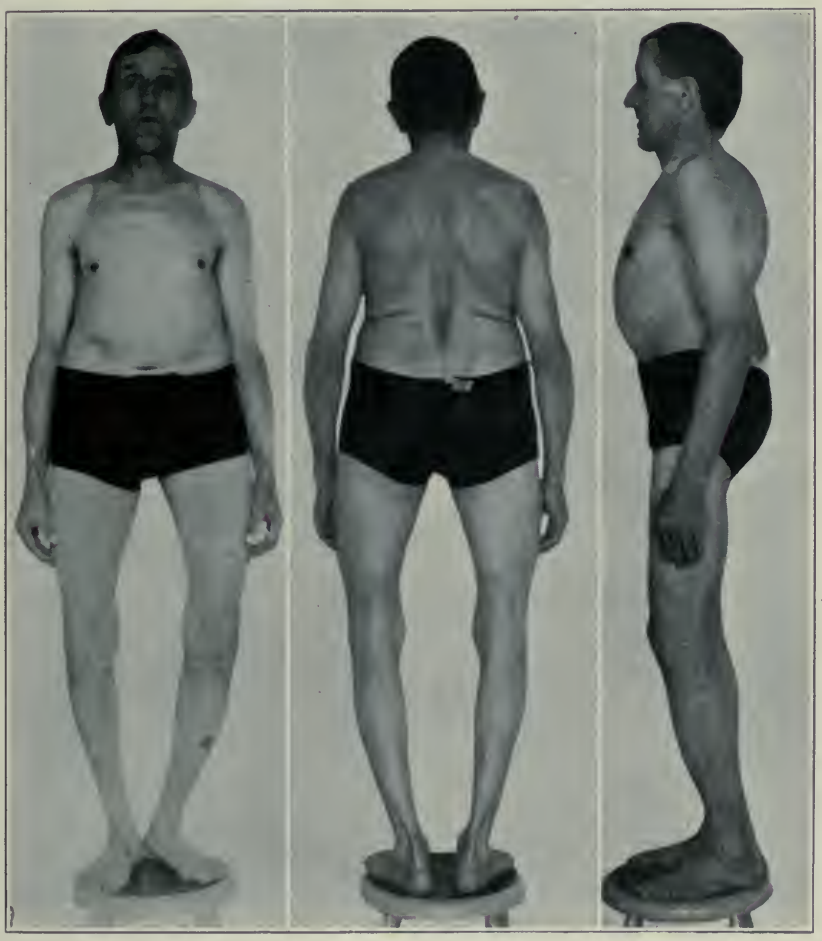

Fig. 2 (Case 2).—Front, back and lateral views.

cardial effusion; old perisplenitis; old pleurisy; chronic oral sepsis; pachyarteriosclerotic kidney, with cloudy swelling; beginning atheroma of the aorta; general emaciation, and secondary anemia.

Case 2.—A. B., an English seaman, aged 47, registered at the Stanford Clinic, February 28, 1922, gave the following history: His mother was alive and well. His father died of cancer at about the age of 64. One brother was alive and well, three or four brothers died in infancy. With the exception of

malaria about thirty years before, and a gonorrheal infection fifteen or twenty years before, the patient has been in good health. No history of syphilis was elicited.

In 1909, the patient was seized with a sudden pain in the back. He was in the hospital for ten days, and had had more or less pain in the back ever since. There had been pain in the legs for years, especially in the shins. In 1915, he

Fig. 3 (Case 2).—Appearance of leg bones.

had an attack of "rheumatism" all over the body, lasting about eight months. For the past year, he had had pain in the feet and ankles. Six months previously, he had another attack of "rheumatism," which lasted for about one month. For the past three weeks, he had had severe pain in the head, and two weeks previously the pain spread all over the body, and had grown worse. It was usually dull, but occasionally became sharp, and was so severe now that it kept the patient from work. The knees became swollen, and "the bones were

getting out of shape." He had had some trouble with his teeth, and considerable postnasal catarrh, but no sore throat. He had been very deaf since the attack of "rheumatism" in 1915.

Physical Examination.—The patient was markedly bow-legged, and the bowing seemed to involve both the tibiae and the femora. The tibiae were bowed anteriorly also. The trunk was very short in comparison to the extremities, and seemed to have sunk down into the pelvis. The anteroposterior diameter of the thorax was increased. The back was markedly rounded in the

Fig. 4 (Case 2).—Appearance of femora.

thoracic region; the shoulders were narrow, and the clavicles were prominent. The right clavicle appeared thicker than the left. The neck was short and thick; the orbits were large, and the eyes deep set. The skull was asymmetrical and pear shaped, with various bosses. The upper extremities appeared disproportionally long. The postcervical lymph nodes were palpable, but the epitrochlears were not. No limitation of motion in the joints was demonstrable except in the spine. The patient had lost several teeth, and the condition of several of those remaining suggested infection.

The temporal arteries were enlarged and tortuous. Moderate arcus senilis was present. The lungs were hyperresonant but were otherwise negative. The heart was negative. The blood pressure was 110 systolic, 70 diastolic, when the patient was in a recumbent position.

The urine showed a faint trace of albumin, a few hyaline casts and a few fine and coarse mucous shreds. The specific gravity was 1.024. The Wassermann test was negative.

The roentgen ray examination revealed abscesses at the roots of several teeth, and changes typical of Paget's deforming osteomyelitis in the tibiae,

Fig. 5 (Case 3).—Appearance of proximal end of femur. The second type changes in the hip are evident.

calvarium, femora, clavicles, spine and pelvis. In addition, the vertebrae showed characteristic spurring of the second great type of chronic arthritis.

The affected teeth were extracted, and the patient was put on potassium iodid, but he sailed for Australia shortly afterward, and was not seen again.

Case 3.—*History.*—M. E. H., a widow, aged 61, presented a case which was peculiar in its rather acute onset, and its sharp localization. The patient's father dropped dead at 81, apparently of some cardiac trouble. Her mother died at 80, two or three months after being injured in a street car accident. The

patient was one of five children, two of whom died in adult life, presumably of late cerebrospinal syphilis. The other three have always been in good health.

At 60 years of age, the patient had an attack of pain in the right knee, lasting for two months. Six months later, she had an attack of lumbago, which lasted for about one month. She had had much trouble with the teeth, and many years ago had the teeth removed from the upper jaw. Six days previously, she was suddenly seized at night with a severe pain in the back, running down the right thigh, along the sciatic nerve. When I first saw her, she was lying on the left side, and in so much pain that a physical examination was impossible, but it was noted that the Kernig manipulation on the left caused pain in the right sacro-iliac region. She was taken to Stanford Hospital in an ambulance.

Examination.—Roentgenograms revealed a normal lumbar spine, slight changes of the second great type of arthritis in the knee, and changes peculiar to Paget's deforming osteomyelitis in the proximal portion of the right femur, namely, heavy and somewhat irregular thickening of the cortex in the proximal portion of the shaft, and heavy trabeculation of the head, neck and trochanter. No other evidences of the disease were found in the bones, roentgenographically. A vaginal examination by Dr. Ludwig Emge disclosed an exquisitely sensitive thickening about the right sacro-iliac joint, running up on the ilium; but roentgenograms of the pelvis as well as of the tibiae and of the skull failed to reveal any further bone changes. Bimanual examination of the pelvic organs gave negative results.

The Wassermann test was negative. Roentgenograms of the teeth revealed rarefaction of the bone about a number of them.

The patient, when first seen (April 28, 1922) was lying doubled up in bed, with the thighs flexed on the abdomen. Any movement or manipulation caused great pain. This condition continued unchanged for several days.

Treatment.—May 2, the deformity was reduced under general narcosis, and a long plaster-of-Paris spica was applied. At the same time, all the remaining teeth were removed from the mandible. The pain now became less severe; but did not completely disappear, and the plaster spica was removed after about three weeks. Then followed a week's rest in bed.

May 31: Arthrodesis of the right sacro-iliac joint was carried out under general anesthesia. The operation was that devised by Smith-Peterson, with the lateral approach to the joint. The wound was closed, and a long plaster spica was applied. Considerable shock followed the operation, and there was some pain for several days. The plaster was removed, June 14, on account of symptoms of marked constitutional involvement—delirium, high temperature, etc. The wound had healed by first intention. The constitutional symptoms slowly subsided, and the patient gradually recovered, returning to work about four months after the operation. A recent letter from her states that, with the aid of Eddyism, she is progressing favorably.

The piece of bone removed from the sacrum at the time of operation was decalcified, imbedded, cut and stained. With the exception of perhaps a slight widening of the haversian canals, nothing abnormal could be distinguished. The marrow was of the lymphoid variety, and was normal.

The peculiar thing about this case is that the bone changes were demonstrated in the femur alone. The symptoms referred to the sacro-iliac joint, as well as the mass felt in the vicinity, pointed to involvement of the ilium; but no bone changes could be distinguished there in the

roentgenogram, and at the operation I used the iliac bone fragment to produce ankylosis of the sacro-iliac joint, and did not feel justified in removing a piece of it for study.

Case 4.—*History.*—M. B., a housewife, aged 50, first came to the clinic, Sept. 6, 1922, complaining primarily of a sensation "as if something wanted to pull

Fig. 6 (Case 4).—Front and back views.

out of the left ear," and of postnasal catarrh. She had had a ringing in the ear for about two years. (It will be recalled that buzzing in the ears was an early symptom in Case 1). A diagnosis of chronic nonpurulent aural catarrh was made. The patient was not seen for about a month. October 3, she returned, complaining of pain in the back, which, she said, had been present

for about four years. She gave the following history: Her mother was alive; her father died at 55, of bronchitis, the patient thought. One brother died of pleurisy, another of bronchitis. The patient was married at 15, had a child at 17, and had never been pregnant since. She had previously been in good health, though the tonsils had been bad for years. She had had frequent attacks of tonsillitis and of quinsy. The tonsils were removed one year previously. All the upper teeth were extracted about three years previously, on account of pyorrhea.

The pain started gradually in the back, four years previously, without history of injury. It was dull, and was worse when the patient stood or walked. The left leg was swollen and painful, and "got stiff." The pain, which ran

Fig. 7 (Case 4).—Appearance of pelvis and proximal end of femora.

down the left leg to the foot, was growing worse, and at times caused the patient to limp. On questioning, she admitted that she was becoming shorter and for the past three and one half years had been growing bow-legged.

As the patient stood, she presented a lateral curve to the left in the lumbar region. All motions of the spine caused pain referred to the left sacro-iliac region. The Kernig sign was negative. The left tibia was slightly rotated outward, and was 1.5 cm. shorter than the right. About the middle, it presented a rather well marked thickening anteriorly, quite sensitive to pressure. Abduction was limited in both hips, as was rotation.

The roentgenograms revealed a thickened cortex in the middle third of the tibia on all sides, with some forward bowing, and an irregularity of outline of

the fibula. Other roentgenograms taken later showed changes characteristic of Paget's deforming osteomyelitis in the skull, mandible, femora, pelvis, spine, radii and humeri; evidences of the second great type of arthritis in the spine, and calcification in the pineal gland.

The dental clinic reported alveolar infection, and removed buried roots from the upper jaw, and one tooth from the mandible.

Fig. 8 (Case 4).—Appearance of leg bone.

Examinations in the women's clinic and examination of the stools for parasites were negative. The medical clinic reported a basal metabolic rate of + 8 per cent.

SUMMARY

The first patient was a man whose mother died of cancer. He probably never had had syphilis, though his wife had miscarried repeat-

edly. The disease began at about the age of 50, with pain in the back, and involved many bones. It lasted for about thirteen years. Infection in the alveolar processes of the jaws was noted during life, and at necropsy, when nephritis, cholelithiasis and liver abscesses were also noted.

Fig. 9 (Case 4).—Appearance of base of skull and cervical spine. The second type changes in the cervical spine are evident.

The second patient, a man of 47, whose father had died of cancer, presented no evidence of syphilis. The disease began at about the age of 34, with pain in the back, and involved many bones. The patient had well marked infection in the alveolar processes of the jaws, and chronic spinal arthritis of the great second type. He was alive at the last note.

The third patient, a woman of 61, whose family history was apparently unimportant, developed the disease at about the age of 60, with pain in the back, or with pain in the knee, and it presumably affected but one bone, or possibly two bones, the femur and the ilium. The patient had an infection in the alveolar processes of the jaws, and a second type arthritis in the knee. She presented no evidence of syphilis. The dead teeth were all removed, and the sacro-iliac joint was ankylosed by an operation. She improved markedly, and at last account had returned to work.

Fig. 10 (Dr. Smith's case).—The two halves of specimen sawed sagittally; *T*, tibia; *K J*, knee joint; *F*, fracture; *F H*, femur head and neck.

The fourth patient, a woman of 50 years, whose family history is not suggestive, developed the disease at the age of about 46, with pain in the back, and it involved many bones. She had also chronic multiple arthritis of the great second type, calcification of the pineal gland, and infection in the alveolar processes of the jaws. No evidence of syphilis was present, and the stools were negative for parasites. The dead teeth were removed, and parathyroid extract was administered. She improved during the three and one-half months of observation.

Two of the patients were men, two women. The age of incidence was presumably 50, 34, 60 and 46. Two had cancer in the family

history; all had infection in the alveolar processes of their jaws, and three had also chronic arthritis of the great second type. In the first patient, this last point was not noted. In all, the disease began with pain in the back; in three, it involved many bones; in one, it involved one bone or possibly two.

To these histories I add notes on a specimen of a femur from another case, presented to me by Dr. Ethan H. Smith.

The femur was obtained from a hip joint amputation in a man of 55 years, in whom the disease had lasted for "at least thirty years." No other bone was involved. Amputation was performed on account of pain, and because of the failure of a subtrochanteric fracture to unite. At operation, the bone was found to be very soft. As. Dr. Smith expressed it: "The head of the femur could be simply pinched off." He found an old hematoma surrounding the fracture.

The specimen was in two parts, the distorted and hardly recognizable femur head, and the distal end of the femur with the proximal end of the tibia. The

Fig. 11.—Appearance of lower extremity of Dr. Smith's patient, from whom the specimen was taken. This photograph was taken in 1906, and the disease then was presumably of about twenty years' standing. Eight years later, the femur was fractured distal to the trochanters. The fracture did not unite.

femur was bowed, shortened, much thickened and otherwise changed in its shape. It presented near its distal end a fracture, of which there is no mention in the history, and about which there is no evidence of any effort at repair. Presumably it occurred postmortem. The bone was very soft, and cut easily with a knife. When sawed sagittally, the remarkable change in its structure was evident. The entire architecture was altered. The femur was increased in diameter, and the cortex greatly thickened and irregular. The posterior cortex was about 2 to 3 cm. thick, and the anterior less than 1 cm. The irregularity in thickness of the cortex was due to the irregularity of contour of its inner surface.

The fracture mentioned in the history was an oblique subtrochanteric one, and showed no sign of any attempt at union.

Sections of the anterior cortex showed the absence of any compact bone whatever. The cortex consisted of scattered bone trabeculae without any definite arrangement. Some of the trabeculae showed so-called osteoclasts in

Howship's lacunae. The marrow consisted of a delicate reticulum of connective tissue, with here and there areas of cellular infiltration. Small hemorrhages had occurred into it.

COMMENT

The cause of this disease has been the subject of much discussion. Syphilis has been suggested, but this theory has been more or less

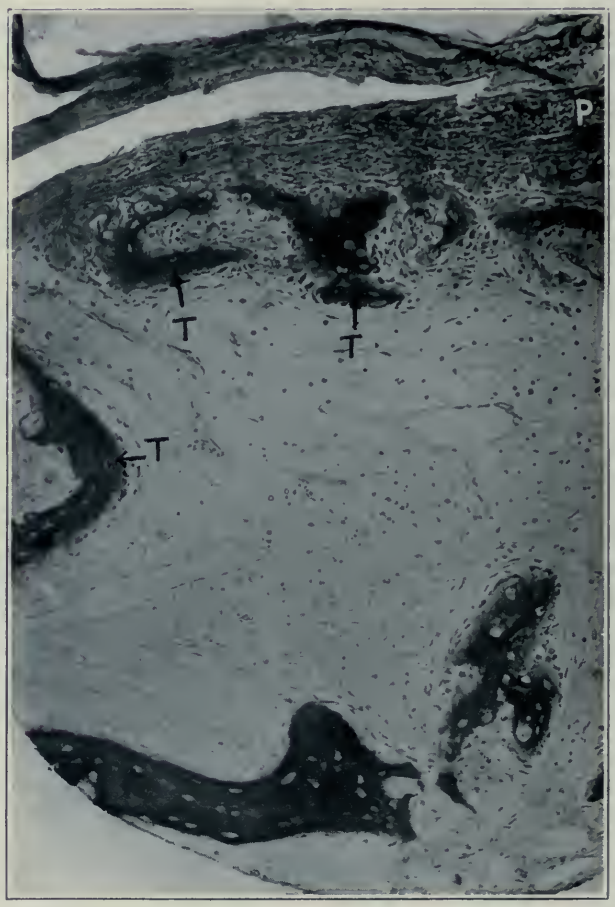

Fig. 12.—Low power photomicrograph of stained slide of a section from the cortex of the femur shown in Fig. 10. The cortex as such has ceased to exist. Under the periosteum are seen a few scattered poorly formed trabeculae, *T, T, T*. The marrow consists of little else than fibrous tissue; *P*, periosteum.

generally abandoned. It could not be diagnosed with reasonable probability in any of my cases. To external inspection, the appearance of the long bones suggested syphilis, but the roentgenographic picture was quite different, and the anatomic changes also. Perhaps the greatest

argument against its syphilitic nature is the failure of antisyphilitic treatment.

Paget drew attention to the fact that his early patients all died of a malignant growth. Other observers have noted the same fact in their cases; and a study of the reported cases of the disease shows the peculiar sequence, never invariable, running through them. It is probable, therefore, either that Paget's deforming osteomyelitis may cause cancer, or that the same cause may be responsible for both diseases. A family history of cancer was obtained from two of my patients.

Ziegler and others have pronounced the bone changes similar to those observed in the second great type of arthritis. On the other hand, this similarity has been denied. The two diseases occurred together in the three of my patients in whom a search for arthritis was made. Certainly both have all the ear marks of a chronic inflammation in the marrow caused by something other than bacteria.

All four of my patients had evidences of osteomyelitis at the roots of their teeth. Generally, the condition of the teeth is ignored in the histories of the reported cases. Vogel, Hartmann and Kutscha indicate that their patients had alveolar infection, Mackey says his patient's teeth were sound. I have repeatedly called attention to the almost invariable presence of alveolar infection in patients with the second great type of arthritis.[1] It is not that the osteomyelitis in the jaw, of itself, acts as the cause, but that it serves as the open door through which the nonbacterial organism enters to infect the bone marrow. What this organism is we have not yet succeeded in determining, and we may only surmise whether the same organism causes chronic arthritis and Paget's deforming osteomyelitis, and possibly cancer also. This line of investigation is much more promising than those proved erroneous, such as syphilis, and much more definite than "disturbed metabolism" or "rheumatic diathesis."

The three patients in this series seen during the past year all had the benefit of our knowledge, recently acquired, of the relation of alveolar infection to the chronic, nonbacterial inflammations in bones, and had the affected teeth extracted as the first step in the treatment. Improvement followed in two cases. The third patient disappeared. If this article should fall into the hands of some one to whom he presents himself for treatment, I shall appreciate any information about him. His name is Banforth. He can be recognized from his photograph.

---

1. Ely, L. W.: Second Great Type of Chronic Arthritis, Arch. Surg. **1**:158 (July) 1920; California State J. Med. **19**:415 (Oct.) 1921; Amoeba as Cause of Second Great Type of Chronic Arthritis, California State J. Med. **20**:59 (Feb.) 1922; Inflammation in Bones and Joints, Philadelphia, J. B. Lippincott Company, 1923, p. 426.

Another promising field for investigation in these cases is the presence of parasites in the gastro-intestinal canal. So far, our search has been in vain, but that does not mean that they are necessarily absent. They are frequently present in patients afflicted with the second great type of arthritis, and are probably responsible for the areas of aseptic

Fig. 13 (Case 5).—Front and lateral view of patient.

necrosis which constitute the primary pathologic lesion in that disease. In certain cases, they may be in the mouth only, and then, of course, would not be revealed by our stool examinations. Proof of this will be hard to secure, for apparently parasites are short lived in the marrow, and are extremely difficult to recognize when they are

present. Authorities on parasitology differ in their opinion of the specimens I have submitted to them. The task will be even more difficult in Paget's deforming osteomyelitis, for we have not yet found any definite pathologic change except the fibrosis of the marrow, and the irregular production and absorption of bone.

In the marrow, of course, we must search for the seat of the difficulty, for the bone simply reacts to disease in its contained marrow, and

Fig. 14 (Case 5).—Appearance of femur.

nothing is ever learned from its study except that it is or is not being properly built up and torn down. Both the building up and tearing down are accomplished through the activity of the marrow.

A recent writer has thrown out a large number of the published cases of Paget's disease, using some criterion of his own. A typical case, such as my first and second, can be recognized immediately from an inspection of the patient, and this was the invariable method of

diagnosis until the introduction of the roentgen rays; but my fourth patient showed only a suggestion of the disease in her photograph, although her bones are extensively involved. In her case, as in that of the third patient, the diagnosis was made by the roentgen rays, and this is the only reliable means at our disposal. Certainly the involvement of many bones is not necessary. The specimen of the femur described here showed absolutely typical bone and marrow changes, but it was the only bone involved.

A good working definition of Paget's deforming osteomyelitis is: a chronic inflammation of the bone marrow, akin to that found in the second great type of arthritis, involving a single or many bones. It occurs in middle or later life, affects men more often than women,

Fig. 15 (Case 5).—Appearance of pelvis and hips.

and is probably caused by some nonbacterial organism which gains access to the system through the sockets of dead teeth.

While the report of these cases was in the hands of the editor awaiting publication, another patient with this disease presented himself at the clinic.

Case 5.—*History.*—A waiter, aged 58, stated that the right leg for the past fifteen years had been growing shorter "by itself," and had become very bowed. The knee had swelled, but had not been painful.

Examination.—There was a marked limp, and barrel chest. The trunk was short, the head slightly pear shaped. The lower ribs were just within the flare of the ilia. The right femur was bowed outward and anteriorly. The right knee was decidedly enlarged, and in slight flexion. It crepitated loudly on motion, and was slightly limited in extension and markedly so in flexion. The

Fig. 16 (Case 5).—Appearance of knee.

Fig. 17 (Case 5).—Appearance of cervical spine.

right thigh muscles were atrophied, and the right hip was limited in motion in all directions. The entire spine was rather bowed, and was limited in its motions throughout its length, except in its uppermost and lowermost joints. The patient moved stiffly. All the upper teeth were gone, and the condition of the lower ones was suggestive of infection. The right trochanter was above Nelaton's line. The right lower extremity measured 90.5 cm., the left, 88.5 cm.

Dental examination revealed abscesses at the roots of most of the remaining teeth. The Wassermann test was negative. The leukocyte count was 7,050. The basal metabolic rate was 18 per cent. Examination of the stools revealed *amoeba coli.* The roentgenograms revealed typical changes of Paget's deforming osteomyelitis in the spine, femora, pelvis and calvarium. Arthritis of the great second type was also noted in many of the joints.

A FUNDAMENTAL FACTOR IN THE RECURRENCE OF INGUINAL HERNIA*

M. G. SEELIG, M.D.
AND
KEHAR SINGH CHOUKE, M.D.
ST. LOUIS

The modern operation for the repair of inguinal hernia may be said to date from 1889 and 1890, when Halsted and Bassini published their studies. It may also be said with assurance that the thirty odd years' experience gained from the performance and study of this operation has taught surgeons that the fundamental principles underlying the permanent operative cure of hernia are: (1) high ligation of the sac; (2) adequate reinforcement of the defective abdominal wall, and (3) primary wound healing.

No one of these three requirements is particularly elusive, nor does any one of them seem difficult of accomplishment. Yet the percentage of postoperative recurrences is far from encouraging. Unfortunately, there exists a disconcerting divergence of opinion regarding the frequency of recurrence, a divergence which ranges all the way from 0.8 to 12 per cent., both groups of figures coming from surgeons of enviable reputation. One cannot help feeling that the higher percentage is, of the two, the more entitled to credence. Inquiries regarding postoperative recurrences are usually made by letter, and the patients' replies are credited at their face value, in spite of the fact that the patient himself is a most untrustworthy judge of early though definite recurrence. Our recent experience with draft men demonstrated the incredibly large percentage of hernias existing without any knowledge of their presence on the part of men affected.

Even more convincing to us than figures covering the frequency of recurrence is the almost incalculably large number of modifications of the Bassini operation that have been devised and described. It may be said of surgery as of medicine that a multiplicity of remedies for any one disease indicates, almost beyond doubt, that none of the remedies is thoroughly satisfactory. Kocher, MacEwen, Andrews, Ferguson, MacArthur, Championnière, McBurney, Pitzman, Hoguet, Downes, Stettin, Harrison, Woelfler, Fournel, Quain and LaRoque are among the authors suggesting modifications of technic. In practically every instance, the modification is aimed, not at simplification of the operative procedure, but at reducing the rate of recurrence. We have included in this list of names no one who has suggested a modification of technic

* From the Department of Surgery of Washington University School of Medicine.

to meet a special indication, such as arises in sliding, voluminous bladder or bilocular hernia. In a recent and exhaustive study, Oudard and Jean reach the conclusion that "the Bassini operation ought to be abandoned."

If we accept as true the statement that high sac ligation, restoration of the abdominal wall and primary wound healing are the essentials to



Fig. 1.—The fascia lata of the thigh is incised, and one edge is folded back on itself. The reduplicated edge thus formed, in imitation of Poupart's ligament, is then sutured to the underlying musculature.

perfect cure, it is clearly evident that proper sac ligation and proper wound healing are to the largest degree under the control of the surgeon. Both of these factors may be dismissed as comparatively insignificant agencies in the causation of recurrence. May the same be said of the restoration of the defective abdominal wall? For over thirty

years, this restoration has been effected mainly by suturing the internal oblique and transversalis muscles and their conjoined tendon, to the inguinal ligament of Poupart. Does this procedure (the main reliance of the surgeon in the modern hernia operation), really accomplish the intended purpose?

The answer to this question may be sought in the operating room and in the laboratory. For several years, one of us (M. G. S.) has directed attention to the relationship between Poupart's ligament and

Figure 2

Figure 3

Fig. 2.—Interrupted catgut suture of fascia to muscle; wound clean (two months after suture).

Fig. 3.—Interrupted silk suture of fascia to muscle; wound clean (four weeks after suture).

the internal oblique and transversalis muscles and their conjoined tendon. In none of his operations in recurrent inguinal hernia, has he ever seen these muscles and the conjoined tendon firmly attached to Poupart's ligament. In practically all instances, these structures are

widely separated, just as if they had never been approximated by suture. More than that, Poupart's ligament almost invariably appears strikingly intact and free from thickenings or adhesive cicatricial bands such as one might naturally expect. Coley [1] states that the muscles remain attached to Poupart's ligament, and he bases his statement on the two facts that his recurrence percentage is small and that in his operations for recurrence he finds the internal oblique muscle "firmly united to Poupart's ligament, nearly down to the pubic bone." We

Figure 4

Figure 5

Fig. 4.—Interrupted silk suture of fascia to muscle; wound clean (five weeks after suture).

Fig. 5.—Continuous silk suture of fascia to muscle; wound clean (seven weeks after suture).

doubt, though with hesitancy, the soundness of Coley's observation, just as, with hesitancy, we are inclined to question the value of his

1. Coley, W. B.: Keen's System of Surgery, Philadelphia, W. B. Saunders Company, **3**:77, 1908, and Progressive Medicine, Philadelphia, Lea & Febiger, 1922, p. 36.

statistical methods in arriving at the conclusion that his recurrences numbered only six in 740 operations (0.8 per cent.).

Several of our colleagues have stated that, in their operations for recurrent inguinal hernia, they also, as a general rule, find Poupart's ligament smooth, glistening, and free from attachments to the muscles to which it had been sutured previously. Oudard and Jean [2] report an

Figure 6

Figure 7

Fig. 6.—Interrupted silk suture of fascia to muscle; wound clean (seven weeks after suture).

Fig. 7.—Interrupted silk suture of fascia to muscle; wound clean (eight weeks after suture).

experience similar to mine. They find no trace of union between Poupart's ligament and the muscles in their operations for recurrence.

2. Oudard and Jean: Hernies Inguinales Récidivées, Rev. de chir. **60**:143, 1922.

Harrison[3] also says that a careful study of approximately 100 operations for recurrent inguinal hernias (personal communication) has convinced him that the suture of Poupart's ligament to the abdominal muscles does not result in a permanently close apposition of these structures.

In operating for recurrent hernia, one usually encounters rather dense scar tissue union between the posterior surface of the external oblique fascia and the underlying sheath of the internal oblique and

Figure 8

Figure 9

Fig. 8.—Interrupted silk suture of fascia to muscle; wound infected (nine weeks after suture).

Fig. 9.—Interrupted silk suture of fascia to muscle; wound badly infected (ten weeks after suture).

transversalis muscles. These dense adhesions usually create the unfortunate impression that the tissues are "glued together"; but if one will

3. Harrison, P. W.: Inguinal Hernia: Surgical Treatment, Arch. Surg. **4**: 680 (May) 1922.

patiently divide these superficial adhesions and thus release the outer flap of the external oblique, he will find that it leads him down to an unattached Poupart's ligament.

Why should this be the case? It goes without saying that if the muscles are anchored to Poupart's ligament under tension, the union will be an uncertain one at best. But is tension the only factor that militates against union? Exactly what happens when muscle is sutured

Figure 10

Figure 11

Fig. 10.—Continuous silk suture of fascia to muscle, which was traumatized by wedge excision; wound infection (seven weeks after suture).

Fig. 11.—Continuous catgut suture of fascia to muscle, which was traumatized by wedge excision; wound clean (three months after suture).

to fascia? A diligent search of the literature failed to bring to light a single study of fascia-muscle wound healing. It was necessary, therefore, to institute these studies in the laboratory, where fifty experiments were carried out on dogs, under ether anesthesia.

The inguinal canal of the dog is so snugly and completely closed as not to permit additional suturing. It was decided, therefore, to study the union of the fascia lata of the thigh to the underlying group of muscles. By a 3-inch (7.5 cm.) longitudinal incision at the anterior and upper portion of the outer aspect of the thigh, the fascia lata was exposed and incised longitudinally for about 2 inches (5 cm.). A free edge of the fascia was then folded back on itself, in imitation of the reflection of the external oblique fascia to form Poupart's ligament. The

Fig. 12.—Interrupted silk suture of fascia to muscle, which was traumatized by wedge excision; clean wound (eleven weeks after suture).

reduplicated edge of fascia was then sutured to the underlying muscle. This suture of muscle to fascia was always carried out, so that there was no tension whatsoever on the sutures, in order to obviate all possibility of the separation of fascia from muscle by pull (Fig. 1). Different types of suture (continuous, mattress and interrupted) and different types of suture material (catgut and silk) were used. In some of the experiments, infection was courted by slovenly technic, in order to observe the effect of suppuration on subsequent muscle-fascia union.

In another group of animals, the muscle was traumatized by excising a thin wedge and then the reduplicated fascial edge was sewed into the traumatized portion of the muscle. By this means, the influence of trauma on union could be observed. Finally, in another group of experiments, fascia was sutured to fascia in order to observe the type and strength of union that resulted. The topic of wound healing of fascia to fascia may be dismissed at this point with the statement that, in all the experiments, the union was perfect and strong, and so smooth that the site of suture could be determined with difficulty, even under the microscope. At the end of periods varying from one to three months, the animals were anesthetized and killed, and the fields

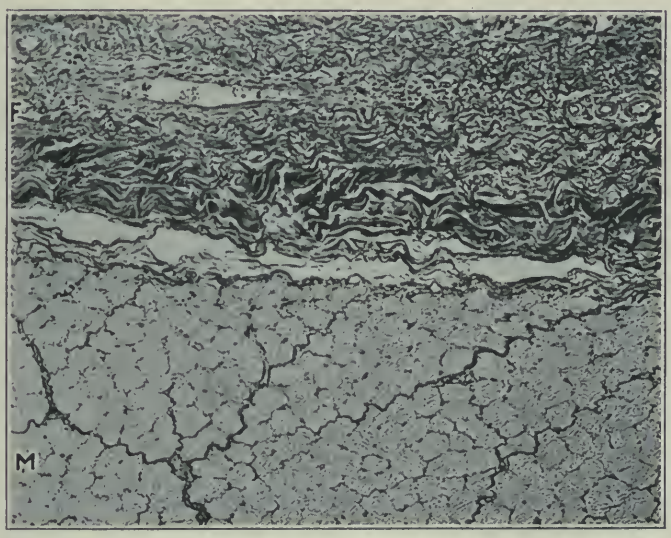

Fig. 13.—The normal separation of fascia lata from the underlying muscles; *F*, fascia lata, *M*, muscle.

of previous operative attack were studied, macroscopically and microscopically.

Figures 2 to 12 represent typical results in the final wound healing. These illustrations are self-explanatory and require little comment. However, by way of summarizing the result of the experiments it may be said:

1. In every instance of clean wound-healing, the fascia was widely separated from the muscle to which it previously had been sutured. A very thin and translucent membrane of areolar tissue bridged the gap between the edges of the fascia and the muscle. The nonabsorbable sutures usually cut their way through the muscle (it has already been stated that there was absolutely no tension on the suture line), and

hung in the fascial edge. In some instances, there occurred along the sutures a reactionary fibrosis, indicated by opaque white streaks in the delicate layer of areolar tissue already described (Figs. 4, 5, 6). It seemed to make no difference whether catgut or silk were used, or whether the suture was applied continuously or interruptedly. The

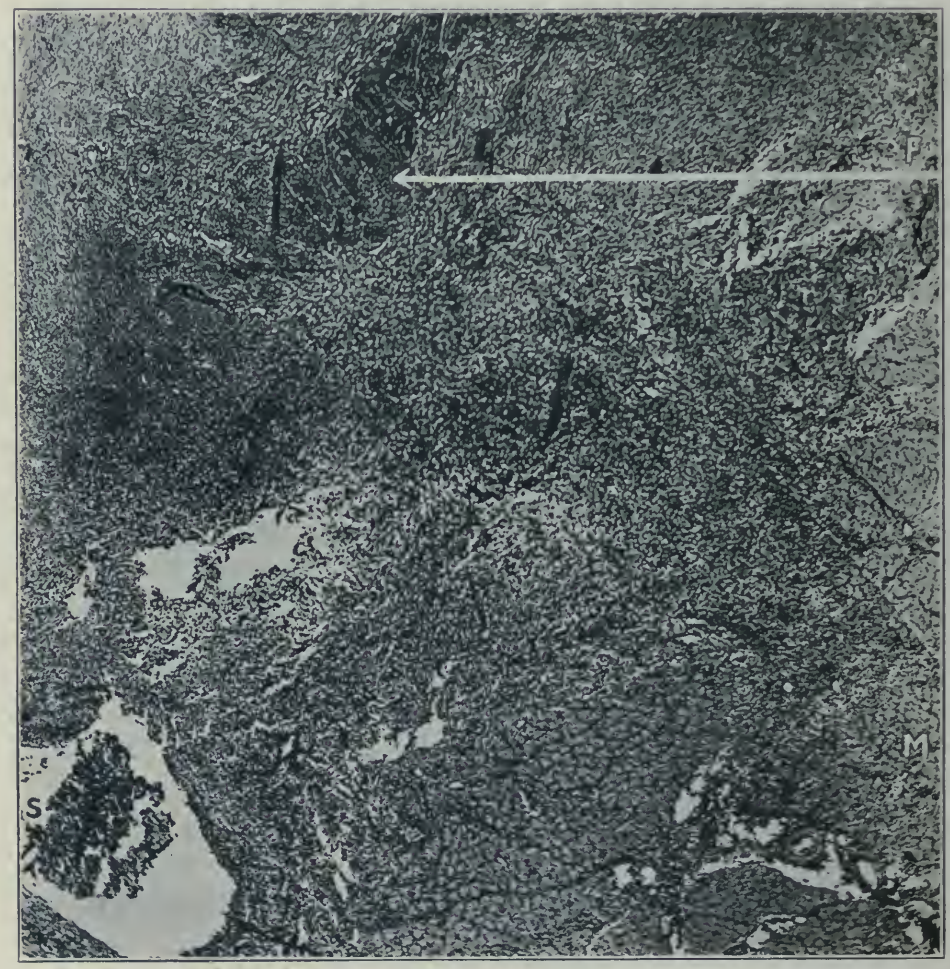

Fig. 14.—Condition of acute inflammation at the site of a suture, in the line of fascia-muscle apposition; *F*, fascia, *M*, muscle, *S*, suture (high power magnification).

muscle and fascia would not establish a close union, in wounds that healed by primary union.

2. In every instance of wound infection, the fascia was separated widely from the muscle to which it previously had been sutured. In

these instances of wound infection, the layer of delicate areolar tissue described above was usually absent; but the reactionary inflammation about the sutures was more marked than in the clean wounds. These streaks of heavy connective scar tissue bridged the space from muscle to fascia, as is shown in Figures 8 and 9. In no instance of simple

Fig. 15.—Site midway between two sutures, in the line of fascia-muscle suture; *F*, fascia lata, *M*, muscle (high power magnification).

suture, in which infection occurred, was there a solid sheet of heavy connective tissue uniting the edges of the separated muscle and fascia. In these infected wounds, therefore, we never saw either direct union of muscle and fascia or even continuous indirect union through a solid uninterrupted layer of cicatricial connective tissue.

3. In every instance in which the muscle was traumatized by the excision of a wedge so that the fascia could be sutured in the raw trough, there was an attempt at direct union between fascia and muscle. This union was complete (Figs. 10, 11, 12) in only one instance.

Before studying the wound healing microscopically, a histologic study was made of the normal relationship between the fascia lata and the underlying muscles, in a dog. This study showed that the fascia lata lies loosely on the muscle and is not only not united to it directly, but is really separated from it by loose areolar tissue (Fig. 13).

The histologic relationship between the fascia lata and muscle were then studied two weeks after suturing the muscle to the fascia with interrupted sutures. It was found that, along the sutures, there was an extensive reactionary, leukocytic (polymorphonuclear) infiltration (Fig. 14); whereas, between the sutures, the fascia merely lay against the muscle as it does normally (Fig. 15). In other words, the sutures

Fig. 16.—Pedicled strip of fascia lata lying in tunnel of muscle (traumatized muscle).

seem to set up a definitely limited inflammation which binds the muscle and fascia together at the immediate sites of the inflammation. Between these sites there is no union, and as the inflammation subsides, the binding power of the inflammatory exudate disappears.

From this group of experiments, therefore, it seems logical to infer that the mere apposition of muscle to fascia does not insure a firm and lasting union between these fundamentally different types of tissue. Wound suppuration seems to favor a partial cicatricial union. Trauma (to the muscle) seems to make it possible, in certain instances, to secure a direct and fairly strong union between muscle and fascia.

In view of the fact that the fascia unites with traumatized muscle (partially at least, in some instances, and firmly, in one experiment), it became necessary to study the details of wound healing in the presence of muscle trauma. In order to do this, a pedicled flap of fascia lata

was made; the underlying muscle was tunneled with a knife, and the fascial strip was laid in the raw muscle tunnel and sutured in situ, without tension, as shown in Figure 16. After periods of from eight to twelve weeks, the area involved was excised, and the relation between fascia and muscle was studied histologically. These studies showed that, wherever the fascial strip came into contact with intramuscular connective tissue (perimysium), it fused with it, and became firmly anchored (Fig. 17). Wherever the perimysial tissue was scanty, the fascial strip lay in its tunnel, with practically no evidences of union to the muscle about it (Fig. 18).



Fig. 17.—Fascial strip imbedded in muscle, which has been traumatized to make a tunnel for the fascia to occupy. The heavy strands of intramuscular connective tissue are fused with the fascial strip, firmly anchoring it; *M*, muscle, *F*, fascia.

The fact that simple apposition of muscle to fascia does not result in a firm union of these two structures is of fundamental importance, and is closely related to the problem of the radical cure of hernia. It is of interest to consider whether nature herself ever directly unites muscle firmly to connective tissue, and to determine how this union is normally established. We could think of only two sites in the human or in the dog where muscle and connective tissue were normally fused: (1) the close fusion of the rectus abdominis muscle with its connective

tissue sheath at the tendinous inscriptions, and (2) the close fusion of muscle and tendon where muscle ends and tendon begins.

As regards the rectus muscle and its union with the sheath of the rectus at the lineae transversae, Figure 19 clearly illustrates how a firm union is established. The sheath sends finger-like processes of connective tissue into the muscle belly. Each process is an integral part of the sheath itself. All along its course through the muscle, the tendinous process anchors itself in place by fusing with the various strands of connective tissue (perimysium) that course through the muscle and separate the various muscle bundles or fascicles. These

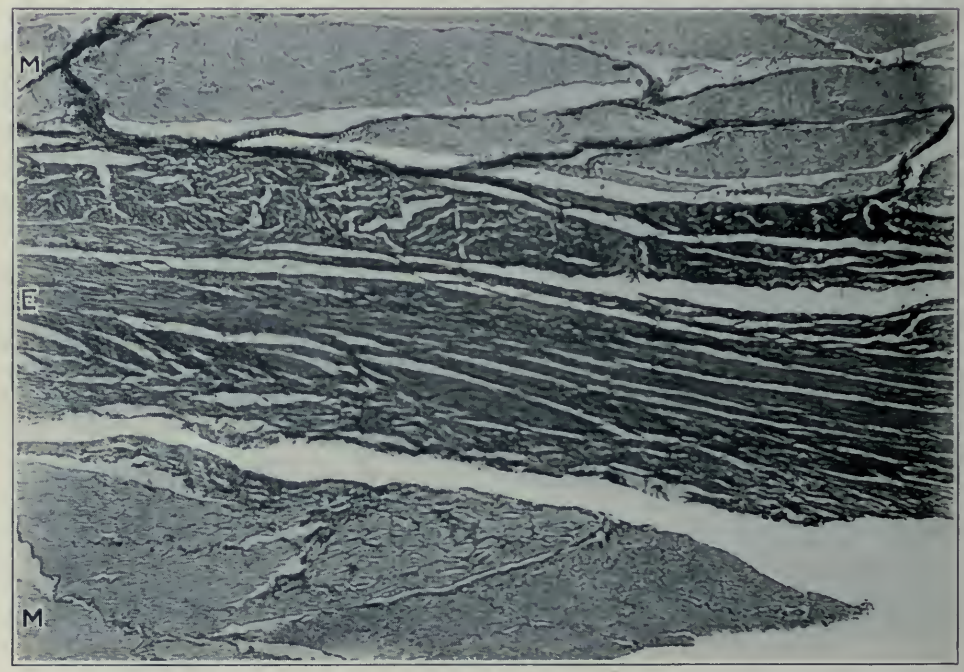

Fig. 18.—Same experiment as that shown in Figure 17, except that at this site the intramuscular connective tissue is scanty, and consequently the fascia is poorly anchored to the muscle; *M*, muscle, *F*, fascia.

various anchorages cause a firm union of sheath and muscle—a fact well known to surgeons, and necessitating sharp dissection, when the rectus is stripped from its sheath at the site of these transverse bands. A higher magnification shows with what care these anchorages are made by nature. Delicate connective tissue fibrils are given off by the tendinous bands and fuse with the connective tissue endomysium surrounding the smaller muscle bundles (Fig. 20).

The union of muscle and connective tissue at the site of muscle-tendon junction is somewhat after the same fashion and furnishes the

same type of histologic architecture as does the rectus muscle at the site of a tendinous band. Figure 21 is a low power magnification of tendon-muscle junction of the external oblique muscle of the abdomen, and shows how the tendon is directly continuous, both with a heavy central strand of connective tissue, running back for a long distance

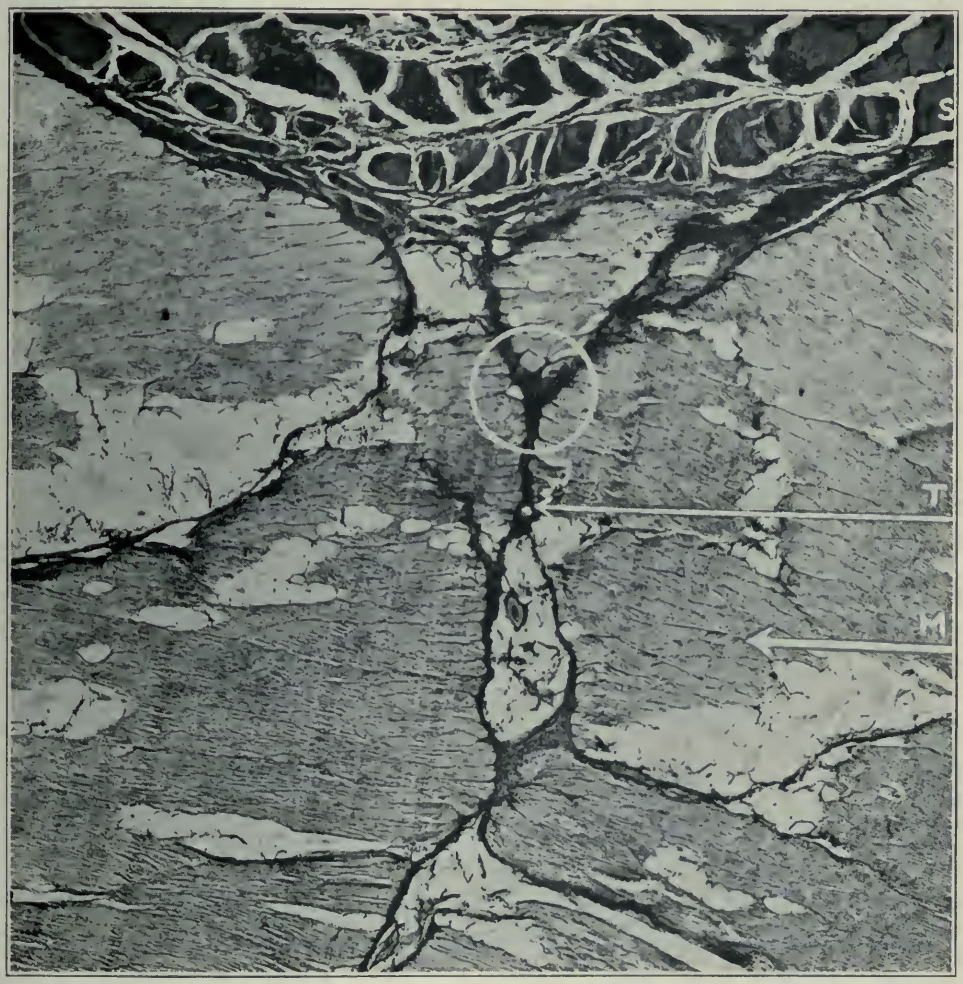

Fig. 19.—Anteroposterior section (low power) through rectus muscle and its sheath at the site of tendinous inscription, showing anchorages of tendinous band, both to the sheath and to the perimysial connective tissue of the muscle; *S*, rectus sheath, *T*, tendinous inscription, *M*, rectus muscle.

in the body of the muscle, and also with the sheath of the muscle that clothes its end and becomes continuous with the central strand of connective tissue. This type of union is very strong and can hardly be

duplicated by surgery. Figure 22 is a high power magnification of the same field and illustrates in greater detail nature's method of strengthening a muscle-connective tissue union. As will be seen in the illustration, the connective tissue system of the tendon is anchored at innumerable sites, to the connective tissue system of the muscle (peri-

Fig. 20.—Lines of anchorage of connective tissue (tendinous inscription) to the muscle endomysium (high power magnification of the circled area in Figure 19).

mysium and endomysium and sheath), producing practically a continuity of muscle and tendon.

Up to this point, we have attempted to show that: 1. No success attended our various trials to establish a strong direct union between muscle and fascia except in those experiments in which the muscle was

traumatized previous to its suture to the fascia. 2. There are very few if any sites in the body where a direct muscle-connective tissue union occurs normally except in the muscle tendon system. 3. In these muscle-tendon systems, nature employs a definite type of architecture. This we in a measure imitate when we traumatize the muscle. But we cannot count on a full measure of success, even when we plan our

Fig. 21.—External oblique muscle and tendon of external oblique (abdominis) to show muscle-tendon junction (low power magnification).

experiments so that there is absolutely no tension at the site of apposition. It goes without saying that when tension is a factor, the sutured structures are very likely to pull apart before wound consolidation can take place.

Thus, we are led to the practical considerations of herniotomy. If the experiments here recorded have been executed properly, and if the conclusions from them have been drawn accurately, it is utterly

futile and useless to suture the internal oblique and transversalis muscles to Poupart's ligament. These muscles will not unite with the fascial ligament unless they have been deliberately and rather extensively traumatized, and even if they did unite the union would not be permanent on account of the inevitable tension that occurs when these structures are approximated. We do not believe that even the conjoined tendon often unites with Poupart's ligament when these two structures are sutured. These structures are both connective tissue, but in addition to the inevitable tension, which pulls against the suture line, there is

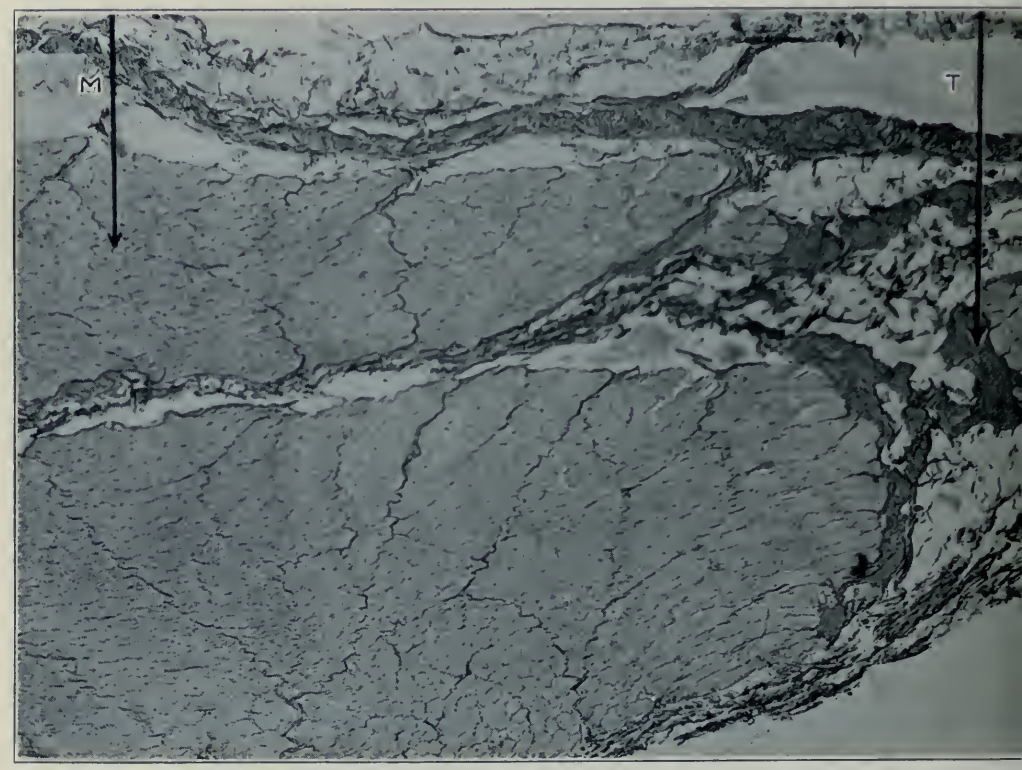

Fig. 22.—Tendon-muscle junction of external oblique (abdominis) muscle (high power magnification).

always present the possibility of the lateral and medial origins of the cremasteric muscle interposing themselves between Poupart's and the conjoined tendon, thus rendering union highly improbable (Fig. 23).

Must we then abandon the idea of reinforcing the weak abdominal wall? By no means. We have at our command three or four procedures:

1. We may rely on a strong union between Poupart's ligament and the outer flap of the external oblique muscle. This is a rational pro-

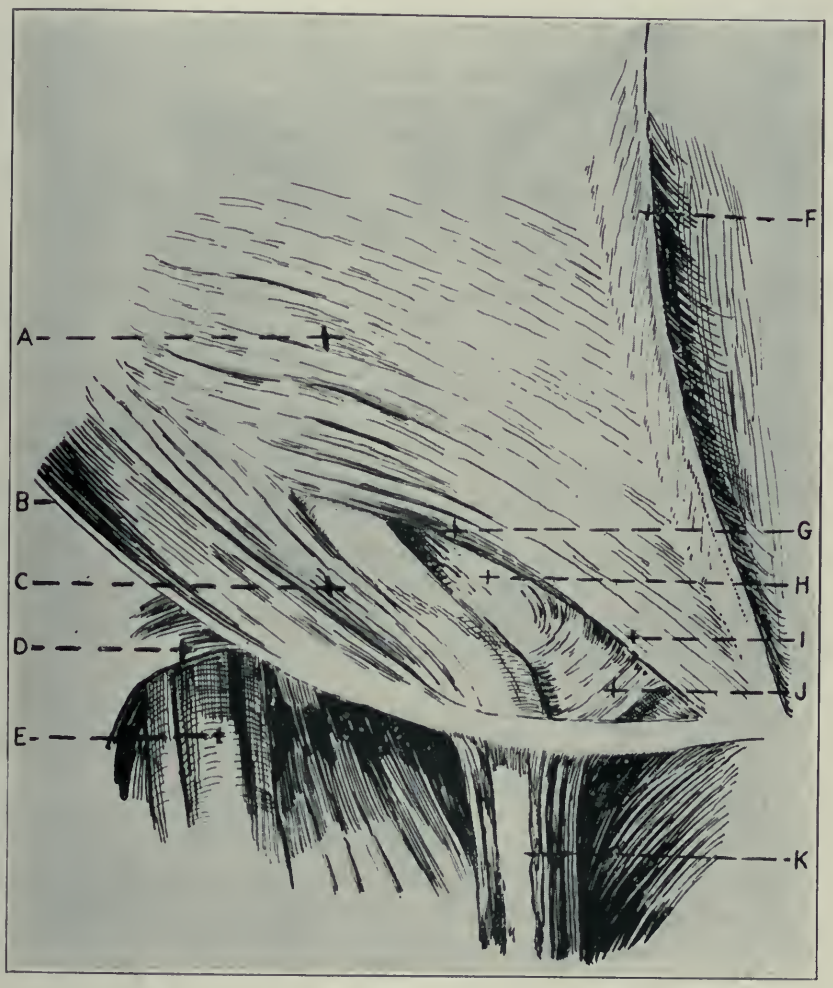

Fig. 23.—The inguinal canal (after Spalteholz), showing interpolation of medial and lateral origins of cremaster muscle, between conjoined tendon and Poupart's ligament; *A*, muscle obliquus internus abdominis, *B*, muscle obliquus externus abdominis (cut through and reflected downward), *C*, lateral origin of the muscle cremaster, *D*, margo falciformis (cornu superius), *E*, vena femoralis, *F*, muscle obliquus externus abdominis (cut through and reflected medianward), *G*, upper wall of the canalis inguinalis, *H*, posterior wall of the canalis inguinalis, *I*, conjoined tendon, *J*, mesial origin of the muscle cremaster, *K*, funiculus spermaticus with muscle cremaster.

cedure. It has been extensively employed in reinforcing the abdominal wall under the name of Andrews' modification, and our experiments show that its utility rests on the affinity of connective tissue for kindred connective tissue, in wound healing. We have been using a modification of this method with unqualified satisfaction, for the past two years, a period too short to permit of any more dogmatic statement.

2. We may employ the method of Pitzman [4] which depends on suturing the separated edges of the transversalis fascia, and ignores the internal oblique and transversalis muscles and their conjoined tendon. Pitzman very properly emphasizes the great strength of the transversalis fascia.

3. We may employ the method of Harrison [3] which also ignores the muscle-ligament suture and relies on the transversalis muscle-fascia suture, made after a plan somewhat different from Pitzman's.

4. We may follow the method of Slattery, which also relies largely on suture of the transversalis fascia.[5]

5. We may use the method of Gallie [6] who sutures the muscles to Poupart's ligament, but employs fascial strips as suture material. Our work shows why these strips should anchor tightly to Poupart's ligament and why they are likely to become well anchored to the intramuscular connective tissue with which they come in contact as they pass through the muscle. Gallie's method is, of course, bound up with the problem of tension on the suture line.

SUMMARY

1. The modern operation for the cure of inguinal hernia is attended with a disconcertingly high rate of recurrence.

2. Normal muscle will not unite firmly with fascia or ligament. It is, therefore, a useless procedure to suture the abdominal muscles to Poupart's ligament, in the hope of buttressing a weak or ruptured abdominal wall.

3. Fascia unites well with fascia.

4. The weak abdominal wall should be strengthened by the use of one of the methods of securing fascia to fascia approximation.

---

4. Pitzman, Marsh: A Fundamentally New Technic for Inguinal Herniotomy, Ann. Surg. **74**:610 (Nov.) 1921.

5. Slattery, R. V.: Radical Cure of Inguinal Herniae, Irish J. M. Sc. p. 389, November, 1922; abstr. Internat. Survey of Surg., p. 74, January, 1923.

6. Gallie, W. E., and LeMesurier, A. B.: Living Sutures in Operative Surgery, Canadian M. A. J. **11**:504 (July) 1921.

EXPERIMENTAL CORD CRUSHES

WITH ESPECIAL REFERENCE TO THE MECHANICAL FACTORS INVOLVED AND SUBSEQUENT CHANGES IN THE AREAS OF THE CORD AFFECTED

JOSEPH F. McVEIGH, B.A., M.D.
Adjunct Professor of Anatomy, University of Texas
GALVESTON, TEXAS

For several years, Dr. William Keiller, with whom I have been associated in the Department of Anatomy of the University of Texas, has contended, from his study of the spinal cords of patients who have died as a result of fracture of the spine, that, since the spinal cord is encased within a fairly firm but apparently slightly elastic tube of pia mater, the cord pulp formed at the site of lesion in crushes resulting in ribbon-like injuries takes the path of least resistance and tracks up and down the cord pushing aside and destroying cord elements. It was with this theory in mind that we undertook a series of experiments on dogs and of studies on human cords obtained fresh at necropsy, the purpose being to study the mechanical factors involved in spinal cord crushes both complete and partial, and the subsequent vital changes occurring in such injuries.

METHODS

Dogs were used for the experiments, and females were preferred because catheterization could be more easily carried out. In each of the dogs, a laminectomy was performed in the dorsal region of the spine at the level of the seventh and eighth vertebrae. The spinous processes were first removed and then the laminae were cut away, the dorsal aspect of the dura mater being thus exposed. In five of the dogs, such pressure was exerted with the tip of the finger that the body of the vertebra could be felt through the crushed cord. In three of the dogs, it was estimated that the crushes were partial, the cord being compressed to but one half of its anteroposterior diameter. The dogs were allowed to live variable lengths of time, from one hour to two weeks, and subsequently the spines were removed with the cord in situ. The human cords were obtained fresh at necropsy and were subjected to pressure between the fingers, the dura remaining intact. Both dog and human cords were then placed in 10 per cent. formaldehyd to harden, the dura being nicked at several levels to allow free access of the fixative.

After three days, the cords were removed and sections were made through, above and below the lesion. These were sectioned and stained with Delafield's hematoxylin and eosin or iron hematoxylin. For pur-

poses of study, the material may be divided into three groups: partial cord crushes in dogs, complete cord crushes in dogs and crushes of the human cord obtained fresh at necropsy.

PARTIAL CORD CRUSHES

EXPERIMENT 1.—*Operation.*—Dog 4, a small white female, pregnant, under ether anesthesia, March 24, 1923, was subjected to a laminectomy in the region of the seventh and eighth dorsal vertebrae. The dura was exposed and the cord was crushed until it seemed to the finger to be about one half of its diameter.

Result.—Eight hours after operation, the dog had apparently recovered from shock and was paralyzed below the site of operation. The reflexes (tendon

Fig. 1 (Dog 2).—Gross cord.

and sex) were present and active. The animal was killed by ether, the spine and cord being removed intact. It lived eight hours.

Gross Pathology.—There was slight deformity at the site of the lesion, with hemorrhagic areas of irregular type scattered above and below the lesion.

Microscopic Examination (Fig. 5, above).—At the lesion, there was destruction of the posterior white columns, with slight hemorrhage. There was marked edema of the remains of the posterior white columns and some of the lateral parts of the cord. Five-tenths cubic centimeter below the lesion, there was marked edema of the posterior white columns. Hemorrhage into central gray matter was noted. There was a curious lamination of the pulp, which had invaded the posterior columns in the ventral part. One half cubic centimeter above, there was a small amount of blood and pulp in the posterior central aspect of the cord, with edema in the posterior and lateral white columns.

Experiment 2.—*Operation.*—Dog 5, a small weak male, was operated on, March 24, 1923, under ether anesthesia, with the technic employed in Experiment 1, except that the cord snapped in two and separated slightly, being apparently brittle.

Result.—The reflexes in this case had become quite exaggerated before the spine and cord were removed twenty hours later, the paralysis being complete below the lesion. The animal had lived twenty hours.

Gross Pathology.—This was similar to that in Experiment 1.

Microscopic Examination (Fig. 5, center).—Through the lesion, there was rupture of the pia, and deformity of the cord, the wedged shaped dorsal columns being pushed back. The ventral aspect of the cord was destroyed. There was marked edema in the posterior and anterolateral white columns. Hemorrhage was noted along the line of the entering dorsal nerve roots and into the anteromedian fissure. One half cm. above, there was marked hemorrhage into the anteromedian fissure. Deformity of the ventral part of posterior white columns,

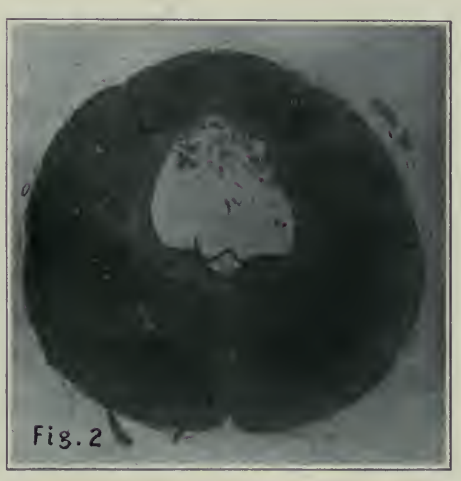

Fig. 2 (Dog 2).—Microscopic section, 2 cm. above lesion. Compare with Figure 9.

showing some pulp material, was present. Five-tenths cm. below, pulp was found in the posterior central part of the cord, and marked edema in the dorsal and lateral white columns.

Experiment 3.—*Operation.*—Dog 6, a large lively black male, was operated on, March 24, 1923, under ether anesthesia, with the technic employed in the case of Dog 4, except that after the cord was crushed, the dura over the site of lesion was incised, allowing the escape of cerebrospinal fluid.

Result.—At the end of thirty-two hours, bladder and bowel activity was automatic. The reflexes were as before. The animal lived thirty two hours.

Gross Pathology.—There was protrusion of the dorsal columns as a pointed process through the nick in the dura, with a gradual slope up and down the cord to normal.

Microscopic Examination (Fig. 5, below).—Through the lesion, there was apparent flowing of disintegrated and undisintegrated cord material toward the

nick in the dura. The pia was ruptured at this level over the dorsal columns. There was marked edema, with a long axis of spaces toward the nick in the dura. Less hemorrhage was noted than in previous cord examinations. Sections above and below the lesion showed some similarity of deformity of the dorsal columns, with much edema and slight hemorrhage.

Experiment 4.—*Operation.*—This was performed on Dog 6, after death by etherization, the site of operation being about 3 inches below that of the previous operation. The technic was that previously employed. The spine was removed with the cord in situ.

Gross Pathology.—There was slight deformity at the side of the lesion.

Fig. 3 (Dog 1).—Section 2 cm. above lesion. Lamination of invading blood and pulp is evident.

Microscopic Examination.—Through the lesion, there was deformity of the cord, but no evidence of hemorrhage or edema, such as would be expected. The same condition was present above the lesion. Five-tenths cm. below the lesion, there was a defect in one of the posterior gray horns, which gave the appearance of having been filled with disintegrated cord matter but which had been lost during the preparation of the sections. Examination of the gross specimen showed slight bulging of the corresponding area of the cut surface.

From an examination of the clinical data, it will be noticed that only a partial crush of the cord was intended. The first change to be noted was the presence of a deformed cord at the site of the lesion, the deformity affecting principally the dorsal white columns, though

in Dog 5 there seemed to be considerable destruction of the anterior white columns, due possibly to the fact that the cord snapped in two. The most marked change constant throughout the cords, with the exception, of course, of Experiment 4, was the presence of a fairly well marked edema involving the perivascular spaces and the nerve sheaths, located for the most part in the dorsal white columns, though the anterior and lateral white columns were also affected to a considerable degree, often giving a honeycombed appearance to these regions of the cord. Edema, as we use the term, is applied to the condition as Gordon Holmes describes it, with swelling of the axis cylinders and distension of the nerve sheaths, the latter sometimes being enormously distended, particularly in the lateral aspects of the cord, with no evidence of axis cylinders present. From our experiments, it will be

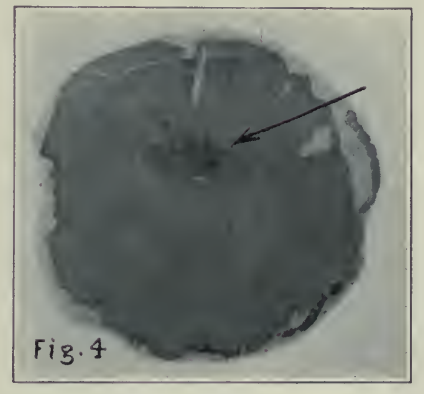

Fig. 4 (Dog 4).—Section 0.5 cm. above lesion. Arrow indicates blood and pulp area.

noted that the edema appears during the first eight hours after the lesion is produced, increasing in amount and area involved for at least two days. It is present above and below the lesion.

Hemorrhage is present in fair amounts, apparently most marked in the dorsal white columns and present above and below the lesion. The central gray matter is likewise involved in the hemorrhage, which is also scattered through the anterior gray horns. There is no massive hemorrhage.

Particular attention should be directed to the sections below the lesion in Dogs 4 and 5. The ventral part of the dorsal white columns seems to have been the seat of invasion by some cord débris, the fibers having been pushed aside and isolated; while in Dog 4 a distinct lamination of débris has occurred. The same state of affairs exists above the lesion in Dog 5. It is the presence of this cord pulp material

Fig. 5.—Above, left to right: Section of cord, 0.5 cm. above lesion, through lesion and 0.5 cm. below lesion (Dog 4). Center: Section of cord, 0.5 cm. above lesion, through lesion and 0.5 cm. below lesion (Dog 5). Below: Section of cord, 0.5 cm. above lesion, through lesion and 0.5 cm. below lesion (Dog 6).

in this specific region of the cord above and below the lesion with which we are particularly concerned in this paper. Attention is called to the fact that, in partial lesions of the cord, the pulp formed at the site of lesion is small in quantity and does not invade the cord above and below for any great distance, though the principle of the movement is the same as in complete lesions.

Dog 6 was subjected to a treatment slightly different from that of the other dogs of this group. It will be noted that the dura was incised over the site of the lesion immediately following crushing of the cord. Examination of these sections will show that, through the lesion, the entire mass of the cord seems to have flooded toward the point of released pressure. All of the different constituents of the cord seem to have been swept into the line of the nick in the dura and the defect in the pia by the rush of a current in a manner very much as débris is arranged by a flood passing through a break in a levee. The vacuoles of the edematous areas have their long axes toward the nick, and the anterior gray horns seems to have been totally disintegrated at this level by the current. Above and below the lesion, the dorsal columns alone show the effect of the current, though the edema is just as marked. There appears to be less hemorrhage in all sections in this cord.

A. R. Allen,[1] in his tentative conclusion, advised, in all cases of spinal fracture with symptoms of a transverse lesion, early laminectomy and medial longitudinal incision, in order to drain the injured tissues of products of edema and hemorrhage. His subsequent histopathologic findings do not indicate that his incision is without its dangers. An examination of the sections of Dog 6, as given above, will illustrate that, from a pathologic point of view, such sudden relief of intrapial pressure would cause untold damage to the cord at the site of lesion without the relief of the edema. In the first place, a comparison of the amount of edema in Dog 6, which lived thirty-two hours, and in Dog 4, which lived only eight hours, will show that the edema is considerably more marked in the former dog. If the relief of the pressure is expected to relieve or lessen edema formation, this should not have been the case.

In the second place, such an incision would not open and drain the lateral columns of the cords, where much of the edema is situated. In the third place, a too sudden relief of the pressure causes the disintegration of the healthy or reasonably healthy cord substance, as the sections show. In the fourth place, the anterior spinal artery or its

1. Allen, A. R.: Surgery of Experimental Lesion of Spinal Cord Equivalent to Crush Injury of Fracture Dislocation of Spinal Column, J. A. M. A. **57**:878 (Sept. 9) 1911.

Fig. 6.—Above, left to right: Section of cord, 2 cm. above lesion, through lesion and 2 cm. below lesion (Dog 1). Center: Section of cord, 3 cm. above lesion, 1.5 cm. above lesion and immediately above lesion. Below: Section of cord through lesion and 2 cm. below lesion (Dog 2).

anteromedian branch is in considerable danger in this incision. One factor in favor of the incision seems to be the less amount of hemorrhage present. Finally, the presence of vacuoles in the lateral aspect of the human cord (Figs. 17, 18 and 19), in which no vital process has been active, would indicate that perhaps it is the mechanical movement of lymph in these localities which gives the appearance of edema formation. This latter point requires further investigation. Hence, it would appear that operative interference of any sort is uncalled for, being useless in complete lesions and harmful in partial lesions, none of the expected results being accomplished, from a pathologic standpoint at least, in spite of the clinical results in Allen's dogs.

COMPLETE CORD CRUSHES

Experiment 5.—*Operation.*—Dog 1, a large female, July 22, 1922, under ether anesthesia, was subjected to a laminectomy in the dorsal region, with exposure of the cord and subsequent crushing of the cord completely through the dura, with the finger. After removal of the finger, it was noted that the cord was separated, and through the interval, spinal fluid flowed freely beneath the dura. After a moment, there seemed to be a return of blood and pulp to the area, and the gap was filled in with a dark mass. There was complete paralysis below the level of operation. The following day, the reflexes (plantar and tendon) were exaggerated; the sphincter and vaginal, active. The dog died on the morning of the third day immediately following catheterization. The spine was removed with the cord intact and placed in 10 per cent. formaldehyd. The animal lived forty-one hours.

Gross Pathology.—At the site of the lesion, the cord was reduced to a soft pulp, mixed with a fair amount of blood. This portion of the cord was about 1 cm. in length. Above and below the lesion, in the posterior central part of the cord, invasion by blood and pulp was evident for about 7 cm. above the lesion and for 4 cm. below. The area occupied by the pulp seemed to remain the same or to increase in diameter on passing above the lesion, and appeared to diminish in size as it passed down.

Microscopic Examination (Fig. 6, above).—Total destruction and pulp formation of the dorsal half of the cord, with marked hemorrhage in and around the pulp, was characteristic of a section through the lesion. Two cubic centimeters above the lesion, the central canal could not be located. There was marked invasion by pulp and blood into the posterior central part of the cord. The central part of the invading material was definitely separated from its surroundings. The posterior gray columns were considerably encroached on. Two cubic centimeters below, the invading blood and pulp were more sharply marked by a definite separation from fairly healthy cord substance about it.

Experiment 6.—*Operation.*—Dog 2, a small white male, July 22, 1922, under ether anesthesia, was subjected to laminectomy as previously performed. There was separation of the cord, and the results were as before. The following day all shock had passed away, with a marked paralysis of the lower half of the body. The reflexes were exaggerated, with very evident sphincteric reflexes present. The bladder was drained by catheter for three days, and after that time, the bowels and bladder acted automatically. In spite of care, the animal

developed bed sores of fairly severe character. At the end of two weeks, the condition of the dog became so bad that he was killed by etherization, the spine being removed with the cord intact. The animal lived fourteen days.

Gross Pathology (Fig. 1).—At the site of the lesion, the dura was adherent to the ventral aspect of the cord, the latter being reduced to half its normal size and of a porous nature. Six cubic centimeters above the lesion, the cord appeared normal. There was a cavity formation involving the posterior central part of the cord, extending for 4 cm. above the lesion and 3 cm. below.

Microscopic Examination (Fig. 6, below).—The central canal seems intact at all levels. The cavity begins immediately above and below the lesion, not as a single definite cavity but as irregular spaces with many smaller channels leading into the single, more cylindrical cavity. The area of the cord involved in the cavity here is much greater, occupying most of the dorsal half of the cord. Two cubic centimeters below the lesion, the cord appears very much as it does the same distance above, except that it encroaches on the dorsal columns almost as far as the pia mater. There is a marked vacuolation through the dorsal and lateral white columns extending the distance of the cavity formation.

Experiment 7.—*Operation.*—Dog 3, a small white female, was operated on, July 15, 1922, under ether anesthesia, an attempt being made to crush the cord by the use of heavy forceps, without laminectomy. The dog was not paralyzed by the operation, and after several days of uncertain activity of the hind legs, the animal became normal. The cord was probably not injured at all. Three months later, October 10, the cord was exposed by laminectomy and crushed as in Dogs 1 and 2. The dog was allowed to live long enough after coming out of the anesthesia to determine whether paralysis was present, and was then killed with ether, the spine and cord being treated as before. The animal lived one hour.

Gross Pathology.—The cord was split longitudinally at the site of the lesion. There was a slight amount of hemorrhage distributed above and below the lesion, of irregular nature. The pia mater was apparently ruptured just above the site of the lesion. The section of cord subjected to attempted crushing three months before was normal.

Microscopic Examination (Fig. 7, above).—One cubic centimeter above the lesion, the pia was ruptured at the side of the entering dorsal nerve roots. There was an anteroposterior split through the entire cord at this level, and slight hemorrhage along this line. One cubic centimeter below, there was only a marked hemorrhage involving the horns and central gray matter. There was no evidence of edema. Three cubic centimeters below, there was only a subpial hemorrhage over the dorsal white columns.

Experiment 8.—*Operation.*—Dog 8, a small female, April 21, 1923, under ether anesthesia, was subjected to laminectomy as before, with exposure of cord and crushing with the broad end of a knife handle. A complete lesion was evident, with refilling of gap with bloody mass after an interval. The dog was swung in a muslin hammock. The following day, it was catheterized. Marked increase in reflexes, both tendon and response to the prick of pin on the sole of the paw, was shown. Mass reflex and elevation of the tail followed stimulation of the clitoris. The next two days, the dog did not eat and seemed weaker. On the morning of April 25, the dog died. The cord was removed as before. There was no evidence of sepsis. The animal lived four days after operation.

Fig. 7.—Reading, left to right, from top to bottom: Section of cord, 1 cm. above lesion, 1 cm. below lesion and 3 cm. below lesion (Dog 3). Section of cord, 2 cm. above, 1 cm. above and through lesion. Section of cord, 1 cm. below and 2 cm. below lesion (Dog 8). Section of cord, 2 cm. above, 1.5 cm. above, through lesion and 0.5 cm. below (Dog 9).

Gross Pathology (Fig. 8).—At the site of the lesion, the cord was reduced to blood and pulp. Some prominence of the dorsal white columns was noted, and subpial hemorrhage extending principally up the cord from the site of injury. A tube of pulp and hemorrhage extended up the cord for a distance of 4 cm. and down 3 cm., occupying the posterior central aspect of the cord.

Microscopic Examination (Fig. 7, five center sections).—Through the lesion, the entire cord mass is reduced to an unrecognizable, pulpy consistency with a

Fig. 8 (Dog. 8).—Gross appearance of cord at various levels.

fair amount of hemorrhage into it. Two cubic centimeters above, there was a small area of pulp invasion just dorsal to the central canal, with very little hemorrhage. One cubic centimeter above, the area of invasion was just dorsal to the central canal, occupying about one third the diameter of the cord. The central part of the area showed separation from the walls of the space occupied, with many large granular glia cells, identical with those described by Gordon

Holmes in this region. Blood cells were most numerous in the periphery. One cubic centimeter below, the area was the same as 1 cm. above, with the exception that the dorsal white columns were more involved and were the seat of marked edema. Two cubic centimeters below, the area of involvement was almost identical with the area 1 cm. above.

Experiment 9.—*Operation.*—Dog 9, a medium sized female, was operated on, April 21, 1923, under ether anesthesia, laminectomy being performed as in Experiment 8. The cord was crushed with the finger in this case; and results were similar, with separation of the ends of the cord and refilling with blood and pulp as before. The clinical history of this dog was practically the same as that of Dog 8, except that Dog 9 became entangled in her hammock during the night preceding April 25, and was hanged, death resulting. The cord and spine were removed as before. The animal lived three and one half days after operation.

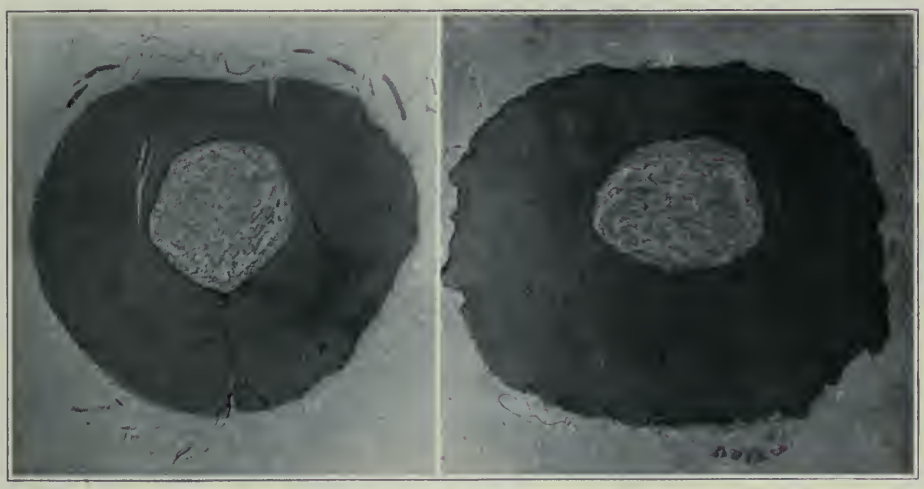

Fig. 9 (Dog 8).—Left, microscopic section through cord, 1 cm. above lesion; right, section 2 cm. below lesion. The pulp is in the process of absorption. (Compare with Figure 10.)

Gross Pathology.—This was identical with that in the case of Dog 8, with the exception that the dorsal white columns were more seriously encroached on for a short distance below the lesion. The pulp and blood advanced approximately the same distance as in the previous case.

Microscopic Examination (Fig. 7, below).—Through the lesion, the cord was reduced to a bloody and pulpy mass, with no evidence of the former architecture, with the exception of the location of the anteromedian fissure. Two cubic centimeters above the lesion, there was a small area of pulp invasion, with some blood cells just posterior to the central canal, which remained intact. The central part of the area was undergoing liquefaction, and the periphery of the mass of pulp had separated from a definitely outlined wall of cord containing excess of glial tissue. One and five-tenths cubic centimeters above the lesion, the area was about one third the diameter of the cord. There was a marked collection of blood cells in the periphery of the area. One cubic

centimeter below, the location and extent of the invading pulp was about the same as it was 1.5 cm. above. Five-tenths cubic centimeter below, apparently the entire dorsal columns were destroyed by pulp invasion in the ventral part and edematous infiltration in the dorsal part. The same was true of the portion 1.5 cm. below, with some hemorrhage. In each of the sections below, the dorsal parts of the lateral columns were also edematous.

In all of the dogs, complete crushing of the cord was performed by pressure with the finger, with the exception of Dog 8, in which the broad handle of a knife was used. A separation of the ends of the crushed cord for perhaps 0.5 cm. with subsequent filling in of the gap with bloody pulp was observed in each case. In all dogs, complete paralysis occurred below the site of lesion, bladder and bowel evacua-

Fig. 10 (Dog 1).—Section of cord, 1 cm. below lesion.

tions becoming automatic after three days in all subjects living at least that length of time. The reflexes, both patellar and plantar, were exaggerated. In the case of the females, mass reflexes and elevation of tail were evident on stimulation of the clitoris.

The gross appearance of the cords indicates that the cord substance at the site of the lesion was reduced to a hemorrhage pulp in each instance. Microscopic examination of sections through the lesion revealed little if any normal cord where the section went directly through the lesion. This pulp was evidently under considerable pressure since sufficient pressure was used to approximate the finger and the body of the vertebra. In every case, the sections above and below the lesion for the distance of several centimeters show the presence of

cord pulp and blood in a definite location in the posterior central part of the cord. When the dog lived two weeks, a cavity occupied the same relative position and extent in the cord. We now have certain facts upon which we may base our consideration of the mechanical factors involved in such crushing of the cord.

The first factor is local force or pressure. This is fundamentally the same whether caused by the finger, as in the experimental lesion, or by the apposition of the vertebral body and posterior arch of the adjoining vertebra, as occurs clinically in fracture dislocations. Compressibility is the second factor concerned. The cord is a compressible substance enclosed within a fairly firm, slightly elastic canal of pia mater. There is a limit to the compressibility of all substances; so in the cord there is a limit beyond which the cord substance is reduced to a pulp.

The question then arises as to the expenditure of the pressure which has been necessary to crush the cord in this manner. In the case

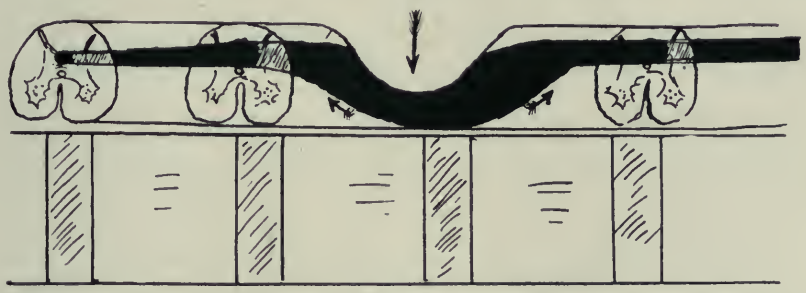

Fig. 11.—Diagrammatic representation of spinal cord showing pulping of cord at level of lesion and distribution of this pulp above and below the lesion as indicated in black (reconstructed from cords of Dogs 1, 8 and 9).

of Dog 3, the pressure was evidently relieved by the rupturing of the pia mater. In the case of Dogs 1, 8 and 9, a different and very characteristic phenomenon occurred. Sections which were made at considerable distance above and below the site of lesion showed that cord pulp and blood, evidently from the site of injury, have made their way up and down the cord, the pia mater in all of these cases remaining intact. Thus, the intrapial pressure originating in the crushed portion in these cases is transferred to the segments of the cord above and below, owing to the entrance of the pulp into these segments; and as it tracks up and down the cord, its force is thus expended.

The portion of the cord usually chosen by the invading pulp mass is the central gray matter dorsal to the central canal, rarely involving the central canal, and the ventral portion of the dorsal white columns. It corresponds very closely to the area of the cord described by Buzzard and Greenfield as *locus minoris resistentiae* (the place of least resist-

ance), principally because of its poor blood supply. They speak of lymph tracking up and down the cord through this area from the site of lesion. Gordon Holmes also speaks of this. However, poor nutrition in itself would not account for the constancy with which the cord pulp (and not lymph), in its effort to adjust the intrapial pressure, seeks this specific region of the cord. It may be reasonably accounted for by a consideration of the anatomic arrangement of the cord constituents. Reference to Figure 11, which is a diagrammatic representation of the cord of Dogs 1, 8 and 9 will show the pulp formation at the site of lesion due to local pressure applied in the direction of the arrow. The pia remained intact in all of these cases; hence, the pulp must go somewhere, and it necessarily tracks up and down the cord, as indicated

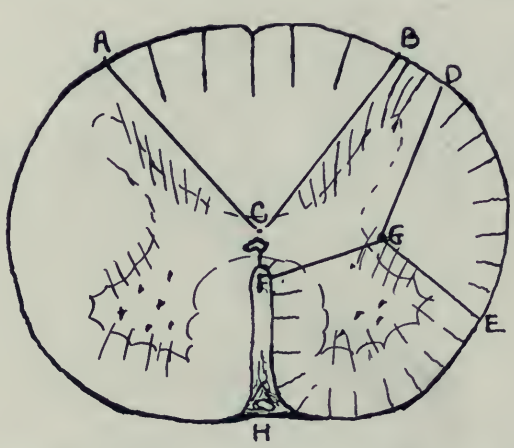

Fig. 12.—Diagrammatic section through cord, showing how any increase in intrapial pressure tends to bind the cord constituents anterior and lateral to the lines *AC* and *BC* more firmly together, thus causing pressure to be diverted toward triangle *ACB*. Fibers are shown entering and leaving the gray horns which serve to strengthen these areas.

in black. Whereas the pulp at first is forced against a fairly large area of cord surface, it is noticed that soon the paths taken by the advancing pulp begin to converge toward the ventral part of the dorsal white columns and the central gray matter, and this site is maintained until the pressure is expended.

What counteracting forces are at work which oppose the invasion of the pulp at all parts of the cord except the location always chosen? In the first place, the cord is fairly firmly bound in a tube of pia mater, which, however, is somewhat weaker, comparatively speaking, in the dog than in man. This pia surrounds the cord very intimately, and a fold of it extends up into the anteromedian fissure. Extending from

the pia are many blood vessels, ensheathed in pial investments, which penetrate some distance into the cord and serve to bind a zone of peripheral white matter to the deep aspect of the pia.

Suppose, now, that the intrapial pressure should be increased by the attempt of blood and pulp, formed at a lesion a segment below, to invade this part of the cord, as pictured in Figure 12. The first result would be an increased tension of the pia. At first thought, it seems that the anteromedian fissure would spread and thus relieve the pressure; but it must be remembered that the linea splendens serves to bind

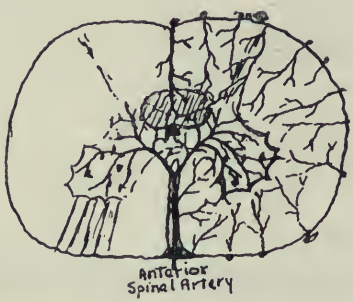

Fig. 13.—Diagram showing vascular supply of the cord. Each vessel carries with it a pial investment which interlaces with the cord constituents, serving to bind them more closely together. The area of poor blood supply is shaded.

Fig. 14.—Diagram of formaldehyd-hardened human cord in the thoracic region, showing in black the uniformity of the cavity remaining after the ventral part of the dorsal white columns had been stripped grossly with the forceps from above downward or vice versa.

the walls of the lower end of the fissure together. Thus, a tense pia acting from point *F* as a point of attachment, then swinging about *H* as a pulley, and extending back to *A* and *B*, which are near the entrance of the posterior nerve roots, would tend to isolate the lateral and anterior parts of the cord on each side, as indicated by the lines *AC* and *BC*, so far as pressure is concerned. Therefore, the cord constituents would be more closely massed together anterior and lateral to

the two lines indicated after the first increase of intrapial pressure due to the invading pulp had occurred, and would thus offer more resistance to further invasion.

Other conditions exist which add to the resistance of this anterolateral area against invasion. One of the most important factors was alluded to previously. A glance at Figure 13 will give some idea of the blood supply to the cord. Each blood vessel carries with it into the cord substance a sheath derived from the pia mater. These vessels all converge toward the point *G* in Figure 12. They pass in from points *D, E* and *F,* and at many points between these places, converging like the spokes of a wheel. These serve to bind the constituents of the anterolateral part of the cord together. Also, it will be remembered that extending from the anterior gray horns are the anterior nerve roots, passing through the white matter to the surface of the cord; while passing into the lateral aspect of the anterior horns are fibers from the pyramidal pathway, and many other descending fibers. The posterior horns are



Fig. 15.—Diagram of formaldehyd-hardened human cord from cervical region showing variations in size of cavity remaining after the ventral part of the dorsal white columns had been stripped with forceps from below upward (above) and from above downward (below). This accounts for the fact that the area involved in pulp invasion is greater above than below the lesion in cervical crushes.

entered by fibers and collaterals from the posterior nerve roots. Thus, we see that the anterolateral aspect of the cord is rather firmly meshed together.

A consideration of the state of affairs existing within the triangle *ABC* brings to our attention the following facts. In the first place, the dorsal part of this area for a certain depth is bound to the deep aspect of pia by blood vessels and their pial sheaths, just as in the other parts of the cord. The blood vessels, however, are small and do not penetrate deeply into the cord. The posterior median septum is composed of glia only except where a median vessel carries in with it a pial investment. A glance at Figure 13 will show that the area shaded is devoid of any large vessels. In the second place the ventral part of the dorsal columns is made up of fasciculi proprii and, to a much less degree,



Fig. 16.—Above: High power drawing of area of cord dorsal to and including the central canal. The animal (Dog 1) lived forty hours. The pulp mass is separated from the cord by an interval. Center: Corresponding area of cord of Dog 8, showing decreased density of pulp. Accumulation of blood cells around periphery of pulp and increased number of granule glial cells. The animal lived four days. Below: Portion of wall of cavity with granule and vacuolated glial cells in the cavity, in the walls and in the central canal (Dog 2).

of a few ascending and descending association fibers, all of which have a longitudinal course. This area of white matter is not bound to the surrounding cord by blood vessels or pia, owing to its distance from the periphery of the cord. Collaterals leave this column, it is true, but they first pass laterally and arch toward the anterior horns of gray matter, thus leaving the gray matter just posterior to the central canal practically unattached to the white matter dorsal to it.

Therefore, we may conclude that, from an anatomic standpoint, the ventral part of the triangle *ABC* is the portion of the cord which will offer least resistance to the invasion of pulp. In other words, the blood and pulp invading a segment of the cord at first is directed against the whole face of the cord, but at once meets resistance in certain localities which, on account of the structural arrangement of the constituents, tends to divert it toward areas which do not have the benefit of this arrangement. So, in this manner, the constant location of the invading pulp and blood may be explained.

As the pulp invades the cord above and below the lesion under pressure, it pushes aside the white fibers which are poorly bound together; separates them from their neighbors, and cuts off their blood supply by tearing through their capillary walls, which accounts for the hemorrhage above and below the actual site of lesion in the region of the periphery of the column of pulp. Thus, the pulp not only invades but also destroys the blood supply of the area affected, either by rupturing the vessels or compressing their walls; and, furthermore, by pressure causes destruction of the nerve fibers pushed aside or included within its boundaries. It has been pointed out that in none of these cases is there a massive hemorrhage.

A study of the sections above and below the lesion in the case of Dog 1, Figure 6, shows that the area involved in the pulp invasion is smaller and extends a shorter distance below the lesion than above. Also in Dog 8, Figure 5, it will be noticed that while the area 3 cm. below the lesion is a mere pin point, the area above the lesion at a similar distance is reduced very little in size. An attempt was made to account for this difference, since the same state of affairs seemed to exist in several of the human cords in our collection. The area of invasion being the ventral part of the dorsal white columns, the fibers involved are the fasciculi proprii of the region of the cord. In the cervical region, where great numbers of the afferent fibers enter the cord, coming principally from the upper extremities, the fibers of the fasiculi proprii are also increased in number, particularly the ascending fibers. The descending fibers are pressed on dorsally by the ascending fibers that have entered at the segment below, and at the same time these descending fibers are diminishing in number, owing to their entrance into the gray matter.

The reverse is also true, i. e., the ascending fibers, though they too are diminishing in number, still are pushed dorsally as they pass up the cord, owing to the presence ventrally of the descending fibers from the segment above. In the thoracic region, though the number of entering fibers is greatly reduced, there is still a slight tendency of the area involved above to be slightly larger, owing possibly to the proximity of the cervical enlargement above.

An effort was made to confirm this grossly. A portion of cervical cord, fixed in formaldehyd, was split in halves by an incision through the anteromedian fissure and posteromedian septum. A portion of the ventral part of the dorsal white columns was then taken in the forceps, and, when it was stripped from above downward, the cavity thus formed decreased in caliber from above downward, forming an apex about two segments below. This is illustrated in Figure 15. The same diagram shows the result of stripping a similar area from below upward, the cavity thus formed remaining approximately the same in diameter, and sometimes increasing slightly. Thus, pulp entering the area of least resistance and passing down the cord follows along the course of these fibers; and, thus advancing, it is caused to take a path that is gradually decreasing in diameter, being pressed toward the center of the cord until its force is expended. On the other hand, when the pulp is forced up, its area of involvement, following the course of ascending fibers, maintains a constant diameter, sometimes increasing and sometimes decreasing, as the force diminishes.

When a portion of the thoracic cord was treated in a similar manner, the result was a cavity of approximately the same diameter, regardless of the direction of stripping the fibers. Figure 14 is illustrative of this fact in the thoracic region. Hence, one would expect that a lesion occurring in the thoracic region would cause a column of pulp to invade the neighboring segments, which would have about the same diameter when traced in either direction, becoming narrower only near the extremities, when the force is almost exhausted.

LATE CHANGES IN THE CORD

Gordon Holmes [2] describes very accurately the secondary changes in the cord as a result of war injuries. He describes the cavities very minutely, and the description which he gives holds absolutely for the condition which was found in our experimental lesions.

A comparison of the cord sections of Dog 2, Figure 1, and of Dog 8, Figure 8, will serve to illustrate the changes which take place above and below the site of the lesion in the injured cord. Dog 2, it

2. Holmes, Gordon: The Goulstonian Lectures on Spinal Injuries of Warfare, Brit. M. J. **2**:769, 815, 855, 1915.

will be remembered, lived two weeks; whereas, Dog 8 lived but four days. The striking feature in a comparison of these cords is the fact that the cavity in the former cord is identical in position with the invading pulp area in the latter. Thus, the condition of Dog 2, ten days before its death, was probably identical with the state of the cord of Dog 8 at the time of its death. In other words, a study of these cords would indicate that, following the invasion by the blood and

Fig. 17.—A human cord which was subjected to postmortem pressure. Arrow points to lesion.

pulp up and down the cord, with the pushing aside of white matter, and the isolation of some white matter with its destruction either by pressure or by rupturing of, or pressure on, walls of blood vessels in the area invaded, a process of absorption sets in, with the ultimate liquefaction and removal of all invading blood and pulp and destroyed cord substance.

Figure 16 shows the progressive changes which take place in the process of cavity formation. The drawings were made to scale by use of microprojection apparatus, and each represents the same relative position in the cord, i. e., just posterior to the central canal and including a portion of the cord in the area immediately adjacent to the invaded area, and some of the invaded area in each case. In the dog that lived forty hours, the pulp mass is slightly separated from the adjacent cord, and there are found a few glial cells of the ameboid and granular type in the débris as well as in the cord adjacent. In the dog that lived four days, the pulp material was not so dense, and the number of glial cells was increased both in the débris and in the walls of the peripheral matter. In the dog that lived two weeks, it will be noted that only a liquid remained in the area formerly occupied by the pulp, and the turbidity of this liquid was dependent on the vacuolated glial cells which it contained. That a glial reaction had occurred was evident from the thickening of the walls of the cavity.

The result is that cavity formation is brought about in that part of the cord corresponding to the area involved in the invasion by the pulp. An examination of the section immediately above the lesion (compare this section in Figure 6) would indicate that this area of the cord, owing to the irregularity of the cavity and its cavernous type, was the site which, during the passage of the pulp, represented the area of deflection. Thus, the pulp, in ascending and at the same time shifting gradually toward the area of least resistance, tunnelled the cord substance in this area which, being followed by liquefaction, left many irregular channels, all leading into the main cavity above. Hence, this cord adds to the evidence in favor of the course of the pulp being gradually diverted to the posterocentral area of the cord.

HUMAN CORD

A human cord was obtained at necropsy, which was performed fourteen hours after death. Laminectomy was performed in the dorsal region and about 5 inches of cord in dura was resected. It was then placed on a firm surface, and pressure was made with the finger in the dorsal region of the cord. As the pressure was being made, the segments of the cord above and below the lesion were noticed to bulge; and after the finger was removed, the cord remained ribbonlike but not without some return of pulp to the area on release of pressure. The dura was then slit up, and the whole placed in 10 per cent. formaldehyd to harden.

The gross cord appeared very like the specimens from cases of actual fracture of the spine which we have in our collection. Figure 17 shows a photograph of this cord. It is flattened and ribbonlike

at the site of lesion. Sections above and below the lesion show the presence of pulp matter in the posterocentral part of the cord.

Microscopic sections appear in Figures 18 and 19. Their great similarity to the dog cords should be noted. Two cubic millimeters above the lesion there is a practically normal cord, with the exception

Fig. 18.—Section of cord shown in Figure 17, 2 cm. above the lesion. The pulp has definitely invaded and pushed aside the dorsal columns. Arrow points to high power photograph of area outlined showing lymph spaces, which suggests that such a condition may be mechanical rather than vital.

of the dorsal columns. A mass of pulp occupies the ventral part of the dorsal white columns, being present to one side of the midline. The white column of the other side is pushed aside and compressed. There

are a few white fibers isolated and included in the pulp-invaded area. The pulp mass is laminated. The dorsal gray horn nearest the pulp mass is bowed out and compressed, with its concavity toward the pulp mass. The anterior horns are normal. The pia is everywhere intact, and the anteromedian fissure has its normal relations. The central canal has not been destroyed, though its walls have been approximated by the pressure. The presence of many swollen nerve sheaths in lateral white columns, giving them a vacuolated appearance, raises the question as to whether this condition is a vital or a mechanical one, and requires further investigation. One cubic millimeter above the lesion, the area occupied by the mass of pulp is much greater, involving nearly all of

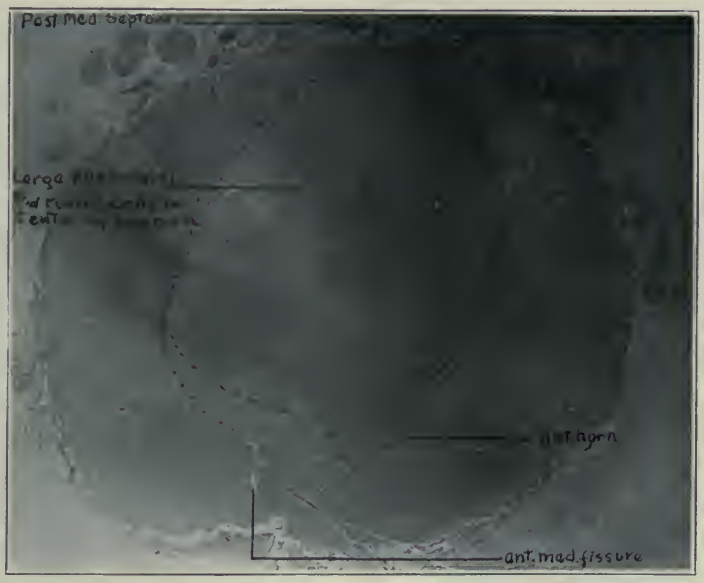

Fig. 19.—Section of cord shown in Figure 17, 1 cm. below the lesion. The area of pulp invasion is greater, and in the center may be seen several large pyramidal and oval cells having the appearance of cells of anterior horn and nucleus dorsalis.

the dorsal white columns except a small zone adjoining the pia. The cord around the mass has been pushed aside and shows signs of compression. The center of the pulp mass shows a few large cells which are not unlike anterior horn cells and some others which are very evidently cells from the nucleus dorsalis. No section was made through the lesion, for here the cord was reduced to a mere empty tube of pia mater containing some pulp material which returned to the area after the pressure was released. One cubic millimeter below the lesion, the state of affairs is very similar to that existing 1 cm. above.

It seems that this experiment with the human cord proves beyond a doubt the pulp invasion theory. When the cord was subjected to pressure, no doubt what actually occurs in fracture dislocations which crush the cord was reproduced. The segments above and below the site of pressure were seen to bulge, owing to the slight elasticity of the pia. The pressure was released and the cord remained flattened, though some of the pulp material returned to the area. Then the cord was sectioned, and the pulp material was found above and below the lesion in the location observed in all of our dog experiments and our actual

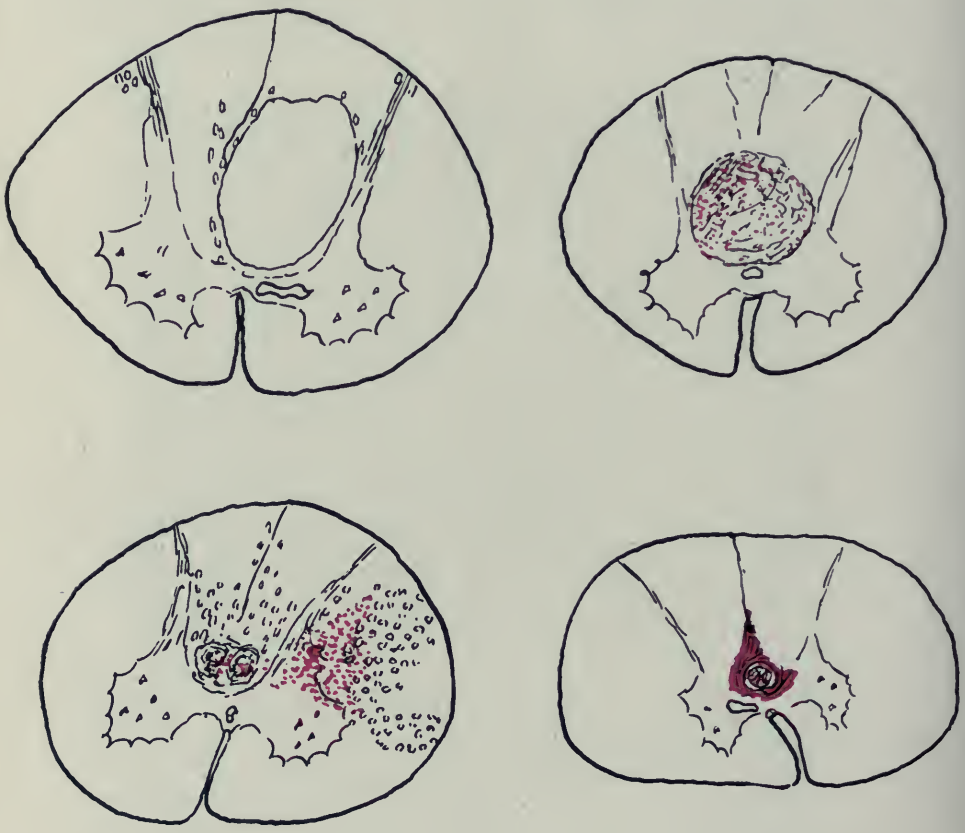

Fig. 20.—Sections of cords from actual cases of fracture dislocation for comparison with experimental lesions. Above, left: Section of cord below lesion of second vertebra. The patient lived three weeks. Right: Section of human cord, 1 inch (2.5 cm.) below lesion. The fracture included the seventh cervical vertebra and extended to the first thoracic vertebra (patient lived forty-eight hours). Below, left: Section of human cord above lesion in fracture of the sixth and seventh cervical vertebrae (patient lived six days). Right: Section of human cord, 1 cm. above lesion of fifth and sixth cervical vertebrae (patient lived one day).

cases as well. The condition found also corresponds to the pictures and descriptions which Gordon Holmes gives in his article on war injuries.[2]

For comparison, we have included four sections (Fig. 20) taken from cases of actual cord crushes due to fracture dislocation of the spine. These should be compared with the cords of dogs, with particular reference to the position and similarity of the invading pulp and blood or of the cavity. Thus, there is a striking likeness in the case of the section (1.5 cm. above the lesion) of the cord of Dog 2, Figure 6, and the section above the lesion from the case illustrated above, left, in Figure 20. Sections of cords from Dogs 1, 8 and 9 compare very favorably with the remaining (human) cases in Figure 20. Another point which should be called to the attention is the still further similarity when one considers the period of time elapsing between crush and death.

Experimental lesions as we have produced them in dogs and in human cords obtained at necropsy are comparable to actual cord lesions in man in all respects, but more especially as regards the mechanical factors as we have discussed them, and the early and late pathologic pictures. The progressive vital changes in the area of the cord involved are strikingly similar. Hence, our conclusions may be applied to actual cases of cord crush.

CONCLUSIONS

1. In partial lesions of the cord, there is usually not sufficient pressure to convert the cord at the site of lesion completely to pulp, and what little pulp is formed is not under sufficient pressure to track very far up and down the cord. That part of the adjacent cord which is invaded, however, is usually an area similar to that invaded in complete lesions, and the principles involved are the same.

2. Edema and hemorrhage are factors to be dealt with in partial lesions and concussions. Massive hemorrhages do not occur as a rule, and small scattered hemorrhages are most often observed. These are probably not extensive enough to produce serious injury, of themselves. Edema comes on within eight hours and attacks the dorsal white columns principally, but it is frequently quite marked in the lateral and anterior columns as well. Time is a factor, since edema seems more marked in proportion to the length of time the dog lives. A marked intrapial pressure is developed as the result of the edema. This becomes more evident when the dura and pia are incised and this pressure is released. Judging from the case in which the dura was nicked, it seems that operative procedure would cause a further destruction of the cord substance without the relief of the edema in areas of the cord often affected. The release of the pressure seems to have no effect in checking edema formation.

3. In complete lesions of the cord, the cord at the site of the lesion is reduced to a pulp and blood mixture, and the ends of the cord separate for a short interval. The pulp is forced into the segments above and below the lesion and causes an increased intrapial pressure, which is released in one of two ways: either the pia ruptures or the pulp tracks up and down the cord until the intrapial pressure is relieved. After an interval, in cases in which the pia remains intact and the local pressure is relieved, a bloody mass returns and fills the gap between the separated ends. If local pressure is maintained, as would be the case in an uncorrected fracture dislocation, no return of pulp would be possible.

4. The area of the cord involved in complete lesions is the area of least resistance, located in the ventral part of the dorsal white columns and that part of the central gray matter dorsal to the central canal. This locality is chosen because of the weaker anatomic structure of this area as compared with other areas.

5. In complete lesions, the area of cord involved in the pulp invasion tends to be larger above the level of the injury in the lower cervical and upper dorsal regions, and consequently more damage results in such regions. This is probably true also in the region of the lumbar enlargement.

6. Liquefaction of the pulp and the area of the cord involved in the débris in complete lesions sets in after forty-eight hours; is progressing rapidly at the end of four days, and is completed within two weeks. Thus, the syringomyelic cavity and symptoms above the level of the lesion and cavity below in many old cases of fracture of the spine are accounted for. The process is brought about by the rupture of or pressure on blood vessels supplying the involved area, and the pressure on the included nervous tissues which are pushed aside. The presence of an increasing number of ameboid and granule glial cells in this area suggests their phagocytic function.

PROGNOSIS AND TREATMENT OF FRACTURES OF THE LEG AND ANKLE *

END-RESULTS IN ONE HUNDRED PATIENTS

ASTLEY P. C. ASHHURST, M.D.

AND

EDWARD T. CROSSAN, M.D.

PHILADELPHIA

Prognosis is defined as the art of foretelling the course and termination of a disease. In no case can one give any accurate prognosis without knowing from his own experience or from that of others what have been the course and termination of similar cases. Hence arises the importance of studying end-results as well as the clinical course of the disease.

It was shown in the report on fractures of the tibia and fibula presented to this association in 1921 [1] that among a total of 914 such fractures analyzed, good function was secured in 71 per cent. of cases, moderate function in 20 per cent. and bad function in 9 per cent. (Table 10); that the average period of disability in simple fractures was four months for ankle fractures and 4.7 months for fractures of the leg proper; while in compound fractures the average period of disability was five and seven-tenths months for the ankle fractures, and seven months for those of the leg (Table 12). It was further noted that these investigations merely pointed the way for further improvement in our means of treating fractures of the tibia and fibula; and that no surgeon having such fractures under his care should rest satisfied until he could publish a series of end-results which in the aggregate would be superior to those therewith reported, since these were merely the average.

It was with this in mind that the present investigation was undertaken. We have compiled accurate records of the end-results in 100 of 152 fractures of the leg and ankle treated in recent years in the service to which we are attached at the Episcopal Hospital, Philadelphia. With few exceptions, the patients have been personally examined by us or by Dr. I. M. Boykin. In the other cases, accurate reports have been secured by letter or by interviews with the social service workers of the hospital. Thirteen of these 152 cases were considered too recent for inclusion in a report of "end-results"; so that we have traced 100 of 139 cases, or 72 per cent. of the entire number treated (Table 1).

---

* Read at a meeting of the American Surgical Association, June 2, 1923.

1. Ashhurst. A. P. C.: Tr. Am. Surg. A. **39**:528, 1921.

TABLE 1.—*Sites of All Fractures*

	Total	Nonoperative	Operative*
Fibula, shaft	5	5	..
Tibia, shaft, above middle	4	4	..
Tibia, shaft, below middle	16	15	1
Tibia and fibula, shafts, above middle	9	9	..
Tibia and fibula, shafts, below middle	22	14	8
Ankle A†	26	24	2
Ankle B	11	8	3
Ankle C	7	7	..
	100	86	14

* This does not include tenotomy of the Achilles tendon for reduction, two cases; Steinmann pin extension from os calcis, seven cases; nor one case of arthrotomy and suture of the knee for hemarthrosis.

† See footnote to Table 4.

TABLE 2.—*Results in All Cases*

		Functional Result		
Anatomic Result	Cases	Good	Moderate	Bad
Good	81	67	13	1
Moderate	17	5	12	0
Bad	2	0	1	1
	100	72	26	2

TABLE 3.—*Results in Leg Fractures*

	Cases		Functional Result				
			Good		Moderate		
Anatomic Result	Number	Per Cent.	Number	Per Cent.	Number	Per Cent.	Bad
Good	43	77	39	91	4	9	0
Moderate	12	21	4	33	8	66	0
Bad	1	2	0	..	1	100	0
	56	100	43	77	13	23	0

TABLE 4.—*Results in Ankle Cases**

Anatomic Result	Cases	Functional Result: Good	Moderate	Bad
Good	A21, B10, C 7 — 38 (86%)	A16, B 7, C 5 — 28 (74%)	A 4, B 3, C 2 — 9 (23%)	A 1, B 0, C 0 — 1 (2%)
Moderate	A 4, B 1, C 0 — 5 (11%)	A 0, B 1, C 0 — 1 (20%)	A 4, B 0, C 0 — 4 (80%)	A 0, B 0, C 0 — 0
Bad	A 1, B 0, C 0 — 1 (3%)	A 0, B 0, C 0 — 0	A 0, B 0, C 0 — 0	A 1, B 0, C 0 — 1(100%)
	44	29 (67%)	13 (30%)	2 (3%)

* A signifies fractures at ankle caused by external rotation of foot; B, those caused by fibular flexion (abduction), and C, those caused by tibial flexion (adduction) of foot (Ashhurst, A. P. C., and Bromer, R. S.: Classification and Mechanism of Fractures of the Leg Bones Involving the Ankle, Arch. Surg. 4 : 51 [Jan.] 1922).

The tables presented herewith are compiled in accordance with the plan of the Fracture Committee of this association, in its 1915 report. It is worth while recalling once again the definitions of this report: The anatomic result denotes the position assumed by the fragments of bone at the time of consolidation. In children, especially, a bad anatomic result in this sense may eventually prove to be a very good anatomic result, but in strict accord with our definition we have counted no anatomic result good unless at the time of consolidation there was present accurate anatomic reposition of the fragments. If such absolute anatomic reposition was not secured, the anatomic result has been recorded as "moderate," even if eventually the bone ends became rounded off so that no palpable deformity remained when the patient was last examined. Any gross anatomic deformity or any appreciable shortening (over 2 cm.) has been classed as a bad anatomic result (Tables 2, 3 and 4).

So also with regard to functional results, we have followed the Fracture Committee's criterion that a good functional result implies the absence of any disability whatever. If there is pain in damp weather, if the patient tires more easily, if after long standing or walking the foot or leg swells or if there is any limp, we have classed the functional result as moderate only, even if the patient has resumed his normal occupation and makes the same wages. Any real incapacity interfering with work has been classed as a bad functional result. We are happy to say such a result occurred only in two patients, both with fractures at the ankle. One of them, aged 40 years, did not come under our care for some weeks after her injury, when it was impossible to secure reduction. She has been unable to do any work since her accident eight years ago. The other patient, who also had an ankle fracture, was a woman, 43 years of age, who came under our care several days after injury, with great swelling and ecchymosis. As two attempts under a general anesthetic failed to secure reduction, she was operated on ten days after the accident, and though a good anatomic result was obtained, pain and disability persist to such an extent after two and one half years that the result must be considered bad.

We give in Table 5 a short summary of the cases in which a good functional result was not obtained. It may be noted that to all intents and purposes many of these patients have entirely satisfactory function; but as it is not perfect, we have classed the results with *moderate*, not *good*, in accordance with the definitions already adopted.

Of the 26 patients who recovered only moderate function, 17 had, and 9 had not, a lessening of endurance; 10 had, and 16 had not, pain at any time; 4 had, and 22 had not, a limp; 3 had, and 23 had not,

swelling; 3 had, and 23 had not, limitation of motion. Among our 100 end-results reported, shortening was noted in four:

Case 1.—A man, aged 57, had 1 cm. shortening, following a comminuted fracture treated by Steinmann nail traction. He was out of work nine months, and anatomic and functional results were both classed as moderate, since he had appreciable shortening and had a slight limp, and complained of pain in wet weather.

Case 2.—A man, aged 37, had 2 cm. shortening following a comminuted fracture of the upper ends of the tibia and fibula involving the knee joint, with marked hemarthrosis, for which arthrotomy was required. He was out of work three months, and anatomic and functional results were classed as moderate, as he limped in fast walking and had slightly less endurance, though he resumed his job at his former wages.

Case 3.—A man, aged 41, had 2 cm. shortening. He refused operation for a simple fracture of the shaft with marked displacement; was out of work fifteen weeks, and recovered perfect function.

Case 4.—A man, aged 48, with 2.5 cm. shortening, following a compound comminuted fracture of the shafts, which was inefficiently treated by extension through a Sinclair skate, was out of work ten months, and recovered with a bad anatomic result (shortening over 2 cm.) and only moderate function, as he had less endurance and made less wages, though working at the same job as before his injury. He had also a fracture of the patella of the other knee.

One patient had lengthening of 1 cm. in the fractured leg, following plating for irreducible displacement. He was out of work fourteen months (from no apparent cause), and secured a good anatomic and functional result. The plate was still in place when he was last seen, over six years after the injury. Bony union was secured in all the 152 cases treated. There were two or three cases in which union was delayed, especially in compound fractures, but no case of nonunion was seen. Nor did any case of peroneal paralysis occur.

It was pointed out in the 1921 report on fractures of the tibia and fibula that the reporters of many of the cases then analyzed had been less strict than the Committee in adhering to its definitions, as some reports then received classed as "good" anatomic results cases in which shortening of as much as 3 cm. was recorded; and as "good" functional results cases in which pain in damp weather persisted or there was evident, but not disabling, limitation of motion, and disability was partial, not entirely absent. In comparing the results there recorded, with those now presented (Table 10), this comparatively optimistic view afforded by the 1921 statistics should be kept in mind. We repeat that in our own cases, only those results have been classed as good functionally in which there was complete absence of any symptoms referable to the fracture. One patient was encountered who maintained that since he had broken his leg it was even better than before the accident.

TABLE 5.—*Patients Recovering Only Moderate Function*

Name, Age and Year Seen	Sex*	Fracture	Treatment	Anatomic Result	Time, Out of Work, Months	Disability	Same Position	Same Wages
			Shaft Fractures					
M. C., 55, 1916	♀	Into knee joint	Fracture box 1 week; circular cast	Good	6	Knee flexes only to 90°; patient limps when tired	Yes	Yes
H. B., 65, 1921	♂	Upper third spiral	Fracture box 3 days; gypsum splints	Good	14 (law suit)	Less endurance after 2 years	Lower	Less
M. B., 57, 1922	♂	Lower third	Fracture box 4 days; then Steinmann pin	Moderate	9	Pain in wet weather; slight limp	Yes	Yes
E. C., 25,1920	♀	Lower half comminuted	Gypsum splints	Moderate	4	Pain in wet weather; less endurance after 3 years	Yes	Yes
T. D., 48, 1919	♂	Lower third compound comminuted	Sinclair skate	Bad	10	Less endurance; also had fractured patella of the other knee	Yes	Less
S. G., 32, 1916	♂	Upper half compound comminuted	Gypsum splints	Good	1	Knee flexes only to 70°; pain in wet weather	Yes	Yes
W. H., 34, 1916	♂	Lower half compound	Steinmann pin	Moderate	8	Less endurance	Lower	Less
A. H., 47, 1915	♀	Lower half compound comminuted (Figs. 11 to 13)	Steinmann pin	Moderate	?	Pain in wet weather after 5½ years	Yes	Yes
C. McK., 38, 1922	♂	Lower third compound comminuted	Steinmann pin	Good	6	Pain and swelling toward night after one year	Yes	Yes
J. M., 32, 1922	♂	Double fracture of tibia and fibula, compound (Fig. 18)	Smith clamps and Steinmann pin	Moderate	9	Less endurance; wore brace 1 year	Yes	Yes
J. P., 37, 1916	♂	Comminuted into knee	Arthrotomy for hemarthrosis; gypsum splints	Moderate	3	Slightly less endurance; limps in fast walking	Yes	Less
M. S., 16, 1921	♂	Lower third compound comminuted	Steinmann pin	Moderate	3	Pain in wet weather; less endurance	Yes	Yes
J. S., 60, 1920	♀	Lower half comminuted	Gypsum splint	Moderate	6	Pain, swelling less endurance	?	?
			Ankle Fractures †					
P. B., 66, 1921	♀	Ankle A 2x	Fracture box 6 days; gypsum splints	Moderate	4	Swelling; less endurance (has generalized arthritis deformans)	Yes	Yes
H. C., 54, 1912	♂	Ankle A 2x	Fracture box 17 days; tenotomy, Achilles tendon and gypsum splints	Moderate	6	Less endurance; had former severe injury to both knees	Yes	Yes
P. D., 67, 1919	♂	Ankle A 2x	Fracture box 2 weeks; circular cast	Good	?	Pain at times; less endurance	Lower	One-half
J. O'M., 47, 1921	♂	Ankle A 1	Adhesive strapping	Good	Nearly 12	Some pain; less endurance	Yes	Yes
I. E., 61, 1920	♀	Ankle A 2x	Gypsum splints	Moderate	6	Pain in wet weather; less endurance	Lower	Less
S. B., 54, 1907	♀	Ankle A 2 with posterior subluxation	Fracture box 13 days; tenotomy, Achilles tendon	Moderate	?	Limp; less endurance	Yes	Yes
T. M., 28, 1921	♂	Ankle A 1	Fracture box 3 days; gypsum splints	Good	6	Painful rigid flat foot; less endurance	Lower	Less

* In this column, ♀ indicates female; ♂, male.

† See footnote to Table 4. A 1 signifies first stage of fracture by external rotation; A 2, second stage of fracture by external rotation, etc.; x, presence also of a posterior marginal fracture of the tibia.

TABLE 5.—*Patients Recovering Only Moderate Function—(Continued)*

Name, Age, and Year Seen	Sex*	Fracture	Treatment	Anatomic Result	Time, Out of Work, Months	Disability	Same Position	Same Wages
E. E., 25, 1920	♂	Ankle B 2a	Screw fixation	Good	6	Pain in wet weather; can walk 2 miles	Yes	Yes
M. H., 46, 1920	♂	Ankle B 2a	Fracture box 3 days; gypsum splints	Good	3	Less endurance	Lower	Less
C. McG., 39, 1919	♀	Ankle B 2b (Fig. 7)	Fracture box 12 days; gypsum splints	Moderate	6	Wore brace one year; less endurance	Yes	Yes
A. V., 28, 1921	♂	Ankle B 3 compound comminuted (Figs. 14 and and 15)	Plate immediately, removed in 10 days (infection); then Steinmann pin	Good	Over 18	Wore brace one year; stiff ankle	No	Less
A. M., 42, 1920	♂	Ankle C 2	Fracture box 3 days; gypsum splints	Good	6	Left foot turns easily; wears arch supporter; very heavy man; right ankle also fractured same time, gives no disability	Yes	Yes
B. P. 59, 1920	♀	Ankle C	Fracture box 6 days; gypsum splints	Good	8	Pain at times; less endurance; has varicose veins	No	Less
R. M., 40, 1914‡	♀	Ankle A 2	Fracture box; circular cast	Bad	Still, after 6 years	Complete	....	...
S. P., 43, 1920‡	♀	Ankle A 2x	Screw fixation (screws removed 10 months later for pain)	Good	12	Pain in wet weather; limited motion; less endurance	Lower	Yes

‡ The functional end-result in the last two cases was bad.

TABLE 6.—*Results in All Cases (Nonoperative)*

Anatomic Result	Total	Functional Result: Good	Moderate	Bad
Good	70 (82%)	59 (84%)	11 (16%)	.....
Moderate	14 (16%)	3 (21%)	11 (79%)	.....
Bad	2 (2%)	.....	1 (50%)	1 (50%)
Total	86 (100%)	62 (72%)	23 (27%)	1 (1%)

TABLE 7.—*Results in All Cases (Operative)*

Anatomic Result	Total	Functional Result: Good	Moderate	Bad
Good	11 (78%)	8 (73%)	2 (18%)	1 (9%)
Moderate	3 (12%)	2 (66%)	1 (33%)	.....
Bad	.....	.....	.....	.....
Total	14 (100%)	10 (72%)	3 (21%)	1 (7%)

TABLE 8.—*Results in Simple Fractures (All Sites)*

Anatomic Result	Total	Functional Result: Good	Moderate	Bad
Good	71 (82%)	60 (85%)	10 (14%)	1 (1%)
Moderate	13 (16%)	4 (30%)	9 (64%)	.....
Bad	1 (2%)	.....	.....	1 (100%)
Total	85 (100%)	64 (75%)	19 (22%)	2 (3%)

TABLE 9.—*Results in Compound Fractures (All Sites)*

Anatomic Result	Total	Functional Result: Good	Moderate	Bad
Good	10 (67%)	7 (70%)	3 (30%)	.....
Moderate	4 (26%)	1 (25%)	3 (75%)	.....
Bad	1 (7%)	.....	1 (100%)	.....
Total	15 (100%)	8 (53%)	7 (47%)	.....

TABLE 10.—*Functional End-Results (All Cases)*

	Total		Good		Moderate		Bad	
	A. S. A.*	A. & C.†	A. S. A	A. & C.	A. S. A.	A. & C.	A. S. A.	A. & C.
Simple	625 (68%)	85 (85%)	468 (75%)	64 (75%)	114 (18%)	19 (22%)	45 (7%)	2 (3%)
Compound	289 (22%)	15 (15%)	180 (62%)	8 (53%)	69 (24%)	7 (47%)	40 (14%)	.....
Total	914	100	648 (71%)	72 (72%)	183 (20%)	26 (26%)	83 (9%)	2 (2%)

* A. S. A., American Surgical Association 1921 Report on Fractures of Tibia and Fibula.
† A. & C., present report by Ashhurst and Crossan.

TABLE 11.—*Influence of Age on Functional Result*

Anatomic Result	Total	Functional Result: Good	Moderate	Bad
Under 15 Years:				
Good	17 (85%)	17 (100%)	.....	.....
Moderate	3 (15%)	2 (67%)	1 (33%)	.....
Bad	.....	.....	.....	.....
Total	20 (100%)	19 (95%)	1 (5%)	.....
Over 15 Years:				
Good	64 (80%)	50 (78%)	13 (20%)	1 (2%)
Moderate	14 (18%)	3 (21%)	11 (79%)	.....
Bad	2 (2%)	.....	1 (50%)	1 (50%)
Total	80 (100%)	53 (65%)	25 (33%)	2 (2%)

TABLE 12.—*Average Period of Disability (All Cases)*

	Total				Simple				Compound			
Fracture	A.S.A., 1921	Disability, Mos.	A.& C.	Disability, Mos.	A.S.A.	Disability, Mos.	A.& C.	Disability, Mos.	A.S.A.	Disability, Mos.	A.& C.	Disability, Mos.
Shafts	413	5.2	51	4.3	331	4.7	39	3.8	82	7.0	12	5.5
Ankle	233	4.4	35	4.3	225	4.0	35	4.3*	8	5.7	..	...
Total	646	4.9	86	4.3	556	4.4	74	4.0	90	6.8	12	5.5

* One case of simple fracture of ankle resulted in complete disability; not included in above.

TABLE 13.—*Average Period of Disability*

Fracture	All Cases	Average Period of Disability, Months	Simple Fracture	Average Period of Disability, Months	Compound Fracture	Average Period of Disability, Months
Fibula, shaft	5	2.5	4	2.6	1	2.0
Tibia, above middle	2	3.5	2	3.5	..	...
Tibia, below middle	15	3.1	13	3.0	2	3.5
Tibia and fibula, above middle	9	4.7	7	5.0	2	3.5
Tibia and fibula, below middle	20	5.3	13	4.4	7	7.1
Total	51	4.3	39	3.8	12	5.5
Ankle A*	21	4.3	21†	4.3	..	...
Ankle B	9	3.9	9	3.9	..	...
Ankle C	5	5.0	5	5.0	..	...
Total	35	4.3	35*	4.3	..	...

* See footnote to Table 4.
† One with complete disability not included in the above.

SIMPLE FRACTURES

Treatment on Admission.—The usual course of treatment followed in these cases has been about as follows: On admission to the hospital, the skin is carefully washed, and if necessary shaved, and rubbed with alcohol, so as to prevent infection of any bullæ which may develop, or of a more deeply placed hematoma. We are convinced that such infection often arises from neglect in caring for the skin surface. The leg is then placed in a fracture box, gross displacements being corrected, and efforts being made to have the pillow inside the fracture box of such size and thickness as to maintain the limb in as nearly correct position as possible. Pads of raw cotton, folded towels or other material are used between the fracture box and the pillow (not between the latter and the leg) to aid in maintaining reduction. The patient is then sent in his bed (all beds are on wheels) to the roentgen-ray laboratory. In fractures of the shafts of the leg bones, no further reduction is attempted unless gross displacement is shown by the x-rays. In ankle fractures, every effort is made to secure accurate anatomic reposition of the fragments; but in fractures of the shafts, we have been content to secure union without appreciable shortening and without axial or rotatory displacement, even if anatomic reposition was not secured. Thus (Tables 3 and 4), in leg fractures, we secured only 77 per cent. of anatomic repositions (resulting in good function in 91 per cent. of the cases); and in ankle fractures, 86 per cent. of anatomic repositions (with good function in only 74 per cent. of these cases).

Cases Without Gross Displacements.—Usually, the leg has remained in the fracture box several days, or until there occurred subsidence of the swelling present on admission or developing within a few hours. Formerly, circular plaster-of-Paris dressings were applied at this stage, and were left undisturbed until union was believed to have occurred. But since about 1914, such dressings have been abandoned entirely, in favor of molded gypsum splints, as introduced by Stimson. The patient's leg, from toes to midthigh, is bandaged, not too snugly, with flannel bandages, and over these the gypsum splints are applied. These splints are made by soaking, one at a time, the ordinary roller bandage of plaster of Paris (about 10 cm. wide) in warm water, and then running it back and forth on itself as it is unrolled, on a smooth surface (table top), until a splint of suitable thickness and length has been secured. Usually, two or, at the most, three roller bandages are used for each splint, three of which are made, each being applied to the leg before the next is prepared. The first splint passes down the

back of the limb from well above the knee under the calf and heel, and is turned up along the sole of the foot to terminate at the toes. This splint is then bandaged snugly to the leg with circular turns of a flannel bandage, all parts of the splint being carefully covered so that the splint next to be applied will not adhere to the first. The second splint is applied with one end on the dorsum of the foot, passing thence around the outer border of the foot, across the sole and up the inner side of the limb to the midthigh. Its initial extremity should not extend so far across the dorsum of the foot as to touch the edge of the same splint as it passes from the sole up the inner side of the leg, since if these moist margins come into contact one will adhere to the other. The second splint is then carefully covered by a flannel roller; and over it the third splint is applied, covering the dorsum of the foot, the sole, and the outer side of the leg and knee, and is itself held in place by a roller bandage. The great advantage of these splints applied in this way is not only that there need be very little disturbance of the fracture during their application (very much less than in the application of a circular case), but that injurious circular constriction never occurs, and, what is probably most important of all, the two lateral splints can be conveniently removed weekly or oftener for proper dressing of the soft parts without disturbing the posterior splint or the fragments. Patients with these splints have their fractures just as securely fixed as with a circular case, and may be allowed to be out of bed and to use crutches with the same impunity. Crutches seldom are used, nor is the patient allowed to have his leg dependent until three or four weeks after the injury. When union appears good, the patient is encouraged to bear a little weight on the limb, and then one of the gypsum splints is discarded at a time, until usually about the sixth to the eighth week the patient is using crutches without any splints. Seldom has troublesome swelling occurred during convalescence. This is attributed to the care of the soft parts during the time the bones were uniting. Weekly or oftener, when the lateral splints are removed, the patient is able to make active movements of the foot without disturbing the fracture; and as soon as enough union is present to prevent displacement of the ends (usually after two weeks), the entire limb can be raised by the surgeon from the posterior splint, and a little motion may be permitted at the knee. Very light *effleurage* is employed by the surgeon at each dressing. This amounts to little more than sponging the skin with alcohol, drying it well, and rubbing in some talc powder with the hand. It is seldom found necessary to have formal treatment by baking and massage instituted during convalescence when proper care has been taken of the soft parts from the first.

In shaft fractures with marked displacement and in ankle fractures in every case with any displacement whatever, efforts are made as soon as possible to correct the displacement. For this, a general anesthetic is given almost always. In shaft fractures, attempts have been made to secure reduction by dressing the leg in Pott's position (lying on its outer side with the knee flexed), but without success. Subsequent roentgen-ray examination has seldom shown any marked improvement in the position of the bones, even when the appearance of the soft

Fig. 1 (E. G., man aged 32, Sept. 16, 1916, on admission).—Left: Compound fracture of tibia and fibula from kick by horse. Free bleeding was controlled by compress. Attempted reduction on fracture table, with mechanical traction under anesthesia was not successful. A plate was applied seven days after injury. Right: Appearance ten days after operation. The patient was out of work six months. A perfect anatomic and functional result was obtained.

parts indicated good reduction; and in a few cases, the displacement has been increased when Pott's position was employed. In some cases with marked displacement (Fig. 1), it is evident that attempts at closed reduction will do more damage to the soft parts than will an operation; and in such cases, no attempts at reduction are made until the bones are

exposed at operation. In other cases, particularly comminuted fractures, it is evident that, even if secured, reduction could not be maintained without continuous extension; and in these, the principle of skeletal traction has been employed by means of the Steinmann pin through the calcaneum. This plan will be described in speaking of compound fractures. In three cases of fractures in the upper third

Fig. 2.—Equinus-lever of Gwilym G. Davis. The leather strap passes across the instep, and the cross bars beneath the ball of the foot. The operator, steadying the far end of the lever in his own axilla, has complete control of the patient's foot.

of the tibia, the ordinary Buck's extension apparatus was advantageously employed. In ankle fractures, reduction frequently may be secured by manual manipulation under anesthesia. In a few cases, we have employed with advantage the equinus lever of G. G. Davis

(Figs. 2, 3, 4); in others, it has failed to procure reduction (Figs. 5 and 6). In two cases (seen in 1907 and in 1912), in which the fracture was not reduced for two weeks and for three weeks, respectively, it was necessary to perform a tenotomy of the Achilles tendon. These patients did not secure perfect function. Each was 54 years of age, and recovered with somewhat lessened endurance and a slight limp. If reduction of an ankle fracture cannot be secured after one or two

Fig. 3 (L. K., woman, aged 69, Sept. 5, 1916, on admission).—Left: Ankle fracture by external rotation, second degree: (1) spiral fracture of fibula through inferior tibiofibular joint, (2) fracture of internal malleolus; complicated by a posterior marginal fracture of the tibia, and with posterior subluxation of the foot (A2x); anteroposterior view before reduction. Right: Lateral view.

attempts under general anesthesia, operative reduction is advised. It was adopted in six of seventy-nine cases of simple fracture, and in all of them screw fixation was employed (Figs. 5 and 6). Some patients refuse any operation (Fig. 7).

Delbet's Gypsum Apparatus.[2]—During the last year, we have employed this apparatus in every case of leg fracture in which it did not seem contraindicated; that is, in about ten cases. We have to thank Dr. Mercier, Dr. Bourgeois and their staff, at Notre Dame Hospital, Montreal, for demonstrating the application of this apparatus. The chief advantages of the apparatus are: 1. It is applied during continuous traction on the foot by weight and pulley, this traction serving to secure sufficiently accurate reduction of fractures of the

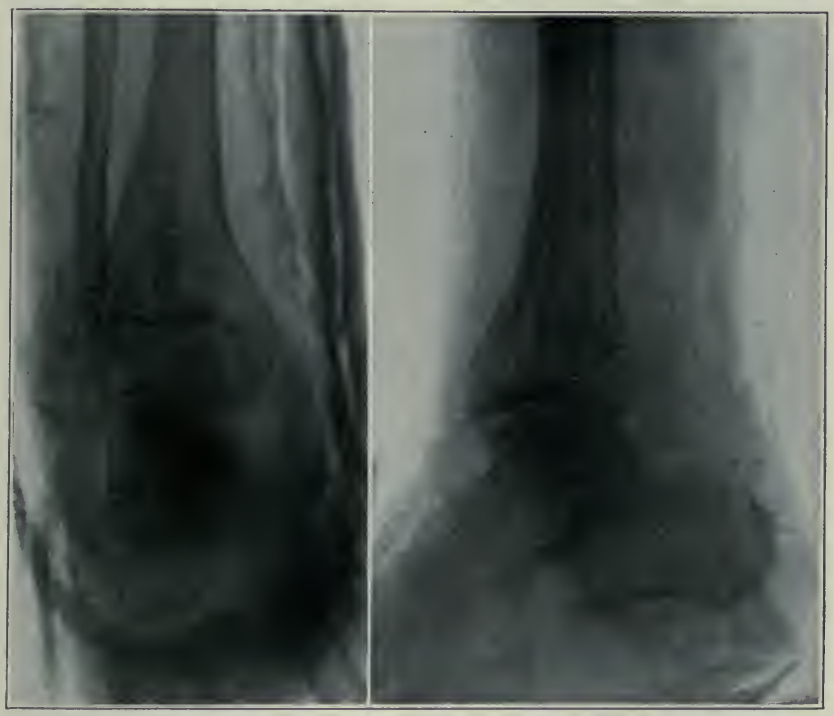

Fig. 4.—Same case as in Figure 3. Left: Appearance after reduction by means of the equinus lever. Gypsum splints (Stimson) were used (antero-posterior view). Right: Lateral view after reduction. The patient was in hospital about eight weeks, and resumed her housework on her return home. A perfect anatomic and functional result was obtained.

shafts without any anesthetic. 2. When applied and as soon as the plaster of Paris has set, the weight extension may be removed, since the apparatus fits snugly to the condyles of the tibia above and to the malleoli below, preventing any subsequent shortening. 3. It leaves both the knee and ankle joints free, so that the patient can move them from

2. Delbet, Pierre: Méthode de traitement des fractures, Paris, 1916.

Fig. 5 (C. K., man, aged 52, Jan. 13, 1917).—Left: Ankle fracture (A2x) after two attempts at reduction, the second attempt aided by the equinus lever; anteroposterior view. Right: Lateral view. Reduction was not obtained.

Fig. 6.—Same case as in Figure 5, showing result of arthrotomy and screw fixation, eleven days after injury. The patient was out of work thirteen weeks. A perfect anatomic and functional result was obtained. The screws were still in place, over seven years after operation.

the start, and thus, by constant use of his leg muscles, materially shorten the period required for consolidation of the bones, and prevent the occurrence of the atrophy of disuse. 4. The patient can leave his bed and begin to walk with crutches during the first week or ten days. 5. Delbet found in his own cases that the average time the splint was worn was thirty-five days, the fragments being then firmly united and all external support discontinued.

The materials required for the application of the apparatus are:

1. A hard flat table with no padding to support the fractured leg. Such support prevents the posterior sagging of the fragments always

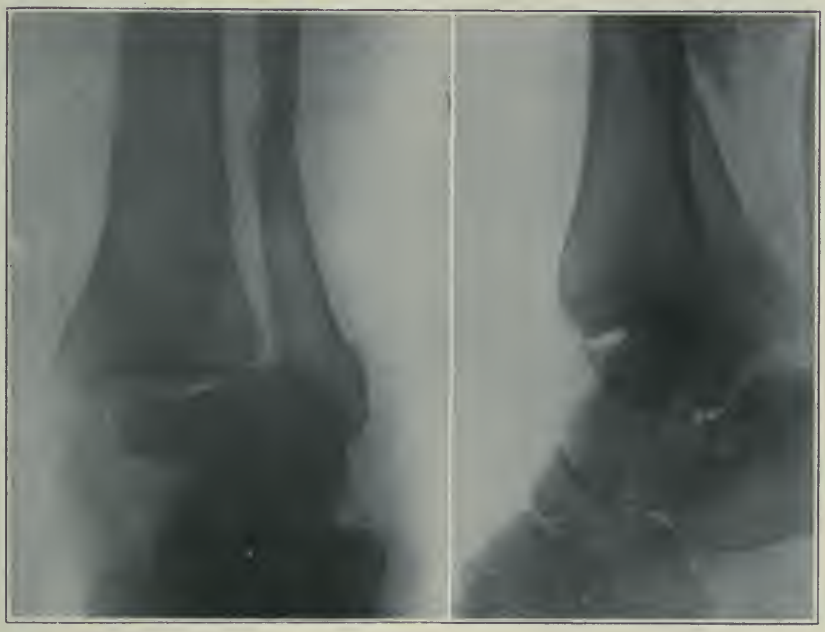

Fig. 7 (C. McG., woman, aged 39, July 17, 1919, on admission).—Left: Ankle fracture (B2b), typical Pott's fracture, with (1) fracture of internal malleolus, (2) diastasis of tibia and fibula and (3) fracture of fibula well above the inferior tibiofibular joint (anteroposterior view). Right: Lateral view, showing posterior subluxation of foot (note absence of a posterior marginal fracture of tibia). Patient first came under the authors' care two weeks after injury. Three attempts at reduction under an anesthetic failed to secure anatomic reposition. The patient refused operation. She was out of work six months, but held her former position at the same wages. A moderate anatomic and functional result was obtained. Pain after much motion, and less endurance were her complaints three years later.

seen in shaft fractures when the limb is placed on an upholstered surface, such as even the firmest mattress. In our own work, we have used a thin board which is laid on top of the mattress (Fig. 8); and we

have had a pulley attached to the board at such a height that traction over it will be directly in the axis of the leg bones, and with the pulley movable laterally on its axis, so that any lateral deformity at the site of fracture can be corrected by shifting the pulley to right or left without in any way disturbing the limb.

2. A scultetus (many-tailed) bandage, made by stitching together at their centers enough rather narrow strips of bandage (each about 50 cm. long) to extend from the heel to the knee. Its ends may be wrapped in cardboard for convenience in handling.

3. Weights for traction. From 16 to 22 pounds (7 to 10 kg.) is required.

4. Material such as tarlatan or crinoline for making the apparatus. This should be cut into pieces of the following dimensions: the two side splints are each of twenty-four thicknesses, 65 by 8 cm. The

Fig. 8.—Method of application of Delbet's apparatus for fractures of the leg. The board is laid on the bed, with pulley for weight extension. There are traction loops over the instep and heel, and a scultetus bandage beneath the leg.

band which encircles the leg below the knee is of sixteen thicknesses, and measures 65 by 5 cm. The band which encircles the malleoli and heel is also of sixteen thicknesses, 65 cm. long, and cut so that its middle portion is 12 by 19 cm., while its right and left thirds are only 5 by 23 cm. long. In the middle third, a semicircular notch is made in the projecting portion to receive the point of the heel. These four splints should be basted together down their middle, for convenience in handling (Fig. 9).

Application of the Delbet Apparatus.—The board with pulley attached is placed under the fractured leg with as little disturbance as possible, and an assistant holds the patient's toes to prevent rotation of the leg. The leg should be cleansed, and if necessary shaved. It should

always be well powdered (talc powder is excellent for this purpose [3]). The scultetus bandage is then carefully drawn under the leg, without disturbing the latter more than is absolutely necessary. Next, a stirrup for traction is made by passing one strip of flannel bandage (about 3 by 45 cm.) beneath the Achilles tendon, and another of the same dimensions across the dorsum of the foot just below the ankle joint. These strips are arranged so that their centers lie in the midline of the heel and ankle, and their ends are overlapped just below and posterior to the malleoli. While the surgeon holds the ends properly

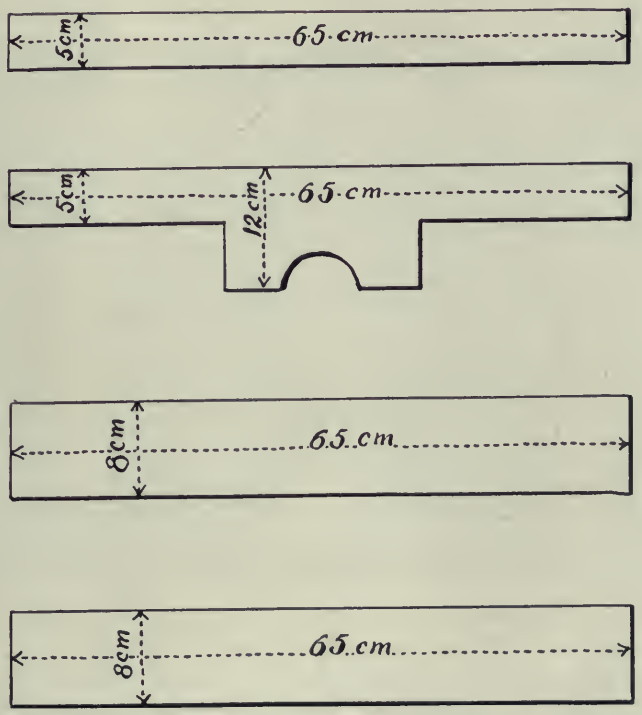

Fig. 9.—Diagram showing the dimensions of the crinoline bands of which Delbet's apparatus is composed. The two lateral bands are made of twenty-four thicknesses of crinoline, and the circular bands of sixteen thicknesses each.

overlapped, the nurse sews them together. This may be facilitated by turning the overlapped ends temporarily upward above the malleoli. Next the free ends of these traction strips are sewed or tied to each

3. As the plaster-of-Paris splints are to be applied directly to the bare skin, discomfort may arise from the hairs sticking to the plaster while moist. Shaving will prevent this, but we have found generous powdering sufficient. It is more satisfactory than greasing, as the latter has a tendency to prevent the plaster of Paris from setting.

other a convenient distance below the sole of the foot; and to the loop thus formed is fastened the rope passing over the pulley and supporting the weights. The weights should be added gradually. Repeated measurements of the fractured leg (from the lower border of the patella to the tip of the internal malleolus) will show its shortening being gradually overcome as the weights are cautiously increased up to a maximum of about 10 kg. Frequently, less weight is enough. As soon as the weights begin to act, the patient's pain ceases.

No effort should be made to push or mold the bone ends into position. Any such attempt will produce pain and muscular spasm, and will totally defeat the object to be gained, which is the gradual reduction of the deformity. The line of pull may be altered readily by shifting the pulley to one side or the other without causing the patient any discomfort. As soon as reduction has been secured, as ascertained by measurement and the restoration of the normal axis of the limb, a plaster cream should be made. About six cupfuls of cold water is placed in a rather shallow but large basin, and plaster of Paris is slowly sifted into the water until the powder no longer sinks rapidly. By this time, a little plaster will have collected on the bottom of the basin; and then, but not until then, should the hand be put into the cream for stirring it. This stirring should be done slowly and regularly and uniformly; no churning is permissible. Delbet says it is better to have a cream too thin than too thick. When it is of the consistency of very thin cream, all four of the crinoline splints should be placed in the mixture at the same time, to prevent unequal distribution among them of the plaster of Paris. When they have become well impregnated, they are taken out and spread out flat and in order.

The band which goes around the malleoli is drawn under the bridge formed by the Achilles tendon without moving the leg, and is pulled down by see-saw motions until it is arrested by the heel. For the time being, its ends are spread out flat on the fracture board. The band for below the knee is next pulled beneath the popliteal space, and drawn downward by see-saw motions until arrested by the calf; and its ends are spread out flat on the fracture board. Next, the two lateral bands are applied beginning just below the level of the knee joint (this is at the lower border of the patella), and extending to within 1 cm. of the sole of the foot at the heel. The bands are then doubled back on themselves, so that the lower one third of the leg is supported by a double thickness. When these lateral bands have been gently molded to the sides of the leg and the malleoli, the circular band already in place beneath the heel is drawn snugly around the malleolar region on top of the two lateral bands, but without any constriction. The long ends of this circular malleolar band are to be crossed on themselves

across the front of the leg at a point above where the tendon of the tibialis anticus becomes subcutaneous. This point may be observed on the normal leg, and the splint arranged to correspond. Neglect of this will lead to the development of a pressure sore at this point. Finally, the upper circular band, surrounding the condyles of the tibia, is drawn snugly but without constriction, around the leg below the knee, and its ends are crossed in front at a point above the crest of the tibia, which is also liable to pressure sores. The usual mistake is to put this upper circular band too high, so that it interferes with flexion of the knee (Fig. 10).

Fig. 10.—Delbet's apparatus for fracture of the leg. The weight is borne on the foot itself, not on the ends of the splint. The lower band crosses above the prominence made by contraction of the tendon of the tibialis anticus. The upper band should not come so far below the tubercle of the tibia as to press on the crest of the tibia. The space for projection of heel should be noted.

Last of all, the scultetus bandage is fastened up, beginning at the heel; and the whole apparatus is carefully molded to the malleoli and tibial condyles as it sets. So soon as it has become reasonably firm, the weights are removed, and the stirrup applied for extension is cut and withdrawn. Neglect to remove it may cause a slough over the dorsum of the foot or over the heel. Usually, the weights do not have to remain in place for more than fifteen or twenty-five minutes from beginning to end of the procedure. The scultetus bandage is removed in twenty-four or thirty-six hours, leaving the gypsum apparatus in place. To

insure proper "setting," the plaster of Paris must be fresh and of good quality; and it is a wise precaution to wash the starch out of the crinoline bands before immersing them in the plaster cream, and to sprinkle some of the dry plaster over the various bands just before they are applied to the leg.

For the first day or two after the Delbet apparatus has been applied, it is well to keep the limb well elevated on pillows, and surrounded with icebags. This tends to prevent injurious swelling and formation of blebs. In a few cases, it may be necessary to remove the apparatus on account of the swelling. Blebs appear not beneath the gypsum apparatus but on the exposed skin. They should be punctured with a sterile knife and dusted with sterile powder, and then usually may be disregarded, giving no further trouble. If the apparatus is not applied until swelling has developed, it usually is necessary to apply a second one within a few days when subsidence of the swelling causes it to become loose. Of 123 cases under Delbet's care, a second apparatus had to be applied in sixty-eight; twenty-eight patients had three plasters, and three patients had four plasters. Only in twenty cases was a single application of the apparatus sufficient.

The subsequent care and treatment of patients wearing the Delbet splint form an integral part of the treatment and must never be neglected. Within the first week or ten days, the patients are gotten up on crutches and taught to walk. Putting the foot flat on the floor, they must be made to dorsiflex the ankle and bend the knee at each step, thus bringing into function both joints, and preventing the atrophy of disuse or joint stiffness. This active mobilization has a singular tendency to promote rapidity of union in the fracture. Delbet says that, in his cases of simple fracture, the average stay in hospital was twenty-four days; whereas, the statistics of the Public Health Service of Paris show that, for simple fractures of the legs under the usual treatment, the average stay in the hospital is from two and one-half to three months. In these latter cases, there is first a period of from thirty-five to forty-five days in the circular plaster-of-Paris case, and then a further period of two or three months or longer for massage, etc. This makes the total period of disability between four and five months, for simple fractures of the leg. This corresponds to the period of disability in the statistics of the Fracture Committee of the American Surgical Association. While Delbet says he does not accurately know the end-results in patients treated by his method, he is convinced the patients are absolutely cured when the apparatus is removed about the end of the fifth week (thirty-five days). Of sixty-five cases traced, he considered "good" results were obtained in sixty, though ten of these

patients limped, and three had shortening of 3 cm. Evidently, he is not so strict in his definition of good results as the Fracture Committee of the American Surgical Association. Delbet uses this apparatus also in ankle fractures, considering it especially adapted to them. Of fifty-five end-results of ankle fractures, he considered fifty-three good. He thinks his apparatus least satisfactory for fractures in the upper third of the tibia and fibula, where fixation of the fragments is nearly impossible unless the knee joint also is immobilized.

The patients in whose cases we have used the Delbet apparatus have been treated too recently to be included in the present report. However, we have found that posterior sagging of the fragments, not infrequent with the former methods of treatment, can almost always be overcome; that the shortening almost always is inappreciable or absent; that the patients get about on their feet sooner, and that union occurs more rapidly. The Delbet splint was also found very useful in a case of delayed union. Applied at the end of the third month, it brought about firm union in three weeks' time. In recent cases, it should be applied at once, before the leg and ankle have swelled. Early reduction may prevent too great swelling. If this swelling occurs in spite of the prompt application of the apparatus, there will be less tendency for shortening and deformity to develop when the apparatus is removed several days after the injury than there was when it was applied; and if the shortening and deformity are allowed to remain uncorrected at the time of the accident, they become daily more and more difficult to overcome.

COMPOUND FRACTURES

There were fifteen cases of compound fracture among the 100 patients traced; fourteen of the shafts, and only one involving the ankle joint. They have readily divided themselves into two classes: (1) those with small skin wounds (2 or 3 cm. or less in length), usually produced by the bones breaking through the skin, and (2) those with large lacerations of the skin and muscles, usually produced by direct violence.

1. The former class, with small skin wounds, have been treated as simple fractures; that is to say, the leg has been cleansed (with iodin), and the wound or wounds have been covered by alcohol compresses, and allowed to heal without primary operation. If operation seemed required for reduction, as it did in four of thirteen cases of this nature, it was not undertaken until the period at which it would have been performed if the fractures had been simple and not compound. By this time (a week or ten days after the injury), the wounds in the soft parts had healed, and the fracture had been converted into the simple type

(Fig. 1). If operation did not seem indicated, the steinmann nail extension was preferred to the Delbet splint when gross displacements of the fragments existed, and especially in comminuted fractures (Figs. 11, 12, 13).

The Steinmann nail may be inserted with local anesthesia only, but a general anesthetic (gas) is preferable. The heel, being properly sterilized, is held firmly in the surgeon's left hand, and a longitudinal

Fig. 11 (A. H., woman, aged 47, Dec. 18, 1915, on admission).—Right: Compound comminuted fracture of tibia and fibula from a fall on icy street. The bones, which protruded through the skin on both sides of the leg, were swabbed with iodin and reduced (anteroposterior view). Left: Lateral view. Steinmann nail traction was employed for eighteen days (compare Figures 12 and 13).

incision about 1 cm. long is made directly down to the calcaneum, about half way between the external malleolus and the sole, just posterior to the line of the fibula. The edges of this incision are held apart by an assistant, with Allis forceps, and the nail, fixed in its handle,

is bored through the calcaneum, care being taken that it passes transversely and not obliquely to the long axis of the leg. It passes through the bone readily as the surgeon keeps constantly pushing it ahead with a rotatory motion in supination only. To pronate the hand while boring the nail through the bone will unscrew the two halves of the nail at their junction. When the point is felt beneath the skin on the opposite

Fig. 12.—Same case as in Figure 11. Left: Anteroposterior view, five days after traction of 7.5 kg. (16 pounds) by Steinmann nail. Right: Lateral view. Shortening is almost overcome, but there is still lateral displacement of more than half a diameter.

side of the heel, a small longitudinal incision is made over it; the skin edges are held apart by Allis forceps, and the point is brought as far out beyond the skin as the other end projects on the opposite side of the heel. The handle is then detached, and a snugly fitting piece of

rubber tubing is passed over each end of the nail so as to prevent the latter from coming into contact with the skin or subcutaneous fat at any point.

Lambotte has pointed out that neglect of this precaution has often resulted in necrosis of the skin edges where these touch the nail; whereas, when they are protected by rubber tubing, they remain healthy. Finally, the tongs are applied, being wrapped at their junction with the

Fig. 13.—Anteroposterior and lateral views of case shown in Figures 11 and 12, two weeks after traction of 7.5 kg. (16 pounds) by Steinmann nail. Shortening is overcome, reduction fair and lateral displacement less than one-quarter a diameter. The anatomic and functional result is moderate (after seven years, the patient still has pain in wet weather).

nails in abundant sterile gauze; and the weights are attached. From 15 to 22 pounds (8 to 10 kg.) is sufficient. Usually, we have employed a posterior gypsum splint (Stimson) along with the nail extension. After ten days or two weeks, the amount of weight is gradually

diminished, the position of the bones being controlled by the roentgen ray; and about the end of the third week or during the fourth week, the traction apparatus is removed. This is readily done without an anesthetic, the projecting sharp point of the nail being caught in a sequestrum forceps, and held firmly while the blunt end is unscrewed with the handle which fits it, the two halves thus being extracted through their proper sides of the calcaneum without carrying any possible contamination across it.

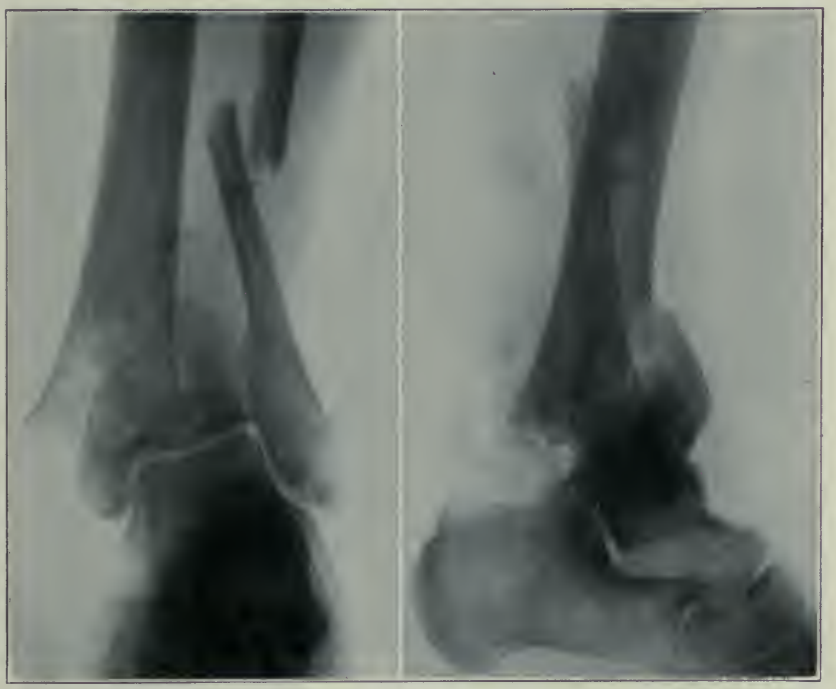

Fig. 14 (A. V., man, aged 28, Sept. 17, 1921, on admission).—Compound fracture of left tibia and fibula involving the ankle joint (B3): (1) fracture of entire lower end of tibia (representative of the internal malleolus in the typical Pott's fracture), followed by (2) fracture of the fibula well above the inferior tibiofibular joint, resulting from a fall from a height, the patient landing on the foot. Immediate operation was performed.

Of the ten cases in which skeletal traction by the Steinmann nail was employed, it proved efficient in eight, though in one of these cases the nail broke at its center screw-joint while the weights were attached. This accident occurred at the end of the third week, when it was time for its removal. Aside from causing the patient discomfort for a few hours, until its removal, no other inconvenience was experienced. In

another case, a defective nail broke in half at the screw joint as it was being inserted. The sharp end had just emerged from the bone on the distal side of the limb but could not be extracted. The blunt end was removed in its handle. The sharp end was temporarily disregarded; but when the patient was returned to the operating room a week later, for fixation of the tibia by plate, it was found, as had been anticipated,

Fig. 15.—Same case as in Figure 14 one week after operation. Ten days after operation the plate was removed because of infection, and a Steinmann nail was applied (Fig. 16).

that enough rarefaction had already occurred around the remaining portion of the nail to allow its being extracted easily, though only the tip of its sharp point was available for the hold of forceps (Fig. 1). In one case, traction (instituted on the sixth day) with a weight of 22 pounds (10 kg.) on the nail failed to improve the position of the fragments, which were subsequently plated.

Cultures were made in almost all cases from the sinuses through which the traction nails passed, at the time of removal of the latter. With one or two exceptions, which gave a growth of staphylococcus, all cultures remained sterile; and all, even those with positive cultures, healed rapidly when the nail was removed. Though the tunnel in the calcaneum may remain visible by roentgen rays for many months, no discomfort has been experienced by the patients. One patient, however, fourteen months after the injury still complained of hyperesthesia in

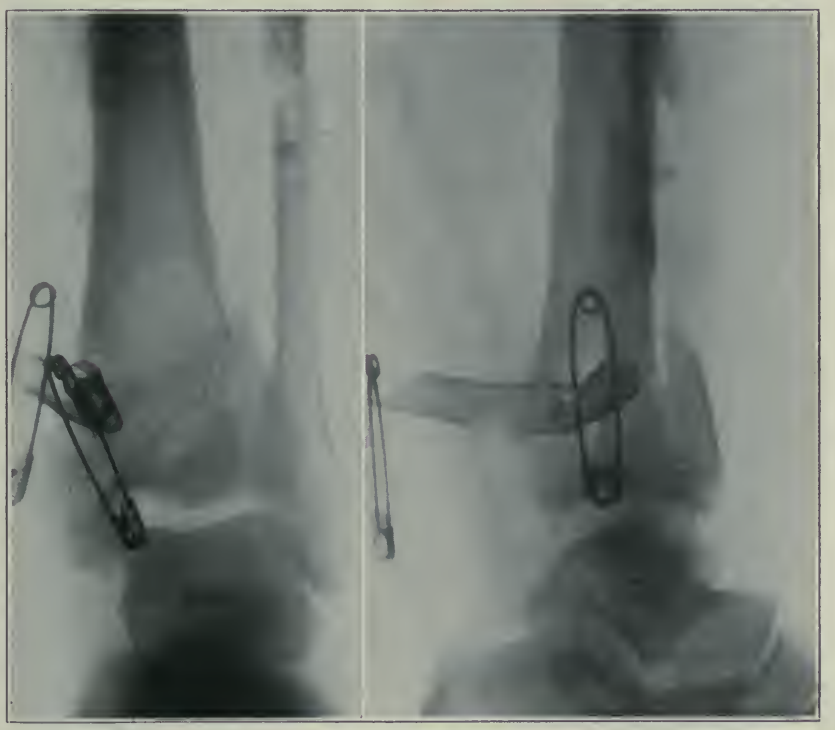

Fig. 16.—Same case as in Figures 14 and 15. A Steinmann nail was inserted, Sept. 27, 1921, ten days after injury, when the plate was removed. The drainage tube emerging through counter-incision at dependent point may be seen. The Steinmann nail was removed, November 1 (five weeks later).

the skin overlying the nail punctures, probably from inclusion of a skin nerve in the scar.

2. The second class of compound fractures, with large wounds of the soft parts, comprised only two cases. They were treated by immediate antiseptic operation, débridement, excision of devitalized tissues, fixation of the bone fragments, drainage and partial closure of the wounds. In neither case could complete closure have been secured

without some form of plastic operation to fill the areas of skin destroyed by the accidents; and it was believed to be a better course to allow the wounds to heal by granulation. Dependent drainage should always be secured, a counter opening being made for this purpose posterior to the fibula, and a drainage tube being passed across the leg at one or more points. In the first case, involving the ankle joint (Fig. 14), the tibia was fixed by a plate and fairly accurate reduction secured (Fig. 15), but owing to a rise in temperature, after ten days the

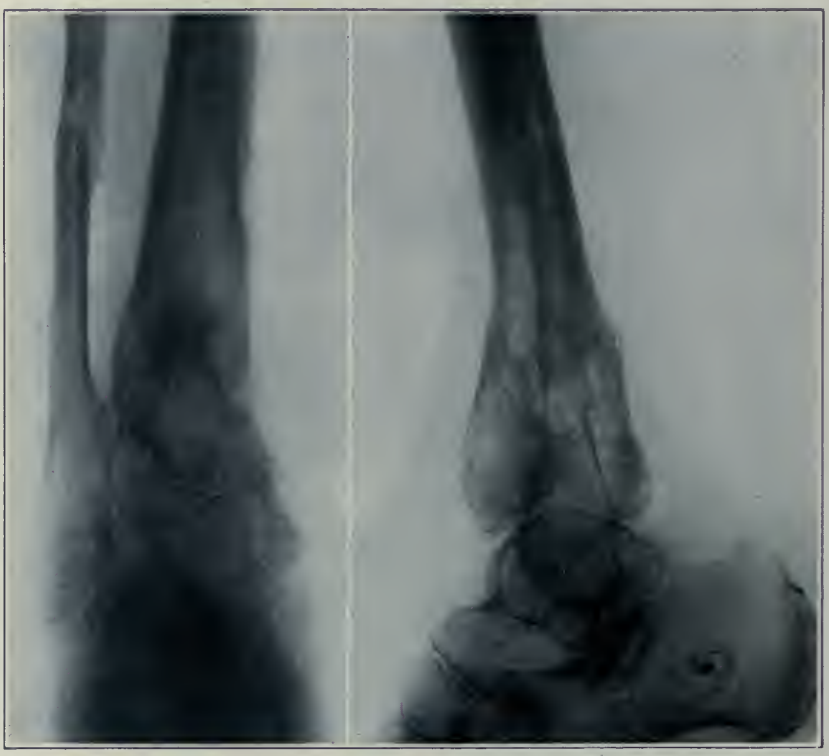

Fig. 17.—Same case as in Figures 14, 15 and 16, one year after injury. The tunnel for nail is still visible in the calcaneum in the lateral view. The patient wore a brace, for a year. He was out of work eighteen months. A good anatomic result with moderate function was obtained. The only disability is a stiff ankle, but the patient cannot resume the same position (which involves climbing telegraph poles) and makes less wages.

gypsum splints were removed, under general anesthesia; and it was then found that the plate had been pulled loose from the lower fragment of the tibia (probably during removal of the splints). The plate was therefore removed entirely, and skeletal traction by the Steinmann nail applied (Fig. 16). This resulted in final union without

deformity, though several sequestrums were removed at another occasion, and a sinus (barely moist) persists eighteen months after the accident. This patient wore a leg brace for a year after the accident; was out of work eighteen months, and has no motion in his ankle joint. He is counted as having recovered with good anatomic and moderate functional results (Fig. 17). He refused secondary ampu-

Fig. 18 (J. M., man, aged 32, Aug. 9, 1922, after operation performed immediately on admission).—Double compound fracture of tibia and fibula, showing temporary clamps used to fix the compound fractures; also a Steinmann nail in calcaneum, and drainage tube emerging through dependent counter-incision. The clamps and traction nail were removed three weeks later. The patient was in hospital ten weeks, and was discharged with firm union, wearing a brace. He was out of work nine months. Anatomic and functional result was moderate (has less endurance than before injury, but no other disability).

tation of the leg, which undoubtedly would have greatly shortened his convalescence. In the only other case in this series, of compound fracture with much destruction of the soft parts, there was a double fracture of both tibia and fibula. The compound fracture of each bone was fixed by a removable clamp (Fig. 18), and the simple fracture of each bone was disregarded, except for continuous traction by a Steinmann nail. The traction nail and the clamps were removed three weeks after the injury, and the soft parts continued to heal uninterruptedly, though the wound was not completely closed for nearly eight months after the accident. The patient was out of work nine months, and secured a moderately useful leg without shortening, but neither the functional nor the anatomic result was perfect.

TABLE 14.—*Operations for Fractures of Tibia and Fibula*

Site	Simple Fractures		Compound Fractures	
	Total Number	Operations	Total Number	Operations
Leg	58	5	14	4
Ankle	79	6	1	1
Total	137	11	15	5

TABLE 15.—*Operations Employed*

Operations	Simple	Compound	Total
Plate	4	5	9
Screws (all ankle fractures)	6	0	6
Open reduction	1	0	1
Total	11	5	16

OPERATIVE TREATMENT

In the entire series of 152 cases (seventy-two fractures of the shafts of the leg bones, and eighty involving the ankle), operation was employed in sixteen patients, fourteen of whom have been traced. These sixteen operations do not include the use of the Steinmann nail for traction in ten cases, tenotomy of the Achilles tendon in two cases, nor one case of arthrotomy of the knee joint (with immediate closure) for hemarthrosis.

Except in compound fractures with great destruction of the soft parts, no immediate operations have been done, a delay of from five to ten days always having been allowed for proper sterilization of the skin. In a series of 130 operations in civil life by one of us (A) for simple fractures of various bones in the body, only one infection has occurred, and this was clearly due to too early operation before the

bullae which followed the original injury had entirely healed.[4] Among the nine cases in which a plate was inserted in the leg, only once has the plate had to be removed subsequently, and then only because the patient was kicked in the shin by a horse, one year after the operation, the horse's kick causing a lacerated wound which exposed the plate.[5] In the tibia, the plate has always been placed on its fibular surface, never subcutaneously, so as to avoid so far as possible any tendency toward such an accident. Of the six cases in which screw fixation[6] was employed for recent fractures of the ankle, the screws were removed in one case about a year after operation, because of persistent pain in the ankle, which was somewhat lessened by their extraction. This case is considered as having a bad functional result. The only case in which open reduction was adopted without direct fixation of the bone occurred in a child, the fracture resembling that shown in Figure 1. In this case, several ineffectual attempts to reduce the fragments had been made by another surgeon (under anesthesia), before the child came under our care and the soft parts were in very bad condition, though the fracture was not compound. In such fractures as these two, it seems to us doubtful whether any attempt at closed reduction is judicious, as we believe it will cause more injury to the soft parts (even were the efforts successful) than operation would entail.

In 78 per cent. of operative reductions, anatomic reposition was secured; in three cases only moderately accurate reduction was secured. In no case, we believe, could as good function have been obtained without as with operation.

CONCLUSIONS

Early reduction of all gross displacement is urged; and in ankle fractures, anatomic reposition should be the goal in view. Stimson splints of plaster of Paris are far superior to circular cases, because permitting proper care of the soft parts at suitable intervals, and preventing atrophy during the process of union, as well as stiffness and swelling during convalescence. The Delbet apparatus has certain additional advantages, notably that of allowing active motion of the knee and ankle joints while the fracture is uniting, as well as hastening the process of union, and shortening the period of disability. In compound and in simple comminuted fractures, traction by the Steinmann nail

4. In one or two other cases, there was superficial infection of the skin at one or more points, but not extending beneath the superficial fascia.

5. There has recently been brought to the notice of the senior author a patient still carrying in the tibia a plate inserted for nonunion by his father (Dr. John Ashhurst, Jr.), twenty-seven years ago.

6. Ashhurst, A. P. C.: Screw-Fixation in Joint Fractures, Med. & Surg. (Oct.) 1917.

has given admirable results. If direct bone fixation is adopted in compound fractures which require immediate open reduction, the fixation apparatus should be removable as soon as fair union is secured. The period of disability for fractures of the shafts of the leg bones in this series averaged (in simple fractures) three and eight-tenths months, nearly a month less than the average period of disability shown by the statistics of the American Surgical Association; and in compound fractures, it averaged five and a half months or about six weeks less than for corresponding cases tabulated by the American Surgical Association. The period of disability for ankle fractures averaged approximately the same in both series (Table 10).

TREATMENT OF FRACTURES BY ORTHOPEDIC METHODS *

SAMUEL W. BOORSTEIN, M.D.

Assistant Visiting Surgeon, Fordham Hospital; Chief of Orthopedic Departments, Bellevue and Fordham Hospitals, Outpatient Department; Neurologico-Orthopedic Surgeon, Central Neurological Hospital; Consulting Orthopedic Surgeon, Union Health Center

AND

ISIDORE J. LANDSMAN, M.D.

Chief of the Roentgenologic Departments of Fordham, Bronx and Bronx Eye and Ear Hospitals

NEW YORK

ORTHOPEDIC ASPECT

Surgery of the extremities has made tremendous progress in the last decade, easily keeping pace with surgery of the abdomen and of the brain. Many new methods of treatment and operation have been devised, and the demand for better results was never so acute as at present. Fractures constitute an important part of the surgery of extremities and the results are more open to criticism than are other operative results. The demands of the public and the general practitioner are different from those of twenty-five or even ten years ago. Some of you may still be using methods in vogue at the time of your graduation, and with good results; but a brief résumé of some modern methods may be of interest. Even if one does not treat fractures, a definite idea of modern treatments and prognosis is of value, enabling one to give the proper information to the patient and his relatives.

The question remains as to whether fractures should be treated by general surgeons or by orthopedic surgeons who claim that their methods have revolutionized bone surgery. Moorehead says, in this connection, that "unless surgeons will pay the same attention to fractures as to abdominal surgery, orthopedic surgeons will grab all the fractures." Osgood [1] justly concludes: "As we watch the trend of surgery, we find in the large centers a seemingly increasing tendency for the general abdominal surgeon to refer acute as well as chronic lesions of

---

* From the surgical service of Fordham Hospital.

* Read before the Bronx County Medical Society, Dec. 20, 1922.

* The orthopedic aspect is presented by Dr. Boorstein; the roentgenologic aspect by Dr. Landsman.

1. Osgood, R. B.: The Standardization of Methods of Treatment in Orthopedic Surgery and in Industrial Surgery of the Extremities and Spinal Column, Illinois M. J. **39**:342 (April) 1921.

the extremities and spinal column to surgeons whose interest has led them to devote special attention to these lesions."

The progressive surgeon does not hesitate to seek the aid of an orthopedic surgeon when the future good of the patient demands it; nor does he hesitate to accept a new method of treating fracture just because it has been invented by an orthopedic surgeon. The use of Whitman's abduction method of treating fracture of the neck of the femur, Albee's bone graft and Thomas' splint are examples of his open-mindedness. The same holds true of the progressive orthopedic surgeon.

In many general hospitals, of which the Massachusetts General Hospital and the New York Hospital are examples, separate fracture services have been instituted. In others, the general surgeon acts in consultation with the orthopedic surgeon. This is particularly true of the difficult cases.

Ollerenshaw,[2] in an extensive article, makes a strong plea for the establishment of special fracture services in general hospitals in charge of surgeons especially interested in bone and joint lesions. The importance of the inclusion of the outpatient cases in such a service is emphasized. He considers about 6 per cent. of the total number of hospital beds are necessary for such a service, and he is convinced that such a plan will avoid many of the bad results which now arise from the general treatment of fractures.

Scudder,[3] who organized one of the first fracture services in America, at the Massachusetts General Hospital; has been impressed by the necessity for improving results in the treatment of fractures throughout the country. He makes the following suggestions: (*a*) special wards restricted to the treatment of fractures; (*b*) a special fracture personnel of surgeons under a chief of service of broad experience; (*c*) a special fracture outpatient clinic under the charge of the special fracture service; (*d*) improvement in the methods of teaching how fractures should be treated and more time for the subject in the medical school curriculum; (*e*) graduate courses for the general practitioner; (*f*) the organization of a clinical surgical fracture society, meeting once a year for the discussion of fracture problems.

In Fordham Hospital, the perfect harmony existing between the general and the orthopedic surgeon has shown the benefits that can be derived from such a procedure. Fractures are under the supervision of the general surgeons, but they often ask the advice of the ortho-

---

2. Ollerenshaw: The Hospital Treatment of Fractures, Brit. M. J. **1**:559 (April 16) 1921.

3. Scudder, C. L.: Treatment of Fractures, Philadelphia, W. B. Saunders Company, 1922; Certain Problems Concerning Fractures of Bone, Ann. Surg. **74**:280 (Sept.) 1921.

pedists. Thus, all serious fractures, as spine, comminuted or bad compound fractures, are seen by the director of the service. He usually refers them to the orthopedist for further suggestions as to treatment and particularly for proper retention apparatus. The orthopedist in turn discusses the case with the general surgeon.

It often happens that a fracture has been properly reduced by the general surgeon but the fragments have slipped. The fault, of course, is in the retention, and he calls in the orthopedist for help. Thus the patient, the intern, the general surgeon and the orthopedic surgeon have the benefit of mutual help. This is particularly true of open bone work.

Undoubtedly, in the future there will develop a class of surgeons who will make fractures their chief interest, though this is not entirely desirable.

Following is a general outline of some orthopedic methods that are of value to the general practitioner, most of which have been accepted by surgeons in the Bronx hospitals.

EARLIER METHODS OF TREATMENT

Of the formulas taught by our predecessors, most are obsolete or should be discarded. The new textbooks on fractures emphasize in their prospectuses that old methods have been replaced by new ones.

These old formulas are: 1. A fracture should not be set before the swelling has subsided. 2. A fracture should be reduced by direct pull. 3. There should be immobilization as far as possible of the joints above and below the break. 4. Straight splints should be applied on a limb despite the fact that the limb is round. 5. Immobilization of bone and joints should be secured by bandages left in place until firm union has occurred. 6. The soft parts, skin, nerves, vessels and muscles may be allowed to take care of themselves.

We shall later on demonstrate that the foregoing formulas are based on false principles and cannot give the best results. The new methods are founded on sound principles and much better results are obtained.

The old methods of retention by means of bass-wood splints, Buck's extension, Liston splints, adhesive plaster dressing for fractured clavicle, etc., need only to be mentioned to call to mind the frequent failure of these contrivances after the fracture has been reduced as indicated by the roentgen ray. Of course, the problem of how to retain a fracture of the humerus, or femur, of a new-born infant or a nursling was doubly hard.

The duration of immobilization used to be from six to eight weeks, and it was hoped that by that time the bones were solid and would not slip; and then, if the surgeon was progressive, he ordered massage or rather rubbing and exercises.

The results, as you well remember, were poor function or marked delay in return of function, sometimes as long as one year. Union was either weak or the callus was so abundant that it could be seen at a distance. This callus alone often acted as a barrier to free motion of the joint, or there were nerves and muscles entangled in it. The shape of the limb was often so changed as to make a real deformity, which acted as a barrier to employment.

The use of the roentgen ray was employed only for the purpose of making sure there was a fracture; that the fracture had been reduced and that alinement was fair. In many fractures, a roentgen-ray examination was not made at all.

This, in general, constituted the treatment in most fractures.

MODERN DEMANDS OF END-RESULTS OF FRACTURES [4]

Fractures are increasing in number all the time, because of the increase of accidents by automobiles, especially in large cities, and the increase in the number of industries which expose workers to injuries. These two main causes put great responsibilities on us for the reason that in accidents not only does the public demand perfect results, since the reward allowed by the compensation or trial juries depends on that, but it also demands from us prediction of the results. To do justice, we are often asked to give the rate of disability. In compensation cases, the end-results treated by one method are so different from those of another that not only must the decision be different, but also the entire future of the workman depends on it. If a workman remains somewhat crippled, he cannot get employment, as the employer fears that an employee so afflicted might be frequently injured, and his compensation insurance rates be thus raised. Thus, even the slightly disabled person often becomes a burden to the family and to society.

The duration of time of treatment is also, at present, a more difficult question than before, as the economic condition of the middle class or the poor class requires early return to work. Even when the insurance companies pay compensation for the injured employee, he receives only two thirds of his salary after two weeks. This expense, of course, is afterward thrown on the product, and is thus paid by the consumer and by the employee involved.

It is also more important at present than previously to reduce the time of confinement to bed. The home conditions (even among the rich) prevent too long confinement. The hospitals are usually overcrowded, and as a great many fractures demand confinement to

4. In the January, 1923, issue of THE ARCHIVES OF SURGERY is published the outline of treatment of fractures as adopted at a special conference at Boston in April, 1922, by general and orthopedic surgeons. The article is extremely valuable to those interested in fractures.

bed, it is of paramount importance to employ the methods which shorten the stay in bed in each individual case.

As to the demands of the public for roentgen-ray examination in fractures, Hey-Groves [5] cleverly states: "It is now universally recognized in the law courts and by the lay mind that an X-ray record should form a part of the routine treatment of every bone injury, and in the face of this it would be folly to do otherwise than act on this view, which, after all, is the common sense one. The X-ray should be taken before the reduction but, if it can be managed, the patient should not be shown the X-ray."

To summarize the modern demands as to end-results, we agree with the practical suggestions of Bucholz or Moorhead. Bucholz [6] justly says: "The old dogma, 'Normal function depends on correct reduction of the fragments,' needs a modification at least for many kinds of fractures. We should rather say, 'Correct reduction of the fragments is one of the most important conditions, but by no means the only one, for the recovery of good function, and in many cases other factors may play a rôle so great that reduction becomes even of secondary value.' At any rate, the anatomical problem should never overshadow the functional problem, but, on the contrary, every step of the treatment must be directed toward a good recovery of the function."

The end-results as stated by Moorhead [7] can best be judged by three elements: (1) function; (2) union, and (3) contour.

Restoration of function is the most important item. This should be the main object of treatment. It is apparent that the profession at large does not as yet appreciate its full value. Function denotes the capacity to perform. Of course, this varies in different people, and we must recognize that fact beforehand. For example, the upper extremity is primarily related to such coordinated acts as the function ("sense") of grasp, of pull, of push, of touch. An artist is much concerned over the loss of sense of "grasp and touch," while the workingman is concerned over the loss of "push and pull."

Union denotes the state of repair of the injured part.

Contour denotes the external appearance of the injured part. In some patients, looks based upon the results of "union and contour" are of more importance than the restoration of function. The laity, unfortunately, generally regards union and contour as the main

---

5. Hey-Groves, E. W.: On Modern Methods of Treating Fractures, New York, William Wood and Company, 1922.

6. Bucholz, C. H.: Therapeutic Exercise and Massage, Philadelphia, Lea & Febiger, 1912.

7. Moorhead, J. J.: Measuring End-Results After Injury, a Suggested Percentage Basis, J. A. M. A. **79**:824 (Sept. 2) 1922.

elements; while the important item is really the function. Suits for malpractice are frequently the outcome when such an interpretation of an end-result prevails, notably in fractures in which, unjustly, the roentgenologic result is considered rather than the clinical or functional result.

To recapitulate, the success of treatment should be judged by return of function, the condition of union, the contour or external appearance, the duration of time under treatment and the duration of time of confinement to bed.

Having enumerated the fallacies of the old methods and having indicated the demands of the present, we can now take up the modern or orthopedic methods of treatment and make a comparison. We will be able to show that they overcome the difficulties arising from the old teachings and meet the requirements outlined.

THE MODERN METHODS

1. *Time of Reduction.*—It has been shown by Sir Robert Jones, Speed, Hey-Groves, Ashhurst and others that the best time for reducing is immediately after the accident, for the swelling usually increases if the fracture is left unreduced. Ashhurst,[8] in an editorial dealing with the prognosis of fractures, states: "The more promptly reduction of the fragments is secured, the easier it will be to obtain anatomical reposition. Especially is this true in joint fractures and in children. If attempts at reduction are delayed until swelling of the soft parts has reached its maximum, or until it begins to subside, they are not apt to be successful, and the mere fact that the broken bone has been restored to its normal form is very frequently enough to prevent injurious swelling of the soft parts from developing." If the fragments remain unreduced, the jagged ends of the bones will cause damage to the muscles and increase the swelling. Besides, the reduction is much more difficult, because of increased muscular spasm. Some adhesions are also formed and organization of the hematoma takes place even within forty-eight hours, and in a late reduction, these have to be torn. It is therefore advisable to reduce the fractures as quickly as possible. When the lesion is evident, it may be permissible to reduce it at once without a roentgenogram, though, as mentioned before, it is advisable and safer for the protection of the surgeon himself to take a roentgenogram. If it can be arranged for, it should be developed quickly and one should not wait twenty-four hours for the result.

2. *Methods of Reduction.*—It is best to reduce the fracture under anesthesia, as the muscular spasm is relaxed. It is also performed under the fluoroscope, where one sees the fragments and thus often

8. Ashhurst, A. P. C.: The Prognosis of Fractures, editorial, Surg. Gynec. & Obst. **35**:661 (Nov.) 1922.

sees where the interference to reduction lies. Later on, we shall discuss the procedure of reducing a fracture under the fluoroscope.

The old method of reducing every fracture by direct pull or extension in a straight line is mechanically wrong, since, when the fragments are overlapping, the muscles running in the same direction are naturally put in spasm and thus the difficulties are increased. Of course, after prolonged pulling, the spasm may be relieved, as the muscles tire, but usually the surgeon does not keep up the traction long enough. He tires more quickly than the muscle. It is much better to put the limb in position to take the pull off the muscles. The best examples of the difference in reduction are in fractures of the lower end of the radius and of the middle of the femur. There should be no fast rule for all fractures, but each fracture should be treated or reduced according to the correct muscle pull. We shall demonstrate this. Take, for example, the old method of treating the fracture of the middle of the femur by direct pull in a straight line with the knee fully extended. By that method, the hamstrings were put in spasm and reduction was prevented. The new method is to flex the hip and knee, thus overcoming the action of the hamstring muscles; and then to pull the lower fragment in line of the flexed knee. After reduction, the limb is put on a Thomas splint or plaster cast with the knee and hip flexed. The second example, fracture of the lower end of the radius (Colles' fracture) cannot always be satisfactorily reduced by the method of "hand shake." Sir Robert Jones,[9] in his excellent book, "Injuries to Joints," says in this connection: "The traditional method of reduction, by taking a grip of the hands as if shaking hands, still appears in text-books. It is quite inefficient in any stubborn case, for it is mechanically impossible to try to replace a small fragment like the detached lower end of the radius by traction and manipulation through a chain of small bones like the metacarpus and carpus through their ligaments." The grip Sir Robert Jones uses is as follows: "The surgeon takes the patient's arm in his left hand with his own tubercle against the projecting lower end of the shaft; he then places his right hand on the dorsum of the patient's wrist with his own scaphoid on the projecting lower fragment. A firm grip with a slight traction and twist of the wrist completely reduces the deformity. It requires knack rather than strength."

We can cite many more examples, but it is not necessary. Suffice it to say that no fast rule should be made. One must take into consideration the action of the muscles and relaxation in certain positions, and the fragments can often be more easily reduced. Under the fluoroscope, this can easily be demonstrated.

---

9. Jones, Robert: Injuries to Joints, Oxford War Premiers, 1915.

The syllabus[10] which we have mentioned above summarizes the important facts concerning reduction as follows:

(*a*) Reduction of any existing displacement should be made as soon after the injury as possible, without waiting too many hours for the roentgen-ray examination.

(*b*) Reduction should be made as gently as possible.

(*c*) Reduction should be as complete as the individual case requires.

(*d*) Reduction may be controlled by fluoroscopic examination in appropriate cases.

(*e*) Reduction should be checked by a roentgen-ray examination as soon as practical.

(*f*) Manipulation should be carried out under an anesthetic with but few exceptions.

(*g*) Further attempts at reduction should be made as soon as the need is recognized.

3. *Means of Retention.*—We must emphasize that the method used for immobilization is merely to maintain immobilization and not reduction. Whether we use plaster or a splint, it acts only as a box to retain the limb in the proper position attained at the time of reduction. In most of the fractures excepting, perhaps, those of the shaft of the femur, the fracture can be reduced and will not be displaced any more if put in proper position to prevent muscular pull.

As for material used for retention, a plaster cast, i. e., a circular cast, is the best. It holds the limb well and prevents mucle spasm. If it is applied properly, there will be no pressure sores. The mistake is often made of employing too much padding, with the result that the cast does not fit well. One cannot put a straight splint on a round limb; hence, a posterior molded splint cannot hold well. Wooden splints (basswood) are still less desirable. A circular cast can be split into two halves in a few days and thus be used for a removable splint. One half can be discarded and the second half can be used to retain the reduction (Figs. 10 and 11).

The other retentive methods are the Thomas splints for the arm and leg and the Jones cock-up splint. The application of these is so simple, as proved by the work of the special splint squads in the war, that every general practitioner should find no difficulty in mastering their application. One can hold almost any fracture with these splints. They can be used at any age. We have used them even in a birth fracture, in infants a few hours old.

The other splints in use at present are the Balkan frame, whose application is rather difficult, and the Bradford frame, used for spine

10. Outline of Treatment of Fractures, Arch. Surg. **6**:172 (Jan.) 1923.

fractures. The inherent value of any apparatus is of less importance than the skill with which it is used.

4. *Duration of Time of Immobilization.*—The earlier teaching was to leave the limb immobilized till firm union was apparently attained. The bandages were usually applied so firmly as not to permit shifting of the fragments during the whole period required for consolidation, which was estimated at between two or three months. Hey-Groves [5] thus points out the fallacy of this teaching: "This principle is liable to be futile or dangerous; it is futile if the bandaging be not really firm, and dangerous if it be. The fixation of the bone is obtained at the expense of the soft parts, the nutrition of which will suffer in proportion to the tightness of the bandage and the completeness of the immobilization. There is, therefore, a complete negligence of the soft parts, muscles, vessels, nerves and joints." The new method is to begin treatments within a few days. Bucholz [6] treats some fractures even on the second day. The means of retention can be so arranged that the fragments are not disturbed when massage is given. For instance, if a Thomas splint is used, the massage is given on the bandage. If a circular cast is used, it can be split in half in such a manner that when one half is taken off the other can retain the fragments (Figs. 10 and 11). After ten days, each half can be taken off during massage. Of course, one has to be trained in the handling of the limb during the massage so as not to dislodge the parts or cause pain, especially when the callus is still soft. As emphasized before, it is the muscular spasm that keeps the muscles apart and will have a tendency to displace them. If, however, the fracture has been reduced and the splints are applied so as to relax the muscles, there is little fear of dislodging them during massage. Proper massage has also the beneficial effect of relaxing the muscles in spasm. In the third week, the splints in some fractures, such as those of the lower end of the radius, can be left off altogether. In others, it is kept on till about the fifth or sixth week. The first retentive apparatus is often changed for a simpler one after a short time. One must keep in mind that repair is more rapid in cancellous than in cortical bone.

5. *After-Treatment of Fractures.*—To hasten the union, to obtain proper union as well as good and early return of function of the limb, we are using the following adjutants: (*a*) Baking. The active hyperemia produced by the baking (dry heat) in really good baking machines (not mere lamps) causes a local increase of arterial blood, an absorption of exudate and an increase of new cells, which, in the case of bones, are the osteogenetic cells. The pain is markedly reduced by this means. One can also use daily local baths in hot water and Epsom salt, when the splint or casts can be temporarily removed. We begin the baking

in most cases (if no splint is applied) on the fifth day. It is given in the beginning every day; then, every other day.

(*b*) Massage. This term, or rather this part of the treatment, is often and too much abused. As too often applied, the massage treatment of fractures consists, first, in splinting a fracture for days or weeks until early union has occurred, thereby producing stiffness of muscles and joints. Then a professional masseur is called in to give a daily "rubbing." The limb is punched and pummelled and the joints are moved with more or less force; and the greater the pain caused, the greater the good the massage is supposed to be doing. It may well be doubted whether such a treatment advances recovery by a single day; in fact, it often positively retards it.

As it ought to be practiced, the method consists in applying a gentle superficial stroking, a soothing caress, to the injured part at the very outset. Such treatment must relieve muscular spasm and not cause pain.

Massage as applied to fractures is applied not directly over the swollen area but at the periphery. One can easily hold the fragments with one hand or on one half of the plaster and use the other hand. In the first few days, the duration of massage should be very short, only three to four minutes, to absorb the hematoma. Later on, it is increased. Massage is usually administered after the baking.

To demonstrate the method of massage and retention we shall consider a common fracture, that of the lower end of the radius (Colles' fracture). As soon as possible, the fracture is reduced and a plaster cast is applied, extending from the elbow to the knuckles. We usually put on two pieces of felt, one at the dorsal aspect of the lower fragment, and one at the anterior aspect of the upper fragment, to hold the fragments better. Three days later, the cast is cut in half in such a manner as to prevent slipping. The dorsal half is taken off and baking is given. For the massage, the forearm, with the anterior half, rests on the masseuse's left hand, while with the right hand she massages the muscles of the forearm, using gentle stroking, kneading and rolling manipulations for three or four minutes. Then, a few gentle slow passive movements of each finger individually are carried out. The splint is reapplied and bandaged.

This treatment is repeated daily, adding every day one minute of massage, up to ten minutes, and a few movements of the fingers, up to ten or fifteen. Gradually, the massage is to include the tendons, hand and fingers. On the tenth day, the anterior half of the splint can be removed and the forearm kept on the masseuse's left hand. Thus, both sides can be massaged. Flexion of the wrist can be used if the operator encircles the fractured area with the index finger and thumb. It usually happens that on the fifteenth day motion of the

fingers is almost completely restored, and even the mobility of the wrist and forearm is improved to a certain extent. One half of the splint can then be left off. At the end of four or five weeks, only a wrist band of felt and adhesive plaster should be used.

(*c*) Exercises. Contrary to the old custom, we begin exercise very early, but do not leave this to the patient himself or to the parents, but instruct our masseuse very carefully as to how this is to be carried out. It is best to begin with active exercises. Later on, resistance exercises are used. If slight adhesions have formed after five or six weeks, passive exercises are to be given, but these should not be very vigorous. Exercises favor the formation of callus. If properly given they cause no pain, but, on the contrary, alleviate it. They cause no pseudoarthrosis. The exercises also shape the callus by allowing the tendons to play freely and normally over the soft callus. They thus prevent adhesions later on.

One must always keep in mind what the final result should be in each limb and aim for that; e. g., the lower limb is used for standing, hence all the energy should be directed toward a straight knee. The upper extremity is used for work; hence, the elbow should be in a flexed position, if one cannot get a real functioning and free elbow. The shoulder should be in an abducted position as much as possible, in order that one may have fair use of that limb.

(*d*) Occupational therapy; function. As mentioned before, the results of a fracture are at present judged by the function. Occupational therapy can therefore be resorted to with great advantage. We allow a patient to return early to his work, hoping that the muscles which the patient needs for performing his work can be made to function early and properly. Of course, this form of exercise is more interesting for the patient, as has been proved, in general, by the benefits derived.

DIFFERENCE BETWEEN THE TWO METHODS

OLD METHODS	MODERN METHODS
1. Reduction of the fracture after the swelling has subsided.	1. Immediate reduction of the fracture.
2. Reduction of the fracture by direct pull.	2. Reduction of the fracture in accordance with relaxation of muscular pull.
3. Immobilization as far as possible of the joints above and below the break.	3. Immobilization to prevent slipping by the muscular spasm, irrespective of whether another joint is to be included or not. Usually only one joint has to be included.
4. Application of straight splints though the limbs are usually round.	4. Application of plaster cast or splint with proper regard to the shape of the limb.

5. Securing of immobilization of bone and joints by bandages left in place until firm union has occurred.	5. Immobilization allowed for a short time only, till one is positive that the fragments will not slip; then other treatment is employed.
6. Allowing the soft parts (skin, nerves, vessels and muscles) to take care of themselves.	6. Proper care of the soft parts by early massage and exercises and removing the splints early.
7. Contour or union in good position the main aim.	7. Function the main aim.
8. Prolonged confinement to bed.	8. Very early return to function.
9. Correction of deformity later on if it occurred during the treatment. It is often considered inevitable.	9. Prevention of deformity very carefully watched.
10. Roentgen ray used only once or twice during the entire time.	10. Roentgen ray used much more frequently.

OPERATIVE METHODS

Cases are frequently seen in which, in spite of any method employed, the fracture has not been reduced or union has not begun. In such cases, open operations become an absolute necessity.

"Operative treatment is indicated when a satisfactory reduction cannot be obtained by nonoperative methods, provided there is no contraindication, and when the expected result of the open method is sufficiently better than that of the closed to justify the additional risk. Furthermore, it is generally recognized and accepted that, in certain types of fractures, it is impossible to obtain satisfactory restitution except by operative methods." [10]

Instead of Lane plates or wiring, the modern methods of bone graft have found a distinct and useful field. It would be out of place to discuss here the indications for operative interference and methods of bone grafting.

INTERPRETATION OF RESULTS

At present, owing to the compensation laws and the frequent legal complications of accidents, and also to the entanglements of the war risk insurance, we are often called on for an exact and detailed report of the disabilities and the exact prediction of the outcome of the accident. The old terms "good," "fair," "poor" or "bad" are inadequate, as they are too vague, and what one surgeon calls fair, the other will call "absolutely bad." The sex and occupation of the patient often comes into consideration: what for a workman will be an excellent result will be considered bad for a violin player.

Moorhead [7] is therefore justified in measuring the end-results on a percentage basis. Taking the three elements of the result: function, union and contour, he arbitrarily allows 60 per cent. for function, 20

per cent. for union and 20 per cent. for contour. While in some cases, the contour may be of more importance than the apportioned 20 per cent. would indicate, it cannot be really considered the most important item of the three. If function is three-fourths perfect, we allow three fourths of 60 per cent. or 45 per cent.; if union is one-half, we allow one half or 10 per cent.; if contour is one-fourth perfect, we allow one-fourth of 20 per cent. or 5 per cent. So our result is the sum of 45 plus 10 plus 5 per cent., giving 60 per cent. as a result. If contour is of importance, one can give it a little higher rating, subtracting this percentage from function. If we wish to bring these descriptive numerical terms in line with our former use of words, we can say that a result of 80 + is good; 60 +, fair; 40 +, poor, and 20 +, bad.

One can often, by this method, make a pretreatment estimate of the condition and then be able to report whether there is improvement or not.

The function as well as the contour has very often to be more exactly reported than in former years. Thus, we record the angle of extreme motion in terms of degrees or present it graphically on charts. To measure the angles of motion of a joint, different forms of "goniometers" have been invented. While not all of them are perfect, most seem to serve the purpose fairly well. The common ones in use are, Thoele's universal caliper, Virchow's cephalometer, Bertillon's caliper, Miller's dactylometer and Bott's goniometer.

The graphic charting of Nutter has been found useful in our work. The angle of the joint as well as the limit of voluntary and passive motion are taken by Bott's or another satisfactory apparatus, so that the exact angle in degrees is noted. This is recorded on a chart which has a rough diagram of a man with the joint in neutral position. The limits of motion are indicated in dotted lines.[11]

For measuring the length, a tape measure should be employed, and not just a glance of the eye. Exact and fixed points are chosen. For the lower extremities, we have employed the letters used in the Hospital for Ruptured and Crippled for a long time, and have found them absolutely reliable: RA, distance from right anterior superior spinous process to internal malleolus; LA, distance from left anterior superior spinous process to internal malleolus; RU, distance from umbilicus to right internal malleolus; LU, distance from umbilicus to right internal malleolus; RT[6], circumference of right thigh taken at a definite point above the lower border of patella, here, 6 inches (15 cm.); LT,[6] circumference of left thigh; RK, circumference of right knee; LK circumference of left knee; RC, circumference of right calf at the bulkiest

11. Nutter, J. G.: Reconstructive Surgery, J. A. M. A. **72**:410 (Feb. 8) 1919; Standardization of Joint Records, J. Orthop. Surg. **1**:423 (July) 1919.

point; LC, circumference of left calf at the bulkiest point; for the upper extremities; RAM_5, right arm at a definite point below acromion process; LAM_5, left arm at a definite point below acromion process; RFM_3, right forearm at a definite point below olecranon process; LFM_3, left forearm at a definite point below olecranon process.

For measuring the power of the hand, the monometer is used which records in terms of pounds. Normally, the power of the right hand is from 50 to 60 pounds; that of the left hand, from 40 to 50 pounds. Of course, this varies in different individuals. It may be worth while since we speak so often of the right and left side, to emphasize that these words should be underlined on the history sheet so that one may not write "left" when he really means the right side.

These, in short, are the methods of measuring and recording results. One may consult the "fracture chart" prepared by the Fracture Committee of the American Surgical Society to see how the different methods are compared. We are accustomed to use the following outline in charting results.

FRACTURES

History No..... Special Fracture No. (Case No.).....

1. Name..... Age..... Occup..... Address.....
   Nat.....M. F.....W. C.....S. M. W.....Photo No.....
   X-ray Nos..... Date of adm.....
2. Date and Time of Injury.....
3. Cause of Fracture:
   Direct violence .....
   Indirect violence .....
4. Bone affected..... Limb..... Part.....
5. Type of Fracture:
   Simple .....
   Compound .....
   Transverse .....
   Oblique .....
   Spiral .....
   Comminuted .....
6. Deformity:
   In long axis.....
   Transverse axis .....
   Shortening .....
7. Character of Line of Fracture:
   From examination .....
   From X-ray plates.....
   From operation .....
8. Previous Treatment .....
9. Method of Reduction:
   (*a*) Time instituted .....
   (*b*) Anesthesia or not.....
   (*c*) Flouroscope .....

10. Closed Method:
    (*a*) Manipulation .....
    (*b*) Splints.....Kind (Bucks, Blakes, Jones, Steinman)
    (*c*) Brace .....
    (*d*) Plaster of paris.....
    (*e*) Traction .....
11. Open Method:
    (*a*) Immediate or delayed operation.....
    (*b*) Simply for reduction or nonunion.....
    (*c*) Wire .....
    (*d*) Plates .....Kind
    (*e*) Bone Transplant.....Method
    (*f*) Nails .....
12. Amount of Shortening:
    (*a*) First dressing.....
    (*b*) When all apparatus were removed.....
    (*c*) At latest observation (date).....
    (State how measurements were taken)
13. After Treatment: Frequency Duration Time Begun
    1. Thermotherapy
    2. Massage
    3. Active motion
    4. Passive motion
    5. Occupational therapy
14. Result:
    (*a*) Function .....
    (*b*) Contour .....
    (*c*) Union .....
15. X-Ray Findings:
    (*a*) Before reduction or operation.....
    (*b*) Immediately after reduction.....
    (*c*) When all fixations are removed.....
    (Note condition of bone)
16. Social and Economic Conditions:
    (*a*) Length of time in bed.....
    (*b*) Length of time absent from work.....
    (*c*) Length of time crutches, canes or other aids to walking were used.....
    (*d*) Is patient able to take his former job?.....
17. Disability at Last Observation Estimated by:
    (*a*) Deformity .....
    (*b*) Endurance .....
    (*c*) Pain .....
    (*d*) Swelling .....
    (*e*) Interference with joint function.....
18. Special:
    (*a*) Carrel-Dakin Solution .....
    Complication .....
19. Mortality:
    (*a*) Cause of death.....
    (*b*) Date .....

COMMON FRACTURES ILLUSTRATING MODERN METHODS [12]

1. *Fracture of Clavicle.*—Hodge [13] uses a T-board with a figure of eight around both shoulders, which we have found very satisfactory. The patient can thus use both hands while union takes place. Massage can be started on the second day.

2. *Fracture of Neck of Humerus (Anatomic and Surgical).*—The upper extremity is put in marked abduction at right angles with the torso and rotated outward. This gives the best result; as an adducted arm can be used very little. The shoulder can be immobilized in that position in a Thomas Jones abduction airoplane splint or a plaster spica. Massage can be started on the seventh day, active motion in the second week.

3. *Fractures of Upper Thirds and Mid-Thirds of Shaft of Humerus (Above Insertion of Deltoid).*—A hinged Thomas arm splint or Jones humerus splint is employed, and the arm can be left at the side (though we prefer abduction). Massage is begun after seven days and active motion in two or three weeks. The splint can be changed for a sling about the fifth or sixth week.

4. *Fractures of Lower Third of Shaft of Humerus.*—The arm is put in a Jones humerus splint or a circular cast, and is suspended or kept at the side. Massage is begun at the end of the first week and active motion at the end of the second week.

5. *Supracondylar or Fractures of Condyle or a T-Fracture into the Joint.*—These require more details than can be here given.

6. *Fractures Around Elbow Joint.*—Sir Robert Jones emphasizes that, with the exception of fractures of the olecranon process, in all fractures around the elbow the joint should be put in acute flexion. Immobilization by means of plaster of Paris can easily be applied. Massage is begun in five days; active exercises in seven days. In fracture of the olecranon process, the arm is put in full extension.

7. *Fracture of Forearm.*—If the fracture is above the attachment of the pronator radii teres, the cast extends to the middle of the arm from the wrist joint. The forearm is in supination. The elbow is flexed at right angles. If the fracture is below the attachment of the radii teres, the plaster cast extends from the knuckles to the elbow joint, which may be included, flexed at right angle, with the forearm in position of pronation or midpronation. A piece of felt must be placed between the two forearm bones to prevent cross union. Massage is begun on the fifth day; active exercises are started on the seventh day.

---

12. I am giving only a general outline of the most common fractures. For details, one should consult the modern textbook. The fracture outline gives in detail the different fractures.

13. Hodge, R. L.: A Simple Splint for the Treatment of Fractures of the Clavicle, J. Orthop. Surg. **1**:439 (July) 1919.

8. *Fractures of the Lower End of Radius (Colles' Fracture).*—The traditional method of reduction, by taking a grip of the hand as if shaking hands, has been shown by Sir Robert Jones to be wrong. Jones' method, previously described, should be employed. The fragments can be retained in position by plaster casts. Usually, two pads of felt are put on, one on the dorsal aspect of the lower fragment and one over the palmar aspect of the upper fragment. Massage is begun on the third or fifth day, exercises on the eighth day. The plaster can be changed to a wrist band at the end of the second week or in the middle of the third.

9. *Fractures of Carpal Bones.*—The hand should be put up in hyperextension, as the hand can be most useful in that position. This can be done in a plaster-of-Paris cast, or a Jones cock-up splint. Baking, massage and active exercises should be begun on the fifth day.

10. *Fractures of Spine.*—There should be immediate immobilization in a Bradford frame or a plaster jacket even if the roentgen ray does not reveal an extensive fracture. Immobilization should be continued for a long time.

11. *Fracture of Pelvis.*—This is best treated by tight swathes, or webbing belts, sometimes by plaster spicas. These alarming fractures usually heal well and quickly and are less serious than is generally feared. The patient may be kept supine for four weeks.

12. *Fracture of Neck of Femur.*—This should be treated by Whitman's abduction method. Age is no contraindication. While the limb can be held in a double Thomas Jones' splint, the plaster cast is much more satisfactory. The plaster is changed for a caliper and crutches about the sixth month. No weight bearing is allowed for five months. Massage can be begun at the end of the third month, and active exercises at the same time.

13. *Fracture of Shaft of Femur.*—This is best treated with Thomas Jones' splint, with flexion of knee and hip. Even infants can be treated by this splint (as has been shown in a previous article [14]). Massage can be started early, but walking should be delayed until the end of the third month, as this bone, in the process of walking, bears the entire weight of the body during one half of the time and will easily bend, and cause marked interference. Active motion is begun at the end of the first month.

---

14. Boorstein, S. W.: Treatment of Birth Fractures at Fordham Hospital, Am. J. Dis. Child. **19**:375-383 (May) 1920.

14. *Fractures Around Knee Joint (Supracondylar or T-Fracture into Knee Joint).*—These are difficult fractures to treat and cannot be discussed in a short article. They often require an open operation.

15. *Fractures of Tibia and Fibula.*—Immobilization up to the knee, with the ankle joint flexed dorsally at right angles, usually suffices. We can permit walking very early, even at the end of the first week. It is important to get good alinement of the tibia, as both knee and ankle joints are hinge joints and a good line is important. Massage is begun on the third or fifth day, active motion at the end of second week.

16. *Fracture of Patella with Separation of Fragments.*—This often requires operation. One may try for eight days full extension of the knee in a Cabot splint or plaster cast with felt pads above and below the patella to approximate the fragments. A caliper splint is used in the second month. Massage is begun immediately if possible and active motion as soon as the skin wound is healed.

17. *Fracture of Patella Without Separation.*—The limb is put in a circular cast, a Cabot splint or a Thomas Jones splint. Massage is begun on the third day, active motion at the end of the first week.

18. *Fractures Around the Ankle Joint.*—One must keep in mind that to have a good function, the foot must be at right angles to the leg. In complicated Pott's fracture, when this position cannot be obtained, one should cut the Achilles tendon in order to pull down the os calcis (Dowd [15]). During the time that the bone unites, the Achilles tendon will unite. Massage is begun on the fifth day, active motion at the end of the second week.

The subjoined cases serve to illustrate that the functional result is the most important consideration, and we should not depend entirely on the roentgenologic findings.

REPORT OF CASES

Case 1.—M. O., a woman, aged 59, recommended by Dr. H. Hershberg, suffered a fracture of the surgical neck of the humerus (Fig. 1), which was reduced under anesthesia and the arm put in a plaster cast in marked abduction. The roentgen ray (Fig. 2) after reduction showed slight impaction. Massage was begun two weeks later. There was a good result in three months (Fig. 3).

Case 2.—J. A., a woman, aged 48, recommended by Dr. Raabe, had a comminuted fracture of the shaft of the humerus, which was reduced under anesthesia, though the fragments were not in a good anatomic position (Fig. 4). Baking and massage were begun after ten days. The result was very good and there was good union (Figs. 5 and 6).

---

15. Dowd, C. N.: Lengthening of the Tendo Achillis in the Treatment of Complicated Pott's Fracture, Ann. Surg. **68**:330 (Sept.) 1918.

Fig. 1 (Case 1).—Fracture of surgical neck of humerus before reduction.

Fig. 2 (Case 1).—Fracture of surgical neck of humerus after reduction. Abduction was obtained but the fragment is not fully reduced.

652

Fig. 3 (Case 1).—Three months after treatments, showing good union. Patient has very good use of the shoulder.

Fig. 4 (Case 2).—Comminuted fracture of the humerus. The postion obtained in the plaster may be noted. One would be inclined to operate in this case.

Fig. 5 (Case 2).—Fracture of humerus; appearance four months after the accident. The good position and the callus formation may be noted.

Fig. 6 (Case 2).—The final result: good union and a proper amount of callus.



Fig. 7 (Case 3).—Fracture of lower end of radius and ulna; displacement of lower fragment of radius backward and inward; *A*, anterior-posterior view, *B*, lateral view.

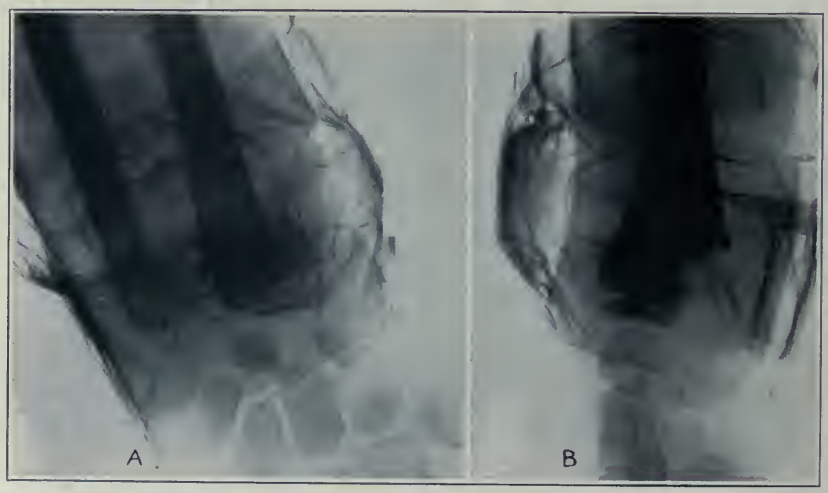

Fig. 8 (Case 3).—Slight improvement in position after several attempts at reduction. There is still an overlapping in the anteroposterior position; *A*, anteroposterior position, *B*, lateral view.

Fig. 9 (Case 3).—Four months after treatments, showing good union and better position. Function was perfect. Two and a half years after discharge, there is no deformity or interference with growth; *A*, anteroposterior view, *B*, lateral view.

Fig. 10.—Bivalved cast for the forearm.

Fig. 11.—Bivalved cast for the leg.

Case 3.—M. L., a boy, aged 6, recommended by Dr. Burstan, had a fracture of the lower end of the radius and ulna, with displacement of the lower fragments (Fig. 7). Two attempts were made by one of us (S. W. B.) to get a good position, but failed. An effort to get the lower fragments into a slight angle (Fig. 8) was successful. Baking and massage were begun on the fifth day. Gradually, the massage shaped the bone so that the final functional result was perfect. The contour also was good though the last roentgen-ray examination revealed a slight deformity (Fig. 9).

These cases do not demonstrate that one should neglect to obtain a good anatomic reposition, but show that frequently if the after treatment is carefully carried out, the final result will be good.

CONCLUSIONS

1. Proper attention should be paid to treatment of fractures, as better and quicker results are now expected.

2. Each fracture should be treated as a problem by itself, with the final aim of restoring good function.

3. Early reduction is absolutely necessary.

4. Reduction should be performed with full consideration of muscle pull and not according to the traditional custom of pulling by direct extension.

5. When possible, the fracture should be reduced under the fluoroscope.

6. Restoration of anatomic position should be the aim, but partial lateral displacement or impaction without alteration of the axis of the limb is allowed.

7. Retention should be planned according to the muscle pull and not according to the old rule that the joints above and below the break should be encased.

8. Straight splints should not be used on round limbs.

9. The retention apparatus should be as simple as possible and made "fool proof." It must be so arranged that no displacement takes place during the healing. It must be properly put on.

10. Prolonged immobilization is harmful.

11. Massage should be commenced very early, about the third or fifth day; but it must be administered very carefully and gently in the hands of an experienced masseuse and not by a plain "rubber."

12. The exercises prescribed should be definite, not haphazard; i. e., simply instruction to the patient to exercise.

13. Active exercises are preferable to passive. These should be commenced early, as they prevent stiffness and adhesions. They never cause pseudoarthrosis.

14. Passive exercises may be justified only at the end of the treatments to obtain full range of motion, but even these should be done gently.

15. A roentgenogram should be taken before and immediately after reduction, and at frequent intervals during the course of treatment. The patient should not be discharged without a final roentgen-ray examination.

16. The end-results should be judged according to the function, contour and union, and not according to the roentgenographic readings.

17. The end-results should be reported accurately, and not by the general terms good, fair, poor and bad.

18. Interns in the hospital should receive proper training in the treatment of fractures just as well as in the practice of general surgery, so as to prepare them for this important work.

ROENTGENOLOGIC ASPECT

The extent of information furnished by the roentgenologist to the surgeon in his treatment of fractures is so great and so obvious that no one now even begins to treat a fracture without his aid.

While it is true that perhaps a fair percentage of cases need no roentgen-ray information for their proper treatment, still even minor juxta-articular bone injuries result disastrously under the best of treatment; hence, the rule of taking roentgenograms in all fractures or suspected fractures.

Some surgeons have stated that it is not necessary to take a roentgenogram at once, but to wait for some time after reduction to determine the final result. The fallacy of such a method is obvious. If it should become necessary to take a roentgenogram during the course of the treatment, it may then be too late to benefit the patient.

As to whether the reduction of fractures should wait on a roentgenographic examination, this is a mooted question. It appears to be the latest teaching that fractures should be reduced and immobilized at once, then examined by roentgen ray to determine the position obtained. The ideal mode of procedure obviously is to take a roentgenogram immediately after the fracture to determine its nature; then to reduce the fracture, and finally to take a second roentgenogram, to note the character of reduction.

In tabulating some of the essential features in the matter of the roentgen-ray examination of fractures, the following should be borne in mind:

1. *Legal Aspect.*—The decision of the courts is all too familiar to require elaboration. It is held that the absence of a roentgen-ray

examination in a fracture is, per se, basis for a malpractice suit, and recovery of substantial damages is the rule in such neglect.

2. *Suspected Fractures.*—Roentgenograms must be made in sprains about the joints to determine their true nature. "Sprains," under the old meaning of the term, simply included all ligamentous injuries. But a careful study of the roentgen plates has shown that a sprain is frequently accompanied by a laceration of the periosteum, and a fracture of a small piece of the cortex of the bone.

3. *Nature of Fracture.*—A determination as to whether it is comminuted, incomplete, transverse, oblique, spiral, etc., is valuable to the surgeon in determining his mode of correction.

4. *Position of Fragments.*—This is determined with reference (*a*) each to the other; (*b*) to the surrounding structures; (*c*) to the structures interposed between the fragments; (*d*) to loose fragments, in the case of comminuted fractures, which may require removal before proper reduction can be attempted; (*e*) to intra-articular fractures. When the joint has been involved, correct reduction is very important. Small fragments of a comminution may require prompt removal to insure a perfect functioning of the joint.

5. *Epiphyseal Fractures.*—In fractures in which only a laceration of the growing epiphysis is noted, with no displacement, the roentgenologist should, as a matter of routine, in view of the importance of this condition, examine the corresponding normal joint for comparison. Frequently, to the inexperienced eye, the multiplicity of epiphyses about a joint may confuse.

6. *Pathologic Fractures.*—Fractures are often caused by a relatively slight injury, and the roentgen-ray examination will determine the underlying pathologic condition, which in itself may necessitate other forms of treatment: (*a*) bone cysts; (*b*) sarcomas; (*c*) metastatic carcinoma, which may be the first indication of the disease without finding the primary lesion; (*d*) myeloma, etc.

7. *Differential Diagnosis.*—Fractures are to be differentiated from (1) scurvy; (2) rickets; (3) osteomyelitis, and (4) arthritic conditions.

8. *Extent of Union.*—Reexamination of the fracture from time to time will often furnish information as to union, and in cases of delayed union, other methods of procedure should be instituted before it is too late. Progress of callus formation can be determined by careful inspection of the osteogenetic layer. If complete bony union has not occurred, and the osteogenetic layer is still present, there is still hope for complete bony union. If, however, no union is present, and there is an absence of the osteogenetic layer, some other means of obtaining

bony union must be resorted to. The extent of the callus can be determined, as to whether it is normal, subnormal or excessive, and, in the case of the last, as to whether the callus is interfering with the joint and involving pressure on the nerves.

9. *Compound Fractures.*—Roentgenograms are made to determine the extent of bone disease (periostitis or osteomyelitis), if present. In order to note the progress of this bone disease, the roentgen examination is important as to determining further procedure.

10. *Reexamination.*—Immediately after reduction, reexamination is important, to determine whether the fragments have been brought into fairly good apposition. But it should be borne in mind that an examination a week or two after the reduction is also of great importance, to determine whether the immobilization has been effective. This is especially true of fractures of the shafts of the long bones, in which the fragments frequently slip past each other, after perfect reduction has seemingly been accomplished.

11. *Atrophy of Bone from Disuse.*—The extent and nature of atrophy can be determined only by roentgen-ray examination.

12. *Operative Reduction.*—In bone grafts, etc., the roentgen ray is indispensable.

13. *Technic.*—An elaborate discussion is too technical for so short a space. Suffice it to say that all fractures should be examined in two planes (the normal planes are preferable) at right angles to each other. If the examination is made obliquely, it should be so stated to the attending surgeon. In several fractures, especially those about the ankle, oblique views are necessary; and again in other parts of the body, as the hip and shoulder, when views in two planes are not feasible, stereoscopic examinations are in order.

14. *Fluoroscope.*—Diagnosis of fracture should not be attempted by this method, as fissure fractures, sprain fractures, incomplete and subperiosteal fractures would often be overlooked. Reduction under the fluoroscope, however, is coming more and more into vogue. A roentgenogram should be made to determine the nature of the fracture, which should then be reduced under the fluoroscope. Lastly, another roentgenogram should be taken in order to note the result. Incidentally, the last roentgenogram would be positive evidence, legally, of institution of proper treatment.

15. *Reporting of Fractures.*—In reporting the character of a fracture, the roentgenologist and surgeon should bear in mind that a good functional and then a good cosmetic result are the objects sought after, and that perfect alinement of the fragments is not necessary to obtain this desired end. Therefore, when the roentgenologist reports "no dis-

placement of fragments," even if there is an apparently slight displacement, one should take his word for it and leave well enough alone.

16. *Portable Apparatus.*—Portable roentgen-ray machines are so well developed today that in the matter of fractures just as good a roentgenogram can be made at the bedside as in a fully equipped laboratory.

529 Courtlandt Avenue—391 East One Hundred and Forty-Ninth Street

SUPPURATIVE TENOSYNOVITIS OF THE FLEXOR MUSCLES OF THE HAND*

MATHER CLEVELAND, M.D.

NEW YORK

On account of their economic importance and surgical interest, a study of the acute infections of the flexor tendon sheaths of the hand was undertaken at the Presbyterian Hospital over two years ago. A series of fifty-seven consecutive cases, observed from Jan. 1, 1916, to Jan. 1, 1923, has been analyzed. The series is presented, with the end-result in each case, observed for an average time of nearly one and one half years. These end-results are defined so that the reader may appreciate what have been considered as various degrees of success or failure. The method of treatment presented has been evolved as a result of lessons learned by experience. By means of a definite technic, to be described subsequently, we have been able to achieve far better results in our later cases than in our earlier ones.

Suppurative tenosynovitis of the flexor tendons of the hand may be divided into two main groups or subdivisions which differ considerably in their physical findings and clinical course, and, indeed, in the end-results obtained. A definition and description of each of these groups is essential before proceeding. They will be designated as the primary and secondary groups.

A primary tendon sheath infection is one in which there is a direct implantation of the invading organism into the sheath, at the time of the original injury or shortly thereafter, by means of the original wound.

A secondary sheath infection is one in which the sheath has been invaded from a surrounding area of infection, such as an improperly drained abscess overlying the sheath or adjacent to it, or from a distant focus of infection. The surgeon's knife may open and infect an uncontaminated sheath by a badly placed incision in attempting to drain a superficial infection of the finger. The sheath is occasionally invaded from the blood stream, as, for example, in two cases of gonorrheal tenosynovitis in this series.

In this series of fifty-seven cases, of which thirty-three are primary and twenty-four secondary, the two groups will be frequently contrasted and compared.

There is usually a trauma preceding the infection, although certain cases, such as those of gonorrheal origin, may show none. Some injury was described in 86 per cent. of our series. Of these injuries, the most frequent was a punctured wound (63 per cent.), and in two thirds

---

* Read at a meeting of the Surgical Section of the New York Academy of Medicine.

of these was a foreign body, such as a wooden or steel splinter or a piece of needle. Incised wounds, with an occasional inadvertent incision into the sheath, were next in frequency, and abrasions and contusions followed. In three cases, the injury was a human bite. These infections, due to the micro-organisms on the teeth and in the mouths of human beings, usually follow a bite, which may allow direct invasion of the sheath; or a cut on the knuckles, from which the sheath is invaded secondarily. The wound of entrance is small, and drainage is soon sealed off by dried exudate. The infection spreads, killing all tissue down to and including bone. The odor is foul. Baking and soaking cause the process to extend with greater rapidity. The sheath

Fig. 1 (Case 12, A. N., 1921).—A primary hemolytic streptococcus infection of the sheath of the little finger, spreading to the ulnar bursa above the annular ligaments, to the radial bursa and sheath of the flexor longus pollicis. The portal of entry was at the distal crease of little finger. The patient came to the hospital five days after onset, during which time she had been under the care of her family physician, who made a small incision in the little finger on the day of admission. The swelling was so enormous that classic signs were masked. The little finger and ulnar bursa were drained first, the radial bursa and sheath of thumb were opened the following day. The annular ligament was split two weeks later, but this procedure was too late to save the tendons, the majority of which sloughed. The culture of pus at the last operation showed hemolytic Staphylococcus aureus—a secondary contamination of the wound. A much better result might have been obtained with more radical incisions from the beginning, and revised technic. The patient was unable to try active motion. Photographs show bad end-result sixteen months after operation. A badly crippled hand with slight flexion at metacarpophalangeal joints of all except the little finger. The thumb can be opposed to all except the little finger. The patient was able to pick up small objects and to write.

invasion is usually followed by osteomyelitis, and amputation may become necessary. We recommend in these cases immediate wide débridement.

WOUND OF ENTRANCE

The tendon sheath is reinforced over the proximal and middle phalanges by a very dense and tough digital vaginal ligament, which is attached to the margins of these two phalanges. Such strong bands, if situated at the interphalangeal joints and at the metacarpal phalangeal joint, would seriously interfere with flexion; therefore, at these points, there are weaker and more delicate transverse bands known as the annular ligaments. The soft parts overlying the sheaths are thinnest at these creases or skin joints. From these anatomic facts, one would expect to find the sheaths most often entered by wounds at the creases. Investigation has shown beyond shadow of doubt that this is the case in the primary tendon sheath infections. The point was not especially noted prior to 1920, but of all the primary cases in the series, nearly 60 per cent. had wounds at the digital flexion crease, with the distal crease involved in 70 per cent. of them. Since 1921, this point has been carefully noted in every case, and 100 per cent. of the thirteen primary cases have shown a wound at a digital flexion crease. The secondary group did not show flexion crease wounds. The sheath was invaded, probably through its unprotected portion, from abscesses of the distal, middle or proximal anterior closed spaces (in order of frequency); from palmar abscesses and web infections, and in two cases from an abscess of the dorsal surface of the finger. Incompletely drained anterior closed space infection is the most frequent cause of this secondary group of flexor sheath infections.

TIME ELEMENT

The average primary case came to operation three days and sixteen hours after the injury was sustained; whereas, in the average secondary case, there was a delay of a little over fifteen days. In the earliest case seen the patient was admitted to the hospital with the classic symptoms and signs of tenosynovitis, seven hours after running a splinter into the distal flexion crease. Another case came to the hospital within nine hours.

SYMPTOMS AND PHYSICAL SIGNS

In order of importance, the symptoms and physical signs are: (1) tenderness along the sheath; (2) position of flexion with inability actively to extend the finger; (3) passive extension of the terminal phalanx, causing exquisite pain. In addition, the patient complains of severe throbbing pain along the sheath, increasing to a point where sleep

is impossible. There may or may not be high fever, chills and malaise. This classic picture of tissue under tension due to exudate within the sheath is most frequently encountered in the primary case. The careful elicitation of varying degrees of tenderness by beginning with gentle pressure over a normal adjacent area and then approaching the sheath is most helpful in arriving at a diagnosis. There is usually no tenderness in the distal closed space. An abscess in the palm or in the proximal anterior closed space may be ruled out by tenderness in the middle anterior closed space. The finger should always be supported in the most comfortable position during the examination. In two cases, in which swelling due to exudate or edema became enormous, especially

Fig. 2 (Case 14, F. M., 1921).—A primary hemolytic streptococcus infection of the sheath of the middle finger. The portal of entry was at the middle flexion crease. The finger was treated with revised technic and active motion. The condition was complicated by severe cellulitis of the dorsal surface of the hand, requiring incisions. The immediate result was a little flexion in all the finger joints, but the end-result was bad—a stiff flexed finger without any motion in the interphalangeal joints. This end-result was in some part due to a chronic arthritis of all finger joints, as shown in Figure 3. The bad end-result eighteen months after operation is shown.

beneath the annular ligament, classic tenderness was masked. This may have been due to pressure on the ulnar and the median nerves. A partially drained sheath fails to show these symptoms and signs; which accounts for the failure of most of the secondary group to present the classic picture.

DIAGNOSIS

In this series, the condition was recognized on first appearance of the patient in 75 per cent. of all cases. In the primary group, the correct diagnosis was made in 82 per cent. Five quite frank primary cases that should have been recognized were not diagnosed for two or three days. Recognition of but 58 per cent. of the secondary group calls for improvement in diagnosis.

HAND OR FINGER INVOLVED

In 73 per cent. of the cases, the right hand was involved nearly three times as often as the left, and the fingers whose sheaths were most frequently invaded are those used most often in grasping: the thumb and the index and middle fingers.

EXTENSIONS OF PUS FOUND AT OPERATION FOR SUPPURATIVE TENOSYNOVITIS

In thirty-four of the fifty-seven cases, the pus was confined to the digital sheath. In those cases in which the pus extended beyond the confines of the sheath, a consideration of the paths traversed and the areas subsequently involved is interesting.

Radial and Ulnar Bursae.—The digital sheath of the flexor pollicis longus muscle was infected eleven times. In three of these cases, there was no extension above the annular ligament. Whether these three cases were confined to the digital sheath and did not invade the radial bursa cannot be definitely stated. If it is assumed that these are digital sheath infections, the percentage corresponds to the percentage of cases in which, according to other authors, the digital sheath is separated from its corresponding radial bursa. In eight cases, the pus extended above the annular ligament. In only three of these eight radial bursa cases was the ulnar bursa and sheath of the little finger invaded.

The sheath of the little finger was invaded seven times, and in four cases infection was confined to the digital portion. All three ulnar bursa infections extended above the annular ligament, but only one showed extension to the radial bursa and sheath of the flexor pollicis longus.

All three of the infections of the thumb sheath which remained localized to the digit were secondary, and three of four of the little finger sheath infections remaining localized were secondary. The only secondary cases to spread above the annular ligament were two infections of the sheath of the flexor pollicis longus.

This suggests that the secondary group of sheath infections extends slowly, 75 per cent. of this secondary group of infections of the thumb and little finger being confined to the digital portion of the sheath. There seems to be time for the sheath to protect itself against the

invading organism. Since 72 per cent. of the infections of the sheath of the thumb extended to the radial bursa, while only 42 per cent. of the little finger sheath infections invaded the ulnar bursa (the number of primary and secondary cases in each being approximately equal),

Fig. 3 (Case 14).—Appearance of finger joints, due in part to a chronic arthritis.

one may be justified in assuming that the radial bursa is easier of access to the organism invading it from its digital sheath than is the ulnar bursa. The anatomic continuity between the radial and ulnar bursae above the annular ligament is open to question. In numerous careful

searches for this continuity in the dissecting room, neither Auchincloss nor I have been able to demonstrate it. The invasion of pus from one of these bursae to the other has taken place in four of ten possible cases, or 40 per cent. We have seen the radial bursa filled with pus and the ulnar bursa free five times; the radial bursa free and the ulnar bursa pus-filled, once. The extension may be explained by the contiguity fully as well as by the continuity of these sacs.

Palmar and Dorsal Extensions.—In four cases, the thenar space was invaded, each time from the sheath of the index finger. The mid-palmar space was invaded twice from the sheath of the ring finger. The web between the index and middle fingers was invaded four

Fig. 4 (Case 16, F. F., 1922).—A primary hemolytic streptococcus suppurative tenosynovitis of the flexor pollicis longus and flexors to the little finger. The portal of entry was at the proximal crease of the thumb. From the sheath of the thumb, the infection spread to the radial bursa, the ulnar bursa and the little finger sheath. The space in front of the pronator quadratus was filled with pus. The hand was widely drained the fourth day after onset, and healing was uneventful. Revised technic and active motion were employed. Photographs show a good end-result nine months after operation. Function in thumb is 75 degrees of normal, with good active flexion at the metacarpophalangeal and interphalangeal joints. The condition of the little finger is less satisfactory, but there is some active flexion in both interphalangeal joints.

times through the lumbrical canal from the index sheath, and once from the middle finger. The web between the ring and middle fingers was invaded twice from the middle finger sheath through the lumbrical canal.

Pus was seen in the dorsal subcutaneous tissue either at the time of operation or subsequently in five cases, the spread being apparently through the web. The dorsal subaponeurotic space was invaded once through the metacarpophalangeal joint.

One secondary case spread from the dorsum of the hand to the index finger sheath and thenar space, apparently through the web between the index and middle fingers. This infection followed a cut on the knuckles from an opponent's teeth, and resulted in the loss of the finger.

Fig. 5 (Case 19, H. A., 1922).—A primary Staphylococcus aureus tenosynovitis of the index finger, the portal of entry being at the distal flexion crease. The condition was unrecognized for two days in the outpatient department. The finger was operated on four days after onset. The condition was complicated by a tremendous sloughing beneath the distal flexion crease, where more adequate drainage should have been provided. Revised technic was used with active motion. Photographs show a good end-result six months after operation, with 60 per cent flexion at proximal interphalangeal joint and 15 degrees at distal. The atrophy following the sloughing of the soft parts may be noted.

The neglected secondary cases of long standing showed the most extensive areas of suppuration. In one of these cases, the patient came to us two and one-half months after a wound on the little finger, with multiple incisions, pus in the midpalmar and thenar spaces, the ulnar

bursa destroyed, pus in front of the pronator quadratus and an osteomyelitis of both radius and ulna.

Another of these, following an index finger infection of one month's duration, presented pus in the thenar space, the midpalmar space and the space in front of the pronator quadratus.

One primary case, the only fatality, in which the pus spread early and rapidly into the forearm, was carefully observed. The sheath of the thumb was invaded, and the infection spread to the radial bursa and then to the ulnar bursa and sheath of the little finger. From the space in front of the pronator quadratus, the pus traveled up the forearm to the intermuscular planes, in front of the interosseous membrane, behind the flexor sublimis and profundus digitorum muscles,

Fig. 6 (Case 17, M. W., 1922).—A primary hemolytic streptococcus infection of the sheath of middle finger which came to operation four days after onset. The portal of entry was at the distal flexion crease. Revised technic was employed with active motion. The wounds healed uneventfully. Photographs show a fairly good end-result four months after operation, with 50 degrees of flexion at the metacarpophalangeal joint and a slight amount of active flexion at both interphalangeal joints. A good fist can be made and the usefulness of the hand is very little impaired.

along the median nerve and its vessels. Extensive pockets of pus were then found between the brachioradialis, the biceps and the brachialis muscles.

CLASSIFICATION OF END-RESULTS

Fifty-six of the fifty-seven cases have been followed for an average time of nearly fifteen months. The follow-up notes have been dictated by eight or ten surgeons, whose opinions naturally vary. All results

have been estimated from an anatomic, symptomatic and economic standpoint, and an optimum result should rank high under each of these headings. In defining our results, we have used function as the main criterion; but the anatomic condition might be used as the gage. This anatomic basis is very important in subsequent plastic repair. A functionally useless finger in good anatomic condition is often very suitable for tenoplastic work.

Our end-results have been divided into the following four groups. The frankly optimum and equally frankly bad results fall easily into

Fig. 7 (Case 5, J. H., 1916).—A primary hemolytic streptococcus tenosynovitis of the flexors to the little finger invading the ulnar bursa in the palm but not above the annular ligament. The wound was adequately drained thirty hours after onset. The optimum end-result nine months after operation is shown.

their respective groups, but classification of other results is more difficult. There are some borderline cases which lie somewhere between good and fair or between fair and bad. We have tried not to overestimate a result in any case.

1. Bad results: (*a*) Death; (*b*) amputation; (*c*) deformed, stiff, painful finger, without motion at the interphalangeal joints and little if any at the metacarpophalangeal joint.

2. Fair results: Almost complete motion at metacarpophalangeal joint but no active motion at the interphalangeal joints. The finger is not necessarily deformed, and a fist may be made with the aid of the other fingers.

3. Good results: Complete function at metacarpophalangeal joint and some slight active motion in the interphalangeal joints. A fist is readily made, actively for the most part, though adjoining fingers may aid in producing extreme flexion.

4. Optimum results: An almost complete return of normal function in the finger. There may be some limitation of extreme flexion, but the finger is practically as useful as before the infection.

BACTERIOLOGY

In studying the bacteriology of this infection, an attempt has been made to determine the relation, if any, which the various micro-organisms bear to the healing of the wound and the end-results obtained. Forty-eight of the fifty-seven cases were cultured, and in forty-one of these, micro-organisms were recovered. *Streptococcus hemolyticus* was found at operation in pure culture in twenty-five cases (60 per cent.), and *Staphylococcus aureus* in pure culture in five cases, or 13 per cent. In the remaining 27 per cent., there was a mixture of various types of streptococci and staphylococci. *Streptococcus hemolyticus* was recovered from the blood of one patient who died of sepsis following a very virulent cellulitis of the entire upper extremity. A study of the bacteriologic findings (Table 1) reveals the following facts:

The hemolytic streptococcus cases usually showed little discharge from the wounds. Sloughing of the subcutaneous tissues and tendons occurred in 33 per cent. of the cases. Osteomyelitis was present in 23 per cent. of the cases. The end-results were good or optimum in 28 per cent. and bad in 42 per cent.

The hemolytic streptococcus cases secondarily contaminated form an interesting group. There were four of these cases definitely proved, and two others should probably be included but cultural evidence is lacking. One of these patients was discharged from the ward with wounds almost healed and was subsequently contaminated in the outpatient department. The other three were contaminated during the course of their ward treatment. In all of this group, careless technic was manifest. The end-results in two of these cases were very bad, one coming to amputation and the other ending with a badly crippled hand, most of the tendons having sloughed. The two other cases which probably belong within the group each had unsatisfactory results. This definite proof of contamination of infected

TABLE 1.—*Bacteriologic Findings*

Organism	Total Number	Number of Cases	Wound Healing: Amount of Exudate: Large	Moderate	Small	Sloughing: Subcutaneous: Absent	Present	Tendons: Absent	Present	Osteomyelitis: Absent	Present	Results: Bad	Fair	Good	Optimum
Hemolytic streptococcus	21	15 primary	0	4	11	13	2	13	2	14	1	4	6	2	3
		6 secondary	2	2	2	1	5	1	5	2	4	5	..	..	1
Hemolytic streptococcus secondarily contaminated with Staphylococcus aureus	4	4 primary	4	0	0	1	3	1	3	3	1	2	..	1	1
Nonhemolytic streptococcus	2	2 primary	1	0	1	2	0	2	0	2	0	..	..	1	1
Streptococcus of various types, with staphylococcus "mixed infection"	8	4 primary	0	1	3	4	0	3	1	3	1	2	1	..	1
		4 secondary	3	1	0	1	3	1	3	2	2	2	1	..	1
Staphylococcus aureus	5	3 primary	2	0	1	0	3	3	0	3	0	..	..	2	1
		2 secondary	2	0	0	0	2	1	1	1	1	1	..	1	..
Staphylococcus albus	1	1 primary	1	0	0	0	1	0	1	0	1	1	..	..	..

tendon sheaths with disastrous results led us to change our postoperative care of all tendon sheath infections to a technic to be described in detail under treatment.

The staphylococcus infections showed more profuse discharge and sloughing of the subcutaneous tissues. The tendons sloughed in only one case, however. Osteomyelitis was present in one case. The end-results were unexpectedly good, four of five being rated good or optimum, and only one result considered bad.

Fig. 8 (Case 8, J. B., 1920).—A secondary tenosynovitis of the sheath of the ring finger following an abscess in the web between the ring and little fingers. The patient came to hospital fifteen days after the original injury. A culture of the pus was sterile. The sheath was drained in the proximal anterior closed space. The optimum end-result with normal function twenty-five months after operation is shown.

The primary mixed infections showed little discharge and little tendency to sloughing, and osteomyelitis was present in only one case. The results were bad or fair in three of four cases. The secondary cases of mixed infections had profuse discharge, sloughing of subcutaneous tissues and tendons and osteomyelitis in three cases. Three

of four of these were rated bad or fair. This group has the poorest record, 75 per cent. of unsatisfactory results.

The two cases of nonhemolytic streptococcus had no sloughing or osteomyelitis. The results were good in one and optimum in the other. It is noteworthy that profuse discharge, sloughing of both tendons and subcutaneous tissues and osteomyelitis were more frequently associated with the secondary than with the primary group.

Gonococcus Tenosynovitis.—The infections of the tendon sheaths due to the gonococcus differ so materially from those due to other micro-organisms and form such a distinct and contrasting group that,

Fig. 9 (Case 9, H. M., 1920).—A primary hemolytic Staphylococcus aureus infection of sheath of index finger. The portal of entry is in the distal flexion crease. The patient was operated on forty-eight hours after onset. Two subsequent operations were performed to give more adequate drainage, but the patient eventually got an optimum end-result with almost complete flexion in all joints. The end-results twenty-six months after operation are shown.

although there are but two cases in our series, it seems worth while to describe them in a little more detail.

One patient (Case 22) sustained a contusion of the palm of the left hand, following which the shoulder was lame, and then pain, tenderness and swelling developed along the course of the sheath of the ring finger. Eight days after the injury, he came to the hospital with symptoms and signs severe enough to indicate the necessity of draining the sheath. The sheath was found to contain a few drops of

pus, from which nothing grew on culture; but a smear showed a few very definite gram-negative intracellular diplococci. The patient had been suffering from gonorrhea. The temperature fell abruptly from 105 to below 100 F. on the second day after operation. The tenosynovitis improved. Prostatic massage and irrigations caused the posterior urethritis to subside. The patient was discharged from the hospital on the fourteenth day after operation, with very good function. The latest follow-up note, three months after operation, shows an almost complete return of function in the ring finger.

The second patient (Case 23) without a history of trauma came to the hospital three days after the onset of his illness. The left ring

Fig. 10 (Case 10, E. B., 1921).—A secondary tenosynovitis of sheath of flexors to the middle finger following an abscess over the palmar portion of sheath, coming to hospital seven days after the onset of the abscess. A small amount of pus was found in the sheath. There was active motion immediately after operation. Optimum end-result with practically complete function in the finger fifteen months after operation is shown.

finger suddenly became painful and swollen. It was very tender; was held in flexion, and the slightest flexion or extension caused excruciating pain. At operation, a considerable amount of cloudy fluid was found within the sheath, from which nothing was grown on culture. The patient had had attacks of gonorrhea eight and four years previously and an epididymitis three weeks prior to the present illness. Following operation, the patient developed successively attacks of fever with pain and swelling in both ankle joints, wrist joints, great toe and

right shoulder; and definite signs of tenosynovitis in other fingers of the same hand. A urethral smear following prostatic massage showed gram-negative intracellular diplococci. The patient remained in the hospital for two and one half months, during which he received prostatic massage, gonococcus vaccines and baking. The subsequent attacks of tenosynovitis were treated without incision. The function of the hand on his leaving the hospital was excellent.

The results in both these cases were practically 100 per cent. recovery of function. Those sheaths which were not drained did fully

Fig. 11 (Case 13, E. M., 1921).—A primary hemolytic streptococcus infection of sheath of flexor pollicis longus, of four days' duration. The portal of entry was at the distal flexion crease. The pus spread above the annular ligament to the space in front of the pronator quadratus. This space was subsequently opened more widely the third day after operation. A culture taken then showed a contamination with Staphylococcus aureus. This case marked the beginning of the use of revised technic which was instituted after the second operation. A great deal of credit for the excellent result must be given to the patient for his tireless effort and unusual courage in early active motion of the thumb. Photographs show the optimum end-result five months after operation. Unfortunately, the thumb was not taken in full extension, a position which was freely attained.

as well as those which were. It is quite fair to raise the question whether this type of tenosynovitis would not always yield to expectant treatment, such as immobilization and traction, with the proper measures applied to any urethral or prostatic focus of infection. One might recommend this procedure did not failure to incise and drain suppurative tenosynovitis early and adequately in those cases due to the streptococcus, staphylococcus, etc., lead to such bad results that, in cases of doubt, it is advisable to risk an unnecessary incision.

TREATMENT

Early incision, accurately located, is the first principle of treatment. The operative procedure should be planned to drain adequately the sheath and any adjoining collections of pus, if these exist. The digital incisions have been for the most part anterolateral, either one or two in each closed space, the middle and proximal spaces most frequently. When single incisions are used, they are generally alternated, as, for example, on the radial side in the middle closed space and on the ulnar side in the proximal space. These incisions should not be placed too far laterally in the closed spaces or the digital vessels and nerves will be divided. The numbness and atrophy which follow such a division are very distressing to the patient. When there is a good deal of subcutaneous pus and necrosis beneath a flexion crease, it is helpful to prolong one of the anterolateral incisions beyond the crease in order to secure adequate drainage. Small cross nicks or transverse incisions in the flexion creases connecting with the anterolateral incision are helpful in relieving tension.

The palmar portion of the sheath should be opened to its full extent by a long median longitudinal incision. The ulnar bursa is opened up to the annular ligament, keeping to the radial side of the deep branch of the ulnar nerve. In only one case was it found necessary to split the annular ligament, and it was then too late to save the tendons from sloughing. We believe there are cases in which the annular ligament should be entirely divided. The radial bursa or sheath of flexor longus pollicis in the palm is opened just to the ulnar side of the thenar eminence. Great caution should be observed lest this incision be continued too far proximally, and the branch from the median nerve to the thenar muscles thus be divided.

We have found delicate instruments absolutely indispensable in this type of surgery. A fine scalpel, small forceps and very tiny sharp and blunt retractors are used. A bloodless field is maintained by either an Esmarch bandage or a blood pressure cuff tourniquet. A careful anatomic dissection is then made, down to the tendon sheath. The sheath is opened with a tiny nick, and then the incision is extended

on a grooved director. With gentle pressure on the surrounding areas, all extensions of pus may be traced and adequately drained. If it is necessary to prolong the operation over forty minutes, the tourniquet is released and reapplied.

Collections of pus above the annular ligament in front of the pronator quadratus muscle are drained by lateral incisions, following closely the shaft of radius and ulna on either side, as described by Kanavel. Drainage of this space by means of volar incisions between the flexor tendons has not been so satisfactory. The drainage material has been for the most part what is called silk binding tape, the incision being packed open with rubber tissue or rubber dam. The rubber tissue or dam gives more bulk and holds the wounds more widely open. This

Fig. 12 (Case 15, R. A., 1921).—Suppurative tenosynovitis of flexor pollicis longus muscle. The portal of entry was at the distal flexion crease. A culture of the pus gave no growth. The space in front of the pronator quadratus was invaded, but there was no spread to the ulnar bursa. Revised technic was employed. The patient was unable to cooperate in early active motion. He showed a wrist drop thought to have been due to pressure neuritis of the radial (musculospiral) nerve from an Esmarch tourniquet used at operation. Photographs show an optimum result six months after operation, with almost complete flexion in thumb. Attention is called to the photograph to the right showing the thumb in three positions.

can be removed at the end of twenty-four hours, while the silk can be removed at the end of thirty-six or forty-eight hours, without bleeding. Prior to 1921, the drains were left in the wounds for an average of six days. During this same period, active motion in the finger was noted on the record in only ten of the thirty-one cases treated, and

the average time when it was first mentioned in these cases was the fifth day after operation. The usual treatment was by means of frequent sterile saline or boric solution drips, soaking or irrigation. Irrigations with surgical solution of chlorinated soda (Dakin's solution) by the Carrel technic, with rubber tubes in the wounds, was used in eight cases, with three good, three bad and two fair results. The one case terminating fatally in the series was treated by this method. Our experience has not justified the use of rubber tubes in the wounds, and we have therefore discarded this form of irrigation with surgical

Fig. 13 (Case 21, M. D., 1922).—A primary hemolytic streptococcus tenosynovitis of the ring finger, the portal of entry being the middle flexion crease. The patient was operated on two days after onset. Revised technic and active motion were employed. The wounds healed uneventfully. Photographs show an optimum end-result six months after operation, with almost normal function.

solution of chlorinated soda. Baking was used in the great majority of cases, often alternated with soaking or with drips.

Early in 1921, our attention was called to the possibility of contaminating these tendon sheath infections. Careless technic in dressing the wounds and the use of soaks of questionable sterility were among the most obvious causes of contamination, serving to counterbalance every

advantage gained by early diagnosis and adequate drainage. The following revised technic was instituted as routine in the treatment of these cases:

The hand and forearm at the time of operation are placed in sterile towels. Two or three hours later when all bleeding has stopped, the towels are removed and the hand is soaked continuously in a 4 per cent. sterile boric solution, with a temperature of 110 F., for twenty-four or thirty-six hours.

Fig. 14 (Case 23, J. B., 1922).—A secondary gonococcus tenosynovitis of the ring finger, operated on three days after onset. Revised technic and immediate active motion were employed. The wound healed uneventfully. Photographs show an optimum end-result with almost normal function, two and one-half months after operation.

This treatment adds very greatly to the patient's comfort, promotes drainage and facilitates active motion, which the patient is encouraged to try from the very beginning. The rubber-dam drains are removed at the end of from twenty-four to thirty-six hours; the hand is placed in sterile towels, and intermittent soaking in boric acid solution is instituted, one hour in and three

hours out. After each soaking, the wounds are irrigated with surgical solution of chlorinated soda by means of a fine capillary pipet. Baking is commenced four or five days after operation, three or four times a day for from twenty to forty minutes at a time, alternated with soaking. As healing progresses, the number of soakings is gradually diminished, until only baking is used. The time to stop the soaking varies, but the condition of the granulations is a very good indication. If they become pale and edematous, so-called water-logged, it is well to discontinue soaking. All drains are removed by the third day after operation.

During this regimen, the patient's hand and forearm are never touched except with sterile gloves or instruments. The frequent irrigations are carried out by those of the nursing staff who have

Fig. 15 (Case 24, R. S., 1922).—A primary Streptococcus viridans and Staphylococcus albus tenosynovitis of the middle finger, the portal of entry being at the distal flexion crease. The patient was operated on seven hours after onset, the earliest case of the series. Revised technic and immediate active motion were employed, the wound healing uneventfully. Optimum end-result with complete function, four months after operation, is shown.

been carefully trained in this technic; while the surgeon dresses the wounds at least once a day. Since the technic must be rigidly enforced, the surgeon cannot delegate responsibility, and hope to achieve good results.

This technic has been used in fifteen cases, five of which were secondary and ten primary, with optimum results in eight, good results in four and bad results in three cases. These figures indicate a 100 per cent. increase in our optimum results.

POSTOPERATIVE COURSE

A patient with a normal temperature five or six days after operation, with healing satisfactory without further operative procedure, has what we consider an uneventful postoperative course, and forty-two of the fifty-seven cases belong in this category. In eleven cases, although the postoperative course was not in any sense alarming from the patient's general condition, subsequent operations were necessary to provide adequate drainage.

Only two of our patients gave the surgeon occasion for grave alarm. Both were trained nurses, one of whom died. The first

Fig. 16 (Case 22, S. A., 1922).—A secondary gonococcus tenosynovitis of the left ring finger, operated on seven days after onset, the wound healing uneventfully. Revised technic and immediate active motion were employed. Photographs, taken three months after operation, show an optimum end-result, with almost normal function.

of these patients developed a suppurative tenosynovitis of the index finger following a paronychia and cellulitis of the distal anterior closed space. The infection, due to a particularly virulent hemolytic streptococcus, developed into a cellulitis of the entire upper extremity. Repeated blood cultures failed to reveal a streptococcus, but for weeks the patient had a high temperature from sepsis. Recovery followed amputation of the finger, and the patient was discharged on the fifty-third day after admission. The second case was a primary hemolytic

streptococcus infection of the sheaths of the thumb and little finger. The hand and fingers seemed to yield readily to drainage, but the infection spread with amazing rapidity up the forearm. Four operations were performed. The temperature remained between 101 and 103 F., and a hemolytic streptococcus bacteremia developed. Amputation of the arm had been decided on, when there was a sudden marked improvement in the patient's general condition. A few hours later, she died from what appeared to be a pulmonary embolism.

It should be noted that of the fourteen patients requiring secondary operations, nine had bad end-results, 64 per cent. as compared to 30 per cent. bad results among all the patients in the series. This fact is a significant indication of the importance of early and adequate drainage.

There were fifteen cases of osteomyelitis of the phalanges or metacarpal bones, with suppurative arthritis in a large percentage of these. One interesting complication was a paralysis of the musculospiral nerve, with consequent wrist drop. This disappeared entirely within three months after operation, and may very possibly have been due to compression neuritis from an Esmarch tourniquet.

END-RESULTS

A study of the end-results in fifty-seven cases summarized in Table 2, in connection with some of the factors influencing them is presented for consideration.

TABLE 2.—*End-Results as Regards Number of Cases*

	Primary		Secondary		Totals	
	No. of Cases	Percentage	No. of Cases	Percentage	No. of Cases	Percentage
Optimum	9	27	6	25	15	26+
Good	8	24	3	12.5	11	19+
Fair	10	30	4	16.6	14	25
Bad	6	18	11	45.8	17	30

1. Time from onset of injury or symptoms until the patient was operated on. Only 19 cases of the series came to the hospital within three days after the onset, and 47 per cent. of these got an optimum result, with 10 per cent. bad results. Of the thirty-eight cases coming to operation over three days after onset, 18 per cent. got optimum results, 40 per cent. bad. The average length of time for all optimum results was three days and fifteen hours; while the average time for all bad results was sixteen days. These facts emphasize the tremendous importance of the time element. The chance of getting a good result in a tendon sheath infection diminishes rapidly as time passes before operation.

2. Secondary and primary groups contrasted. A glance at Table 2 will show a striking contrast between the results in the primary and in the secondary groups. With 45.8 per cent. bad results and 25 per cent. optimum results in the secondary group, compared to 18 per cent. bad and 27 per cent. optimum results in the primary group, one can easily appreciate that the chance of getting a useful hand or finger is considerably better in the primary group. The secondary cases have usually come to the hospital after considerable treatment.

3. Previous treatment. In an attempt to discover the relation between end-results and treatment prior to admission to the hospital,

Fig. 17 (Case 25, A. W., 1922).—A secondary Staphylococcus aureus tenosynovitis of the middle finger following an abscess of the proximal anterior closed space. Definite symptoms developed and the condition was recognized immediately. The patient was operated on one day after onset of the sheath infection, revised technic and immediate active motion being employed, and the wound healing uneventfully. An optimum end-result, with almost complete return of function is shown four months after operation.

the patients have been divided into two groups. In one group are included all patients with previous surgical treatment, and in the other group, all patients without previous surgical treatment. There were thirty-one cases in the previously treated group, with 42 per cent. bad results and only 9 per cent. optimum results. The twenty-six surgically untreated cases had only 8 per cent. bad and 50 per cent.

optimum results, in marked contrast. The time element cannot however be disregarded, as the previously treated cases invariably arrived later at the hospital.

4. Micro-organisms. The staphylococcus cases showed a high percentage of good and optimum results. The cases with mixed staphylococcus and streptococcus recovered from pus at the time of operation had a high percentage of bad results, as did the cases secondarily contaminated and then presenting a similar mixed growth. The streptococcus cases with other factors favorable, such as time after onset, no previous treatment, etc., yielded some of the best results.

5. Postoperative treatment. To realize fully the important bearing this has upon end-results one has but to review the fact that, in the last fifteen cases treated by the revised technic, there were 53 per cent. optimum results and 78 per cent. good or better, a marked contrast to the similar percentage of the entire series. In addition to this scrupulous care in dressing, early removal of drains has been insisted on. The remaining factor in the postoperative treatment is early active motion. The patient is urged, at times driven, to move the finger immediately after operation. His cooperation is invaluable in this matter.

6. Chronic arthritis. This complication has been noted in two cases, and in both of them, a fair or good immediate result has been completely nullified, and the finger has become stiff and deformed. Many patients well past middle age show a tendency toward this condition, which is an unfavorable factor in an effort to obtain a good result (Case 4).

CONCLUSIONS

In the course of this series, we have studied the evidence presented by the individual case, endeavoring to learn something from each patient. At the end of every case on our summary sheets, we have drawn up a conclusion on that particular case, preparatory to reaching conclusions on the series as a whole. Every case offers something of interest, but certain facts stand out as common to many or to all of them. From these facts, we have drawn the following conclusions, which we present, not as preconceived theories or formulated ideas, but rather as a summary of amassed evidence.

1. The suppurative infections of the tendon sheaths fall naturally into two groups. The primary group, in which the infection is primarily that of the tendon sheath, usually gives the classic picture of tenosynovitis. In this group lies the greatest opportunity for obtaining good results by means of proper treatment. The secondary group, in which the sheath is usually invaded as an extension from some other

preexisting suppurative process in the hand or a distant focus, is frequently not recognized until late, and has a much less hopeful prognosis than the primary group.

2. The flexor tendon sheaths are most frequently infected from wounds at the digital flexion creases. Wounds at these points should always be considered as predisposing to suppurative tenosynovitis.

3. Time must not be lost in making a diagnosis, as every hour lost diminishes the patient's chance of a good end-result.

4. Wounds due to human bites should be primarily debrided.

5. The hemolytic streptococcus is the most frequent invading organism. The wound healing and end-results have varied considerably with the different micro-organisms.

6. Conservative treatment in gonococcus tenosynovitis, owing to the resemblance of this condition to tenosynovitis due to the pyogenic micro-organisms, is not without danger.

7. A tendon sheath already infected may be secondarily contaminated by another variety of micro-organism through careless technic. Such cases frequently have bad end-results.

8. Tendon sheath infections which are temporized with by means of inadequate and poorly placed incisions usually do badly.

9. Employment of special delicate instruments; careful dissection in a bloodless field, and the use of small strips of binding silk and rubber dam as drainage material, to be early removed, are recommended.

10. A revised technic described above, in which a painstaking effort is made to keep the wounds uncontaminated, has yielded 100 per cent. better results than our previous methods.

11. Early active motion, following almost immediately after recovery from the anaesthesia, is most advisable. Soaking in hot solutions will aid materially in attaining this objective, but a great deal depends on the cooperation of the patient.

12. It stands to reason that these patients should be hospitalized, as the foregoing treatment cannot be carefully supervised in ambulatory cases. They should be kept in the ward until their wounds are almost, if not quite, healed, as an important safeguard against secondary contamination.

13. The presence of, or a tendency to, chronic arthritis in the fingers makes a poor prognosis for the recovery of function.

14. In recapitulation, to attain optimum results in suppurative tenosynovitis the desiderata are: (*a*) early diagnosis and immediate operation; (*b*) properly placed, adequate incisions, draining all collections of pus; (*c*) avoidance of unnecessary trauma; (*d*) early removal of drains; (*e*) early and continued active motion, and (*f*) prevention of secondary contamination of the infected sheath.

CORRESPONDENCE

"BLOOD TRANSFUSION: A STUDY OF TWO HUNDRED AND FORTY-FIVE CASES"

To the Editor.—Dr. Horsley's report, under "Correspondence" in the September issue of the ARCHIVES, of thirty direct blood transfusions, in addition to the twenty-four transfusions he had previously reported as being performed without a subsequent chill or unusual rise of temperature, is a remarkable one. It speaks well for his and for his associates' technical ability in vascular surgery and justifies the particular method used by them. However, other writers have reported many cases of direct transfusions of blood by vascular suture and cannula followed by severe reactions; so that it can hardly be said in general to be a method "that is not followed by a varying percentage of reactions." There have been exceptional series of cases by other methods of transfusion. The late Dr. Lindeman reported 214 cases of blood transfusion by the syringe cannula technic without a subsequent chill; yet one would hardly claim that technic to be free from posttransfusion reactions. There have been a small number of consecutive cases of transfusion at Barnes Hospital without reaction. The word reaction is used to include all manifestations of agglutination, hemolysis, anaphylaxis, chills, febrile reactions, etc.

This series of fifty-four cases without a posttransfusion reaction is more interesting in view of the evidence lately presented by Guthrie and Huck in the *Bulletin of the Johns Hopkins Hospital,* "On the Existence of More Than Four Iso-Agglutinin Groups in Human Blood." I have thought that part of our posttransfusion reactions might be due to some of these heretofore unknown agglutinins, but evidently they are not great factors in reactions, as surely they would have caused a reaction in a few of the fifty-four cases reported. It will be interesting to know Dr. Horsley's method of determining compatibility of blood.

Transfusion of arterial instead of venous blood may be advantageous, but I cannot agree with Dr. Horsley that the "measurement of the amount of blood transfused seems immaterial." The knowledge of the quantity of blood transfused seems essential for the welfare of both donor and recipient, as well as the rate of flow of the blood, which is also unknown in a direct transfusion.

Dr. Horsley has suggested in his letter that there are technical difficulties in a direct transfusion, and he mentions the aversion of most professional donors to having their blood vessels exposed and incised. He also writes, in his book "Surgery of the Blood Vessels" of "some unsatisfactory results from a mechanical standpoint" in his early cases performed by this method. There is a current objection among professional donors in this locality to any operation on their vessels except puncture.

Furthermore, direct transfusion by vessel anastomosis seems to offer a greater opportunity than other methods for the formation of thrombi and emboli, for intravascular entrance of air and for clotting, to cause a failure of the transference of blood. Many transfusions are emergency procedures, and there is not time to make a blood Wassermann test on the recipient or to determine in certain recipients whether there is a septicemia present before

transfusion. The apposition of the tissue of such a recipient to a donor's open wound is not desirable and may be mentioned as an objection to the method.

These factors militate against ease of performance of a direct transfusion by vascular suture or cannula and, hence, against its becoming a popular general method. In spite of Dr. Horsley's outstanding record of no reactions following fifty-four transfusions and the fact that "posttransfusion reactions are harmful," I believe technics other than direct transfusion by vessel anastomosis are preferable because of the objections mentioned and that they will be rightfully used except by the few who possess the technical skill characteristic of Dr. Horsley's clinic, which is necessary for direct transfusion.

Glover H. Copher, St. Louis.

INDEX TO VOLUME 7

Anesthesia, deetherization by means of carbon dioxid inhalations, with some observations on pulmonary ventilation and ether tension during anesthesia; J. C. White 347
Ankle, fractures, prognosis and treatment; end-results; A. P. C. Ashhurst and E. T. Crossan 601
Appendicitis, skin signs or viscerosensory phenomena in acute appendicitis; E. M. Livingston 83
Ashhurst, A. P. C., and Crossan, E. T.: Prognosis and treatment of fractures of leg and ankle 601

Bagley, C., Jr.: Extensive hemorrhagic extravasation from venous system of Galen, with a clinical syndrome 237
Blair, V. P., and Padgett, E. C.: Pyogenic infection of parotid glands and ducts 1
Blood, transfusing of unmodified blood; O. A. Brines 306
transfusion: study of 245 cases; G. H. Copher 125, 687
"transfusion: study of 245 cases"; J. H. Horsley 466
Bone, study of viability of bone after removal from the body; S. L. Haas .. 213
tumors, clinical and pathologic study of 10 bone tumors; J. J. Morton and W. C. Duffy 469
tumors, unusual alteration in natural history of a giant cell tumor of bone; W. S. Stone and J. Ewing 280
Book Reviews:
Reconstructive Surgery of the Upper Extremity; A. Steindler 465
Boorstein, S. W., and Landsman, I. J.: Treatment of fractures by orthopedic methods 633
Brain abscess, with especial reference to abscess of frontal lobe; H. H. Kerr 297
hemorrhage, extensive hemorrhagic extravasation from venous system of Galen, with a clinical syndrome, report of 3 fatal cases with 2 necropsies; C. Bagley, Jr 237
Brines, O. A.: Transfusing of unmodified blood 306
Brown, L. T., and others: Twenty-first report of progress in orthopedic surgery 415
Bucholz, C. H., and others: Twenty-first report of progress in orthopedic surgery 415

Carbon dioxid, deetherization by means of carbon dioxid inhalation with some observations on pulmonary ventilation and ether tension during anesthesia; J. C. White 347
Cattell, Mc.: Studies in experimental traumatic shock: the influence of morphin on blood pressure and alkali reserve in traumatic shock .. 96
Chouke, K. S., and Seelig, M. G.: A fundamental factor in recurrence of inguinal hernia 553
Cleveland, M.: Suppurative tenosynovitis of flexor muscles of hand 661
Colon, resection of proximal colon for malignancy; F. W. Rankin and A. J. Scholl 258

Copenhaver, N. H.: Intra-abdominal hernias..... 332
Copher, G. H.: Blood transfusion: study of 245 cases.....125, 687
Crile, G. W.: Studies in exhaustion: V. hemorrhage..... 154
Crossan, E. T., and Ashhurst, A. P. C.: Prognosis and treatment of fractures of leg and ankle..... 601

Danforth, M. S., and others: Twenty-first report of progress in orthopedic surgery 415
Desmoid tumors, report of thirty-one cases; R. W. Nichols..... 227
Duffy, W. C., and Morton, J. J.: A clinical and pathologic study of 10 bone tumors..... 469

Ely, L. W.: Notes on 5 cases of Paget's deforming osteomyelitis..... 532
Empyema necessitatis and some allied conditions; F. J. Tees..... 321
Endothelioma of spleen, study of 2 cases, with review of literature of primary malignancy of spleen; C. E. Smith and G. Y. Rusk..... 371
Ewing, J., and Stone, W. S.: Unusual alteration in natural history of a giant cell tumor of bone..... 280
Exhaustion, studies in: V. hemorrhage; G. W. Crile..... 154

Fibula, fracture, prognosis and treatment of fractures of leg and ankle, end-results in 100 patients; A. P. C. Ashhurst and E. T. Crossan.... 601
Fistula, physiology of an arteriovenous fistula; E. Holman..... 64
Fractures of leg and ankle, prognosis and treatment; end-results in 100 patients; A. P. C. Ashhurst and E. T. Crossan..... 601
treatment of fractures by orthopedic methods; S. W. Boorstein and I. J. Landsman 633

Galen's veins, extensive hemorrhagic extravasation from venous system of Galen, with a clinical syndrome, report of 3 fatal cases with 2 necropsies; C. Bagley, Jr..... 237
Giant cell tumor, unusual alteration in natural history of a giant cell tumor of bone; W. S. Stone and J. Ewing..... 280
Goiter, end-results of surgery of thyroid gland; J. deJ. Pemberton..... 37

Haas, S. L.: Study of viability of bone after removal from the body..... 213
Hemorrhage, studies in exhaustion: V. hemorrhage; G. W. Crile..... 154
Hernia, inguinal, a fundamental factor in recurrence of inguinal hernia; M. G. Seelig and K. S. Chouke..... 553
intra-abdominal hernias; N. H. Copenhaver..... 332
Holman, E.: The physiology of an arteriovenous fistula..... 64
Horsley, J. H.: "Blood transfusion: a study of 245 cases"..... 466

Injections, prolonged intravenous infusion and the clinical determination of venous pressure; W. G. Penfield and D. Teplitsky..... 111
Intestine, cancer, resection of proximal colon for malignancy; F. W. Rankin and A. J. Scholl..... 258
traumatic lesions of intestine caused by nonpenetrating blunt force; B. M. Vance..... 197

Kerr, H. H.: Brain abscess; with especial reference to abscess of frontal lobe 297

Landsman, I. J., and Boorstein, S. W.: Treatment of fractures by orthopedic methods..... 633

Livingston, E. M.: The skin signs or viscerosensory phenomena in acute appendicitis 83
Low, H. C., and others: Twenty-first report of progress in orthopedic surgery 415

McVeigh, J. F.: Experimental cord crushes, with especial reference to mechanical factors involved and subsequent changes in areas of cord affected 573
Morton, J. J., and Duffy, W. C.: A clinical and pathologic study of 10 bone tumors 469
Murray, H. A. Jr.: The chemical pathology of pyloric occlusion in relation to tetany, a study of chlorid, carbon dioxid and urea concentration in blood 166

Nicholson, B. B.: Histopathology and etiology of varicose veins 47
Nichols, R. W.: Desmoid tumors: report of 31 cases 227

Orthopedic surgery, treatment of fractures by orthopedic methods; S. W. Boorstein and I. J. Landsman 633
twenty-first report of progress in orthopedic surgery; R. B. Osgood, R. Soutter, H. C. Low, M. S. Danforth, C. H. Bucholz, L. T. Brown, P. D. Wilson and M. N. Smith-Petersen 415
Osgood, R. B., and others: Twenty-first report of progress in orthopedic surgery 415

Padgett, E. C., and Blair, V. P.: Pyogenic infection of parotid glands and ducts 1
Paget's deforming osteomyelitis, notes on 5 cases with description of a specimen of a femur from a sixth; L. W. Ely 532
Parotid Duct, pyogenic infection of; V. P. Blair and E. C. Padgett 1
Parotid Gland, pyogenic infection of; V. P. Blair and E. C. Padgett 1
Pemberton, J. deJ.: The end-results of surgery of thyroid gland 37
Penfield, W. G., and Teplitsky, D.: Prolonged intravenous infusion and the clinical determination of venous pressure 111
Pyloric occlusion, the chemical pathology of pyloric occlusion in relation to tetany, a study of chlorid, carbon dioxid and urea concentration in blood; H. A. Murray, Jr 166

Rankin, F. W., and Scholl, A. J.: Resection of proximal colon for malignancy 258
Rusk, G. Y., and Smith, C. E.: Endothelioma of spleen; study of 2 cases, with review of literature of primary malignancy of spleen 371

Seelig, M. G., and Chouke, K. S.: A fundamental factor in recurrence of inguinal hernia 553
Scholl, A. J., and Rankin, F. W.: Resection of proximal colon for malignancy 258
Shock, studies in experimental traumatic shock; the influence of morphin on blood pressure and alkali reserve in traumatic shock; McK. Cattell 96
Smith, C. E., and Rusk, G. Y.: Endothelioma of spleen; study of 2 cases, with review of literature of primary malignancy of spleen 371
Smith-Petersen, M. N., and others: Twenty-first report of progress in orthopedic surgery 415
Soutter, R., and others: Twenty-first report of progress in orthopedic surgery 415

Spinal cord, experimental cord crushes, with especial reference to mechanical factors involved and subsequent changes in areas of cord affected; J. F. McVeigh 573
Spleen, endothelioma, study of 2 cases, with review of literature of primary malignancy of spleen; C. E. Smith and G. Y. Rusk 371
Stone, W. S., and Ewing, J.: Unusual alteration in natural history of a giant cell tumor of bone 280

Tees, F. J.: Empyema necessitatis and some allied conditions 321
Tenosynovitis, suppurative tenosynovitis of flexor muscles of hand; M. Cleveland 661
Teplitsky, D., and Penfield, W. G.: Prolonged intravenous infusion and the clinical determination of venous pressure 111
Tetany, the chemical pathology of pyloric occlusion in relation to tetany, a study of chlorid, carbon dioxid and urea concentration in blood; H. A. Murray, Jr 166
Thyroid, the end-results of surgery of the thyroid gland; J. deJ. Pemberton 37
Tibia, fracture, prognosis and treatment; end-results; A. P. C. Ashhurst and E. T. Crossan 601
Transfusion: See Blood transfusion.

Vance, B. M.: Traumatic lesions of intestine caused by nonpenetrating blunt force 197
Varices, histopathology and etiology of varicose veins; B. B. Nicholson 47
Venous pressure, prolonged intravenous infusion and the clinical determination of venous pressure; W. G. Penfield and D. Teplitsky 111

White, J. C.: Deetherization by means of carbon dioxid inhalations, with some observations on pulmonary ventilation and ether tension during anesthesia 347
Wilson, P. D., and others: Twenty-first report of progress in orthopedic surgery 415

RD
1
A72
v.7
Biological
& Medical
Serials

Archives of surgery

PLEASE DO NOT REMOVE
CARDS OR SLIPS FROM THIS POCKET

UNIVERSITY OF TORONTO LIBRARY

STORAGE